

Clinical Psychological Aspects within The Concept of Pediatric Dentistry

Oprea Valentin BUȘU¹

Mihaela Cristina STAN²

Elena Cristina ANDREI³

¹Assist., PhD, Teaching Staff Training Department - University Of Craiova,

² Department of Dental Prosthesis Technology, Faculty of Dental Medicine,

University of Medicine and Pharmacy of Craiova

³Stud., Faculty of Dentistry, University of Medicine and Pharmacy of Craiova

Abstract

In this paper we aim to describe the pediatric dentistry (pedodontics) which is a branch of dental medicine dealing exclusively with children and adolescents, being a field that has experienced an impressive development over the past years in our country, being introduced as a specialty in the program of residency in 2016.

The purpose of this article is to highlight a number of clinical and psychological aspects resulting from a study of a sample of 10 children on the behavior adopted in the dental office in two distinct situations: in the presence of parents and in their absence. It is extremely important that at the age of 6 months the child should have his first visit at the dentist, followed by yearly checks, in order to familiarize the child with dentistry, thus preventing the establishment of anxiety towards the dentist.

Based on the analysis of the two situations, we noticed the following: children who were assisted by parents in the dental office tended to be much more agitated, non-cooperating, permanently anxious, being mostly influenced by the way in which

the parent talks, threatens or even involuntarily induces their fear of the dentist. In the case of unaccompanied children, a stronger relationship was observed between the patient and the dentist, the children being more attentive to what their doctor explains, gained confidence and became more self-assured, becoming aware of the role of maintaining a good oral hygiene.

Keywords: baby tooth, child psychology, clinical cases, pediatric dentistry, Tooth Fairy

THE PURPOSE OF PEDIATRIC DENTISTRY

Pediatric dentistry aims at maintaining the oral health of children and adolescents, preventing the occurrence of oral cavity diseases and the curative treatment of injuries already installed. Unlike other branches of dentistry, pedodontics involves the accumulation of knowledge in the following areas: child and adolescent psychology, child development, age-related prophylactic and curative methods and techniques. If doctors in other dental care sectors tend to tackle dental stomach injuries in adults, dental pediatricians know that there are major physiological and psychological differences. A temporary tooth ("baby tooth") is not similar to a permanent tooth from a morphological and functional point of view, nor from the point of view of its histological composition. The first significant difference is the physiological rhythm of growth and formation of the tooth, given that the temporary tooth is subjected to the rhizome process. The rhizome process translates into the resorption of the root, which leads to the mobility of the dental crown and finally to the exfoliation of the tooth from the dental arch. (Bataiosu, pp. 34-35). With regard to the number of teeth it is noted that temporary dentition is characterized by a smaller number of dental units (20), because the premolars are not present, they appear later, replacing the one and two temporary molars. Also, temporary teeth have a lighter color

compared to permanent teeth that tend to develop yellow or even gray nuances. (Bataiosu, p.24). The reason why it is often necessary to extract the temporary tooth compared to the permanent tooth is not that it will eventually disappear from the arcade shortly and there will be another tooth in its place, but the fact that the roots of temporary teeth present a complex morphology, sometimes having a "ribbon" aspect. This morphology leads to the failure of the endodontic treatment of tooth preservation and maintenance.

Not only the teeth of children and adolescents are different from adult dental structures, but also the tissues of the oral cavity. These have a high degree of sensitivity, especially to radiation and trauma, and this is the reason why it is recommended to reduce the time for radiological examinations, but also to protect children who play different sports. The increased sensitivity of young tissues derives from the fact that these tissues are incomplete, not yet mature.

As far as the management of dental pain in children is concerned, the tendency of parents to resort to various sources such as pharmaceutical workers or general practitioners for the purpose of treatment has been observed over time. This has often led to a worsening of the already existing situation because the pathology of the child's oro-maxillofacial sphere is extremely complex and does not respond to the same type of medication as in the case of an adult. (Mason, 1997). Another major problem faced by pediatricians is the lack of information from parents about the frequency and role of dental checks. Most children come to the dental office when teeth damage is at an advanced stage. Although the severity of the condition does not produce a psychological impact on the physiological aspect (Granville, 2018), but only a strong emotional impact caused by pain, during the teen years is unaesthetical. Starting from this type of situation, the period of adolescence will be marked by depressive episodes, anxiety or even anorexia / bulimia. At a difficult age, of contrasts, but also of the discovery of one's own identity, the teenager will be deeply marked by the perception

of those around him (especially his group of friends, colleagues). The degree of influence of the crowd is a key element in the emergence of social and psychological disorders, and the unfavorable aspect of teeth is a factor that is not to be neglected in this context. According to McDougall (1920) primitive instincts occupy an important place in triggering anxiety and anger. Thus, through the acidic comments of people around the adolescent, as well as through social discrimination or marginalization, we can witness the installation of the anonymity effect (Le Bon, 1908; Voinea, Negrea & Teodorescu, 2016). Therefore, the child should not be considered a "small adult" because he is a particular entity with completely different body structures from an anatomical, physiological and psychological point of view (Călin & Teodorescu, 2016; Vlăduțescu, 2018; Unguru & Sandu, 2018).

CHILD AND ADOLESCENT ANXIETY IN THE DENTAL OFFICE

Anxiety can be defined as a fear of a situation / thing without a well-founded reason (Anne, 2009, p. 13). Anxiety theories are divided into two categories: biological theories and psychoanalytic theories. Biological theories emphasize the fact that many biological processes are related to this disorder, but the enigma of these theories lies in the uncertainty about the moment when these processes are triggered (Iorgulescu, 2017, p. 72). There are two possibilities: either biological processes are secondary to a psychological mechanism or vice versa. The psychoanalytic theories of anxiety are divided into three main classes: Freudian, non-Freudian theories, and the cognitive theory of social learning. Freudian theory claims that there are three types of anxiety: objective, moral and neurotic (Freud, 1933). He also argues that moral and neurotic anxiety are the ones that lead to the establishment of psychological disorders. Objective anxiety occurs in the case of all individuals and is considered to be a rational

process, representing the ability of the human being to defend itself from dangers in the external environment.

The dental anxiety of children and adolescents in most cases is the result of an inappropriate approach to the first visit to the dentist. The failure of the first visit to the dentist can be blamed on the medical staff, parents or both sides. This first contact of the child with dentistry is of particular importance because it will influence for a very long time the child's conception of how to perceive the dental act. Some of the dentist's mistakes that may compromise the consultation are: stiffness, poor communication, the use of formal language containing medical terms that can trigger fear (eg injection, syringe, extractors, scalpel). Parents are often very stressed at the first visit of the child to the dentist, which makes their anxiety condition immediately perceived by the child and it leads to anxiety, agitation, irritability. (Iorgulescu, pp. 121-122, 2017). In this case the nurse has a pivotal role, her tasks being: creating a friendly environment to calm and encourage the little patient; in clinical cases requiring anesthesia it is advisable to have the syringe prepared in a place inaccessible to the child's visual area or even the use of caps for syringe in various forms (animals, princesses, superheroes). (Porter, p. 86, 2011).

Within the FAD concept (fear and anxiety of the dentist), H.R. Chapman and K. Turner (1999) have stated that there are five factors to trigger anxiety:

- fear of pain and its anticipation;
- distrust, but also the fear of being betrayed;
- fear of losing control of the situation;
- fear of the unknown;
- fear of intrusion.

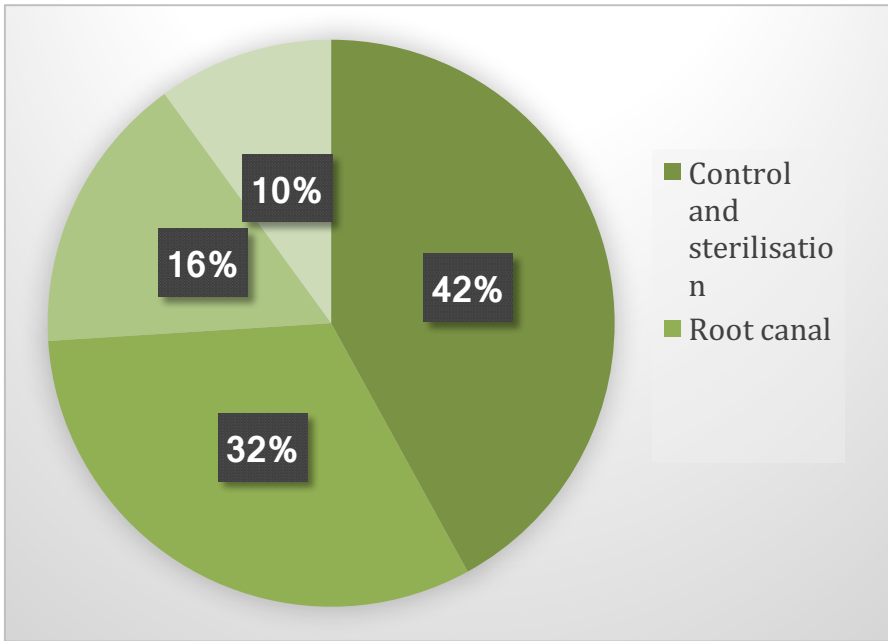
As methods of preventing or reducing anxiety in the dental office, we mention the Tell.Show.Do method and the MEOPA method. (Statov, p. 5, 12, 2011). The Tell.Show.Do method involves explaining to the patient what treatment will be given,

but in a positive, encouraging and non-complex or fearful medical terms way, the next step is to demonstrate the doctor's procedure, and the last step, being the most attractive for the little patient, consists in handling and exploring various instruments, appliances or dental materials. (they are carefully chosen to prevent possible injuries during their operation). The MEOPA method refers to anaesthesia that is carried out with the help of nitrous oxide to induce the relaxation state. However, this technique provides for a number of contraindications such as:

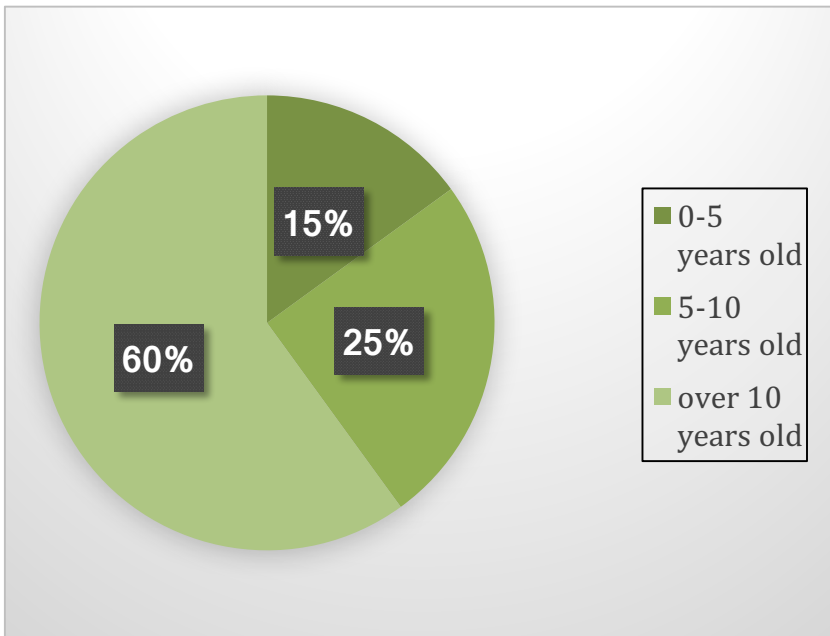
- patients with nasal obstruction or obstruction at the Eustachio tube;
- patients with perforations in the eardrum;
- discerning or non-cooperating patients; those with severe psychiatric disorders;
- patients with obstructive chronic bronchopneumopathy;
- patients with oncological conditions who undergo chemotherapy with bleomycin;
- patients with multiple sclerosis neuromuscular diseases;
- patients with hippocampus, especially vitamin B12, because nitrous oxide reduces vitamin B12 levels.

We conducted a study on the assessment of anxiety in a sample of 178 adolescents, using the questionnaire method containing simple, multiple complement questions and a last free-answer question. The results obtained indicated:

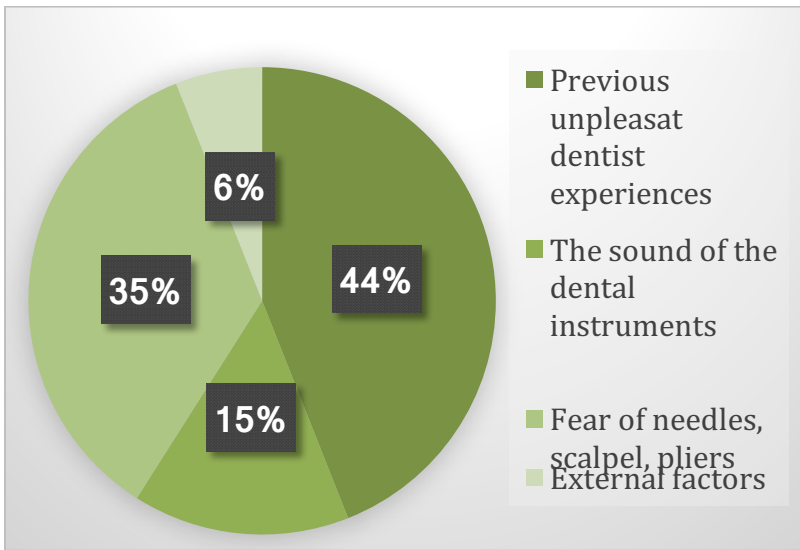
I. Frequent reasons for presenting to the dentist:



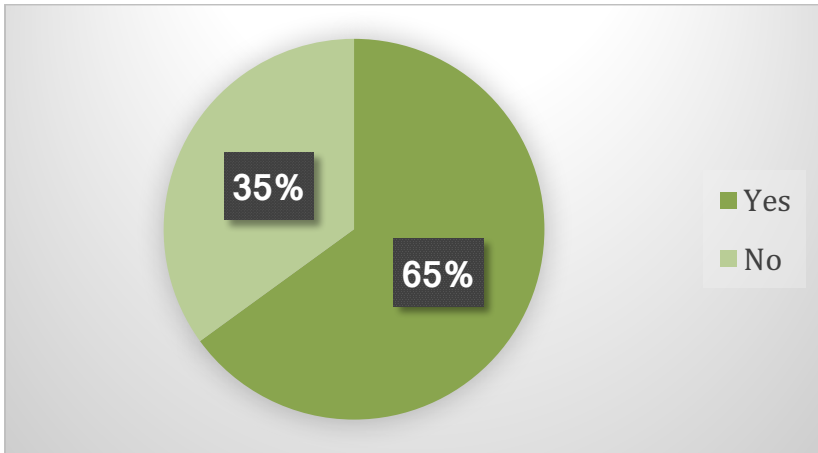
II. First visit to the dentist



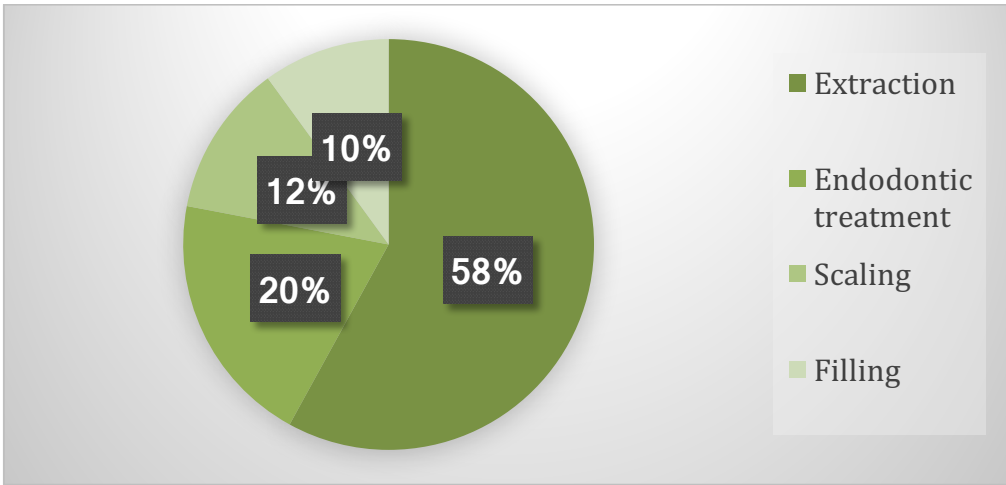
III. Causes of dental anxiety



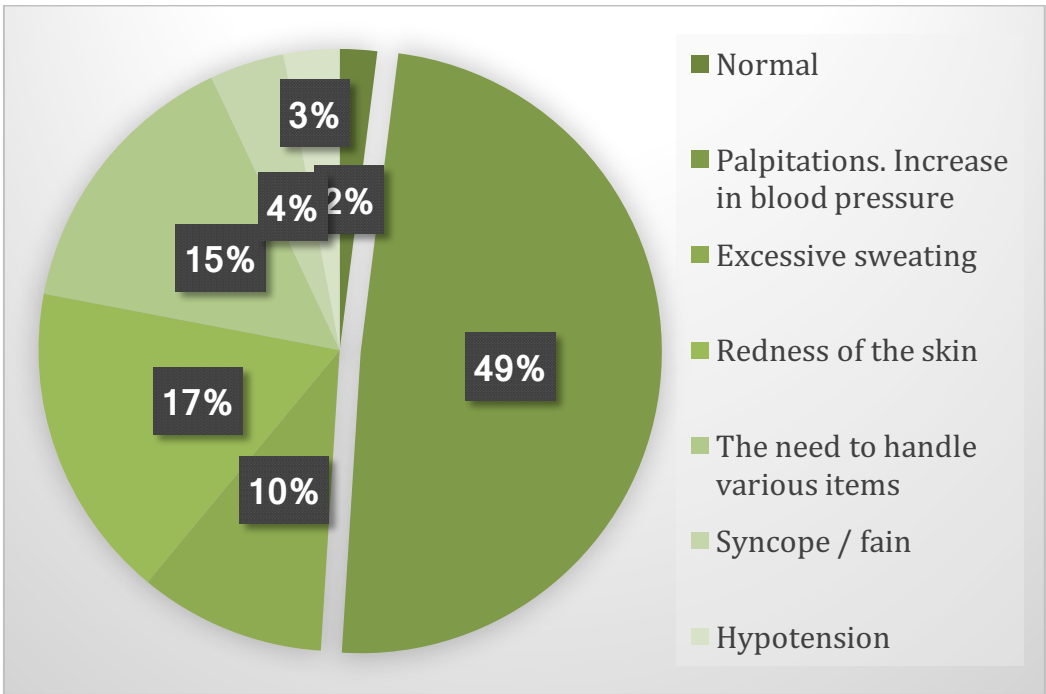
IV. Would gas anaesthesia be a solution to ameliorate dental anxiety?



V. Selection of the most traumatic dental treatment



VI. Patient status during dental treatment:



CLINICAL CASES

We conducted a study in a dental office on a sample of 10 patients aged between 7 and 16 years old, divided into two categories: those who are accompanied in the dental office by the parent and those who come unaccompanied.

Case no. 1

The F.A., 8-year-old male, appeared in the dental office for periodic and hygiene control. He insisted on being accompanied by his mother in the cabinet, and the discussions with him and his mother revealed that he had an unpleasant previous experience of visiting the dentist because the dentist had not had enough patience with him, even raising his voice. This incident prompted the child to avoid as much as possible visits to the dentist. When examining the oral cavity, we discovered multiple cavities, the coronary fracture of a tooth, bacterial plaque deposits and tartar due to the increased consumption of sweets and carbonated beverages, but also the dental presence of a temporary tooth whose functional period had ended by about one year. We decided to limit ourselves to familiarizing the child with the dental sphere at this first session, and turned to activities such as the coloring of dental illustrations with an educational role, watching a movie explaining the role of oral hygiene and periodic control to the dentist. At the second session, we ensured that the child's condition was normal, relaxed and we started with minimally invasive (non-traumatic) maneuvers: professional brushing, scaling, then we explained the role of tooth sealing and let him choose the color he wanted to seal his teeth (he chose the blue color), I made local fluoridation, leaving the aroma of the fluoride to the patient's choice (chose caramel flavor). The second meeting ended successfully, meeting all the goals we have set ourselves. In the third session, we went to more complex operations: occlusal coronary obturation and temporary superior incisor extraction. If there were no complications

in the case of obturation, there were some hesitations in the extraction process from the child, but I was relieved, we performed anesthesia with anesthesia spray at the site of extraction and only used compressions for extraction, to avoid fear. At the end of the session, I gave the little patient a letter that she had to complete on herself to the Tooth Fairy. It should be noticed that during all sessions the child has been agitated and anxious every time his mother intervened, thus hindering the act of the therapist and requiring a longer time for the session.

Case no 2

The 16-year-old B.P., male, is present in the dental office for hygiene and coronary obturation at the lower two molar. He chose to come unaccompanied by the parent, waiting in the waiting room where he completed the anamnesis, because at the age of 16 the patient is still minor and the consent regarding the dental services is given by the parent / guardian authority. In the endo-oral examination, we noticed, besides the problems the patient had evoked, a dento-alveolar incongruence through severe spacing, namely the existence of large spaces between the teeth, as well as an accentuated vestibularisation of the teeth. Following the discussion with the patient, I found out that he refused to wear an orthodontic device because school colleagues and a group of friends often made jokes and mischievous remarks about this treatment. At that moment, I asked him a series of questions to find out about his orthodontic treatment and came to the conclusion that he does not consider the braces as an unpleasant accessory, but the opinions and influence of those around him are those that he was saying, have determined not to follow the treatment. After giving him many examples of personalities who wore braces, and also his own example (currently wearing braces), he started to look at things differently and be more confident in the decisions he should take. Thus, the patient gained courage and after having done his

treatment, he went and made an appointment to the orthodontist to correct the aesthetics of his teeth.

BABY BOTTLE CAVITIES - PSYCHOLOGICAL AND SOCIAL IMPLICATIONS

Most parents tend to neglect cavities of the temporary teeth, and this attitude leads to irreparable negative consequences. This type of cavity occurs because of nocturnal breastfeeding, the use of excess sweet liquids, and of the frequent use of the baby bottle after the child has acquired the first temporary tooth. (Bataiosu, pp. 43-44, 2010). One of the major consequences of bottle feeding, that has a strong psychological and social impact, is due to the location of the cavities on the front teeth, which are always visible. Thus, a baby with baby bottle cavities will end up with problems when it comes to entering a social environment such as kindergarten. At an early age, children are prone to criticism, but also to make negative assessments of the physiognomy, the result being social isolation, separation from the social environment, and also lowering school performance. Another negative consequence of bottle feeding is the fact that this affection influences the development of permanent teeth. We can see that in most cases, if a child has been affected by this type of cavity, it will present permanent structural defects, defects characterized by both chromatic changes (teeth with yellow or brown spots) and changes in structure (imperfect amelogenesis or dentinogenesis, translated by insufficient development of enamel or dentin, resulting in fractures of the tooth, which develops a high degree of fragility). The loss of pertinent dental structures at the age of adolescence will drastically affect the facial appearance, and the teenager will be prone to psychological disorders such as depression, anorexia or bulimia. As preventive treatment, we can indicate fluoridation both locally and globally (Pătroi, 2001, p. 64-75).

MANAGING THE CHILD'S EMOTIONS IN THE DENTAL OFFICE

In the case of very young children, aged between 6 months and 2 years, both the dentist and the parents often face the problem of crying. They must understand that crying is a way of indirectly communicating states, feelings, or even systemic disorders (Nessia, 2008, p. 44). In this situation, it is very important to remain calm and to find out the cause that triggered crying and solving it. A state of restlessness and anxiety on the part of the doctor or parent would only amplify the child's already installed state. Also, the dentist can inform parents about the behavioral aspects of the child or behavioral changes, identifying anxiety or depression in the anamnesis (Jacques, 2011, p. 43). Of particular importance is the communication of the doctor with the patient. To make communication more effective, but also to make the child behave appropriately without affecting his / her self-esteem, it is advisable for the physician to predominantly use first-person messages (Thomas, 2011, pp. 129-130). like "I'm disappointed that you did not wash your teeth as I told you," compared to second-person messages: "You're a disobedient child!" If in the first situation one can notice a transmission of the feeling of disappointment of the doctor to the child, in the second situation the child will understand only that he is disobedient and bad.

In the case of adolescents, the situation is much more different, because they are at an age when they discover themselves, they form an image of both their own person and the world around them (Ann, 2000, pp. 256-257), often being dominated by internal conflicts. (Boyte, 2017, p. 16). The dentist must show patience and understanding about their aesthetic requirements and explain the negative consequences of the treatments for which they generally opt (lip augmentation, dental bleaching, dental jewelry). Another extremely important feature of the doctor is empathy (Gill, 2016, p. 51). In many situations, he has to translate into the patient's

place and understand why the patient chose to make different changes in his oro-facial appearance.

ART TECHNIQUE IN PEDIATRIC DENTAL TREATMENTS

The ART technique (atraumatic restorative treatment) is a treatment solution that can be applied to both temporary and permanent teeth for people with anxiety about the dentist. (Bataiosu, 2010, p. 60). The method consists in the removal of the superficial altered layer of the teeth using only hand tools, not rotational ones, with the aim of not traumatizing the child by the noise produced (Tuculina, 2009, p. 18). This method has numerous advantages, such as the use of biocompatible fillings that continuously remove fluorine and help to remineralize the structure (glass ionomer cement), is a minimally invasive method and has a low price (Srivastava, 2011, p. 199). As a disadvantage of the method, we can mention that it can not be used in clinical situations with profound lesions.

CONCLUSION

To conclude, pediatric dentistry is a complex area of dental medicine that is not strictly limited to the treatment of oral cavity lesions and disorders, but it integrates in addition to the dental and psychological notions of the child, as well as knowledge from the field of pediatrics with the purpose of understanding the stages of child growth and development.

REFERENCES

- Bacus, A. (2009). *Ajută-ți copilul să-și învingă frica*. București: Editura Teora.
- Bataiosu M. (2010). *Pedodonție. Vol. I*. Craiova: Editura Universitaria
- Birch, A. (2000). *Psihologia dezvoltării*. București: Editura Tehnică.
- Boyte, L. (2017). *Adolescența- Magna cum laude parental*. Editura SITECH. Craiova

Busu, O. V. and Andrei, E. C. (2017). *Managing a Dental Practice and How to Deal with the Patient's Emotions*. Logos Universality Mentality Education Novelty, Section: Social Sciences, VI(1), 109-116. Doi: <http://dx.doi.org/10.18662/lumenss.2017.0601.10>

Călin, R. A., & Teodorescu, B. (2016). The Tutoring Phenomenon-An Exploratory Study. *Creative Imagination in Social Sciences*, 127.

Freud S. (1933). *New Introductory lectures in psychoanalysis*. New York: Norton

Gordon, Th. (2014). *Părintele eficient*. București: Editura Trei.

Hines, G. (2016). *Ajută-ti copilul să devină independent*. Iași: Editura POLIROM.

Iorgulescu, G. (2017). *Elemente de științe comportamentale și neuroștiințe în medicina dentară*. București: Editura Medicală.

Laniado, N. (2008). *Când copilul plânge*. București: Editura ALL.

Mason, C., Porter, S.R., Madland, G. And Parry, J. 1997. *Early management of dental pain in children and adolescents*. Journal of Dentistry. Vol. (25. Issue 1, January 1997. Pages 31-34

Patroi, G. (2001). *Stomatologie preventivă*. Craiova: Editura Fundația Scrisului Românesc.

Popescu, A.M. *Prescriptive Models of Intervention Strategy Choice of Manager in the Resolution of Conflict Moods*. Procedia-Social and Behavioral Sciences, 180, 197-202, 2015.

Popescu, A. M., & Stefan, M. A. *Training the educator for methodological alternatives and paradigm changes in education*. Revista de Științe Politice, (43), 171-183, 2014

Porter, K. (2013). *Cartea asistentului de medicină dentară*. București: Editura ALL.

Tuculina, M. (2009). *Curs de odontoterapie conservatoare și restauratoare. Vol. II*. Craiova: Editura Medicală Universitară.

Statov, N. (2011). *Comunicarea medic-pacient în medicina dentară pediatrică*. Teză de doctorat. Cluj-Napoca: Universitatea de Medicină și Farmacie "Iuliu Hatieganu".

Srivastava, V. K. (2011). *Modern Pediatric Dentistry*. New Delhi: Jaypee Brothers Medical Publishers

Thomas, J. (2011). *Tulburările de atenție la copii*. Iași: Editura POLIROM.

Unguru, E., & Sandu, A. (2018). Normative and Institutional Frameworks for the Functioning of Supervision in Social Work. *Revista Romaneasca pentru Educatie Multidimensionala*, 10(2), 69-87. <https://doi.org/10.18662/rrem/47>

Vlăduțescu, Ș. (2018). Postmodern Convergence of Dao with the Apophatism. *Postmodern Openings/Deschideri Postmoderne*, 9(1).

Voinea, D. V., Negrea, X., & Teodorescu, B. (2016). Journalistic Language as a Part of Romanian Language. *Analele Universității din Craiova. Seria Științe Filologice. Lingvistică*,(1-2), 284-291.