

Clinical Case Seminar**A2(1-6)**

Thyroid dysfunction in patients treated with the immune checkpoint inhibitor nivolumab: different clinical features

Giuseppe Giuffrida¹, Alfredo Campenni², Francesco Trimarchi³, Rosaria M. Ruggeri¹

¹Unit of Endocrinology, Department of Clinical and Experimental Medicine, University of Messina, Italy; ²Unit of Nuclear Medicine, Department of Biomedical and Dental Sciences and Morphofunctional Imaging, University of Messina, Italy; ³Accademia Peloritana dei Pericolanti, Messina, Italy.

Abstract

Rationale. Immune Checkpoint Inhibitors (ICIs) are approved for some advanced neoplasms, increasing survival. ICIs block inhibitor receptors cytotoxic T lymphocyte antigen 4 (CTLA4) and programmed death-1 (PD-1) and trigger T cell-mediated immunity against tumor. Their action is accompanied by several immunity-related adverse events (IRAEs), also involving the endocrine system (pituitary, thyroid, adrenals). We report two different cases of thyrotoxicosis following administration of the anti-PD-1 nivolumab.

Patients. Patient 1, M, 75 years-old, treated for non-small cell lung carcinoma (NSCLC) since September 2016, with euthyroid multinodular goiter. In January 2017 (12 weeks from baseline), he developed frank hyperthyroidism, with positive TSH-receptor antibodies (TRAb) and thyroperoxidase antibodies (TPO-Ab). A Tc99m thyroid scintiscan showed diffuse uptake and “cold” areas. After nivolumab withdrawal, treatment with metimazole (MMI) 5 mg per day was started and euthyroidism was resumed, so to restart the drug in May 2017. Patient 2, M, 80 years-old, treated for a left-eye choroid melanoma since January 2017, with euthyroid nodular goiter. In April 2017 (6 weeks from baseline), thyrotoxicosis was detected, with positive thyroglobulin antibodies (Tg-Ab, 244 IU/ml, nv <4) and no scintiscan uptake, as in destructive thyroiditis. Scalar-dose prednisone was initiated, and after 3 months TSH was >4.5 μ IU/ml (subclinical hypothyroidism). Patient was treated with replacement doses of levothyroxine (LT-4), and continued nivolumab infusions.

Conclusions. Two forms of thyrotoxicosis were reported: the first with thyroid hyperfunction and positive TRAb, the latter as a destructive thyroiditis. In both cases (mean onset after 9 weeks), the moderate severity and the appropriate management of endocrine IRAEs allowed treatment continuation.

KEYWORDS: immune checkpoint inhibitors, autoimmunity, autoimmune thyroid diseases

Introducing Member: Rosaria Maddalena Ruggeri

Corresponding Author: Giuseppe Giuffrida, g.giuffrida87@gmail.com

Introduction

Cancer is characterized by an immune escape that favors its progression (1). Novel monoclonal autoantibodies (mAbs) known as ICIs boost the response against tumor antigens blocking T-cell inhibitory receptors, CTLA4 (ipilimumab, tremelimumab), PD-1 (nivolumab, pembrolizumab)

and its ligand PD-1L (atezolizumab, durvalumab). These receptors act as negative coregulators to limit further T-cell activation and to prevent autoimmunity (2), with distinct roles: CTLA4 modulates the early MHC-mediated antigen presentation phase, while the PD-1/PD1L pathway limits the following immune-inflammatory response to protect normal tissues (3). ICIs have been approved for selected advanced stage neoplasms (malignant melanoma, renal cell carcinoma, NSLC), with improved survival (4, 5) and a response rate ranging from 10-15% with ipilimumab (6) to 32% with nivolumab (7). Conversely, their action is accompanied by several IRAEs, the most common involving skin, gastrointestinal and endocrine system (8). Endocrine IRAEs mainly include hypophysitis, thyroid dysfunction and, rarely, adrenal insufficiency and type 1 diabetes mellitus (T1DM, 3). The US National Cancer Institute has provided a grading scale, according to the Common Terminology Criteria for Adverse Events (CTCAE, 9), ranging from moderate (*grade 1-2*) to severe (*3-4*) up to death (*5*) (**Table 1**). These criteria can inform the management of specific IRAEs, considering anticancer treatment withdrawal and/or corticosteroid administration. Herein we report two cases of thyrotoxicosis after nivolumab infusions (3 mg/kg every 2 weeks).

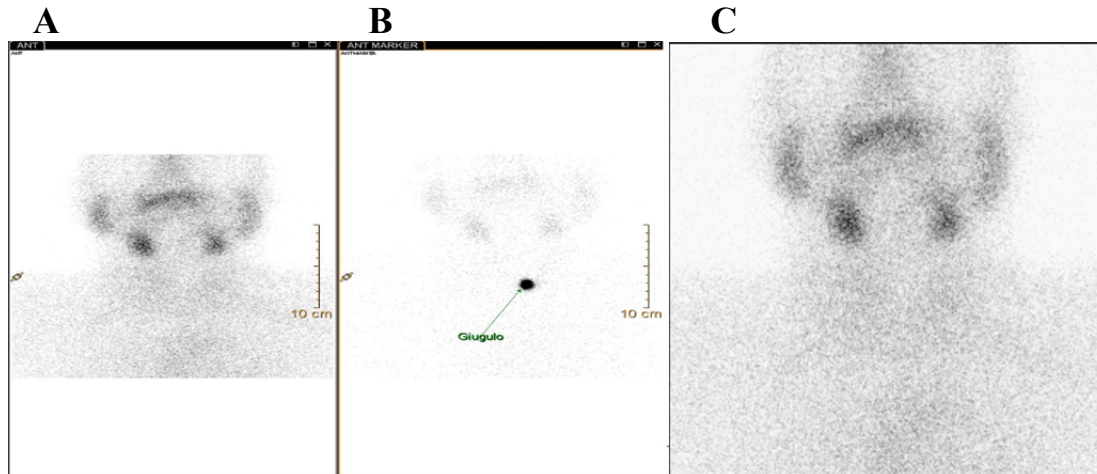
Case Report

Patient 1. M, 75 years-old, suffering from NSCLC diagnosed in September 2016, with multinodular euthyroid goiter never treated with L-T4. Baseline hormonal profile showed FT3 3.19 pg/ml (nv 1.71-3.71), FT4 1.06 ng/dl (nv 0.7-1.48) and TSH 0.7 μ IU/ml (nv 0.3-4.2). In January 2017, 12 weeks after nivolumab infusions started, the patient became overtly hyperthyroid (FT3 3.81 pg/ml, FT4 1.68 ng/dl, TSH 0.04 μ UI/ml) with slight positivity of TRAb (1.6 IU/L, positive >1.5) and TPO-Ab (52 IU/L, nv 0-9). He underwent a ^{99m}Tc thyroid scintiscan, that revealed increased uptake and “cold” areas, corresponding to the known nodules. Considered the persistent hyperthyroidism and related symptoms (anxiousness, tremor, mean HR 88 bpm - Grade 2-3), nivolumab withdrawal was followed by administration of MMI 5 mg per day and low-dose propranolol (20 mg per day). A quick resolution of symptoms was observed, and being a stable euthyroidism confirmed in May 2017 (TSH 1.61 μ IU/ml), the infusions continued.

Patient 2. M, 80 years-old, treated with nivolumab for a left-eye choroid melanoma from the beginning of 2017, with nodular euthyroid goiter. His baseline hormonal profile was FT3 3.44 pg/ml, FT4 1.02 ng/dl, TSH 0.831 μ IU/ml. In April 2017, 6 weeks after the first infusion, biochemical parameters revealed FT3 10.78 pg/ml, FT4 6.64 ng/dl, TSH 0.06 μ IU/ml, negative TRAb and TPO-

Ab, Tg-Ab 244 IU/ml (nv <4). The patient reported nervousness and sporadic palpitations (Grade 2). Also, he developed high fever (40°C), in the absence of hypotension and/or respiratory failure and/or evidence of coagulopathy (that is, not related to cytokine release syndrome). Thyroid scintiscan with ^{99m}Tc showed no uptake, as in destructive thyroiditis (Fig. 1).

Fig 1. In patient 2, images obtained from thyroid scintiscan showed absent thyroid uptake (A and B), as in subacute thyroiditis. A detail is shown in C.



Corticosteroid therapy was started (prednisone 50 mg per os, adequately tapered in about 6 weeks), with rapid resolution of symptoms. After 4 weeks, mild subclinical hypothyroidism was detected (TSH 4.512 μ IU/ml) and confirmed by a second determination. Consequently, the patient underwent replacement therapy with LT-4, and nivolumab infusions were continued as scheduled.

Discussion

The inhibition of immunity suppression mechanisms by ICIs leads to IRAEs, ranging from 15% to 90%, with a risk of severe effects from 7 to 25% when ipilimumab dose was increased from 3 to 10 mg/kg (10); on the contrary, some experiences with anti-PD1 reported a frequency of grade 3-4 IRAEs <2% (11), with a comparable incidence of IRAEs both at 2 and 10 mg/kg for pembrolizumab (12). So, it is conceivable that anti-PD-1 toxicity is not dose-dependent (or it only follows shorter intervals of administration), and it is globally lower than anti-CTLA4. Endocrine dysfunctions usually present 9 weeks after the first dose (range 5-36 weeks, 13). Anti PD-1 are more commonly associated with thyroid dysfunction, that ranges from grade 1-2 hypothyroidism (4%) and hyperthyroidism (2-3%), to acute thyroiditis (1%). Hypophysitis accounts for 0.2-1% of cases, type 1 diabetes mellitus for 0.1% (13, 14). Signs and symptoms are often aspecific with headache, tiredness, changes in mood etc., but dehydration, hypotension or shock symptoms should lead to suspect an adrenal crisis, a life-threatening condition requiring prompt

administration of corticosteroids. Thyroid disorders mainly appear as Hashimoto's thyroiditis, with subclinical or overt hypothyroidism. Presence or increase of organ-specific autoantibodies Tg-Ab and TPO-Ab have been reported during treatment. Hypothyroidism has a higher incidence than under anti-CTLA4 (4-10% vs 2-4% with Ipilimumab at 3 mg/kg), and is rarely severe (15). It is usually managed with LT-4 replacement doses (1-1.5 μ g/kg), without the need of interrupting ICIs.

Thyrotoxicosis is less common, and it may be caused by Graves' disease (GD) related to TRAb, even if transient destructive thyroiditis has been reported especially with nivolumab (16). Therapeutic approach depends on the cause: GD requires thyreostatic treatment with MMI plus β -blockers to control heart rate and tremor, subacute thyroiditis can be managed with symptomatic β -blockade and prednisone. In both situations anticancer treatment can usually be continued, even when thyroid dysfunction is particularly severe (grade 3-4, or in prolonged grade 2 effects), but administration of IV corticosteroids (mainly methylprednisolone) should be considered (11). In our patients, thyrotoxicosis had a mean onset of 9 weeks, and patient 2, who suffered from subacute thyroiditis with good response to oral corticosteroids, became hypothyroid 4 weeks within the initiation of symptoms. This is in contrast with a recent case series by Yamauchi et al. (17), in which 5 patients were diagnosed with nivolumab-related painless thyroiditis, and those who interrupt anticancer therapy or were treated with IV methylprednisolone seemed "protected" from the subsequent hypothyroidism. More data should be collected to verify this finding. Besides, since our patients frequently underwent CT studies with contrast medium in the months before, the possibility of iodine-induced thyrotoxicosis (the so-called jod-Basedow effect) had been excluded by periodical hormonal investigations and thyroid scintigraphy, when indicated. In conclusion, an adequate monitoring of hormonal profile and routine parameters, like glycemia and electrolytes, is fundamental before starting anticancer treatment, during the infusions and even beyond, since some adverse events can occur late. In our cases, the punctual follow-up of patients has allowed clinicians to correctly manage endocrine IRAEs, leading to the completion of the scheduled treatments, even with a temporary withdrawal. These concepts highlight the importance of team-work between endocrinologists, oncologists and other specialists, to early detect, if possible, the occurrence of IRAEs and to reduce their impact on patients' health during anticancer therapy.

Table 1. General classification of drug-related endocrine adverse events and, accordingly, symptoms grading as expressed by NCI in Common Terminology Criteria for Adverse Events (CTCAE), comprehending those applicable to ICIs treatment (see reference 9).

Endocrine disorders					
Adverse Event	Grade				
	1	2	3	4	5
Adrenal insufficiency	Asymptomatic; clinical or diagnostic observations only; intervention not indicated	Moderate symptoms; medical intervention indicated	Severe symptoms; hospitalization indicated	Life-threatening consequences; urgent intervention indicated	Death
Definition: A disorder that occurs when the adrenal cortex does not produce enough of the hormone cortisol and in some cases, the hormone aldosterone. It may be due to a disorder of the adrenal cortex as in Addison's disease or primary adrenal insufficiency.					
Cushingoid	Mild symptoms; intervention not indicated	Moderate symptoms; medical intervention indicated	Severe symptoms, medical intervention or hospitalization indicated	-	-
Definition: A disorder characterized by signs and symptoms that resemble Cushing's disease or syndrome: buffalo hump obesity, striae, adiposity, hypertension, diabetes, and osteoporosis, usually due to exogenous corticosteroids.					
Delayed puberty	-	No breast development by age 13 yrs for females; testes volume of <3 cc or no Tanner Stage 2 development by age 14.5 yrs for males	No breast development by age 14 yrs for females; no increase in testes volume or no Tanner Stage 2 by age 16 yrs for males; hormone replacement indicated	-	-
Definition: A disorder characterized by unusually late sexual maturity.					
Growth accelerated	-	>= +2 SD (standard deviation) above mid parental height or target height	-	-	-
Definition: A disorder characterized by greater growth than expected for age.					
Hyperparathyroidism	Mild symptoms; intervention not indicated	Moderate symptoms; medical intervention indicated	-	-	-
Definition: A disorder characterized by an increase in production of parathyroid hormone by the parathyroid glands. This results in hypercalcemia (abnormally high levels of calcium in the blood).					
Hyperthyroidism	Asymptomatic; clinical or diagnostic observations only; intervention not indicated	Symptomatic; thyroid suppression therapy indicated; limiting instrumental ADL	Severe symptoms; limiting self care ADL; hospitalization indicated	Life-threatening consequences; urgent intervention indicated	Death
Definition: A disorder characterized by excessive levels of thyroid hormone in the body. Common causes include an overactive thyroid gland or thyroid hormone overdose.					
Hypoparathyroidism	Asymptomatic; clinical or diagnostic observations only; intervention not indicated	Moderate symptoms; medical intervention indicated	Severe symptoms; medical intervention or hospitalization indicated	Life-threatening consequences; urgent intervention indicated	Death
Definition: A disorder characterized by a decrease in production of parathyroid hormone by the parathyroid glands.					
Hypothyroidism	Asymptomatic; clinical or diagnostic observations only; intervention not indicated	Symptomatic; thyroid replacement indicated; limiting instrumental ADL	Severe symptoms; limiting self care ADL; hospitalization indicated	Life-threatening consequences; urgent intervention indicated	Death
Definition: A disorder characterized by a decrease in production of thyroid hormone by the thyroid gland.					
Precocious puberty	Physical signs of puberty with no biochemical markers for females <8 years and males <9 years	Physical signs and biochemical markers of puberty for females <8 years and males <9 years	-	-	-
Definition: A disorder characterized by unusually early development of secondary sexual features; the onset of sexual maturation begins usually before age 8 for girls and before age 9 for boys.					
Virilization	Mild symptoms; intervention not indicated	Moderate symptoms; medical intervention indicated	-	-	-
Definition: A disorder characterized by inappropriate masculinization occurring in a female or prepubertal male.					
Endocrine disorders - Other, specify	Asymptomatic or mild symptoms; clinical or diagnostic observations only; intervention not indicated	Moderate; minimal, local or noninvasive intervention indicated; limiting age-appropriate instrumental ADL	Severe or medically significant but not immediately life-threatening; hospitalization or prolongation of existing hospitalization indicated; disabling; limiting self care ADL	Life-threatening consequences; urgent intervention indicated	Death

*of note, there are no reports about cases of virilization/precocious puberty with ICIs, neither about their use in paediatric populations

Conflicts of Interest: There is no potential conflict of interest, and the authors have nothing to disclose. This work was not supported by any grant.

References

1. Kim, R., Emi, M., Tanabe, K. (2007) Cancer immunoediting from immune surveillance to immune escape. *Immunology*, 121:1-14.
2. Wang, X. B., Zheng, C. Y., Giscombe, R. et al. (2001) Regulation of surface and intracellular expression of CTLA4 on human peripheral T-cells. *Scandinavian J Immunol*, 54:453-458.
3. Torino F., Corsello S.M., Salvatori R. (2016) Endocrinological side-effects of immune checkpoint inhibitors. *Curr Opin Oncol*, 28:278-287.
4. Hodi, F.S., O'Day S.J., McDermott, D.F. et al. (2010) Improved survival with ipilimumab in patients with metastatic melanoma. *N Engl J Med*, 363:711-723.
5. Brahmer, J.R., Tykodi, S.S., Chow, L.Q. et al. (2012) Safety and activity of anti-PD-L1 antibody in patients with advanced cancer. *N Engl J Med*, 366:2455-2465.
6. Robert, C., Thomas, L., Bondarenko, I. et al. (2011) Ipilimumab plus dacarbazine for previously untreated metastatic melanoma. *N Engl J Med*, 364:2517-26.
7. Weber, J.S., D'Angelo, S.P., Minor, D. et al. (2015) Nivolumab versus chemotherapy in patients with advanced melanoma who progressed after anti-CTLA-4 treatment (Check-Mate 037): a randomised, controlled, open-label, phase 3 trial. *Lancet Oncol*, 16:375-84.
8. Hofmann, L., Forschner, A., Loquai, C. et al. (2016) Cutaneous, gastrointestinal, hepatic, endocrine, and renal side-effects of anti-PD-1 therapy. *Eur J Cancer*, 60:190-209.
9. U.S. Department Of Health And Human Services NIOH, National Cancer Institute. (2009) Common Terminology Criteria for Adverse Events v4.0 (CTCAE) [updated (v4.03: June 14, 2010) May 28, 2009].
10. Horvat, T. Z., Adel, N. G., Dang, T. O. et al. (2015) Immune-related adverse events, need for systemic immunosuppression, and effects on survival and time to treatment failure in patients with melanoma treated with ipilimumab at memorial sloan kettering cancer center. *J Clin Oncol*, 33:3193-3198.
11. Eigentler, T.K., Hassel, J.C., Berking, C. et al. (2016) Diagnosis, monitoring and management of immune-related adverse drug reactions of anti-PD1 antibody therapy. *Cancer Treatment Rev*, 45:7-18.
12. Herbst R.S., Baas P., Kim D. Et al. (2016) Pembrolizumab versus docetaxel for previously treated, PD-L1-positive, advanced non-small-cell lung cancer (KEYNOTE-010): a randomised controlled trial. *Lancet*, 387:1540–1550.
13. Joshi, M.N., Whitelaw, B.C., Palomar, M.T.P. et al. (2016) Immune checkpoint inhibitor-related hypophysitis and endocrine dysfunction. *Clin Endocrinol*, 85:331-339.
14. EMA, European Public Assessment Report Nivolumab-BMS (EMA/CHMP/392114/2015).
15. Robert, C., Schachter, J., Long, G.V. et al. (2015) Pembrolizumab versus ipilimumab in advanced melanoma. *N Engl J Med*, 372:2521-32.
16. Tanaka, R., Fujisawa, Y., Maruyama, H. et al. (2016) Nivolumab-induced thyroid dysfunction. *Jpn J Clin Oncol* 46:575–579.
17. Yamauchi, I., Sakane, Y., Fukuda, Y. et al. (2017) Clinical features of nivolumab-induced thyroiditis: a case series study. *Thyroid*, 27:894-901.



©2017 by the Author(s); licensee Accademia Peloritana dei Pericolanti (Messina, Italy). This article is an open access article distributed under the terms and conditions of the Creative Commons Attribution 4.0 International License (<https://creativecommons.org/licenses/by/4.0/>).

Communicated and received November 15, 2017, revised December 4, 2017, published on line December 20, 2017