



# Occipital neuralgia in lung carcinoma: a rare clinical scenario case report

Sovan Sarang Dhar<sup>1</sup>, Rajendra Sahoo<sup>2</sup>, Zulfuqur Hossain Khan<sup>3</sup>, Saroj Kumar Das Majumdar<sup>1</sup>, Dillip Kumar Parida<sup>1</sup>

## SUMMARY

Arch Oncol 2018; 24(1):10-11

Published Online

July 2, 2018

<https://doi.org/10.2298/AO0180330002D>

<sup>1</sup>All India Institute of Medical Sciences, Department of Radiotherapy, Bhubaneswar, India

<sup>2</sup>Health World Hospitals, Anaesthesiology and Pain Management Department, Durgapur, India

<sup>3</sup>North Delhi Municipal Corporation Medical College and Hindu Rao Hospital, Department of Physiology, New Delhi, India

Correspondence to:

Dr. Sovan Sarang Dhar

[sovan.sarangdhar@gmail.com](mailto:sovan.sarangdhar@gmail.com)

Received 2018-03-30

Accepted 2018-05-25

*Occipital neuralgia is an uncommon cause of pain over occipital region. When occipital nerves are affected due to osteogenic / vasculogenic / neurogenic causes it is manifested as a sharp shooting or stabbing type of pain over the occipital region of scalp, often progressing to involve the vertex and the temporal region as well. Use and withdrawal of variety of drugs result in headache. The role of any chemotherapeutic drug, as a causative agent for occipital neuralgia, has not been described in literature so far. We are reporting a rare case of occipital neuralgia precipitated while on combination chemotherapy regimen in lung carcinoma.*

**Key words:** Pain; Neuralgia

## INTRODUCTION

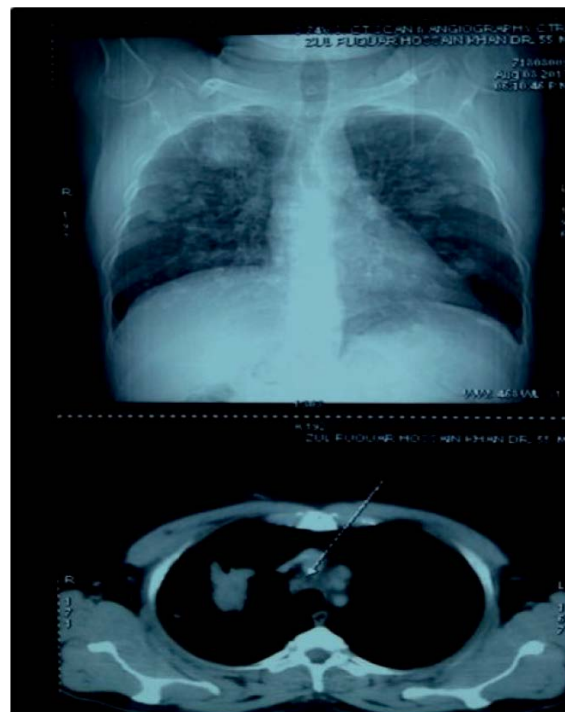
Occipital Neuralgia (ON) is characterised by sharp shooting pain arising in the sensory distribution of occipital nerves. Owing to be an uncommon diagnosis and at the same time due to overlap in criteria with more common neuralgias, its incidence and prevalence is rarely reported (1). A study in the Dutch general population reported a relatively low incidence of 3.2 per 100.000 (2).

Reported etiology for precipitation of ON can be divided in to vascular, neurogenic, muscular, and osteogenic causes. The pathophysiology of occipital neuralgia is yet to be specified. The prevalent hypothesis is that it results from injury to the C2-C3 nerve roots and/or occipital nerves through various mechanisms such as vertebral instability, trauma, inflammation, entrapment etc.

The onset of pain in occipital neuralgia is usually acute. It is described in various ways - stabbing / shooting / electric shock like that starts in the nuchal region and spreads towards vertex. The episode may start spontaneously or precipitate by factors such as movement, combing of hair, exposure to cold etc. On palpation, the occipital nerve trunks may reveal local tenderness. Percussion over occipital nerve often reproduces the distribution of pain (Tinel's Sign)(1). Diagnosis of ON is achieved with the help of above mentioned clinical manifestations. Cervicogenic headache, Trigeminal neuralgia and referred occipital pain may mimic clinical features of ON and need to be ruled out.

## CASE REPORT

Fifty four year old patient without known addictions, co-morbidities and without any relevant family history was diagnosed with lung adenocarcinoma and brain metastasis (cT2N3M1b, Figs. 1 and 2). He received whole brain radiotherapy (20 Gy / 5 fractions) followed by combination chemotherapy with Pemetrexed (500 mg/m<sup>2</sup>) + Carboplatin (AUC x 5) with palliative intent. After completing three cycles of chemotherapy he experienced an acute onset of sharp shooting pain over occipital region bilaterally, accompanied by tenderness and positive Tinel's sign which progressively involved vertex of scalp and responded minimally to nonsteroidal anti-inflammatory drugs (NSAIDs). No previous history of chronic headache of any form/ trauma/muscle spasm could be elicited. The greater and lesser occipital nerves were blocked with 2 ml of 0.5% Bupivacaine and 20 mg Methylprednisolone acetate each under real-time sonographic visualisation. Pain responded completely to nerve blockade and didn't recur. After ruling out migraine, trigeminal neuralgia, cervicogenic headache and referred occipital pain, the presenting clinical feature and response to cervical nerve



**Figure 1.** Contrast enhanced computed tomography of thorax showing multiple metastases in ipsilateral, contralateral lung and right Paratracheal node

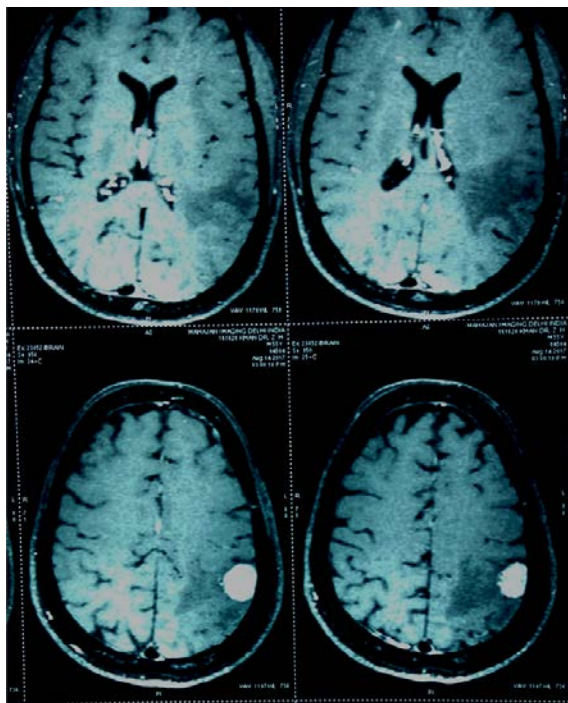
root blockade lead us to the diagnosis of occipital neuralgia. Presently, the patient has completed the scheduled number of chemotherapy, is asymptomatic and under immunotherapy.

## DISCUSSION

The International Headache Society (IHS) has described occipital neuralgia as an "Unilateral or bilateral paroxysmal, shooting or stabbing pain in the posterior part of the scalp, in the distribution of the greater, lesser or third occipital nerves, sometimes accompanied by diminished sensation or dysesthesia in the affected area and commonly associated with tenderness over the involved nerve(s)" (3). Apart from vascular, neurogenic, muscular, and osteogenic reasons it also has been known to be precipitated due to Herpes Simplex Virus infection of cervical dorsal root ganglion (4), hair transplantation (5), Schwannoma of greater occipital nerve (6) and Atlanto-axial Chordoma (7).



This work is licensed under a Creative Commons Attribution 4.0 license



**Figure 2.** T1 weighted contrast enhanced magnetic resonance imaging of the axial brain section showing contrast enhancing space occupying lesion in left parietal lobe with significant oedema suggestive of metastatic deposit

Following the IHS guidelines for diagnosis, in the presented report the clinical scenario and patient history ruled out the differential diagnoses like migraine, cluster headache and trigeminal neuralgia. After arriving at the diagnosis of occipital neuralgia, the cause behind it was searched for. Trauma and stiffness of neck muscles were not found from patient history and physical examination. After ruling out diabetes mellitus and gout using biochemistry tests osteoarthritis, spinal cord tumour / metastases were also ruled out using clinical assessment and imaging. Since the metastatic deposit visualised in brain MRI was intracranial, the radiotherapy dose employed in above scenario was unlikely to affect occipital nerves. No such report could be found even after extensive literature search or in institutional experience. Except for high dose per fraction, none of the other known risk factors (low energy beam, large proportion of nerve in treatment area, high total dose, heterogeneous high dose region, field junction over nerve, concomitant or previous neurotoxic chemotherapy, young or advanced age, obesity, hypertension, diabetes mellitus, dyslipidaemia or pre-existing collagen vascular disease) were present. Also, the onset of ON from the completion of radiotherapy was nearly 2.5 months, whereas reported latency period of radiation induced neuropathy has been measured in years. Considering these facts radiotherapy as a causative factor was unlikely (8).

Tumour and radiotherapy aetiologies were excluded. After a detailed discussion in a multispecialty clinic, none of the rare causes published in literature could be identified as precipitating cause in this case (9). Following exclusion of common as well as rare but reported causes, drug induced occipital nerve neuropathy was considered as probable aetiology. Even though carboplatin is neurotoxic, the reported frequency of peripheral neuropathy stands at 4-6% (10). Combination chemotherapy with other neurotoxic agents and in elderly patients (>65 years) may increase neurotoxicity. In the National Cancer Institute of Canada study, amongst ovarian cancer patients receiving carboplatin and cyclophosphamide the incidence of sensory side effects was 6%, while central nervous system neurotoxicity was 28% (11). Unlike platinum

compounds, pemetrexed induced neuropathy has only been reported in or following combination with platinum compounds. Hence, in view of the facts and clinical scenario above carboplatin induced occipital neuralgia hypothesis has been put forward. The mechanism underlying platinum induced neuropathy is due to accumulation of DNA-platinum adducts in dorsal-root-ganglions and peripheral neurons. These cells (being post-mitotic and non-dividing) do not die, instead manifest toxicity in the form of neuropathy. After meticulous search in PubMed and EMBASE databases no report/article about carboplatin causing occipital neuralgia could be found. This could be the first reported case of carboplatin induced occipital neuralgia.

## CONCLUSION

Carboplatin induced neuropathy is not uncommon in combination chemotherapy. In the above described report after ruling out known benign causes and after analysing tumour as well as treatment related factors a hypothesis of carboplatin induced occipital neuralgia is put forward which adequately responded to occipital nerve block.

## Declaration of Interests

Authors declare no conflicts of interest.

## REFERENCES

- Garza I, Swanson JW, Dashe JF. Occipital neuralgia. UpToDate. 2018. website. <https://www.uptodate.com/contents/occipital-neuralgia> published 2017. Last updated August 25, 2017. Accessed January 1, 2018.
- Koopman JSHA, Dieleman JP, Huygen FJ, de Mos M, Martin CGM, Sturkenboom MCJM. Incidence of facial pain in the general population. *Pain* 2009;147(1):122-127. doi: 10.1016/j.pain.2009.08.023
- Headache Classification Committee of the International Headache Society (IHS). The International Classification of Headache Disorders, 3rd edition (beta version). *Cephalalgia* 2013;33(9):629-808. doi: 10.1177/0333102413485658
- Valyi-Nagy T, Rathore J, Rakic A, Rathore R, Jain P, Slavin K. Herpes Simplex Virus Type 1 Human Cervical Dorsal Root Ganglionitis. *Case Reports in Neurology* 2017;9(2):188-194. doi: 10.1159/000479146
- Siefferman J, Khelemsky Y. Occipital Neuralgia after Hair Transplantation and Its Treatment. *Case Reports in Neurological Medicine* 2015;1-3. doi: 10.1155/2015/428413
- Krishnan P, Kartikueyan R, Chowdhury S, Das S. Schwannoma of the greater occipital nerve: An uncommon cause of occipital neuralgia. *Journal of Neurosciences in Rural Practice* 2015;6(4):634. doi: 10.4103/0976-3147.165434
- Kim WS, Park JT, Lee YB, Park WY. Atlantoaxial Chordoma in Two Patients with Occipital Neuralgia and Cervicalgia. *Journal of Lifestyle Medicine* 2014;4(2):104-108. doi: 10.15280/jlm.2014.4.2.104
- Sylvie Delanian, Jean-Louis Lefaix, Pierre-François Pradat. Radiation-induced neuropathy in cancer survivors. *Radiotherapy and Oncology* 105 (2012) 273-282. <https://doi.org/10.1016/j.radonc.2012.10.012>
- Choi I, Jeon SR. Neuralgias of the Head: Occipital Neuralgia. *Journal of Korean Medical Science* 2016;31(4):479. doi: 10.3346/jkms.2016.31.4.479
- McWhinney SR, Goldberg RM, McLeod HL. Platinum neurotoxicity pharmacogenetics. *Molecular Cancer Therapeutics* 2009;8(1):10-16. doi: 10.1158/1535-7163.mct-08-0840
- Swenerton K, Jeffrey J, Stuart G, Roy M, Krepart G, Carmichael J, MacLean G. Cisplatin-cyclophosphamide versus carboplatin-cyclophosphamide in advanced ovarian cancer: a randomized phase III study of the National Cancer Institute of Canada Clinical Trials Group. *Journal of Clinical Oncology* 1992;10(5):718-726. doi: 10.1200/jco.1992.10.5.718