

# Feasibility and accuracy of a voxel-based neuronavigation system with 3D image rendering in preoperative planning and as a learning tool for young neurosurgeons, exemplified by the anatomical localization of the superior sagittal sinus

Guenther C. Feigl<sup>1,2\*</sup>, Firas Thaher<sup>3</sup>, Sören Danz<sup>4</sup>, Marcos Tatagiba<sup>2</sup>, Anne K. Hickmann<sup>3</sup>, Antje Fahrigr<sup>5</sup>, Tomaz Velnar<sup>6,7</sup>, Marcel Kullmann<sup>2</sup>

<sup>1</sup>Department of Neurosurgery, General Hospital Klinikum Bamberg, Bamberg, Germany, <sup>2</sup>Department of Neurosurgery, University of Tuebingen Medical Center, Tuebingen, Germany, <sup>3</sup>Department of Neurosurgery, Katharinenhospital, Klinikum Stuttgart, Stuttgart, Germany, <sup>4</sup>Department of Neuroradiology, University of Tuebingen Medical Center, Tuebingen, Germany, <sup>5</sup>Department of Radiotherapy and Radiooncology, General Hospital Klinikum Bamberg, Bamberg, Germany, <sup>6</sup>Department of Neurosurgery, University Medical Centre Ljubljana, Ljubljana, Slovenia, <sup>7</sup>Alma Mater Europaea – European Center Maribor (AMEU-ECM), Maribor, Slovenia

## ABSTRACT

It is essential for a neurosurgeon to know individual anatomy and the corresponding anatomical landmarks before starting a surgery. Continuous training, especially of young neurosurgeons, is crucial for understanding complex neuroanatomy. In this study, we used a neuronavigation system with 3D volumetric image rendering to determine the anatomical relationship between the sagittal suture and the superior sagittal sinus (SSS) in patients with intracranial lesions. Furthermore, we discussed the applicability of such system in preoperative planning, residency training, and research. The study included 30 adult patients (18 female/12 male) who underwent a cranial computed tomography (CT) scan combined with venous angiography, for preoperative planning. The position of the sagittal suture in relation to the SSS was assessed in 3D CT images using an image guidance system (IGS) with 3D volumetric image rendering. Measurements were performed along the course of the sagittal sinus at the bregma, lambda, and in the middle between these two points. The SSS deviated to the right side of the sagittal suture in 50% of cases at the bregma, and in 46.7% at the midpoint and lambda. The SSS was displaced to the left of the sagittal suture in 10% of cases at the bregma and lambda and in 13% at the midpoint. IGSs with 3D volumetric image rendering enable simultaneous visualization of bony surfaces, soft tissue and vascular structures and interactive modulation of tissue transparency. They can be used in preoperative planning and intraoperative guidance to validate external landmarks and to determine anatomical relationships. In addition, 3D IGSs can be utilized for training of surgical residents and for research in anatomy.

**KEY WORDS:** Neuronavigation system; 3D volumetric image rendering; resident training; preoperative planning; anatomical relationship; superior sagittal sinus; sagittal suture; voxel-based

DOI: <https://dx.doi.org/10.17305/bjbms.2019.3815>

*Bosn J Basic Med Sci. 2019;19(2):180-185. © 2019 ABMSFBIH*

## INTRODUCTION

Knowledge of patient's anatomy is essential in neurosurgical procedures. Neuronavigation systems are image-guided, computer-assisted systems that provide a three-dimensional (3D) view of patient-specific anatomy. These systems are

practical in preoperative planning and intraoperative navigation [1,2], especially in cases in which neurovascular structures are displaced by space-occupying lesions. Neuronavigation systems can also be used as an educational tool for training neurosurgical residents [2,3], to facilitate the complex and time-consuming process of learning neuroanatomy and surgical skills [2-4]. In addition, they can be used as a research tool in anatomical studies. The application of neuronavigation systems in training and research is especially important, as time, money and cadaver specimens are limited in such circumstances [3].

\*Corresponding author: Guenther C. Feigl, Department of Neurosurgery, General Hospital Klinikum Bamberg, Buger Straße 80, 96049 Bamberg, Germany. Phone: +49-951-503-12181; Fax: +49-951-503-12189. E-mail: [guenther.feigl@web.de](mailto:guenther.feigl@web.de)

The sagittal suture is regarded as an external landmark of the superior sagittal sinus (SSS) [1], although cadaveric studies show that the SSS is deviated to the right of the sagittal suture [5,6]. In this study, we used a neuronavigation system with 3D volumetric rendering of CT data to determine the spatial relationship between the sagittal suture and the SSS in patients with intracranial lesions. Furthermore, we discussed the applicability of such system in preoperative planning, training of neurosurgical residents, and in anatomical research.

## MATERIALS AND METHODS

### Patients

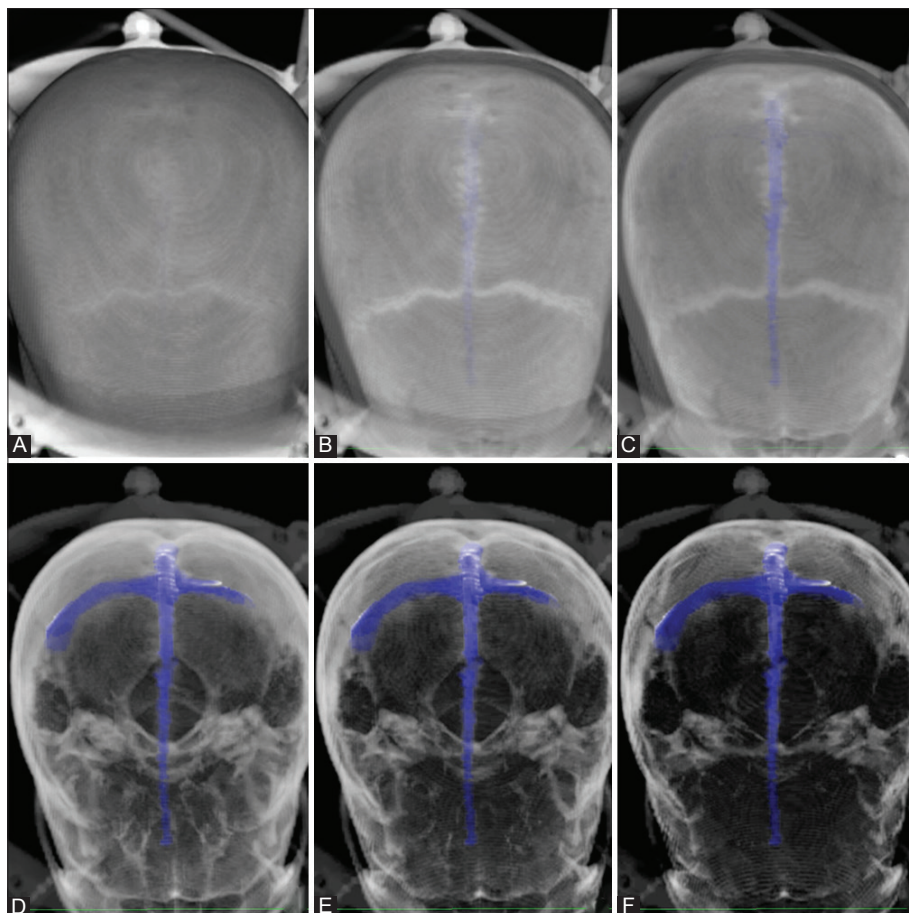
This retrospective study included 30 adult patients (18 female/12 male) who underwent a cranial computed tomography (CT) scan combined with venous angiography, for preoperative planning. The mean age of patients was 52.5 years (range: 17–86 years). We included only patients without a parasagittal lesion or mass effect causing a midline shift of the brain and excluded patients with a skull deformity, such as hyperostosis or abnormal SSS.

Each patient received a high-resolution CT scan combined with venous angiography, which was performed on a multislice Somatom Plus 4 CT scanner (Siemens, Erlangen,

Germany). The following examination protocol was applied: nonionic contrast medium (100 ml of 300 mg/ml solution) was injected with a pump into the cubital vein at a rate of 3.5 ml/s. After a delay of 28 to 37 seconds, 100 to 120 helical scans were acquired at 1 mm/s table-forward speed (1024 matrix, 120 kV, and 240 mA). The slice thickness was 1 mm. The axial images were transferred to the workstation of the neuronavigation system. Three-dimensional volume rendered images of the cranium and the underlying vasculature were acquired with a minimum density threshold of approximately 60 to 80 HU and a maximum density threshold of 300 to 400 HU.

### Neuronavigation

We used a voxel-based optical neuronavigation (CBYON™, Med Surgical Services Inc., Sunnyvale, California, USA) with 2D and 3D real-time perspective image rendering. The image-guided system (IGS) consists of a central processing unit (CPU), a tool interface unit connected to an infrared camera, a touchscreen monitor with a pen for manual segmentation, and the navigation software CBYON Suite 2.8. The system performs a volumetric reconstruction of 3D CT images and it can also combine segmented volumes from different imaging modalities, such as magnetic resonance imaging (MRI) and CT, into one 3D image. An additional feature of the system is



**FIGURE 1.** Opacity adjustment using a three-dimensional (3D) voxel-based image rendering system. We gradually increased the opacity in images A to F which allowed stepwise visualization of the superior sagittal sinus (SSS, colored blue) in relation to bony structures.

image-enhanced endoscopy [7]. Similar to conventional neuronavigation systems, this feature allows the surgeon to register the tip of an endoscope and track it on the triaxial images. Moreover, it displays the live endoscopic image simultaneously next to the virtual 3D voxel-based endoscopic image and from the same view as the endoscope camera [8]. Modulation of the tissue transparency in the virtual endoscopic image provides a virtual look into patient's head, which is useful for preoperative planning of surgical approach and intraoperative localization of neurovascular structures.

The CBYON neuronavigation system visualizes at the same time the bony landmarks and the underlying segmented venous structures, by gradually rendering the skull bone translucent. The manually segmented SSS, which was colored blue to achieve adequate contrast for visualization, thus became visible together with the sutures of the overlying skull bone (Figure 1). We assessed the position of the sagittal suture in relation to the SSS (Figure 1 and 2). Measurements were performed at three predefined points along the course of the SSS, i.e., at the bregma, lambda and in the middle between these two points (midpoint). In a coronal section, we marked the right and left borders of the SSS and the sagittal suture at the three points. To determine the deviation of the SSS from the sagittal suture at the three points, we measured the width of the SSS and the sagittal suture and calculated the delta

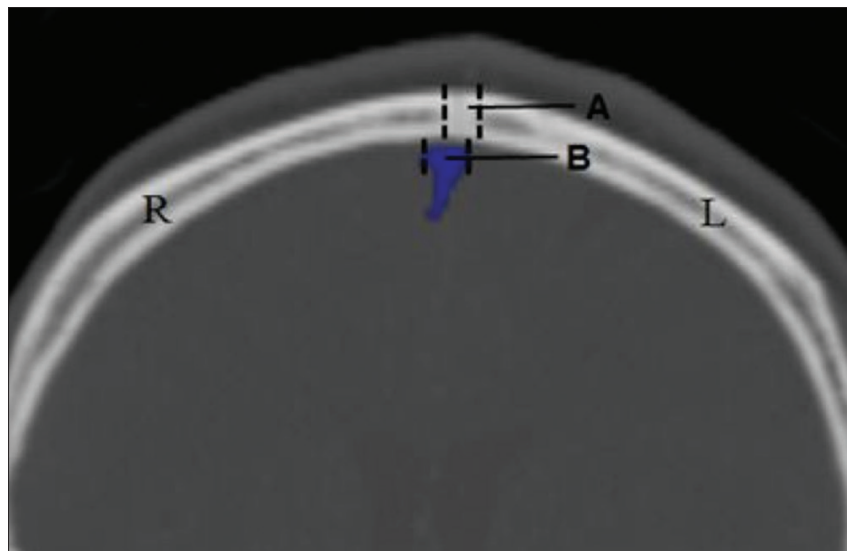
between the measurements (Figure 2). A single investigator (FT) performed all segmentations in the neuronavigation system and all measurements to avoid interobserver variability.

## RESULTS

All patients had a normal midline sagittal suture and a single SSS. The length of the sagittal suture ranged from 11 cm to 12.5 cm (mean 11.7 cm). The width ranged from 1 mm to 8.5 mm (mean 5.5 mm) at the bregma, from 4.5 mm to 10.8 mm (mean 7.8 mm) at the midpoint between the bregma and lambda, and from 3.1 mm to 12.4 mm (mean 7.1 mm) at the lambda. The width of the SSS was from 3.9 mm to 10.5 mm (mean 5.6 mm) at the bregma, 5 mm to 13 mm (mean 6.6) at the midpoint, and 5 mm to 12 mm (mean 7) at the lambda (Table 1).

The relationship between the sagittal suture and the SSS is summarized in Table 2.

At the bregma, in 12 cases (40%) the sinus was located within the margins of the sagittal suture. In 15 cases (50%), the SSS deviated between 1.4 mm and 6.7 mm (mean 4 mm) to the right of the right lateral margin of the sagittal suture. In three cases (10%), the SSS deviated between 2.2 mm and 3.2 mm (mean 2.4 mm) to the left of the margins of the sagittal suture.



**FIGURE 2.** Deviation of the superior sagittal sinus (SSS) to the right side of the sagittal suture. Measurements were performed at three predefined points along the course of the sagittal sinus, i.e., at the bregma, lambda and in the middle between these two landmarks (midpoint). In a coronal section, we marked the right and left borders of the SSS and the sagittal suture at the three points. To determine the deviation of the SSS from the sagittal suture at the three points, we measured the width of the SSS and sagittal suture and calculated the delta between the measurements. A = sagittal suture; B = SSS; R = right; L = left.

**TABLE 1.** Anatomical relationship between the sagittal suture and the superior sagittal sinus (SSS) at three predefined points

Location	Sagittal suture		SSS	
	Range of width (mm)	Mean width (mm)	Range of width (mm)	Mean width (mm)
Bregma	1–8.5	5.5	3.9–10.5	5.6
Midpoint	4.5–10.8	7.8	5–13	6.6
Lambda	3.1–12.4	7.1	5–12	7

**TABLE 2.** Deviation of the superior sagittal sinus (SSS) from the sagittal suture at three predefined points

Location	% of cases (n=cases; mean deviation in mm)		
	Right deviation	Left deviation	w/o deviation
Bregma	50 (n=15; 4)	10 (n=3; 2.4)	40 (n=12)
Midpoint	46.7 (n=14; 2.5)	13.3 (n=4; 2.5)	40 (n=12)
Lambda	46.7 (n=14; 3.5)	10 (n=3; 2.5)	43.3 (n=13)

At the midpoint, the SSS was located within the margins of the sagittal suture in 12 cases (40%). In 14 cases (46.7%), the SSS deviated between 1 mm and 5.5 mm (mean 2.5 mm) to the right of the midline. In four cases (13.3%), the deviation of the SSS was between 1.2 mm and 3.3 mm (mean 2.5 mm) to the left of the midline.

At the lambda, the SSS was under the sagittal suture in 13 cases (43.3%). In 14 cases (46.7%), the SSS deviated between 2 mm and 5.8 mm (mean 3.5 mm) to the right of the sutural margins and, in three cases (10%), it deviated between 2 mm and 3.5 mm (mean 2.5 mm) to the left.

No gender-specific differences were observed in the course of the SSS nor in the maximum deviation of the SSS from the sagittal suture.

## DISCUSSION

Knowledge of neuroanatomy and the corresponding anatomical landmarks is essential for neurosurgeons, even in the era of readily available 3D neuronavigational systems. Before starting the surgery, a neurosurgeon must know how to localize intracranial structures such as the SSS without the use of IGS [9], to decrease surgical morbidity [10,11]. Continuous training, especially of young neurosurgeons, is crucial for understanding complex neuroanatomy [2,3]. However, continuous practice is not possible with the conventional teaching methods that rely on 2D images and cadaveric dissections, due to the limited duration of training sessions and number of cadavers [2,12]. Similarly, the use of 2D images for preoperative planning has disadvantages [3,12], for example, it requires the neurosurgeon to mentally reconstruct the 3D relationship between neurovascular/anatomical structures.

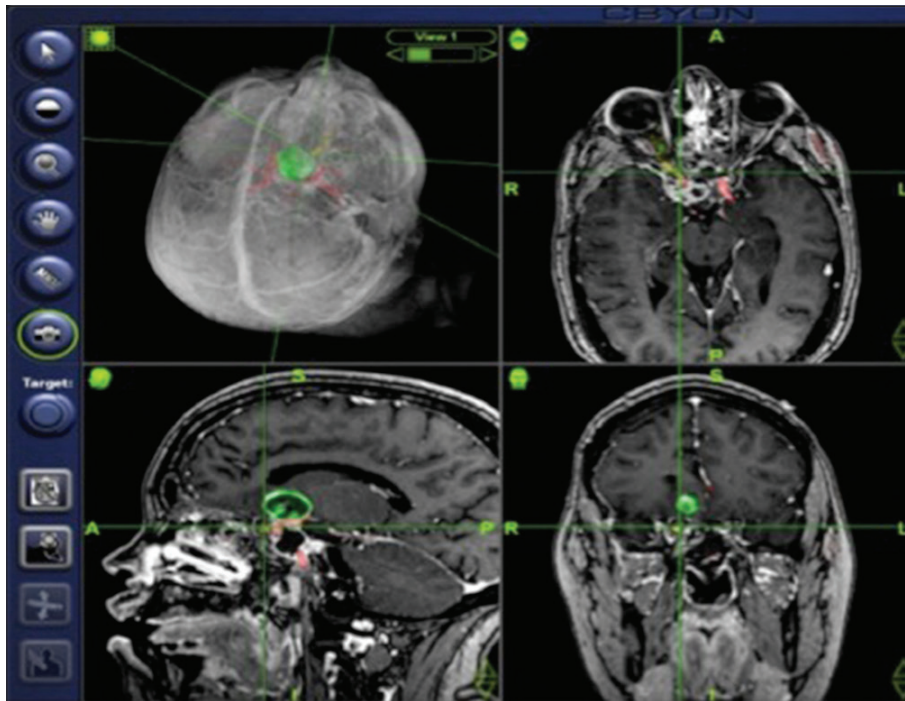
With the advent of new technologies, such as 3D voxel-based image analysis, more methods for teaching and learning neuroanatomy have become available [2,3,12]. In addition to residents in training, these tools are useful to experienced neurosurgeons [2], e.g., for preoperative planning and intraoperative guidance during complex surgery of the skull base [13,14].

Compared to 3D surface image rendering that produces only a hollow 3D model of an anatomical structure (e.g., in BrainLab AG neuronavigational system), voxel-based 3D image rendering creates a complete 3D model and allows stepwise visualization of 3D anatomy by opacity adjustments of displayed

structures (Figure 1) [3]. Gharabaghi et al. showed the usefulness of 3D volumetric image rendering in determining the precise anatomical relationship between the asterion and the underlying transverse-sigmoid sinus transition (TST) complex [15,16]. Namely, with the use of 3D volumetric rendering of CT venography [15] and of combined CCT and CT venous angiography [16] they could identify the spatial relationship between the two structures in more than 90% of examined cases. In the current study, we used the same IGS with 3D volumetric image rendering as in the studies of Gharabaghi et al. [15,16] to visualize the spatial relationship between the sagittal suture and the SSS. We found that the SSS was deviated to the right of the sagittal suture in 50% of cases at the bregma and in 46.7% of cases at the midpoint and lambda. Our findings are in agreement with the results from cadaveric studies [5,6], which showed displacement of the SSS to the right side in the majority of specimens, with the maximum deviation of 11 mm [5,6]. Together these results indicate that the 3D voxel-based neuronavigation with CT scans is comparable to cadaveric dissections in analyzing spatial relationships between anatomical structures.

The high accuracy of 3D neuronavigation systems in anatomical analysis makes them suitable as a learning tool for residents in training. Studies investigating the efficacy of simulators in simulating and planning surgical procedures in different specialties show that they decrease the learning curve, enhance the skills of surgical residents, and reduce intraoperative adverse events [2-4,12,17-19]. In contrast to traditional forms of surgical training, i.e. on patients, cadavers and using 2D images, 3D simulation allows visualization of the entire skull, including the internal structures, which can then be selectively highlighted using the image rendering feature and by manual segmentation or modulation of integrated filters. During surgery, the ability of a resident to learn about individual anatomy is limited by the size of surgical field. With the advent of minimally invasive techniques, such as endoscopic-assisted surgery with angulated endoscope, the surgical field has become even smaller in size, limiting the view of neurovascular structures and making it more difficult to understand the individual anatomy [3].

MRI and CT are the imaging modalities of choice for preoperative planning in patients with intracranial lesions [11,20,21], where both methods have some advantages and disadvantages [21]. For instance, structures such as the SSS can be easily recognized with both techniques when a contrast agent is used, however, bony surface structures that are often used as intraoperative landmarks can be visualized adequately only with CT [21]. In addition, neither MRI nor CT allows simultaneous visualization of bones, vessels and soft tissue structures, since separate windowing is required on the screens. Digital subtraction angiography (DSA), on the other hand, allows visualization of the skull bones and intracranial



**FIGURE 3.** Intraoperative 4-window view obtained with the CBYON navigation system. The system allows real-time opacity adjustment as deeper layers are exposed during surgery. Green = tumor; red = the carotid artery; yellow = the optic nerve.

arteries and veins in the same window [22]. Thus, although DSA is an invasive imaging technique and increases the risk of complications in patients, it is still the gold standard for visualization of intracranial vasculature [20,23]. However, it is not reasonable and it is ethically questionable to perform DSA in every patient undergoing a neurosurgical procedure, just to visualize venous or arterial structures, especially if they are not directly involved in the lesion.

If an IGS with 3D volumetric image rendering is available, the surgeon can use a noninvasive high-resolution CT scan in combination with venous or arterial angiography to overcome the problem of nonsimultaneous visualization of different anatomical structures. The advantages of CT over DSA are less side effects in patients due to a lower dose of radiation and reduced amount of contrast medium, shorter time of image acquisition, as well as its higher availability and cost efficiency [21,23]. Furthermore, the 3D images obtained preoperatively can be used for intraoperative guidance [3], with the advantage of real-time opacity adjustment as deeper layers are exposed during surgery (Figure 3). Image-enhanced endoscopy is another example of IGS which simultaneously displays registered real and virtual endoscopic images. The simultaneous display of endoscopic images and the option to adjust tissue transparency in the virtual images allow the surgeon to see beyond visible surfaces during endoscope-assisted surgery [7]. In addition, this method may be combined with conventional imaging such as MRI, as well as with functional imaging techniques [3].

Another application of voxel-based IGSs is in anatomical research. The results of the current and previous studies [14,16]

show that the voxel-based IGS is comparable to intraoperative methods in determining spatial relationships between anatomical structures. Abbasi et al. showed a high accuracy of two neuronavigation systems that are used in surgery, Radionics and BrainLab, by performing *in vitro* measurements on a phantom skull [24]. Compared to cadaveric studies, a larger number of cases can be studied in a shorter time with the use of neuronavigation systems, which makes anatomical studies less time consuming and more cost efficient.

## CONCLUSION

In preoperative planning, 3D volumetric image rendering can be used to validate external landmarks and to determine spatial relationships between bony surfaces, soft tissue and vascular structures by simultaneous visualization of these structures and interactive modulation of tissue transparency. The 3D images obtained preoperatively can then be used for intraoperative guidance, allowing real-time opacity adjustment during surgery. Finally, by providing accurate presentation of complex 3D relationships between neuroanatomical structures, 3D neuronavigation systems represent a valuable learning tool for both residents in training and experienced neurosurgeons, and a useful research tool in anatomical studies.

## DECLARATION OF INTERESTS

The authors declare no conflict of interests.

## REFERENCES

- [1] Tubbs RS, Salter G, Oakes WJ. Superficial surgical landmarks for the transverse sinus and torcular herophili. *J Neurosurg* 2000;93(2):279-81. <https://doi.org/10.3171/jns.2000.93.2.0279>.
- [2] Chan S, Conti F, Salisbury K, Blevins NH. Virtual reality simulation in neurosurgery: Technologies and evolution. *Neurosurgery* 2013;72(Suppl 1):154-64. <https://doi.org/10.1227/NEU.0b013e3182750d26>.
- [3] Elder JB, Hoh DJ, Oh BC, Heller AC, Liu CY, Apuzzo ML. The future of cerebral surgery: A kaleidoscope of opportunities. *Neurosurgery* 2008;62(6 Suppl 3):1555-82. <https://doi.org/10.1227/01.neu.0000333820.33143.od>.
- [4] Gelinas-Phaneuf N, Del Maestro RF. Surgical expertise in neurosurgery: Integrating theory into practice. *Neurosurgery* 2013;73(Suppl 1):30-8. <https://doi.org/10.1227/NEU.0000000000000115>.
- [5] Tubbs RS, Salter G, Elton S, Grabb PA, Oakes WJ. Sagittal suture as an external landmark for the superior sagittal sinus. *J Neurosurg* 2001;94(6):985-7. <https://doi.org/10.3171/jns.2001.94.6.0985>.
- [6] Samadian M, Nazparvar B, Haddadian K, Rezaei O, Khormaei F. The anatomical relation between the superior sagittal sinus and the sagittal suture with surgical considerations. *Clin Neurol Neurosurg* 2011;113(2):89-91. <https://doi.org/10.1016/j.clineuro.2010.09.006>.
- [7] Shahidi R, Bax MR, Maurer Jr CR, Johnson JA, Wilkinson EP, Wang B, et al. Implementation, calibration and accuracy testing of an image-enhanced endoscopy system. *IEEE Trans Med Imaging* 2002;21(12):1524-35. <https://doi.org/10.1109/TMI.2002.806597>.
- [8] Bax MR, Khadem R, Johnson JA, Wilkinson EP, Shahidi R. Calibration and accuracy testing for image-enhanced endoscopy. *Stud Health Technol Inform* 2002;85:52-6.
- [9] Tubbs RS, Loukas M, Shoja MM, Bellew MP, Cohen-Gadol AA. Surface landmarks for the junction between the transverse and sigmoid sinuses: Application of the "strategic" burr hole for suboccipital craniotomy. *Neurosurgery* 2009;65(6 Suppl):37-41. <https://doi.org/10.1227/01.NEU.0000341517.65174.63>.
- [10] Bisaria KK. Anatomic variations of venous sinuses in the region of the torcular Herophili. *J Neurosurg* 1985;62(1):90-5. <https://doi.org/10.3171/jns.1985.62.1.0090>.
- [11] Jackson CG. Skull base surgery. *Am J Otol* 1981;3(2):161-71.
- [12] Vloeberghs M, Glover A, Benford S, Jones A, Wang P, Becker A. Virtual neurosurgery, training for the future. *Br J Neurosurg* 2007;21(3):262-7. <https://doi.org/10.1080/02688690701245824>.
- [13] Rosahl SK, Gharabaghi A, Hubbe U, Shahidi R, Samii M. Virtual reality augmentation in skull base surgery. *Skull Base* 2006;16(2):59-66. <https://doi.org/10.1055/s-2006-931620>.
- [14] Feigl GC, Krischek B, Ritz R, Thaher F, Marquardt JS, Hirt B, et al. Evaluation of a 3-dimensional voxel-based neuronavigation system with perspective image rendering for keyhole approaches to the skull base: An anatomical study. *World Neurosurg* 2014;81(3-4):609-16. <https://doi.org/10.1016/j.wneu.2013.10.039>.
- [15] Gharabaghi A, Rosahl SK, Feigl GC, Samii A, Liebig T, Heckl S, et al. Surgical planning for retrosigmoid craniotomies improved by 3D computed tomography venography. *Eur J Surg Oncol* 2008;34(2):227-31. <https://doi.org/10.1016/j.ejso.2007.01.032>.
- [16] Gharabaghi, Rosahl SK, Feigl GC, Liebig T, Mirzayan JM, Heckl S, et al. Image-guided lateral suboccipital approach: Part 1-individualized landmarks for surgical planning. *Neurosurgery* 2008;62(3 Suppl 1):18-23. <https://doi.org/10.1227/01.neu.0000317369.07641.9c>.
- [17] Lemole GM Jr, Banerjee PP, Luciano C, Neckrysh S, Charbel FT. Virtual reality in neurosurgical education: Part-task ventriculostomy simulation with dynamic visual and haptic feedback. *Neurosurgery* 2007;61(1):142-9. <https://doi.org/10.1227/01.neu.0000279734.22931.21>.
- [18] Yudkowsky R, Luciano C, Banerjee P, Schwartz A, Alaraj A, Lemole GM Jr, et al. Practice on an augmented reality/haptic simulator and library of virtual brains improves residents' ability to perform a ventriculostomy. *Simul Healthc* 2013;8(1):25-31. <https://doi.org/10.1097/SIH.0b013e3182662c69>.
- [19] Tolsdorff B, Pommert A, Hohne KG, Petersik A, Pflesser B, Tiede U, et al. Virtual reality: A new paranasal sinus surgery simulator. *Laryngoscope* 2010;120(2):420-6. <https://doi.org/10.1002/lary.20676>.
- [20] Stam J. Thrombosis of the cerebral veins and sinuses. *N Engl J Med* 2005;352(17):1791-8. <https://doi.org/10.1056/NEJMra042354>.
- [21] William RL, Ashley W, Charbel FT. Neurovascular imaging. In: Winn H, editor. *Youmans neurological surgery*. 6<sup>th</sup> ed. Philadelphia: Saunders; 2011. p. 3603-14.
- [22] Modic MT, Weinstein MA, Starnes DL, Kinney SE, Duchesneau PM. Intravenous digital subtraction angiography of the intracranial veins and dural sinuses. *Radiology* 1983;146(2):383-9. <https://doi.org/10.1148/radiology.146.2.6336847>.
- [23] Kaufmann TJ, Huston J 3<sup>rd</sup>, Mandrekar JN, Schleck CD, Thielen KR, Kallmes DF. Complications of diagnostic cerebral angiography: Evaluation of 19,826 consecutive patients. *Radiology* 2007;243(3):812-9. <https://doi.org/10.1148/radiol.2433060536>.
- [24] Abbasi HR, Hariri S, Martin D, Shahidi R. A comparative statistical analysis of neuronavigation systems in a clinical setting. *Stud Health Technol Inform* 2001;81:11-7.