

**Case Report****Aspergillosis in a Child with Acute Myeloid Leukemia: Complications, and Treatment**Azadeh Horri <sup>1</sup>, Mehrnaz Khademi <sup>2</sup>, Javad Faryabi <sup>3</sup>, Razieh Shojaeepour <sup>1</sup><sup>1</sup> Dept. of Pediatric Dentistry, Oral and Dental Research Center, School of Dentistry, Kerman University of Medical Sciences, Kerman, Iran.<sup>2</sup> Dept. of Pediatric Dentistry, School of Dentistry, Birjand University of Medical Sciences, Birjand, Iran.<sup>3</sup> Dept. of oral & Maxillofacial Surgery, School of Dentistry, Member of Oral and Dental Diseases Research Center, Kerman University of Medical Sciences, Kerman, Iran.**KEY WORDS**Leukemia;  
Fungal infections;  
Complications;  
Psychological;*Received June 2017;  
Received in Revised form September 2017;  
Accepted October 2017;***ABSTRACT**

Microbial infection is common in patients with leukemia. However, aspergillosis is a rare complication of oral region. Attention to early diagnosis and multidisciplinary treatment can reduce the wide range of complications of the infection in these patients.

This article reports 4-year history of a child with leukemia, who suffered from a rare aspergillosis infection in the palatal region of oral cavity during chemotherapy. Early diagnosis and treatment of bacterial and fungal infections, especially rare types such as aspergillosis, in patients with leukemia is important for reducing widespread complications. However, prosthetic treatment and attention to psychological complications of orofacial defects would also improve their quality of life significantly. These improvements can be seen more clearly in children.

**Corresponding Author:** Khatami M., Dept. of Pediatric Dentistry, School of Dentistry, Birjand University of Medical Sciences, Birjand, Iran. Email: mehr.kh6688@yahoo.com Tel: +98-56-32234715

**Cite this article as:** Horri A., Khademi M., Faryabi J., Shojaeepour R. Aspergillosis in a Child with Acute Myeloid Leukemia: Complications, and Treatment. *J Dent Shiraz Univ Med Sci.*, 2018 December; 19(4): 320-324.

**Introduction**

Fortunately, leukemia is a rare condition in children and adults. However, since 1970, there has been a slow increase in the incidence of this malignancy during childhood. [1] A specialty team is necessary to treat leukemic children properly; this team should consist of a pediatric oncologist and hematologist, a pediatrician, a pedodontist, a pediatric psychiatric, and so on. [2] Patients with leukemia require long-team follow-ups due to the complications of the condition itself and adjunctive treatments. Leukemia is classified into myeloid and lymphocytic variants. Approximately, 20% of leukemia cases have a myeloid origin. [3] The majority of myeloid leukemia cases are of the acute type. In this condition, the self-destruction process of stem cells or progenitors decrease and the cellular differentiation capacity becomes limited. Therefore, these groups of cells accumulate in the bone marrow and if the bone marrow blast cells increase to over 20%, the condition will be acute. [1] Patients undergoing chemotherapy are susceptible to different bacterial, viral, and fungal infections due to the

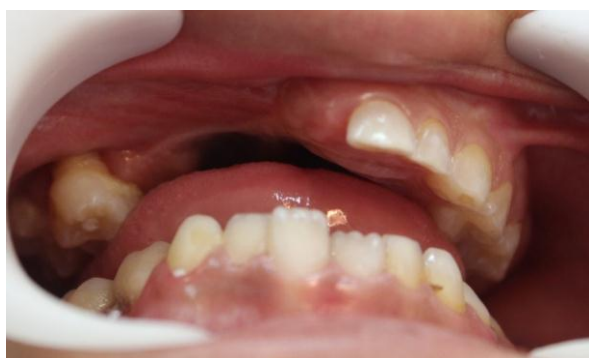periodic weakening of the immune system. Prophylactic use of antibacterial and antifungal agents in children undergoing treatment for acute myeloid leukemia (AML) has been advocated. [4] Invasive fungal infections are some of the most important complications of patients undergoing chemotherapy for AML; this condition has a poor prognosis but success has been reported by surgery and a multidisciplinary approach. However, the possible defect created might result in major functional and psychological complications. [5-6]

We hope that reporting this case will provide valuable information for dentists on the diagnostic criteria, therapeutic steps, and complications after the treatment of leukemia patients. In addition, this report draws attention to the psychological problems of such patients and can provide the necessary information about the fabrication of dentures for them.

**Case Report**

An 8-year-old boy was referred to the Department of Pediatric Dentistry, Faculty of Dentistry, Kerman Uni-

versity of Medical Science, Kerman, Iran. The parents complained of the patient's facial asymmetry, especially during speaking, smiling, and the boy's psychological problems, including social isolation and lack of self-confidence in social circumstances. The patient's history revealed the incidence of AML when he was 3 years and 7 months of age. Clinical examination revealed facial asymmetry, especially during smiling. The child had poor eye contact and was reluctant to speak. Intraoral examination revealed an osseous defect in the alveolar ridge and palate from deciduous central incisors on the maxillary right side to the deciduous first molar on the same side (Figure 1).

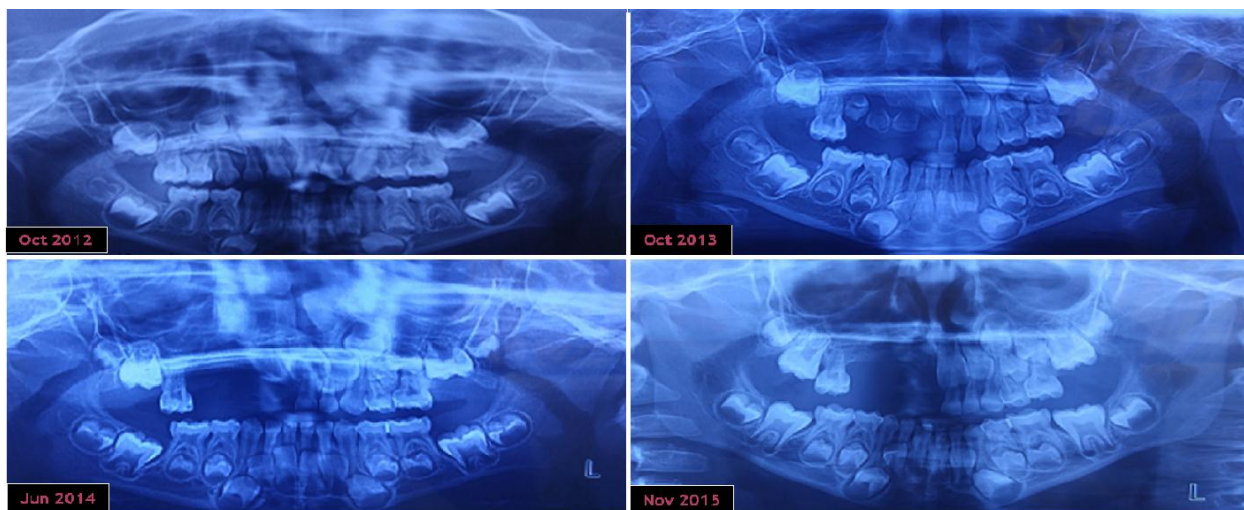


**Figure 1:** Defect in the alveolar ridge and palate

No other anomalies were found in other intraoral areas. Evaluation of the medical file of the patient showed that at 3 years and 7 months of age, the patient experienced fever, constant rhinorrhea, and listlessness during sleep. However, physicians reached no specific diagnosis during repeated visits. After a month, the child manifested sudden and progressive cyanosis on his hands. The patient was admitted into a hospital and a CBC test revealed a severe depletion of platelets to <1000. Given the possibility of intracranial hemorrhage, after supplementary paraclinical examinations, the patient received platelets and plasma. After evaluation of paraclinical examinations, a diagnosis of AML M2 with an unknown cause was reached. After the diagnosis, chemotherapy was administered. After four series of chemotherapy, the patient exhibited a 40° fever for one month, which was managed with acetaminophen. Then there were multiple hemorrhages, swelling and progressive cyanosis of the right side of the face for one month. Intraoral examination of the patient revealed a brown exophytic lesion in the area of right maxillary deciduous central incisor up to the deciduous first molar on the

same side along with the exposure of the necrotic bone and movable osseous sequestra. The area afflicted on the maxillary right quadrant underwent an incisional biopsy by a maxillofacial surgeon and the histopathological diagnosis of necrotizing fungal infection (aspergillosis) revealed the presence of *Aspergillus* fungal species. After the last chemotherapy session, the gingiva and alveolar ridge area of the right maxilla affected by fungal infection underwent surgical resection. Then the patient was discharged from the hospital and received voriconazole, fluconazole, and amphotericin B for 3 months. Six months after discontinuation of medications for fungal infections, the fungal infection recurred in the same area. Subsequently, a maxillofacial surgeon resected the maxillary bone in the area of the deciduous central incisor on the right side up to the deciduous first molar on the same side with removal of permanent teeth buds. Then antifungal medications were administered again for 2 months. After these procedures, the patient had no problems and laboratory tests revealed normal hematologic parameters. A maxillofacial surgeon and an oncologist examined the patient every two months as check-ups (Figure 2).

After complete treatment of leukemia and fungal infection, the chief complaint of the patient and his parents was difficulty in eating food and facial asymmetry during speaking and smiling that resulted in psychological problems and his avoidance in presence in social environments concerning his appearance. The patient underwent thorough clinical and radiographic examinations with the use of panoramic radiographic technique and alginate impressions. After fabrication of a special tray and border molding, a final impression was taken with alginate and the patient's casts were mounted in an articulator at a correct and proper relationship. One of the problems was the absence of the alveolar ridge and a large osseous defect in the area of maxillary right deciduous central incisor up to the deciduous first molars on the same side. As a result, the prosthetic maxillary teeth were set in an end- to-end relationship with a labial inclination to preserve the health of unsupported buccal tissues in the maxillary defect area. After checking the position of the teeth in the patient's oral cavity and evaluation of the status of the adjacent soft tissue, the prosthetic appliance was fabricated with the use of heat-cured acrylic resin. In order to increase retention and pa-



**Figure 2:** Patient's serial panoramic radiographs since the initial appear of fungal lesion

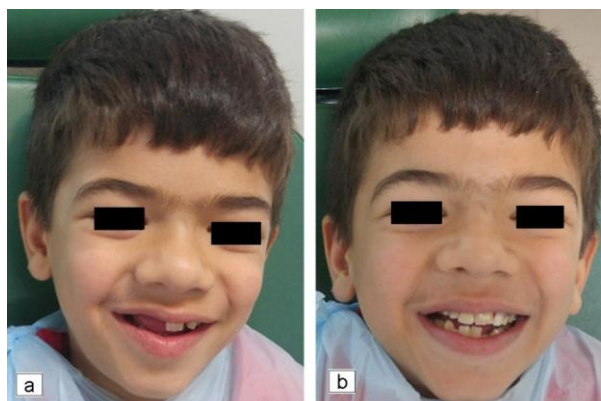
tient comfort, two Adams clasps were placed on the maxillary deciduous second molars and a C clasp was placed on the maxillary left deciduous central incisor. After fabrication of the prosthetic appliance in the laboratory, the final adjustment of the appliance was carried out in the patient's oral cavity. During the follow-up visits after one day, one week, one month and consequent monthly follow-ups for six months, the child had no functional problems and exhibited proper esthetic appearance (Figure 3a and b).

Clinical examinations of the oral cavity and soft tissues did not reveal any specific problems. Based on the parents' report, the child exhibited much higher inclination for speaking and smiling with the prosthetic appliance and improved his performance in school. Nine months after the delivery of the first prosthetic appliance, another prosthetic appliance was fabricated for the patient due to his growth and tightening of the appliance. The same procedures were followed for the

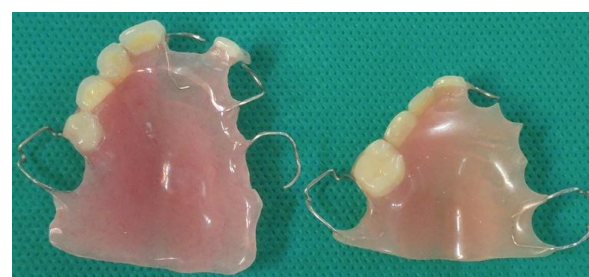
fabrication of the second appliance (Figure 4). Currently, the patient is under 3-month dental follow-ups and the parents have been advised in relation to the necessity of a high level of oral hygiene and periodic clinical examinations and fabrication of new prosthetic appliances considering the patient's growth. In addition, suggestions have been made to the parents concerning the possibility of bone grafts in the affected area and placement of implants after the growth period at 18 years of age.

**Discussion**

Invasive fungal infections are one of the most important complications in AML patients undergoing chemotherapy. Even individuals that survive after initial invasive fungal infection have a poor long-term survival rate in case of recurrence. [5-6] The prognosis of invasive fungal infection is poor subsequent to chemotherapy. Areas that are most frequently affected are lower respiratory tracts, upper airways, digestive tract, and bloodstream, in addition to the incidence of hepatosplenic microabscesses; in some rare cases, genitourinary tract, skin, intestines and central nervous system are affected. Aspergillus infection of the oral cavity is rarer than infections with other fungal species. [7-8] However, the inci-



**Figure 3a:** Facial asymmetry of patient during smiling. **b:** Face of the child with the prosthetic appliance exhibited proper esthetic appearance.



**Figure 4:** The first and second prosthetic of the patient

dence of *Aspergillus* infection has increased in the past two decades and one of the signs that has been reported, similar to that in the present case, is fever that does not subside with the use of antibiotics. [9] It is very important to treat fungal infections rapidly and effectively in patients under treatment for hematologic conditions to be able to continue chemotherapy. [8, 10] There are reports about the involvement of the palate by *Aspergillus*. It is difficult to diagnose oral aspergillosis initially in leukemic patients and it might be confused with periodontitis. Cho *et al.* [8] reported a case of aspergillosis on the palate in a patient with acute lymphoblastic leukemia. Initially, a diagnosis of bacterial periodontitis was made for the presence of cellulitis along with a gray necrotic lesion on the palate in the area of the second permanent molar, and the tooth was extracted. After tooth extraction, cellulitis resolved but fever and the painful necrotic ulcer, yellow-brown in color, and swelling on the palatal gingiva persisted. After incisional biopsy, a diagnosis of aspergillosis was established. After an excisional surgical procedure in association with antifungal therapy, the intraoral lesion improved and the fever subsided. Follow-ups for three months did not reveal recurrence of the lesion. [8] If the early diagnosis is not reached, the odds of morbidity and mortality will increase. [8, 11]

Surgical intervention in association with antifungal therapy yields better results than antifungal therapy alone. [8]

Unfortunately, in the case presented here aspergillosis erupted in the oral cavity on the right side of the maxilla due to the neutropenia and the immunocompromised status of the subject due to disease and chemotherapy. Despite gingival surgery and resection of a part of the alveolar ridge of the maxilla, fungal infection recurred despite antifungal therapy due to the poor prognosis of the invasive aspergillosis of the orofacial tissues and the therapeutic team was forced to expand the surgical area. Fortunately, consistent with other studies, the surgery and medical management was successful. [12] In the case presented here, similar to other studies, the defect had a significant effect on all the life aspects of the patient after the surgical procedure. The prosthetic treatment of the maxillofacial defect in patients not only improves the functional and physical defect, but also helps treat the patients' psychosocial

problems. [13] Unfortunately, this part of treatment, i.e. treatment of and assistance to improve the psychological status of patients with maxillofacial defects is neglected. Treatment of patients with maxillofacial defects, who have psychological problems, is a major challenge. Psychologists emphasize the importance of improving the physical status to improve the psychological status of such patients.

Studies have shown that such patients compare their own appearance with other attractive, capable, and socially favorable individuals and the differences they see result in a decrease in self-confidence and social isolation. [14] Children that are positively supported by their families exhibit less behavioral problems. Studies have shown that 30–40% of children with craniofacial abnormalities have behavioral problems, including introvert behaviors (depression, a decrease in self-confidence, social isolation and shame) or externalizing behaviors (disobedience, fighting and impulsive behaviors). [15] Unfortunately, due to difficult and complex nature of medical treatments in such patients, this is neglected in many cases by physicians and families. Dentists can play a very important role in such cases by fabricating proper prosthetic appliances in the oral cavity. It appears the prevalence of psychological problems in patients with craniofacial defects is much higher than that reported in the literature. [16] In the child reported here, despite comprehensive support by the family, behavioral problems were evident and the child even refused to attend school. In the present case, too, similar to other studies, [16] the patient's function and appearance improved by timely dental intervention and its positive effects on the child's personal life and social activities were completely evident through an increase in happiness and social activities and relationships. The subject reported here exhibited superb cooperation in the use of the prosthetic appliance and after this prosthetic appliance was fabricated and delivered, he exhibited a higher level of participation in social environments and in playing with his peers. Based on the parents' report, the subject's nutrition, esthetic appearance, and self-confidence increased significantly. It is necessary to deliver a new prosthetic appliance periodically to the child, regarding his constant growth, through regular periodic examinations.

## Conclusion

Two of the most important reasons for reporting this case are first, drawing dentists' attention to the fever and swelling of maxillofacial region, especially in the oral cavity of leukemia patients since it may easily be confused with dental infections. Such a misdiagnosis can cause delays in treatment of the main cause of infection and thus its complication from various aspects can be multiplied. Second, in cases in which medical problems (such as cancer) result in the loss of a part of craniofacial bones, the therapeutic team should pay a lot of attention to the psychological status of the patient. This is more important in children because of their greater psychological sensitivity.

## Conflict of Interest

Authors have no conflicts of interest to declare.

## References

- [1] Board PP. Childhood Acute Myeloid Leukemia/Other Myeloid Malignancies Treatment (PDQ®). Available at: [http://www.dana-farberbostonchildrens.org/conditions/leukemia-and-lymphoma/acute-myelogenous-leukemia.aspx?utm\\_source=bing&utm\\_medium=cpc&\\_vsig=ck&\\_vsrefdom=AMLbing&utm\\_campaign=Acute%20Myeloid%20Leukemia&utm\\_term=acute%20myeloid%20leukemia&utm\\_content=Acute%20Myeloid%20Leukemia](http://www.dana-farberbostonchildrens.org/conditions/leukemia-and-lymphoma/acute-myelogenous-leukemia.aspx?utm_source=bing&utm_medium=cpc&_vsig=ck&_vsrefdom=AMLbing&utm_campaign=Acute%20Myeloid%20Leukemia&utm_term=acute%20myeloid%20leukemia&utm_content=Acute%20Myeloid%20Leukemia)
- [2] Pritchard-Jones K, Hargrave D. Declining childhood and adolescent cancer mortality: great progress but still much to be done. *Cancer*. 2014; 120: 2388-2391.
- [3] Ries LAG, Smith MA, Gurney JG, Linet M, Tamra T, Young JL, et al. Cancer Incidence and Survival among Children and Adolescents. No. 99-4649. United States SEER Program 1975-1995. Bethesda, MD.: National Cancer Institute, SEER Program. NIH Pub.; 1999. p. 149-156. Available at: <https://seer.cancer.gov/archive/publications/childhood/>
- [4] Kurt B, Flynn P, Shenep JL, Pounds S, Lensing S, Ribeiro RC, et al. Prophylactic antibiotics reduce morbidity due to septicemia during intensive treatment for pediatric acute myeloid leukemia. *Cancer*. 2008; 113: 376-382.
- [5] Tang JL, Kung HC, Lei WC, Yao M, Wu UI, Hsu SC, et al. High Incidences of Invasive Fungal Infections in Acute Myeloid Leukemia Patients Receiving Induction Chemotherapy without Systemic Anti-fungal Prophylaxis: A Pro-spective Observational Study in Taiwan. *PLoS One*. 2015; 10: e0128410.
- [6] Yunus S, Pieper S, Kolve H, Goletz G, Jürgens H, Groll AH. Azole-based chemoprophylaxis of invasive fungal infections in paediatric patients with acute leukaemia: an internal audit. *J Antimicrob Chemother*. 2014; 69: 815-820.
- [7] Del Principe MI, Buccisano F, Maurillo L, Venditti D, Cefalo M, Sarlo C, et al. Infections increase the risk of central venous catheter-related thrombosis in adult acute myeloid leukemia. *Thromb Res*. 2013; 132: 511-514.
- [8] Cho H, Lee KH, Colquhoun AN, Evans SA. Invasive oral aspergillosis in a patient with acute myeloid leukaemia. *Aust Dent J*. 2010; 55: 214-218.
- [9] Spasova MI, Grudeva-Popova JG, Genev ED, Lazarova A, Stoyanova AA, Mumdjiev IN. Pseudomembranous necrotizing tracheobronchitis caused by *Aspergillus* spp--contribution of one case with acute myeloid leukemia. *Folia Med (Plovdiv)*. 2006; 48: 93-97.
- [10] Ali R, Ozkalemkas F, Ozcelik T, Oz-kocaman V, Ozkan A, Bayram S, et al. Invasive pulmonary aspergillosis: role of early diagnosis and surgical treatment in patients with acute leukemia. *Ann Clin Microbiol Antimicrob*. 2006; 5: 17.
- [11] Bojic M, Willinger B, Rath T, Tobudic S, Thalhammer F, Böhm A, et al. Fatal skin and pulmonary infection caused by *Hormoglyphiella aspergillata* in a leukaemic patient: case report and literature overview. *Mycoses*. 2013; 56: 687-689.
- [12] Karabulut AB, Kabakas F, Berköz O, Karakas Z, Kesim SN. Hard palate perforation due to invasive aspergillosis in a patient with acute lymphoblastic leukemia. *Int J Pediatr Otorhinolaryngol*. 2005; 69: 1395-1398.
- [13] Hatfield E, Sprecher S. *Mirror, mirror: The importance of looks in everyday life*. 1st ed. SUNY Press: New York, United States; 1986. p. 199-231.
- [14] Harter S. Processes underlying the construction, maintenance, and enhancement of the self-concept in children. *Psychological perspectives on the self*. 1986; 3: 136-182.
- [15] Endriga MC, Kapp-Simon KA. Psychological issues in craniofacial care: state of the art. *Cleft Palate Craniofac J*. 1999; 36: 3-11.
- [16] Hickey AJ, Salter M. Prosthetic and psychological factors in treating patients with congenital and craniofacial defects. *J Prosthet Dent*. 2006; 95: 392-396.