



Tehran University of Medical
Sciences Publication
<http://tums.ac.ir>

Iran J Parasitol

Open access Journal at
<http://ijpa.tums.ac.ir>



Iranian Society of Parasitology
<http://isp.tums.ac.ir>

Original Article

Parasitic Helminths in Wild Boars (*Sus scrofa*) in Mazandaran Province, Northern Iran

Samira DODANGEH^{1,2}, Davoud AZAMI^{1,2}, Ahmad DARYANI¹, Shirzad GHOLAMI¹,
Mehdi SHARIF¹, Iraj MOBEDI³, *Shahabeddin SARVI¹, Eissa SOLEYMANI^{1,2},
Mohammad Taghi RAHIMI⁴, Majid PIRESTANI⁵, Shaban GOHARDEHI^{1,2}, Reza
BASTANI^{1,2}

1. *Toxoplasmosis Research Center, Mazandaran University of Medical Sciences, Sari, Iran*

2. *Student Research Committee, Mazandaran University of Medical Sciences, Sari, Iran*

3. *Dept. of Medical Parasitology and Mycology, School of Public Health, Tehran University of Medical Sciences, Tehran, Iran*

4. *Dept. of Basic Medical Sciences, School of Medicine, Shahrood University of Medical Sciences, Shahrood, Iran*

5. *Dept. of Parasitology, School of Medical Sciences, Tarbiat Modares University, Tehran, Iran*

Received 10 Jul 2017

Accepted 12 Sep 2017

Keywords:

Wild boar,
Parasitic helminths,
Prevalence,
Iran

***Correspondence**

Email:

shahabesarvi@yahoo.com

Abstract

Background: Wild boars (*Sus scrofa*) are distributed worldwide and found in many parts of Iran. Although *S. scrofa* is reservoirs for many parasites, there is little data on helminthic prevalence in them. We aimed to survey the status of helminthic infections in *S. scrofa* in the Mazandaran Province of northern Iran.

Methods: Twenty-one wild boars were captured and examined for helminth infection during Dec 2012-Mar 2014. Adult worms such as *Macracanthorhynchus hirudinaceus* were identified by helminth size and shape, and the arrangement of the proboscis hooks. The sedimentation and flotation techniques were used to detect parasite eggs and larvae in faecal samples. Muscle samples were also surveyed for *Trichinella* larvae by artificial digestion method.

Results: Of the 21 samples, 13 (61.9%) were infected with one or more helminth species. Seven helminth types were identified in the alimentary track, comprising 5 nematodes, 1 trematode, and 1 acanthocephalan, with prevalence rates of *Macracanthorhynchus hirudinaceus* (57.14%), *Globocephalus* spp. (33.33%), *Trichuris suis* (19.04%), *Gongylonema pulchrum* (14.28%), *Fasciola hepatica* (14.28%), *Diocotophyma renale* (4.76%), and *Ascaris suum* (4.76%).

Conclusion: Wild boars might be involved in transmitting zoonotic parasites to humans. The abundance of these animals near human habitation creates favorable conditions for infection. So the risk of parasitic helminth diseases increases in other animals and humans.

Introduction

Wild boars (*Sus scrofa*) are distributed worldwide (1) and are omnivorous, with diets comprising insect larvae, amphibians, reptiles, mushrooms, birds, bird eggs, small rodents, fruits, etc. (2). Owing to their natural feeding habits, *S. scrofa* is host and reservoir of many parasites; they play an important role in the transmission of infections to domestic animals and humans (2).

Sus scrofa may pass feces including infectious agents in the farming fields and cause to contaminate water resources and the subsequent these agents influence to crops and plants. Therefore, people who eat these plants are infected (3).

Wild boars are found in many parts of Iran, especially in the mountainous areas. They usually cause destruction of crops and are often killed by farmers or hunted for meat by Christian Armenians (3). Although *S. scrofa* is widely distributed in northern Iran, little information is available about the parasitic infections in wild boars in northern Iran.

We determined the status of helminthic infections in wild boars in the Mazandaran Province of northern Iran.

Materials and Methods

Ethical approval

Ethical approval of present study was received from the Ethics Committee in Mazandaran University of Medical Sciences, Mazandaran, Iran.

Study area

This study was conducted in the suburbs of 3 different cities (Sari, Savadkuh, and Behshahr) in the Mazandaran Province, Iran. The Mazandaran province (36° 33' 56" N 53° 03' 32" E) is located in northern Iran on the southern coast of the Caspian Sea (Fig. 1). It covers an area of approximately 23842 km² and has a population of 2,922,432 individuals. This province has a moderate and subtropical climate and is geographically divided into the three regions: plains, forests, and mountains.

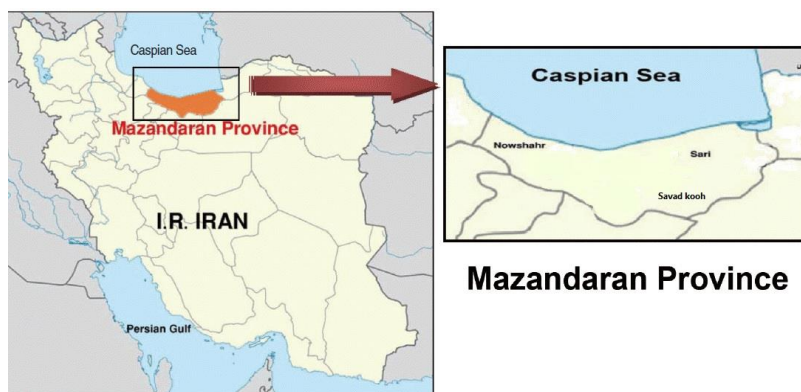

Fig. 1: Map of Mazandaran Province, northern Iran and 3 different cities (Sari, Savadkuh, and Behshahr), Iran

Sample collection

Twenty-one wild boars were captured from Dec 2012 to Mar 2014. During sampling, the shooting site, sampling time, sex, and age of each boar were recorded. Based on tooth shape and development and physical appear-

ance, the samples were categorized into three age groups (4). The abdominal viscera of the animals were removed immediately after capture, placed in plastic bags, labeled, and sent to the parasitology laboratory, Mazandaran University, Iran. Necropsy was performed in the

laboratory, and in the first step, internal organs such as oesophagus, stomach, small and large intestines, liver, and muscles, including the diaphragm were examined macroscopically for the presence of helminthic parasites. All the parasite worms were identified (5). For example in present study, *M. hirudinaceus* was identified according to helminth size and shape, and the arrangement of the proboscis's hooks.

To recover non-visible helminths, the stomach and intestine were separately washed in buckets with tap water and squeezed through 500- μm and 150- μm sieves. The sedimentation and flotation techniques were used to detect parasite eggs and larvae in faecal samples collected from the intestinal tract (6). The ova were identified based on morphological features (shape, structure, and presence of larva) (7). In addition, muscle samples were surveyed for *Trichinella* larvae by two direct and artificial digestion methods.

Statistical analysis

SPSS version 16.0 (Chicago, IL, USA) was used for all statistical analyses. Chi-squared (χ^2) test was performed to investigate the significance of the differences in prevalence of helminth infections between age and sex in

the different groups. The level of significance was $P < 0.05$ for all calculations.

Results

Of the 21 wild boars (11 females and 10 males) examined for helminthic infections, 13 (61.9%) were infected with one or more helminth species. Seven helminth types were identified, comprising 5 nematodes, 1 trematode, and 1 acanthocephalan. The prevalence of helminth species in the suburbs of 3 different cities in the Mazandaran Province are shown in Table 1. The highest prevalence was observed for *M. hirudinaceus* (57.14%) (Fig. 2), while the lowest was recorded for *Dioctophyma renale* (4.76%) and *Ascaris suum* (4.76%). Helminth infections were found in 10 of 11 wild boars (90.9%) in Savadkuh, 3 of 5 (60.0%) in Behshahr, and 0 of 5 (0%) in Sari. Of the 13 (61.9%) wild boars infected with helminth species, Poly-parasitism was more common (84.62%) than mono-parasitism (15.38%). Poly-parasitism with *M. hirudinaceus* was the most frequent (Table 2). The age of the wild boars could not influence the prevalence of infection. In addition, there was no significant difference in the prevalence rates of infection in males and females (Table 3).

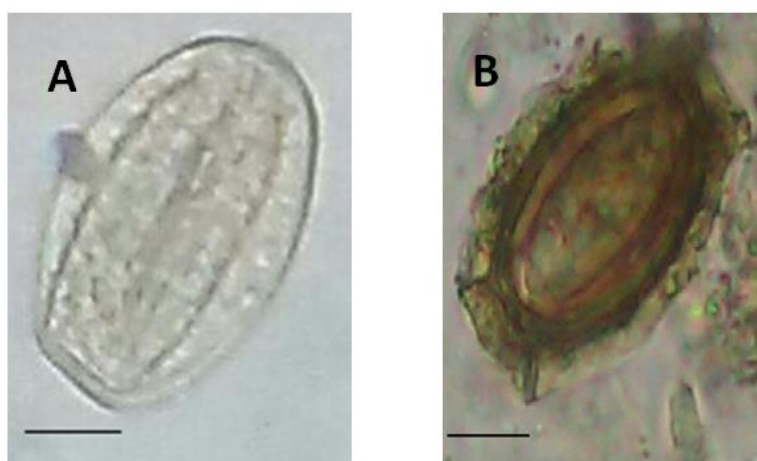


Fig. 2: Endoparasites of isolated from *Sus scrofa*
A: Egg of *Macracanthorhynchus hirudinaceus*; B: Egg of *Trichuris suis*. Bars=15 μm . Eggs are shown by $\times 40$ magnification (Original)

Table 1: Prevalence of helminth infections in *Sus scrofa* in Mazandaran, northern Iran

<i>Parasites</i>	<i>Infected wild boars number</i>			<i>Prevalence (%)</i>
	<i>Behshahr City</i>	<i>Sari City</i>	<i>Savadkuh City</i>	
<i>M. hirudinaceus</i>	9	0	3	57.14
<i>Globocephalus</i> spp.	7	0	0	33.33
<i>T. suis</i>	3	0	1	19.04
<i>G. pulchrum</i>	3	0	0	14.28
<i>F. hepatica</i>	2	0	1	14.28
<i>Diocotophyma renale</i>	1	0	0	4.76
<i>A. suum</i>	1	0	0	4.76

Table 2: Prevalence of multiple infections (helminths) in 21 wild boars in Mazandaran, northern Iran

<i>Species of parasite per wild boar</i>	<i>Number of infected wild boars</i>
<i>M. hirudinaceus</i>	2
<i>M. hirudinaceus</i> + <i>Globocephalus</i> spp.	2
<i>M. hirudinaceus</i> + <i>T. suis</i>	1
<i>M. hirudinaceus</i> + <i>F. hepatica</i>	1
<i>Globocephalus</i> spp. + <i>A. suum</i>	1
<i>M. hirudinaceus</i> + <i>Globocephalus</i> spp. + <i>G. pulchrum</i>	2
<i>M. hirudinaceus</i> + <i>Globocephalus</i> spp. + <i>T. suis</i>	1
<i>M. hirudinaceus</i> + <i>T. suis</i> + <i>F. hepatica</i>	1
<i>M. hirudinaceus</i> + <i>F. hepatica</i> + <i>G. pulchrum</i>	1
<i>M. hirudinaceus</i> + <i>Globocephalus</i> spp. + <i>T. suis</i> + <i>Diocotophyma renale</i>	1
Total number of infected wild boars	13

Table 3: Prevalence of helminth infections of wild boars in relation with age and sex

<i>Variable</i>	<i>Number examined</i>	<i>Number infected</i>	<i>Percentage (%)</i>	<i>P-value</i>
Age (yr)				> 0.05
≤ 1	9	3	33.3	
1 < and < 3	6	4	66.6	
3-10	6	6	100	
Sex				> 0.05
Male	10	8	80	
Female	11	5	45.4	
Total	21	13	61.9	

Discussion

There is little data available on helminth prevalence in *S. scrofa* in Iran, and there have been no comprehensive studies on worm prevalence in the Mazandaran Province. The results of this study showed a helminth prevalence of 61.9% in 21 *S. scrofa* from the Mazandaran Province of Iran. This prevalence was higher than that reported from Talesh

City, in the Guilan Province of Iran (34%) (8), but was almost similar to results (1), who reported a prevalence of 74% in the north, northeast, and southwest of Iran, and another (9), who reported a prevalence of 58.3% in Luristan in western Iran. Similarly, in Tamil Nadu, south India opined which majority of wild boars surveyed (62%) had at least one helminth species in the internal organs (10). The reasons for such similarity in Tamil Nadu

and Mazandaran might be assigned to the feeding regime of wild boars and climatic conditions of these two areas.

In the present study, we found seven types of helminths in wild boars, while 16 species of worms were reported in 57 wild boars (1). Of the 7 important nematode species included in the veterinary report (11), two were found in our study: *A. suum* and *T. suis*.

Our results also showed that *M. hirudinaceus* was the most prevalent helminth, followed by *Globocephalus* spp. While this is consistent with the other results (9), it is in contrast to the results (1), who reported that *Globocephalus* spp. was the most prevalent helminth in wild boars. *M. hirudinaceus* is distributed worldwide and has been reported in different hosts such as dogs, pigs, and even humans (12). While this parasite has been frequently reported in kinds of dogs and wild boars in Iran (13), human infection has not yet been reported. Definitive hosts have been known to be infected after ingestion of different beetle species (14). In this study, 12 of the 21 (57.14%) *S. scrofa* were infected with this parasite, indicating that these animals could play an important role in the infection of humans with *M. hirudinaceus* in Iran, especially in the suburban and rural areas.

In this study, the prevalence rate of 33.33% was recorded for *Globocephalus* spp. The moderately high prevalence of *Globocephalus* spp. might be due to the suitable conditions for resistance against the infectious larvae in this region. Wild boars infected with *Globocephalus* spp. suffer from anaemia and pathologic changes in the mucosa (15).

T. suis (Fig. 2), found in this study, is an intestinal nematode found in wild boars (16), and is similar to *Trichuris trichura* in humans, with respect to life cycle, morphology, and symptoms (17). Additionally, the successful transmission of this nematode from pigs to humans was reported (18).

G. pulchrum is another nematode identified in the present study with a prevalence of 14.28%. A higher prevalence (35%) of this worm was

reported (1). Humans could be accidentally infected with *G. pulchrum* (19).

F. hepatica, a liver fluke identified in the current study with a prevalence of 14.28%, was reported to have a prevalence of 4% (1). In the northwest region of Spain, a prevalence of 11.2% for *F. hepatica* was found in 358 wild boars from Galicia (20). This was the first study to suggest that wild boars could be primary hosts for *F. hepatica*. As people consume forest herbs and plants in the northern regions of Iran, wild boars might be considered reservoir host of fascioliasis for human infection.

Among the helminths identified in this study, egg *Diocotophyma renale* was also observed in the faeces; while eggs of mentioned species are shed in the urine, there is the possibility that the eggs passed through the alimentary system of wild boar after the consumption of infected host.

Furthermore, the prevalence of 4.76% recorded for *A. suum* in this survey was almost the same as that reported in three geographical areas (north, northeast, and southwest) of Iran (5%) (1), but was lower than that reported in Eastern Ghana (12.7%) (21) and Botswana (54.6%) (22). Although the prevalence of *A. suum* recorded in the present study was not very high, it is nevertheless important because this parasite has been known to cause severe visceral larval migration, liver and lung lesions, and eosinophilic pneumonia in humans (23).

However trichinellosis frequently occurs in extensive varieties of canids in Iran (24), in this study, no wild boars were infected.

In the three regions of the Mazandaran Province studied, only Sari city had no boars with helminthic infection. This may be due to the different climatic, geographical, and environmental conditions of this region, compared to the other regions. Sari city has comparatively lesser vegetation than the two other cities and is located in a flat area.

Conclusion

Wild boars might play an important role in transmitting zoonotic parasites to humans. The

abundance of these animals near human habitation creates favorable conditions for infection. Therefore, the risk of protozoan diseases increases in other animals and humans.

Acknowledgements

The authors would like to appreciate very much for kind collaboration of Dr. Badali. They also would like to thank the financial support by Vice Chancellors for Research of Mazandaran University of Medical Sciences, Iran (project no. 901).

Conflict of interest

The authors declare that there is no conflict of interests.

References

- Eslami A, Farsad-Hamdi S. Helminth parasites of wild boar, *Sus scrofa*, in Iran. *J Wildl Dis.* 1992; 28(2):316-8.
- Mowlavi G, Massoud J, Mobedi I et al. Very highly prevalent *Macracanthorhynchus hirudinaceus* infection of wild boar *Sus scrofa* in Khuzestan province, south-western Iran. *Helminthologia.* 2006;43(2):86-91.
- Yaghoobi K, Sarkari B, Mansouri M, Motazedian MH. Zoonotic intestinal protozoan of the wild boars, *Sus scrofa*, in Persian Gulf's coastal area (Bushehr province), Southwestern Iran. *Vet World.* 2016; 9(10):1047-1050.
- Anezaki T. Estimating age at death in Jomon Japanese wild boar (*Sus scrofa leucomystax*) based on the timing of molar eruption in recent comparative samples. *Mammal Study.* (2009);34(2):53-63.
- Mehlhorn H, Düwel D, Raether W. Atlas de parasitología veterinaria. Grass, Barcelona. 1992; p.436.
- Ziomko I, Cencek T. Outline of laboratory diagnosis of farm animal parasitoses. Publisher National Veterinary Research Institute, Pulawy; 1995.
- Thienpont D, Rochette F, Vanparijs O. Diagnosing helminthiasis by coprological examination. Published in Beerse by Janssen Research Foundation; 1986.
- Garedaghi Y, Mojallal S, Ouzbandi A. Helminth Parasites of a hunted-wild boar (*Sus scrofa*) in the Talesh City, North of Iran. *Bull Env Pharmacol. Life Sci.* 2014;3(3):247-250.
- Solaymani-Mohammadi S, Mobedi I, Rezaian M et al. Helminth parasites of the wild boar, *Sus scrofa*, in Luristan province, western Iran and their public health significance. *J Helminthol.* 2003; 77(3):263-7.
- Boon A, Jayathangaraj MG, Palanivelrajan M et al. Prevalence of helminthic fauna in wild pigs in comparison with domestic pigs: A study in the adjoining areas of Mudumalai, Anamalai and Sathyamangalam tiger reserves, Tamil Nadu south India. *J. Parasitol. Vector Biol.* 2015; 7(3): 46-52.
- Nansen P, Roepstorff A. Parasitic helminths of the pig: factors influencing transmission and infection levels. *Int J Parasitol.* 1999; ;29(6):877-91.
- Leng YJ, Huang WD, Liang PN.. Human infection with *Macracanthorhynchus hirudinaceus* Travassos, 1916 in Guangdong Province, with notes on its prevalence in China. *Ann Trop Med Parasitol.* 1983; 77(1):107-9.
- Arbabi M, Doroodgar A, Hooshyar H et al. *Macracanthorhynchus hirudinaceus* in carnivores of Kashan region, Iran. In Third National Congress on Medical Parasitology, Sari, Iran. 2001.
- Mobedi I, Arfaa F, Vedadi L. The possible role of dung-pusher beetles in the epidemiology of intestinal helminths. *Bull Soc Pathol Exot Filiales.* 1971; 64(6):924-5.
- Soulsby eJL. Helminths, arthropods and protozoa of domesticated animals. *Can Vet J.* 1968; 10(8):223.
- Pattison HD, Thomas RJ, Smith WC. A survey of gastrointestinal parasitism in pigs. *Vet Rec.* 1980; 107(18):415-8.
- Holland C. Neglected infections-trichuriasis and strongyloidiasis. Impact of Helminth Infections on Human Nutrition. London: Taylor and Francis. 1987; 161-201.
- Beer RJ. Experimental infection of man with pig whipworm. *Br Med J.* 1971; 2(5752):44.

19. Bleier T, Hetzel U, Bauer C, Behlert O, Burkhardt E. *Gongylonema pulchrum* infection and esophageal squamous cell carcinoma in a vari (Lemur macaco variegata; Kehr 1792). *J Zoo Wildl Med.* 2005; 36(2):342-5.
20. Mezo M, González-Warleta M, Castro-Hermida JA et al. The wild boar (*Sus scrofa* Linnaeus, 1758) as secondary reservoir of *Fasciola hepatica* in Galicia (NW Spain). *Vet Parasitol.* 2013; 198(3-4):274-83.
21. Tiwari k. P, Chikweto A, Belot G et al. Prevalence of intestinal parasites in pigs in Grenada, West Indies. *W Indian Vet J.* 2009; 9(1):22-27.
22. Nsoso SJ, Mosala KP, Ndebele RT, Ramabu SS. The prevalence of internal and external parasites in pigs of different ages and sexes in Southeast District, Botswana. *Onderstepoort J Vet Res.* 2000; 67(3):217-20.
23. Kakihara D, Yoshimitsu K, Ishigami K et al. Liver lesions of visceral larva migrans due to *Ascaris suum* infection. *Abdom Imaging.* 2004; 29(5):598-602.
24. Mobedi I, Arfaa F, Madadi H, Movafagh K. Sylvatic focus of trichinosis in the Caspian region, northern Iran. *Am J Trop Med Hyg.* 1973; 22(6):720-2.