

Case Report

# Stroke due to Paradoxical Embolization Related to Fibroid Uterus Enlargement Compressing the Right Common Iliac Vein

Sarkis Morales Vidal · Geeta Verma · Carolyn Goldschmidt · José Biller

Department of Neurology, Loyola University Chicago Stritch School of Medicine, Maywood, IL, USA

## Keywords

Ischemic stroke · Paradoxical embolization · Fibroid uterus enlargement · Right common iliac vein compression

## Abstract

Stroke in young women is commonly cryptogenic or associated with an underlying hypercoagulable state (e.g., hormonal contraception). Paradoxical embolization has been postulated as a potential risk factor for stroke in young adults. Many sources of venous thrombosis leading to paradoxical embolization have been described. There have been few reported cases of uterine enlargement leading to iliac vein compression and paradoxical embolization. We present the case of a young adult woman who had a left middle cerebral artery infarction related to patent foramen ovale and right common iliac vein compression from an enlarged fibroid uterus.

© 2018 The Author(s)  
Published by S. Karger AG, Basel

## Case Presentation

The patient is a 46-year-old female with morbid obesity but otherwise no past medical history who presented to an outside hospital with right-sided weakness and inability to communicate. She suddenly collapsed at home and was found to be unable to speak or answer

questions. The patient was brought to a local emergency department where she was noted to be globally aphasic with right hemiparesis. Her initial NIHSS was 25. CT of the head showed no acute intracranial hemorrhage. She was given intravenous tissue plasminogen activator within 2 h of symptom onset and was subsequently transferred to our tertiary care facility for a possible endovascular intervention.

Upon arrival to our facility, the patient had full strength in all extremities but persistent global aphasia. Follow-up NIHSS was 11. CT angiogram of the head and neck at the time of her arrival to our institution revealed patency of all large intracranial and extracranial vessels.

MRI of the brain (Fig. 1) revealed restricted diffusion in the left middle cerebral artery territory. The patient had a normal complete blood count without evidence of anemia. A lipid panel test showed an LDL level of 132. Her HgbA1c level was 5.3. EKG and telemetry for 4 days showed no evidence of atrial fibrillation. Echocardiogram (transthoracic initially, then transesophageal) showed a patent foramen ovale with an associated atrial septal aneurysm and no left atrial appendage thrombus. Hypercoagulable workup was negative. She was not on hormonal contraceptive therapy. Venous Doppler ultrasounds of the lower and upper extremities were negative for acute deep vein thrombosis. MRV of the pelvis (Fig. 2a, b) revealed an enlarged fibroid uterus causing compression of the right common iliac vein.

The most likely explanation for her cerebral infarction was secondary to paradoxical emboli in the setting of right common iliac vein compression due to uterine fibroids. She was started on dual antiplatelet therapy with aspirin 81 mg/day, clopidogrel 75 mg/day, and atorvastatin 80 mg/day for stroke prevention.

## Discussion

Ischemic strokes in young adults are habitually cryptogenic. The differential diagnosis is broad, including small-vessel ischemic disease (e.g., CADASIL), large-vessel intracranial disease, large-vessel extracranial disease (e.g., cervical arterial dissection), cardioembolic (e.g., paradoxical embolization, rheumatic heart disease, etc.), and associated with an underlying hypercoagulable state (inherited vs. acquired). Hormonal therapy (e.g., hormonal contraception) is a known risk factor for stroke in young women [1]. Our patient was not on hormonal contraceptive therapy. Iron deficiency anemia has also been postulated to lead to a hypercoagulable state and stroke in young women with uterine fibroids [2]; however, our patient had no evidence of anemia during her hospitalization. The patient's main cardiovascular risk factor was morbid obesity. The most plausible explanation was paradoxical embolization related to right common iliac vein compression from an enlarged fibroid uterus.

Uterine tumors may compress iliac veins prompting venous thrombosis with subsequent pulmonary embolism [3]. Paradoxical embolization leading to cerebral infarction has been reported in young women with embolic strokes of undetermined source [4]. May-Thurner syndrome refers to left iliac vein compression by the right iliac artery and may result in deep venous thrombosis. May-Thurner syndrome may lead to paradoxical embolization and stroke in young women [5]. Uterine masses have also been reported to compress iliac veins and lead to paradoxical embolization and stroke [6]. Therefore, they should be considered as a potential source of paradoxical embolism in young women with stroke.

### Statement of Ethics

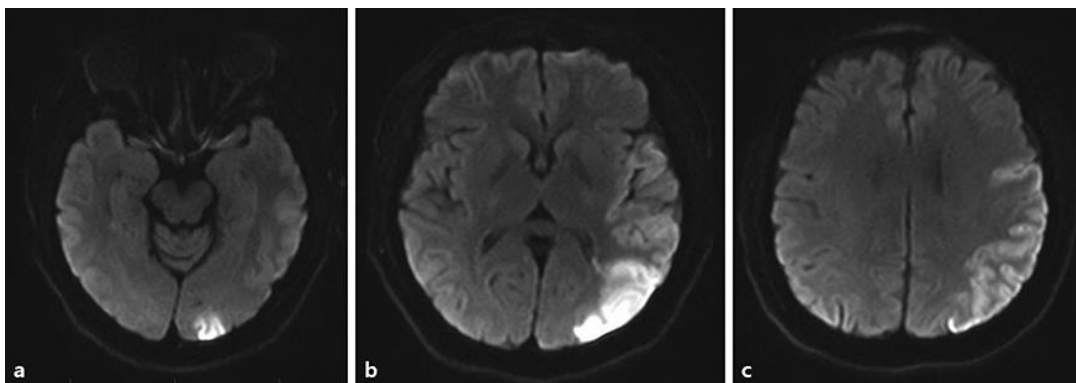
The authors have no ethical conflicts to disclose.

### Disclosure Statement

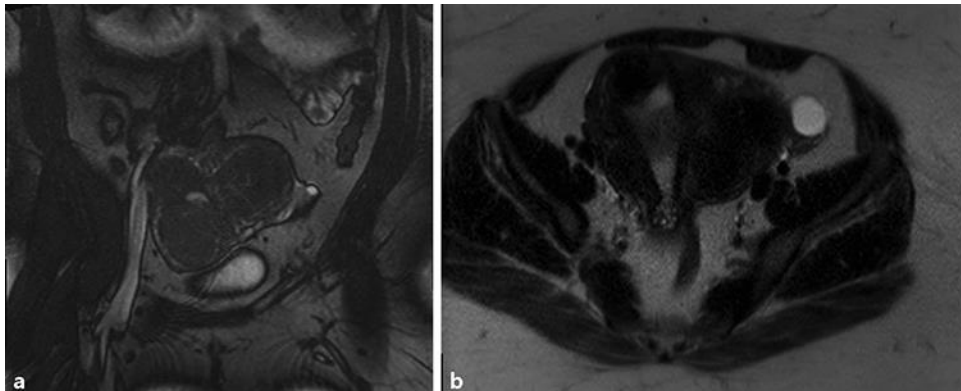
The authors declare no conflicts of interest.

### References

- 1 Lidegaard Ø, Løkkegaard E, Jensen A, Skovlund CW, Keiding N. Thrombotic stroke and myocardial infarction with hormonal contraception. *N Engl J Med*. 2012 Jun;366(24):2257–66.
- 2 Naito H, Naka H, Kanaya Y, Yamazaki Y, Tokinobu H. Two cases of acute ischemic stroke associated with iron deficiency anemia due to bleeding from uterine fibroids in middle-aged women. *Intern Med*. 2014;53(21):2533–7.
- 3 Fernandes FL, Dinardo CL, Terra-Filho M. Uterine myoma as a cause of iliac vein thrombosis and pulmonary embolism: common disease, rare complication. *Respirol Case Rep*. 2014 Dec;2(4):132–4.
- 4 Srivatsa A, Burdett J, Gill D. A 35-year-old woman with uterine fibroids and multiple embolic strokes. *Neurology*. 2005 Apr;64(8):1479–80.
- 5 Eswaradass PV, Qazi E, Menon BK. Embolic Stroke of Undetermined Source (ESUS) Unraveled: The May-Thurner Syndrome. *Can J Neurol Sci*. 2016 Sep;43(5):713–4.
- 6 Toru S, Murata T, Ohara M, Ishiguro T, Kobayashi T. Paradoxical cerebral embolism with patent foramen ovale and deep venous thrombosis caused by a massive myoma uteri. *Clin Neurol Neurosurg*. 2013 Jun;115(6):760–1.



**Fig. 1.** Diffusion-weighted MRI of the brain. **a–c** Areas of restricted diffusion (ADC not shown) in the left middle cerebral artery territory involving the left temporo-parietal region are shown.



**Fig. 2.** **a** Coronal view showing uterine fibroids and compression of the vena cava. **b** Axial view showing uterine fibroids and compression of the vena cava.