

Quiz: Pacemaker

Fragment of the ECG was recorded on the 12 leads
Holter monitor (Fig. 1).
Speed of the recording – 25 mm/s.

The permanent pacemaker in DDD mode was implanted
to patient.
There are 5 morphologies of PQRST seen on this ECG.

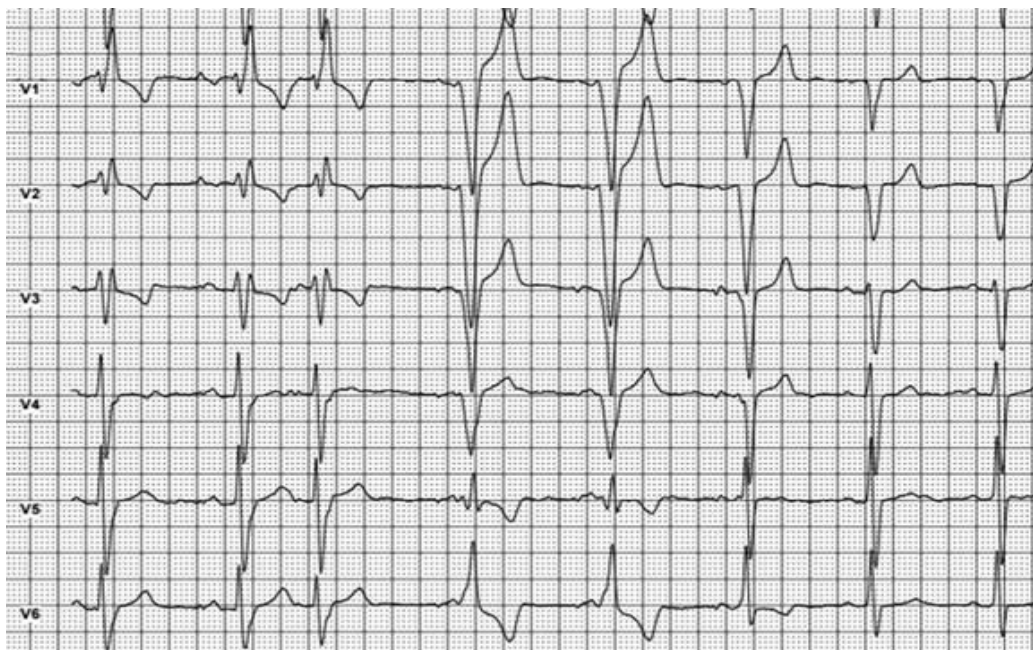
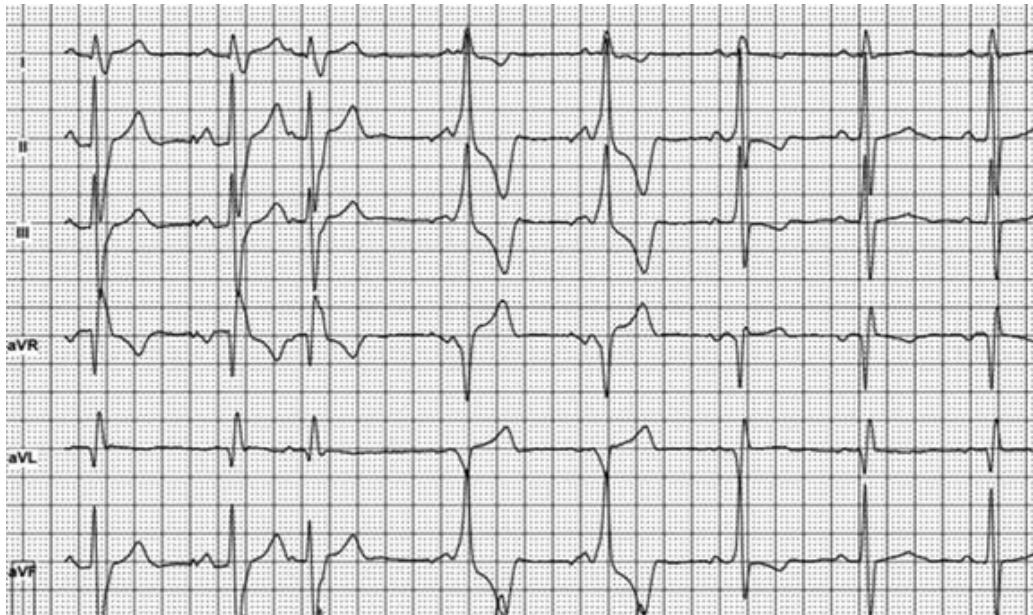


Figure 1. Multichannel Holter ECG recording
ECG - electrocardiogram

The correct description of the PQRST complexes (showed by order of numbers below) morphology on this ECG is:

A) 1,2 – atria: sinus rhythm, ventricles: paced rhythm;
3 – atria: premature beat, ventricles: paced rhythm;
4,5 – atria paced rhythm, ventricles: impulse conducted via AV node with LBBB;
6 – atria and ventricles – fusion beat;
7,8 – atria and ventricles – sinus rhythm with incomplete LBBB.

B) 1,2 – atria: paced rhythm, ventricles: impulse conducted via AV node with RBBB;
3 – atria: premature beat, ventricles: impulse conducted via AV node with RBBB;
4,5 – atria: paced rhythm, ventricles: impulse conducted via AV node with LBBB;
6 – atria and ventricles – fusion beat;
7,8 – atria and ventricles – sinus rhythm with incomplete LBBB.

C) 1,2 – atria: paced rhythm, ventricles: impulse conducted via AV node with RBBB;
3 – atria: premature beat, ventricles: impulse conducted via AV node with RBBB;

4,5 – atria sinus rhythm, ventricles: impulse conducted through accessory pathway;
6 – atria and ventricles – fusion beat;
7,8 – atria and ventricles – sinus rhythm with incomplete LBBB.

D) 1,2 – atria: paced rhythm, ventricles: impulse conducted via AV node with RBBB;
3 – atria: premature beat, ventricles: impulse conducted via AV node with RBBB;
4,5 – atria: paced rhythm, ventricles: paced rhythm;
6 – atria and ventricles – fusion beat;
7,8 – atria and ventricles – sinus rhythm with incomplete LBBB.

Mykhaylo Sorokivskyy
Lviv Regional Cardiology Center,
Danylo Halytsky Lviv National Medical University, Lviv,
Ukraine

Peer-review: Internal

Conflict of Interest: None to Declare

Authorship: M.S.

Acknowledgement and funding: None to declare