



Case report

Mucinous cystadenoma of the pancreas associated with pregnancy. Case report and review of the literature

Nicolae Berevoescu^{1,2}, Răzvan Scăunașu^{1,2}, Mihaela Berevoescu³, Alexandru Croitoru⁴

¹Colțea Clinical Hospital, Department of General Surgery, Bucharest, Romania

²Carol Davila University of Medicine and Pharmacy, Bucharest, Romania

³Craiova University of Medicine and Pharmacy, Dolj, Romania

⁴Colentina Clinical Hospital, Department of General Surgery, Bucharest, Romania

Abstract

Objective. We present a rare pathology with uncommon onset.

Background. Mucinous cystic pancreatic neoplasms (MCNs) are rare tumors, which generally occur in the fifth and sixth decades of women. Although some tumours are frankly malignant, all are in fact considered to be potentially malignant.

Case report. We present the case of a 30-year-old patient, with a 16/11 cm tumor located in the pancreas body, which was diagnosed 8 months after birth. The preoperative assessment of the pancreatic lesion suggested the diagnosis of mucosal cyst neoplasm, without being able to determine its benign or malignant nature. Central pancreatectomy was performed with a good postoperative evolution. Histopathologic result was represented by mucinous pancreatic chistadenoma. Two years after surgical intervention, the patient presented no signs of recurrence or pancreatic (exocrine or endocrine) secretion deficiency.

Conclusions. Preoperative imaging evaluation could be suggestive for mucinous cystic tumour, but this cannot specify however the nature of the tumor. The postpartum occurrence could establish a possible relationship between hormonal levels encountered during pregnancy and the development of this tumor, taking into considerations the ovarian-type stroma and the presence of hormone (estrogen and progesterone) receptors in this neoplasm. Central pancreatectomy without anastomosis preserves the functions of pancreas, and also decreases morbidity.

Keywords

: pancreas, mucinous cystadenoma, central pancreatectomy, pregnancy

Highlights

- ✓ Mucinous cystic neoplasms of pancreas are rare tumors, occur especially in women and raise problems in the diagnostic and therapeutic attitude, especially during pregnancy.
- ✓ Central pancreatectomy without anastomosis preserves the functions of the pancreas and decreases morbidity.

To cite this article: Berevoescu N, Scăunașu RV, Berevoescu M, Croitoru A. Mucinous cystadenoma of the pancreas associated with pregnancy. Case report and review of the literature. J Clin Invest Surg. 2018; 3(2): 88-94. DOI: 10.25083/2559.5555/3.2/88.94

Introduction

Mucinous cystic neoplasms (MCNs) of pancreas are rare tumors, occurring especially in women. Histologically, MCNs exhibit specialized ovarian stroma (ovarian stroma-like), lined with a columnar epithelium, which produces mucus. They may be benign, borderline or malignant tumors (1).

We describe one of these cystic pancreatic lesions, with uncommon onset, resolved through a particularly surgical intervention that conserved both exocrine and endocrine pancreatic functions. We also provide a review of the literature for presenting the state of knowledge on this type of tumors (2-4).

Case Report

A 30-year-old woman, eight months postpartum, presented in Colentina clinical hospital, Department of General Surgery, for pain in the upper abdomen, nausea and vomiting, associated with abdominal distension. Laboratory tests showed normal values for all constants, including several tumour markers (like CEA and CA 19.9). Abdominal ultrasonography and also computer tomography revealed a 16 cm-sized multilocular cystic lesion in the body of the pancreas, which was suggestive of a cystic mucinous neoplasm (Figures 1a, 1b).

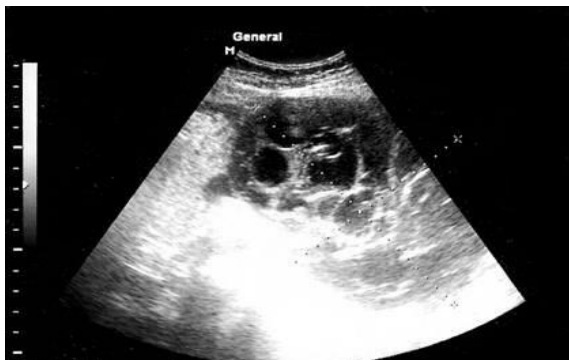

Figure 1a. Ultrasonography; multilocular pancreatic tumor formation.

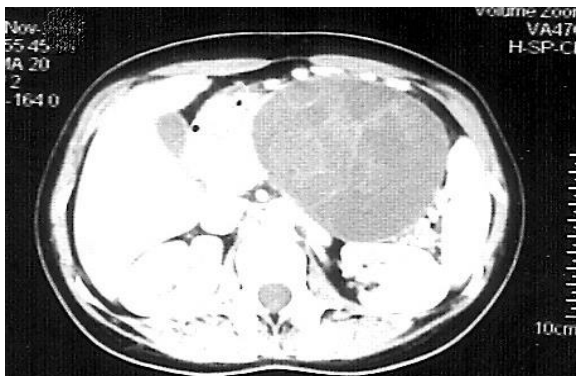


Figure 1b. Computer tomography with contrast substance. Cystic and multilocular tumor located to corporeocaudal pancreas level.

No retroperitoneal lymph nodes were identified and no involvement of other surrounding anatomic structures. Surgery was performed with central pancreatectomy without anastomosis (Figures 2a, 2b).

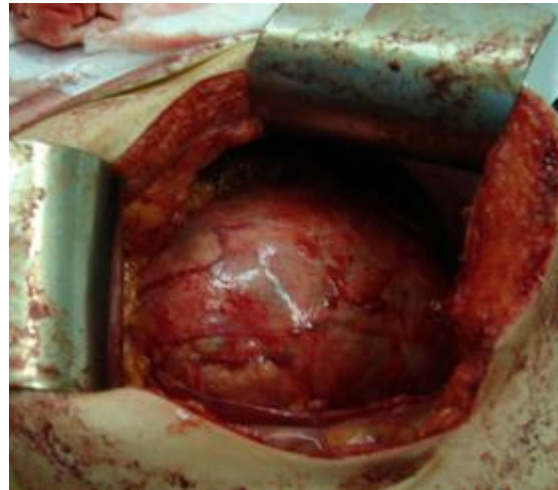


Figure 2a. Intraoperative imagery. Pancreatic corporeocaudal tumor.

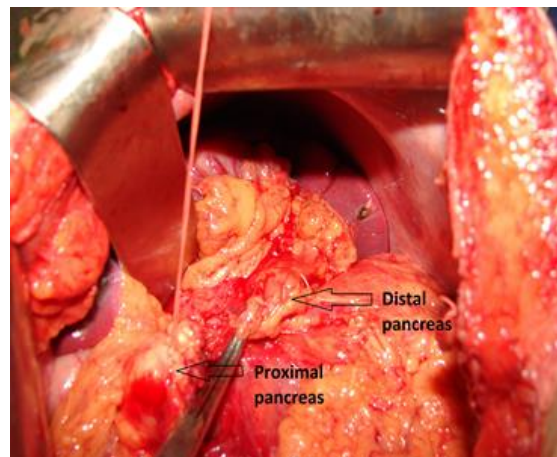


Figure 2b. Intraoperative imagery. Central pancreatectomy.

Results

The tumor size was 18,5/14/8,5 cm (Figure 3), presented a smooth, congestive surface, with no communication with the pancreatic ductal system. Cystic compartments, varying in dimension (1.5-6 cm), and including thick mucus that were found within the tumor.

Histopathological examination evidenced a cystic mass with papillary mucinous cystadenoma appearance, having an inner columnar epithelial layer and outer densely cellular ovarian-type stromal layer (Figures 4a, 4b).

The post-surgery evolution of the patient was good, being discharged 8 days after the surgical intervention. After 2 years, the patient presented a good general

condition, without signs of tumour relapse or alteration of pancreatic functions.

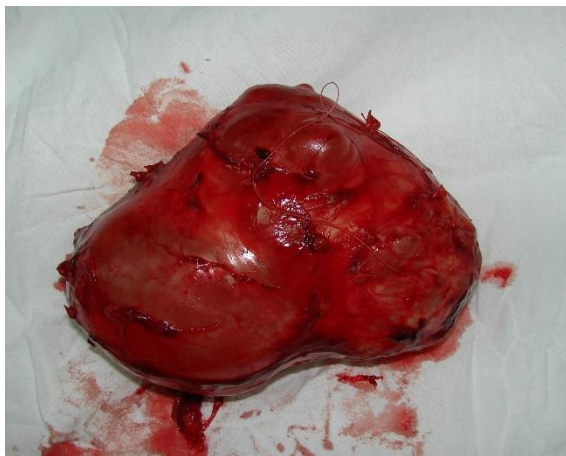


Figure 3. Pancreatic tumor, 18.5/ 14 cm

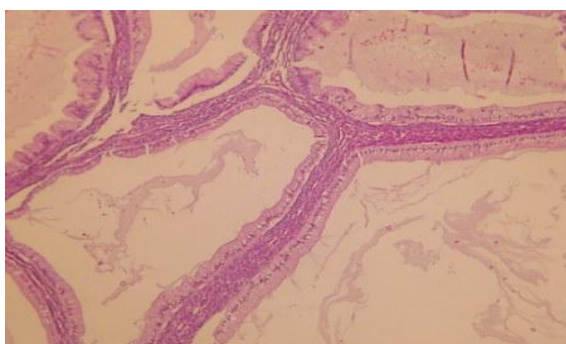


Figure 4a. Cystic wall with cylindrical mono-stratified epithelium, secretory by mucus; specialized stroma, ovarian type. HE x 200.

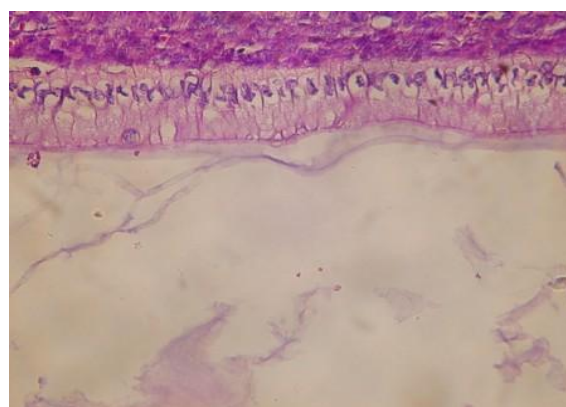


Figure 4b. Cystic wall with cylindrical mono-stratified epithelium, secretory by mucus; specialized stroma, ovarian type. HE x 400.

Discussions

Mucinous cystic neoplasms are rare pancreatic lesions, accounting for approximately 2-5% of all exocrine pancreatic tumors and 40-50% of primary cystic pancreatic neoplasms (5-7). It occurs almost exclusively in women (F: M = 9: 1), in the 5-th and 6-th decade of age (5-8 years) without a predisposition to a certain ethnic group (8). Associated with pregnancy, we

encountered 25 reported cases (9-13). They were diagnosed in women aged 21 to 41 years, with an average of 32 years.

Etiopathogenesis of MCNs is not fully elucidated (9-11). The possibility of stromal tissue provenance of MCNs in the ovary primordia is supported by the incidence of tumors, almost exclusively in women, of stromal tissue similar to ovarian cortex and the expression of estrogen and progesterone receptors detected in immuno-histochemistry (12, 13). It was hypothesized that, during pancreas embryogenesis, ectopic ovarian stromal tissue in the biliary or retroperitoneal stroma could release hormones and growth factors with the proliferation of neighboring epithelia and the formation of cystic tumors (14). In addition, the proximal relationship of the left gonadal primordial and dorsal pancreatic bud, from the 4-th and 5-th week of development, could explain the predilection for the pancreatic corporal-caudal region of MCNs (15).

MCNs are localized in the majority of cases at the corporeal-caudal level (14, 15), the head of the pancreas being very rarely interested, predominantly by mucinous cystadenocarcinomas (16, 17).

Macroscopically, MCNs are massive round-oval tumors, with a smooth surface, having a pseudo-capsule of variable thickness and with frequent calcification. The size of the tumors varies between 2 cm and 35 cm in the largest diameter, while those associated with pregnancy ranged from 5 cm to 22 cm, averaging 14.5 cm. The dimensions of MCN diagnosed during pregnancy or postpartum and their rapid increase, suggest a possible relationship between the hormonal status present during pregnancy and this type of tumor (18-20).

In addition, Shin-ichi Ikuta (11) found that MCNs may have a rapid growth rate during pregnancy. On a cross section, these cystic lesions are unilocular or multilocular, with cystic spaces that range from a few millimetres to a few centimetres in diameter, and the cystic content is a viscous, mucinous fluid, or a mucinous mixture of necrotic and hemorrhagic material (21-23). The internal surface of the unilocular tumors is usually smooth, glossy, while in the multilocular one, and often presents papillary protrusions and mural nodules. These latter features, multilocularity, intracystic papillary prominences, and mural nodules are commonly found in malignant cystic malignant neoplasms (14).

Although cases have been reported in the literature in which the tumor has been communicating with the pancreatic duct system (17), MCNs usually do not communicate with the pancreatic ducts (4).

Microscopically, MCNs have two distinct components: an internal epithelial layer and a peripheral, compact compartment formed of ovarian-like stroma cells (24).

The clinical manifestations of patients with MCNs is nonspecific. Small tumors (<3 cm) are asymptomatic, being incidentally discovered, while large cystic lesions manifest symptoms of tumor compression on neighboring anatomical structures, and are often accompanied by palpable abdominal tumor mass. Due to the MCNs topography of the pancreas, predominantly in the body and tail of the pancreas, obstructive jaundice is rarely encountered (3), but these tumors commonly associate diabetes mellitus (2).

Our patient noticed 5 months after birth that the abdomen did not diminish, and after 7-8 months postpartum it became clinically manifest, associating bloating, nausea, moderate pain and vomiting, symptoms caused by the rapid growth in size of the tumor formation.

Laboratory tests usually show elevated CEA and CA 19-9, and blood sugar levels. In our case, CEA and CA 19-9 values were within normal limits.

Abdominal X-ray may reveal the presence of calcifications arranged in a curved like fashion on the wall of the tumor, but they are far better highlighted on a CT. Barium examination show unspecific changes, when the cysts are large enough to produce extrinsic compression of the stomach or duodenum (7, 25). US and CT imaging usually identifies the unilocular or multilocular cystic tumor, sometimes heterogeneous, with presence of calcifications in the wall (26, 27).

Cytological and biochemical examination of the cyst content obtained by needle aspiration guided via US, CT or intraoperatively may orient the diagnosis towards MCNs. Suggestive for MCNs are elevated CEA, CA 19-9, TAG-72, CA 15-3 and low amylase values for cystic fluid analysis. Some reports show that CA 19-9 values greater than 50,000 U/ mL have a sensitivity of 75% and a specificity of 90% for MCNs (28). Also, CEA values in cystic fluid higher than 800 ng/ mL have a sensitivity of 42.9% and a 95.2% specificity for the diagnosis of MCNs (29).

In addition, very high levels of these tumor markers have been observed in the case of mucinosis of cystadenocarcinomas (30-32). These changes are useful

in diagnosis, especially in cases of tumors that develop during pregnancy.

The presence of varying dysplastic changes in some MCNs suggests that these tumors are in a continuous process of progression of neoplastic changes. Thus, mucinous cystadenomas, borderline tumors may evolve to invasive mucinous cystadenocarcinomas (33-35). For this reason, oligolocular MCNs must be clearly distinguished from pancreatic pseudo-cysts because cystic drainage is the optimal solution for patients with pseudocysts but is inadequate in the case of a mucosal cystadenoma (36-38).

In addition, genetic data support this MCNs progression model: the more advanced the mucinous tumor, the more genetic changes are encountered. For example, Bartsch et al. (39) reported that mutations in the K-ras gene are much more common in mucinous cystadenocarcinomas than in benign mucous cystic neoplasms. These data were also confirmed by Jimenez et al. (40), which has also shown that changes in p53 protein immunoreactivity occur early in the in-situ carcinoma stage. Based on these data, we believe that when an MCN is diagnosed during a pregnancy, we must take into account the malignant potential, the mass effects on the fetus and the risks arising from a resection intervention.

Neoplastic dissemination pathways in the case of mucinous cystadenocarcinomas are similar to those found in ductal adenocarcinomas. The first metastases are found in peripancreatic lymph nodes and in the liver (2), and the staging of MCNs is the same as in ductal adenocarcinomas. Regarding MCNs complications, these are mainly due to compression of tumors on neighboring anatomical structures.

Main treatment is surgical resection for all MCNs due to their malignant potential. In most cases, distal pancreatectomy is required with or without splenectomy. Central pancreatectomy is an option for mucinous cystadenomas and is advantageous because this procedure preserves the exocrine and endocrine functions of the pancreas. When the tumour is located cephalad, cephalic duodenopancreatectomy is required (41-43). A more limited resection such as enucleation, is not indicated because of the risk of pancreatic fistula formation and the possibility of remaining marginal tissue, neoplastic infiltration (44).

If the tumor is completely resected, the prognosis of MCNs is very good regardless of the degree of cellular atypia (45, 46). In the case of mucosal cystadenocarcinomas, the prognosis depends on the

degree of tumor invasion. Tumor recurrence correlates with tumor outgrowth of tumor walls and tumor infiltration of neighboring tissues (14).

The location, dimensions, macroscopic appearance of the tumor and immunoreactivity of the p53 protein are of no prognostic importance. However, aneuploidy that is rarely encountered in MCNs, in some mucous cystadenocarcinomas, gives a poor prognosis (47, 48).

The 5-year survival rate for patients with MCNs is excellent: >95% for benign or borderline MCNs, 50-75% for invasive mucinous cystadenocarcinomas, totally resected (49). Some studies have also shown that the 10-year survival rate of patients with invasive mucinous cystadenocarcinomas, is approximately 50% (50, 51).

Conclusions

MCNs raise problems in the diagnostic and therapeutic attitude, especially when they are discovered during pregnancy or postpartum. Its onset in the postpartum period can indicate the relationship between hormone levels during pregnancy and the development of this tumor. Central pancreatectomy without anastomosis preserves the functions of the pancreas and decreases morbidity.

Conflict of interest disclosure

There are no known conflicts of interest in the publication of this article, and there was no financial support that could have influenced the outcomes. The manuscript was read and approved by all authors.

Compliance with ethical standards

Any aspect of the work covered in this manuscript that has involved human patients has been conducted with the ethical approval of all relevant bodies and that such approvals are acknowledged within the manuscript.

References

1. Klöppel G, Solcia E, Longnecker DS, et al. World Health Organization International Histological Classification of Tumours. Histological Typing of Tumours of the Exocrine Pancreas (ed 2). Berlin, Springer-Verlag, 1996.
2. Solcia E, Capella C, Klöppel G. Atlas of tumor pathology. Tumors of the pancreas. Washington, DC, AFIP, 1997.
3. Thompson LD, Becker RC, Przygodzki RM, Adair CF, Heffess CS. Mucinous cystic neoplasm (mucinous cystadenocarcinoma of low-grade malignant potential) of the pancreas: a clinicopathologic study of 130 cases. *Am J Surg Pathol.* 1999; 23(1): 1-16. PMID: 9888699
4. Naveed S, Qari H, Banday T, Altaf A, Para M. Mucinous Cystic Neoplasms of Pancreas. *Gastroenterology Res.* 2014; 7(2): 44-50. PMID: 27785269, DOI: 10.14740/gr600e
5. Wilentz RE, Albores-Saavedra J, Hruban RH. Mucinous cystic neoplasms of the pancreas. *Semin Diagn Pathol.* 2000; 17(1): 31-42. PMID: 10721805
6. Grogan JR, Saeian K, Taylor AJ, Quiroz F, Demeure MJ, Komorowski RA. Making sense of mucin-producing pancreatic tumors. *AJR.* 2001; 176(4): 921-9. PMID: 11264079, DOI: 10.2214/ajr.176.4.1760921
7. Buetow PC, Rao P, Thompson LD. From the Archives of the AFIP. Mucinous cystic neoplasms of the pancreas: radiologic-pathologic correlation. *RadioGraphics.* 1998; 18(2): 433-49. PMID: 9536488
DOI: 10.1148/radiographics.18.2.9536488
8. Fallahzadeh MK, Zibari GB, Wellman G, Abdehou ST, Shokouh-Amiri H. Mucinous cystic neoplasm of pancreas in a male patient: a case report and review of the literature. *J La State Med Soc.* 2014; 166(2): 67-9. PMID: 25075598
9. Takashima S, Wato M, Inaba T, et al. A case of pancreatic mucinous cystic neoplasm that enlarged during pregnancy and was resected after childbirth. *Nihon Shokakibyō Gakkai Zasshi.* 2014; 111(9): 1789-97. PMID: 25195964
10. Shirakawa S, Matsumoto I, Nakayama S, et al. Mucinous cystic neoplasm of the pancreas associated with pregnancy: report of two cases. *Nihon Shokakibyō Gakkai Zasshi.* 2010; 107(11): 1828-34. PMID: 21071901
11. Ikuta S, Aihara T, Yasui C, et al. Large mucinous cystic neoplasm of the pancreas associated with pregnancy. *World J Gastroenterol.* 2008; 14(47): 7252-5. DOI: 10.3748/wjg.14.7252.
12. Kosumi K, Takamori H, Hashimoto D, et al. Mucinous cystic neoplasm of the pancreas activated during pregnancy. *Surg Case Rep.* 2015; 1(1): 13. DOI: 10.1186/s40792-014-0012-2.
13. Kleeff J, Holzapfel K, Steiger K, Esposito I. Progression of a cystic pancreatic lesion during pregnancy. *JOP (Online)* 2015; 16(4): 394-6.

14. Zamboni G, Scarpa A, Bogina G, et al. Mucinous cystic tumors of the pancreas: clinicopathological features, prognosis, and relationship to other mucinous cystic tumors. *Am J Surg Pathol.* 1999; 23(4): 410-22. PMID: 10199470
15. Pantea-Stoian A, Ditu G, Diculescu M, Manuc M, Suceveanu I, Manuc D, Diaconu C, Suceveanu AP, Nitipir C, Hainarosie R, Poiana C, Serafinceanu C. Pancreatogenic type 3C diabetes. *J Mind Med Sci.* 2018; 5(2): 270-277. DOI: 10.22543/7674.52.P270277
16. Compagno J, Oertel JE. Mucinous cystic neoplasms of the pancreas with overt and latent malignancy (cystadenocarcinoma and cystadenoma). A clinicopathologic study of 41 cases. *Am J Clin Pathol.* 1978; 69(6): 573-80. PMID: 665578
17. Yamada M, Kozuka S, Yamano K, Nakazawa S, Naitoh Y, Tsukamoto Y. Mucin-producing tumor of the pancreas. *Cancer.* 1991; 68(1): 159-68. PMID: 2049738
18. Ganepola GA, Gritsman AY, Asimakopulos N, Yiengpruksawan A. Are pancreatic tumors hormone dependent? A case report of unusual, rapidly growing pancreatic tumor during pregnancy, its possible relationship to female sex hormones, and review of the literature. *Am Surg.* 1999; 65(2): 105-11. PMID: 9926740
19. Herring AA, Graubard MB, Gan SI, Schwaitzberg SD. Mucinous cystadenocarcinoma of the pancreas during pregnancy. *Pancreas.* 2007; 34(4): 470-3. DOI: 10.1097/mpa.0b013e31803799d8.
20. Ishikawa K, Hirashita T, Kinoshita H, Kitano M, Matsuo S, Matsumata T, et al. Large mucinous cystadenoma of the pancreas during pregnancy: report of a case. *Surg Today.* 2007; 37(11): 1013-7. DOI: 10.1007/s00595-007-3500-1.
21. Sarr MG, Carpenter HA, Prabhakar L, et al. Clinical and pathologic correlation of 84 mucinous cystic neoplasms of the pancreas. *Ann Surg.* 2000; 231(2): 205-12. PMID: 10674612
22. Izumo A, Yamaguchi K, Eguchi T, et al. Mucinous cystic tumor of the pancreas: immunohistochemical assessment of "ovarian-type stroma". *Oncol Rep.* 2003; 10(3): 515-25. PMID: 12684617
23. Reddy RP, Smyrk TC, Zapiach M, et al. Pancreatic mucinous cystic neoplasm defined by ovarian stroma: demographics, clinical features, and prevalence of cancer. *Clin Gastroenterol Hepatol.* 2004; 2(11): 1026-31. PMID: 15551256
24. Gil E, Choi SH, Choi DW, Heo JS, Kim MJ. Mucinous cystic neoplasms of the pancreas with ovarian stroma. *ANZ J Surg.* 2013; 83(12): 985-90.
25. Lima JE, Javitt MC, Mathur SC. Mucinous cystic neoplasm of the pancreas. *RadioGraphics.* 1999; 19(3): 807-11. PMID: 10336204, DOI: 10.1148/radiographics.19.3.g99ma15807
26. Scott J, Martin I, Redhead D, Hammond P, Garden OJ. Mucinous cystic neoplasms of the pancreas: imaging features and diagnostic difficulties. *Clin Radiol.* 2000; 55(3): 187-92. PMID: 10708611, DOI: 10.1053/crad.1999.0341
27. Nitecki SS, Sarr MG, Colby TV, van Heerden JA. Long-term survival after resection for ductal adenocarcinoma of the pancreas: is it really improving? *Ann Surg.* 1995; 221: 59-66. PMID: 7826162
28. Hammel P, Levy P, Voitot H, Levy M, Vilgrain V, Zins M, Flejou JF, Molas G, Ruszniewski P, Bernades P. Preoperative cyst fluid analysis is useful for the differential diagnosis of cystic lesions of the pancreas. *Gastroenterology.* 1995; 108(4): 1230-5. PMID: 7535275
29. Attasaranya S, Pais S, LeBlanc J, McHenry L, Sherman S, DeWitt JM. Endoscopic ultrasound-guided fine needle aspiration and cyst fluid analysis for pancreatic cysts. *JOP.* 2007; 8(5): 553-63. PMID: 17873459
30. Lewandrowski KB, Southern JF, Pins MR, et al. Cyst fluid analysis in the differential diagnosis of pancreatic cysts. A comparison of pseudocysts, serous cystadenomas, mucinous cystic neoplasms and mucinous cystadenocarcinoma. *Ann Surg.* 1993; 217(1): 41-7. PMID: 8424699
31. Sperti C, Pasquali C, Pedrazzoli S, et al. Expression of mucin-like carcinoma-associated antigen in the cyst fluid differentiates mucinous from nonmucinous pancreatic cysts. *Am J Gastroenterol.* 1997; 92(4): 672-5. PMID: 9128321
32. Fukushima N, Zamboni G. Mucinous cystic neoplasms of the pancreas: update on the surgical pathology and molecular genetics. *Semin Diagn Pathol.* 2014; 31(6): 467-74. PMID: 25441310
33. Hruban RH, Wilentz RE. The pancreas, in Weidner N, Cote RJ, Suster S, et al (eds): *Modern Surgical Pathology.* Philadelphia, PA: Saunders, 2000.
34. Hyde GL, Davis JB, McMillin RD, et al. Mucinous cystic neoplasm of the pancreas with latent malignancy. *Am Surg.* 1984; 50(4): 225-9. PMID: 6712017

35. Anila KR, Mathew AP, Mathews A, Jayasree K. Mucinous cystic neoplasm of pancreas with intermediate-grade dysplasia. *Int J Surg Pathol.* 2014; 22(8): 707-8. PMID: 25305219, DOI: 10.1177/1066896914553665
36. Jang KT, Park SM, Basturk O, Bagci P, Bandyopadhyay S, Stelow EB, Walters DM, Choi DW, Choi SH, Heo JS, Sarmiento JM, Reid MD, Adsay V. Clinicopathologic characteristics of 29 invasive carcinomas arising in 178 pancreatic mucinous cystic neoplasms with ovarian-type stroma: implications for management and prognosis. *Am J Surg Pathol.* 2015; 39(2): 179-87. DOI: 10.1097/PAS.0000000000000357
37. Pan ZG, Wang B. Anaplastic carcinoma of the pancreas associated with a mucinous cystic adenocarcinoma. A case report and review of the literature. *JOP.* 2007; 8(6): 775-82. PMID: 17993730
38. Zamboni G, Bonetti F, Castelli P, et al. Mucinous cystic tumor of the pancreas recurring after 11 years as cystadenocarcinoma with foci of choriocarcinoma and osteoclast-like giant cell tumor. *Surg Pathol.* 1994; 5: 253-62.
39. Bartsch D, Bastian D, Barth P, et al. K-ras oncogene mutations indicate malignancy in cystic tumors of the pancreas. *Ann Surg.* 1998; 228(1): 79-86. PMID: 9671070
40. Jimenez RE, Warshaw AL, Z'graggen K, et al. Sequential accumulation of k-ras mutations and p53 overexpression in the progression of the pancreatic mucinous cystic neoplasms to malignancy. *Ann Surg.* 1999; 230(4): 501-11. PMID: 10522720
41. Cuschieri A, Jakimowicz JJ. Laparoscopic pancreatic resections. *Semin Laparosc Surg.* 1998; 5(3): 168-79. PMID: 9787203
42. Hackert T, Michalski CW, Büchler MW. Mucinous Cystic Neoplasms of the Pancreas: A Surgical Disease. *JAMA Surg.* 2017; 152(1): 26. PMID: 27760264, DOI: 10.1001/jamasurg.2016.3596
43. Testini M, Gurrado A, Lissidini G, Venezia P, Greco L, Piccinni G. Management of mucinous cystic neoplasms of the pancreas. *World J Gastroenterol.* 2010; 16(45): 5682-92. PMID: 21128317
44. Talamini MA, Moesinger R, Yeo CJ, et al. Cystadenomas of the pancreas. Is enucleation an adequate operation? *Ann Surg.* 1998; 227(6): 896-903. PMID: 9637553
45. Santini D, Campione O, Salerno A, et al. Intraductal papillary-mucinous neoplasm of the pancreas. A clinicopathologic entity. *Arch Pathol Lab Med.* 1995; 119(3): 209-13. PMID: 7887773
46. Didolkar M, Malhotra Y, Holyoke E, Elias E. Cystadenoma of the pancreas. *Surg Gynec Obstet.* 1975; 140(6): 925-8. PMID: 1129684
47. Southern JF, Warshaw AL, Lewandrowski K. DNA ploidy analysis of mucinous cystic tumors of the pancreas. Correlation of aneuploidy with malignancy and poor prognosis. *Cancer.* 1996; 77(1): 58-62. PMID: 8630940
48. Flejou JF, Boulange B, Bernandes P, Belghiti J, Henin D. p53 protein expression and DNA ploidy in cystic tumors of the pancreas. *Pancreas.* 1996; 13(3): 247-52. PMID: 8884845
49. Fernandez-del Castillo C, Warshaw AL. Cystic tumors of the pancreas. *Surg Clin North Am.* 1995; 75(5): 1001-16. PMID: 7660245
50. Wilentz RE, Albores-Saavedra J, Zahurak M, et al. Pathologic examination accurately predicts prognosis in mucinous cystic neoplasms of the pancreas. *Am J Surg Pathol.* 1999; 23(11): 1320-7.
51. Wilentz RE, Hruban RH, Albores-Saavedra J. Prognosis of invasive mucinous cystadenocarcinomas of the pancreas: a study of over 29,000 patients from SEER database. *Mod Pathol.* 1999; 12: 169A