

## Endoscopic thyroidectomy: why we need a transoral approach

**Antonina Catalfamo, Fausto Famà, Francesca Pia Pergolizzi, Maribel Cristina Sanchez Cruz, Giorgio De Pasquale, Sam Mahli, Gianlorenzo Dionigi**

**Division for Endocrine and Minimally Invasive Surgery, Department of Human Pathology in Adulthood and Childhood "G. Barresi", University Hospital G. Martino, University of Messina, Via C. Valeria 1, 98125, Messina, Italy**

### Abstract

Transoral thyroidectomy (TT) is a feasible novel surgical procedure that does not need visible incisions, a truly scar-free surgery. Inclusion criteria are (a) patients who have a ultrasonographically (US) estimated thyroid diameter not larger than 10 cm, (b) US estimated gland volume  $\leq 45$  mL, (c) nodule size  $\leq 50$  mm, (d) a benign tumor, such as a thyroid cyst, single-nodular goiter, or multinodular goiter, (e) follicular neoplasm, (f) papillary microcarcinoma without evidence of metastasis. The procedure is carried out through three-port technique placed at the oral vestibule, one 10-mm port for 30° endoscope and two additional 5-mm ports for dissecting and coagulating instruments. CO<sub>2</sub> insufflation pressure is set at 6 mmHg. An anterior cervical subplatysmal space is created from the oral vestibule down to the sternal notch, laterally to the sternocleidomuscles. TT is done fully endoscopically using conventional endoscopic instruments. TT represents probably the best scarless approach to the thyroid due to the short distance between the thyroid and the incisions, respecting the surgical planes.

**KEYWORDS:** transoral thyroidectomy – endoscopic thyroidectomy – robotic thyroidectomy - natural orifice transluminal endoscopic surgery - NOTES

**Introducing Member:** F. Trimarchi

**Corresponding Author:** Gianlorenzo Dionigi, [gdionigi@unime.it](mailto:gdionigi@unime.it), <https://orcid.org/0000-0003-0864-6087>

### Introduction

Technologies have been proposed and applied in thyroid surgery (1). Intraoperative neural monitoring (IONM) to prevent laryngeal nerve paralysis, early measurement of iPTH to avert symptomatic hypocalcaemia, new devices for hemostasis and dissection to better control bleeding, furthermore genetic screening with improvement of survival rate (2-6). The impact of these technologies on quality of thyroid surgery is remarkable (1). Likewise endoscopic thyroid procedures gradually lead to a surgical progress improving the perioperative life quality: cervical minimally invasive mini-incision and video-assisted techniques ameliorated the postoperative course, extracervical access achieved excellent cosmesis (7-14).

Endoscopic thyroid surgery is rapidly becoming a common issue in a high volume endocrine

surgery practice (8-10). In some Centers, endoscopic thyroid procedures represent almost 90% of all thyroidectomies (8-10). Improving cosmetic outcomes have been a direct and logical derivative of technical advances, minimally invasive and endoscopic approaches (7-14). Surgeons while gain experience, focus and emphasize on cosmetic outcomes introducing in their routine practice endoscopic procedures (7-14). The prevalence of thyroid disease is significantly higher in young woman than man . Women have an increase societal focus on appearance and cosmetic outcomes (15). Increase societal focus on woman in work is also rapidly demanding (15). When aesthetically pleasing endoscopic thyroidectomy can be performed without compromising surgical goals and patient safety, cosmetics in 2016 should be a factor in the presurgical planning and discussion with patients.

### **Review of the literature**

The total number of endoscopic thyroid techniques published, including some variations, account for about 20 different approaches (7-14). The variety of surgical endoscopic approaches to the gland may imply that the ideal technique as well the best instruments have not yet emerged, or that endoscopic thyroidectomy is merely a “transition state” between open surgery and truly noninvasive surgery, i.e. surgery without an incision through a natural orifices such as the mouth (16, 17). Neither thyroid endoscopic procedure is unequivocally better than the other and no large prospective randomized trials comparing the outcomes of different endoscopic procedures demonstrate a high level of evidence and grade of recommendation (16, 17).

Natural orifice transluminal endoscopic surgery (NOTES) is an surgical technique whereby "scarless" operations can be performed with an endoscope passed through a natural orifice as the mouth, urethra, anus, etc., then through an internal incision in the stomach, vagina, bladder or colon, thus avoiding any external visible incisions and scars (16-18).

Endoscopic thyroid surgery has been proposed and applied with NOTES by transoral endoscopic thyroidectomy with a sublingual, or via a transtracheal approach in order to achieve a scarless advantage since 2008 (19-25). However these techniques cause severe tissue damage, high complication, and conversion rates to open surgery and surgical difficulties due to limitation of movement (19-25). These were abandoned.

Between 2013 and 2015, a new NOTES procedure for a truly scar-free surgery with a vestibular approach has been successfully introduced for thyroid surgery by Anuwong from Thailand (26-34). Authors presented a standardized technique in porcine and cadaver models first (26-34). Using these models, the procedure and surgical view was improved, validated and

then safely introduced in human subjects using common endoscopic instruments or robot (26-34). The procedure is carried out under general anesthesia through three-port technique placed at the oral vestibule, one 10-mm port for 30° endoscope and two additional 5-mm ports for dissecting and coagulating instruments (26-34). CO<sub>2</sub> insufflation pressure is set at 6 mmHg. An anterior cervical subplatysmal space is created from the oral vestibule down to the sternal notch, laterally to the sternocleidomuscles (26-34). Thyroidectomy is done fully endoscopically or robotically using conventional endoscopic instruments. No dressing is required. Oral antibiotics and mouthwash 3 times per day are prescribed for 5 days. Patients are mobilized from bed at +4hrs postoperatively. All patients start an oral diet on day 0 postoperatively, evening. Patients can take a shower and man shave the evening. Patients can sunbathe on the following weekend (26-34). Discharge from hospital are dictated by the common rules of the thyroid surgery, after careful evaluation by the surgeon, endocrinological and anesthesiological specialist, serum calcium dosage and after neck, mouth and laryngoscopy evaluation. TT is currently multi-istitutional. Transoral thyroidectomy is being embraced by several universities internationally (26-34). Transoral thyroidectomy was proposed, introduced and applied in different Countries as in Thailand, South Korea, India, China, Singapore, Taiwan, USA, Mexico, Japan, Hongkong, Philippines, Indonesia, Ecuador and Italy. The general impression is that TT, will be accepted as the newest frontier in minimally invasive surgery (34).

### **Inclusion criteria**

TT follows a precise inclusion criteria, i.e. (a) patients who had a ultrasonographically (US) estimated thyroid gland diameter not larger than 10 cm, (b) US estimated thyroid volume  $\leq 45$  mL, (c) US estimated main nodule size  $\leq 50$  mm, (d) a benign tumor, such as a thyroid cyst, single-nodular goiter, or multinodular goiter, (e) follicular neoplasm, (f) papillary microcarcinoma of the thyroid without evidence of metastasis (26-34). Exclusion criteria comprise patients who (a) are unfit for surgery, (b) cannot tolerate general anesthesia, (c) previous radiation in the area of the head, neck and/or upper mediastinum, (d) had previous neck surgery, (e) recurrent goitre, (f) thyroid volume  $>45$  mL, (g) dominant nodule size  $>50$ mm, (h) evidence of lymph node or distant metastases, (i) tracheal/esophageal invasion, (l) recurrent laryngeal nerve palsy (m) biochemical or ultrasound signs of hyperthyroidism and (n) oral abscesses (26-34).

### **Transoral approach**

This new approach has peculiar features (Table 1).

First observation is relative to the definition of minimally invasive in endoscopic thyroid surgery. This may be defined by the length, location, number of incision, by the area needed for dissection, the minimization of cervical exploration and trauma, the use or not of a videoscope, cosmesis, locoregional anesthesia, pain, duration of procedure or by an outpatient care setting (16-18). The terms “minimal access” and “minimally invasive” are not synonymous (20-27). The techniques proposed by Miccoli and Henry are minimally invasive because the cervical access is direct, with less dissection area (16-18).

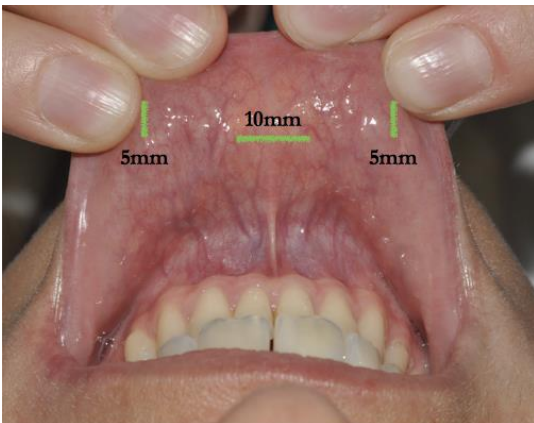
**Table 1. Characteristics of Transoral Thyroidectomy**

<b>-Cosmesis, truly scar-free surgery</b>
<b>-Minimize surgical trauma, respects surgical planes, avoids a distant surgical access and excessive tissue dissection</b>
<b>-Central-median approach, with bilateral exposure of the gland and central compartment</b>
<b>-Technique is consistent and now reproducible in many Countries</b>
<b>-Both conventional endoscopic and robotics</b>

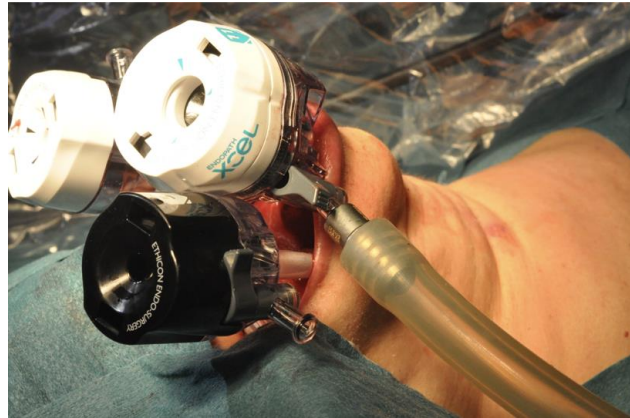
Extracervical totally endoscopic procedures may be not minimally invasive as the area of surgical dissection is larger (trocar are away from neck and this require a vast exploration area) (16-18). Extracervical endoscopic procedures have various advantages and disadvantages, although none of them completely avoids a cutaneous scar or scars in the neck and chest region. Furthermore, some of these approaches are often associated with more postoperative pain, given the additional tissue dissection and retraction necessary to access the gland from a distant cutaneous entrance site. TT is a minimally invasive procedure as is a near length to the thyroid gland guaranteeing few dissection (26-34). The route, the way, the approach to the anterior neck is close, shorter than that from the axilla, or breast, or retroauricular (26-34).

Traditional open surgery involves a low transverse cervical incision, at least 4 cm long, that result in visible scar. TT in comparison to both conventional and endoscopic thyroidectomy has the advantage of no visible scar (26-34). And as a consequence, no physical or physiological complication related to scar as Keloid, hypertrophic scar, contracture formation, dehiscence (26-34). Moreover, given the predominance of thyroid surgery in female patients, often with benign histology, effort should be given to minimize the invasiveness of surgery and improve cosmesis. The main advantage for the patients in choosing TT is the excellent cosmetic result with no scarring and emotional benefit. Cosmetics concerns and request are frequently demanded from young woman and man. Presently, the minimally invasive aspect and cosmetic advantage seem to be an important factor for the patients. Considering the prevalence of thyroid disease is higher in young women and men, this scarless endoscopic thyroidectomy would be highly beneficial for these patients (26-34).

**Fig.1. Inferior vestibular incisions**



**Fig.2. Intraoperative view**



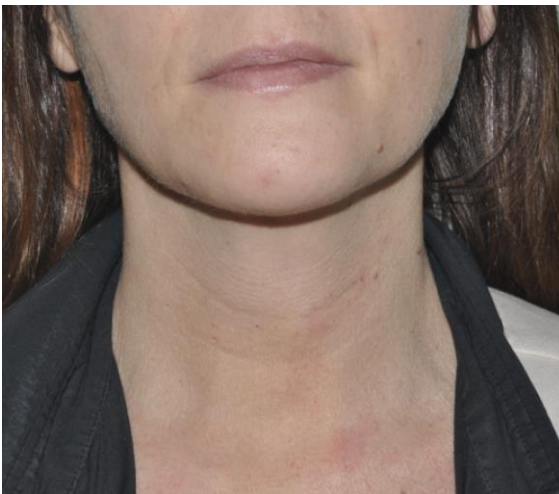The transoral approach respects surgical planes while minimizing surgical trauma, avoids a distant surgical access and excessive tissue dissection, and avoids scar. The transoral approach offers a remote access technique to make the surgery virtually scarless, and yet the area of dissection between the oral cavity and the neck only minimally adds to the standard surgical bed. Anatomical landmarks are standard reference points in the neck such as protuberances or lines (26-34). Detailed anatomic references are relevant to the surgeon for starting a new technique (26-34). The safety and reproducibility of reaching and resecting the thyroid gland by a TT approach was precisely defined with anatomical landmarks, the plane and route of dissection, the sequence of surgical steps (26-34). TT went through long process of study, evaluation and approval, before in animals, than in cadavers and in last 2 years in humans (26-34). Animal and cadaver studies have shown that TT can be performed in a safe and successful way (26-34). Authors did report pervasively endoscopic cervical anatomic references to perform safely this new challenging technique in the future (26-34).

TT is through a central-median approach (Fig. 1), thus it provides bilateral exposure of the gland and bilateral procedure can be performed without additional incisions (26-34). In published series, there were about 75% total thyroidectomy (26-34). The transoral approach offers superb visibility of the central compartment of the neck down to the level of the innominate artery below the sternal notch. In contrast to other endoscopic and robotic-assisted approaches that have a lateral entry point, the transoral approach provides a midline exposure and equivalent access to both the right and left thyroid lobes and central compartments. This is a considerable advantage over the transaxillary technique, in which approaching the contralateral thyroid lobe or paratracheal nodal basin may be quite challenging. We believe that the view from the transoral approach (Fig. 2) is more akin to that offered by the traditional open approach and might diminish the learning curve, since this approach is well known by

experienced thyroid surgeons. It provides a more familiar perspective for identifying the recurrent laryngeal nerve and provides excellent exposure, allowing a complete central neck dissection. We believe the exposure offered by this approach to the central neck is superior to that of the transaxillary approach; specifically to the deep aspects of level VI inferior to the gland and clavicle to reach the borders of a true paratracheal dissection, as we confirmed in our cadaver. Thus, transoral robotic-assisted thyroidectomy may provide the safest access to both paratracheal beds, permitting more comprehensive treatment of the posterolateral suspensory ligament of Berry, the recurrent laryngeal nerve, and any paratracheal lymphatics.

Although robotic surgery is now well established in neck surgery, it is not yet performed on a larger scale because of difficulties in the economy and viability of these procedures in most centers around the world. Thus, the technology is currently available for a limited number of selected cases..

**Fig. 3. Cosmetic outcome of a transoral thyroidectomy**



Considering the economic reality of most countries, the alternative use of TT seems to be a more feasible option. TT can be carried with or without the aid of the robot, with only the use of conventional endoscopic instruments. In conclusion, this is an opinion report of our ongoing experience on TT. We will continue to carefully apply this technique in selected patients (Fig.3). TT should only be performed in highly specialized centers for endocrine and endoscopic surgery. Current and future trends in research will focus on refinement or developing dedicated surgical instruments.

## References

1. Dralle, H., (2006) Impact of modern technologies on quality of thyroid surgery. *Langenbecks Arch Surg* 391:1-3.
2. Dionigi, G., Barczynski, M., Chiang, F.Y., Dralle, H., Duran-Poveda, M., Iacobone, M., Lombardi, C.P., Materazzi, G., Mihai, R., Randolph, G.W., Sitges-Serra, A., (2010) Why monitor the recurrent laryngeal nerve in thyroid surgery? *J Endocrinol Invest.* 33:819-22.
3. Souberbielle, J.C., Brazier, F., Piketty, M.L., Cormier, C., Minisola, S., Cavalier, E., (2017) How the reference values for serum parathyroid hormone concentration are (or should be) established? *J Endocrinol Invest.* 40:241-256. doi: 10.1007/s40618-016-0553-
4. Pacella, C.M., Papini, E., (2013) Image-guided percutaneous ablation therapies for local recurrences of thyroid tumors. *J Endocrinol Invest.* Jan;36:61-70. Review.

5. Miccoli, P., Materazzi, G., Baggiani, A., Miccoli, M., (2011) Mini-invasive video-assisted surgery of the thyroid and parathyroid glands: a 2011 update. *J Endocrinol Invest.* 34: 473-80. doi: 10.3275/7617.
6. Cassio, A., Corbetta, C., Antonozzi, I., Calaciura, F., Caruso, U., Cesaretti, G., Gastaldi, R., Medda, E., Mosca, F., Pasquini, E., Salerno, M.C., Stoppioni, V., Tonacchera, M., Weber, G., Olivieri, A., Italian Society for Pediatric Endocrinology and Diabetology.; Italian Society for the Study of Metabolic Diseases and Neonatal Screening.; Italian National Institute of Health.; Italian National Coordinating Group for Congenital Hypothyroidism.; Italian Thyroid Association.; Italian Society of Pediatrics.; Italian Society of Neonatology.; Italian Society of Endocrinology.; Associazione Medici Endocrinologi.. The Italian screening program for primary congenital hypothyroidism: actions to improve screening, diagnosis, follow-up, and surveillance.( 2013) *J Endocrinol Invest.* ;36(3):195-203. doi: 10.3275/8849. Review.
7. Miccoli, P., Berti, P., Materazzi, G., Minuto, M., Barellini, L., (2004) Minimally invasive video-assisted thyroidectomy: five years of experience. *J Am Coll Surg* 199(2):243-8
8. Tan, C.T., Cheah, W.K., Delbridge, L., (2008) "Scarless" (in the Neck) endoscopic thyroidectomy (SET): an evidence-based review of published techniques. *World J Surg* 32(7):1349-57.
9. Yeung, G.H., (2002) Endoscopic thyroid surgery today: a diversity of surgical strategies. *Thyroid* 12(8):703-6.
10. Duh, Q.Y., (2003) Presidential Address: Minimally invasive endocrine surgery--standard of treatment or hype? *Surgery* 134(6):849-57.
11. Henry, J.F., (2008) Minimally invasive thyroid and parathyroid surgery is not a question of length of the incision. *Langenbecks Arch Surg* Ng, J.W., (2004) Minimally invasive surgery or minimal-incision thyroidectomy? *Arch Surg* 139(7):802.
12. Dionigi, G., Boni, L., Duran-Poveda, M.,( 2011) Evolution of endoscopic thyroidectomy. *Surg Endosc.*;25(12):3951-2; author reply 3953. doi: 10.1007/s00464-011-1763-5
13. Dionigi, G.,( 2009) Evidence-based review series on endoscopic thyroidectomy: real progress and future trends. *World J Surg.*;33(2):365-6. doi: 10.1007/s00268-008-9834-z.
14. <http://www.telegraph.co.uk/women/womens-life/9968817/Meet-the-Italian-women-fighting-to-be-more-than-mothers-and-lovers.html>
15. Cunningham, S.C., (2006) Minimally accurate nomenclature. *Surg Endosc* 20(6):998.
16. Cuschieri, A.,( 1992) "A rose by any other name ..." Minimal access or minimally invasive surgery? *Surg Endosc.*; 6(5):214.
17. Miccoli, P., Materazzi, G., Berti, P., ( 2010) Natural orifice surgery on the thyroid gland using totally transoral video-assisted thyroidectomy: report of the first experimental results for a new surgical method: are we going in the right direction? *Surg Endosc.*;24(4):957-8
18. Witzel, K., von Rahden, B.H., Kaminski, C., et al (2008) Transoral access for endoscopic thyroid resection. *Surg Endosc.*; 22:1871-1875
19. Benhidjeb, T., Wilhelm, T., Harlaar, J., et al (2009) Natural orifice surgery on thyroid gland: totally transoral video-assisted thyroidectomy (TOVAT): report of first experimental results of a new surgical method. *Surg Endosc.*: 23:1119-1120
20. Wilhelm, T., Metzger, A., (2010) Endoscopic minimally invasive thyroidectomy: first clinical experience. *Surg Endosc.* ;24:1757-1758
21. Wilhelm, T., Metzger, A., (2011) Endoscopic minimally invasive thyroidectomy (eMIT): a prospective proof-of-concept study in humans. *World J Surg.*; 35:543-551
22. Liu, E., Qadir Khan, A., Niu, J., Xu, Z., Peng, C.,(2015) Natural Orifice Total Transtracheal Endoscopic Thyroidectomy Surgery: First Reported Experiment. *J Laparoendosc Adv Surg Tech A.*;25(7):586-91.
23. Woo, S.H.,(2014) Endoscope-assisted transoral thyroidectomy using a frenotomy incision. *J Laparoendosc Adv Surg Tech A.*;24(5):345-9.
24. Benhidjeb, T., Stark, M., (2011) Endoscopic minimally invasive thyroidectomy (eMIT): safety first! *World J Surg* 35:1936-1937 Anuwong, A.,(2016) Transoral Endoscopic Thyroidectomy Vestibular Approach: A Series of the First 60 Human Cases. *World J Surg.* ;40(3):491-7.
25. Clark, J.H., Kim, H.Y., Richmon, J.D.,(2015) Transoral robotic thyroid surgery. *Gland Surg.*;4(5):429-34.
26. Lee, H.Y., Richmon, J.D., Walvekar, R.R., Holsinger, C., Kim, H.Y.,(2015) Robotic transoral periosteal thyroidectomy (TOPOT): experience in two cadavers. *J Laparoendosc Adv Surg Tech A.*

25(2):139-42.

27. Lee, H.Y., You, J.Y., Woo, S.U., Son, G.S., Lee, J.B., Bae, J.W., Kim, H.Y.,(2015) Transoral periosteal thyroidectomy: cadaver to human. *Surg Endosc.* ;29(4):898-904.

28. Lee, H.Y., Hwang, S.B., Ahn, K.M., Lee, J.B., Bae, J.W., Kim, H.Y.,(2014) The safety of transoral periosteal thyroidectomy: results of Swine models. *J Laparoendosc Adv Surg Tech A.* ;24(5):312-7.

29. Inabnet, W.B., 3rd, Suh, H., Fernandez-Ranvier, G.,(2017) Transoral endoscopic thyroidectomy vestibular approach with intraoperative nerve monitoring. *Surg Endosc.* ; 31(7):3030. doi: 10.1007/s00464-016-5322-y. Epub 2016 Nov 10.

30. Park, J.O., Kim, M.R., Kim, D.H., Lee, D.K.,(2016) Transoral endoscopic thyroidectomy via the trivestibular route. *Ann Surg Treat Res.*;91(5):269-272.

31. Witzel, K., Hellinger, A., Kaminski, C., Benhidjeb, T.,(2016) Endoscopic thyroidectomy: the transoral approach. *Gland Surg.* ;5(3):336-41. doi: 10.21037/g.s.2015.08.04. Review.

32. Udelsman, R., Anuwong, A., Oprea, A.D., Rhodes, A., Prasad, M., Sansone, M., Brooks, C., Donovan, P.I., Jannitto, C., Carling, T.,(2016) Trans-oral Vestibular Endocrine Surgery: A New Technique in the United States. *Ann Surg.*; 264(6):e13-e16.

#### AUTHOR CONTRIBUTIONS

**Conception and design:** Gianlorenzo Dionigi, Antonina Catalfamo, Francesca Pia Pergolizzi;

**Administrative support:** Gianlorenzo Dionigi

**Collection and assembly of data:** Antonina Catalfamo;

**Data analysis and interpretation:** Francesca Pia Pergolizzi;

**Manuscript writing:** All authors;

**Final approval of manuscript:** All authors.



©2017 by the Author(s); licensee Accademia Peloritana dei Pericolanti (Messina, Italy). This article is an open access article distributed under the terms and conditions of the Creative Commons Attribution 4.0 International License (<https://creativecommons.org/licenses/by/4.0/>).

**Communicated and received November 15,2017; revised November 20,2017; published on line December 20, 2017**