

## Sebaceous carcinoma in a mature teratoma of the ovary

Renata Bernardini de Lima<sup>a</sup> , Juliana Elizabeth Jung<sup>a</sup> ,  
Sérgio Ossamu Ioshii<sup>a,b</sup> , Roger Mitsuo Kami<sup>c</sup> 

**How to cite:** Lima RB, Jung JE, Ioshii SO, Kami RM. Sebaceous carcinoma in a mature teratoma of the ovary. *Autops Case Rep* [Internet]. 2018;8(4):e2018047. <https://doi.org/10.4322/acr.2018.047>

### ABSTRACT

The finding of a sebaceous carcinoma in a mature teratoma is rare in human pathology, with fewer than 10 cases currently reported in the literature. In this article, we report a case of sebaceous carcinoma in a mature teratoma of the ovary in a 59-year-old patient and discuss its histological findings.

### Keywords

Teratoma; Ovarian Neoplasms; Sebaceous Adenocarcinoma

### INTRODUCTION

Sebaceous carcinoma in a mature teratoma is a rare event of human pathology, with fewer than 10 cases currently reported in the literature, but none from Brazil.<sup>1-8</sup>

Sebaceous carcinoma is a rare tumor in itself, with an incidence of one to two cases per million persons a year.<sup>9-11</sup> Nonetheless, it is the third most common malignancy on the eyelid, after basal cell and squamous cell carcinomas. The most common extrapalpebral locations are the head and neck, and less frequently the trunk and extremities. There are even fewer extracutaneous sites, one of which is the ovary.<sup>12,13</sup>

### CASE REPORT

A 59-year-old female patient was admitted to our institution for the evaluation of a pelvic mass identified on an ultrasound exam. The imaging report described an expansive mass on the right adnexa, measuring

190mm, with both solid and liquid components. The patient was submitted to laparotomy with bilateral oophorectomy. The procedure was uneventful and the patient had a good recovery. The intra-operative pathology report identified a teratoma.

After the final histologic report was released, which stated malignancy, the patient underwent another laparotomy for the removal of the uterus and the omentum; peritoneal biopsies were also performed. The pathological reports for these organs were unremarkable.

The patient still makes regular follow-up visits to our hospital, and almost 3 years later has no further complaints and no change in follow-up test results.

### PATHOLOGICAL FINDINGS

Grossly, the right ovary showed a smooth and uniform external surface, measuring 18.5 × 15.0cm. When cut it revealed cysts with an output of greasy

<sup>a</sup> Hospital Erasto Gaertner, Department of Pathology. Curitiba, PR, Brazil.

<sup>b</sup> Pontificia Universidade Católica (PUC), Hospital Erasto Gaertner, Department of Pathology. Curitiba, Paraná, Brazil.

<sup>c</sup> Pathodiagnose Pathology Laboratory. Chapecó, SC, Brazil



material and hair tufts. The inner surface showed a frail vegetative yellowish area of 4.5 × 4.0 cm (Figure 1).

Microscopically, the usual components of a teratoma were readily identifiable: epidermis, hair follicles, and sebaceous glands. Focally, lobular arrangements of atypical sebaceous cells – with the

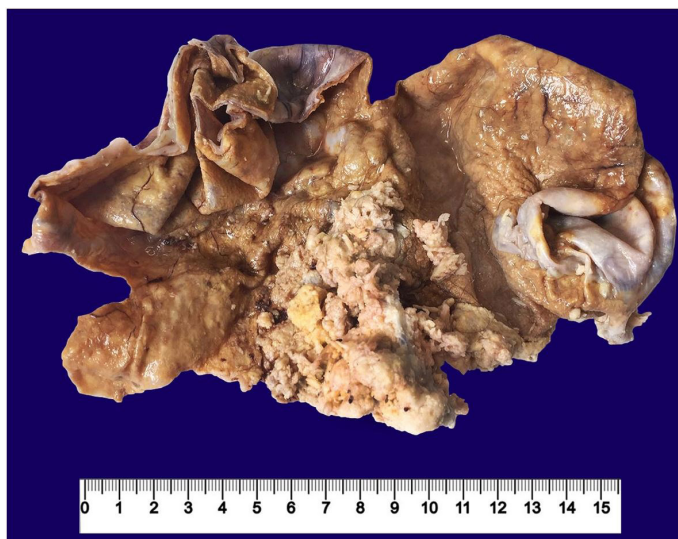presence of mitoses and nuclear pleomorphism – were observed, constituting a sebaceous carcinoma. The malignancy had no capsular nor lymphovascular invasion (Figure 2 and 3).

The left uterine adnexa had no gross nor microscopic alterations.

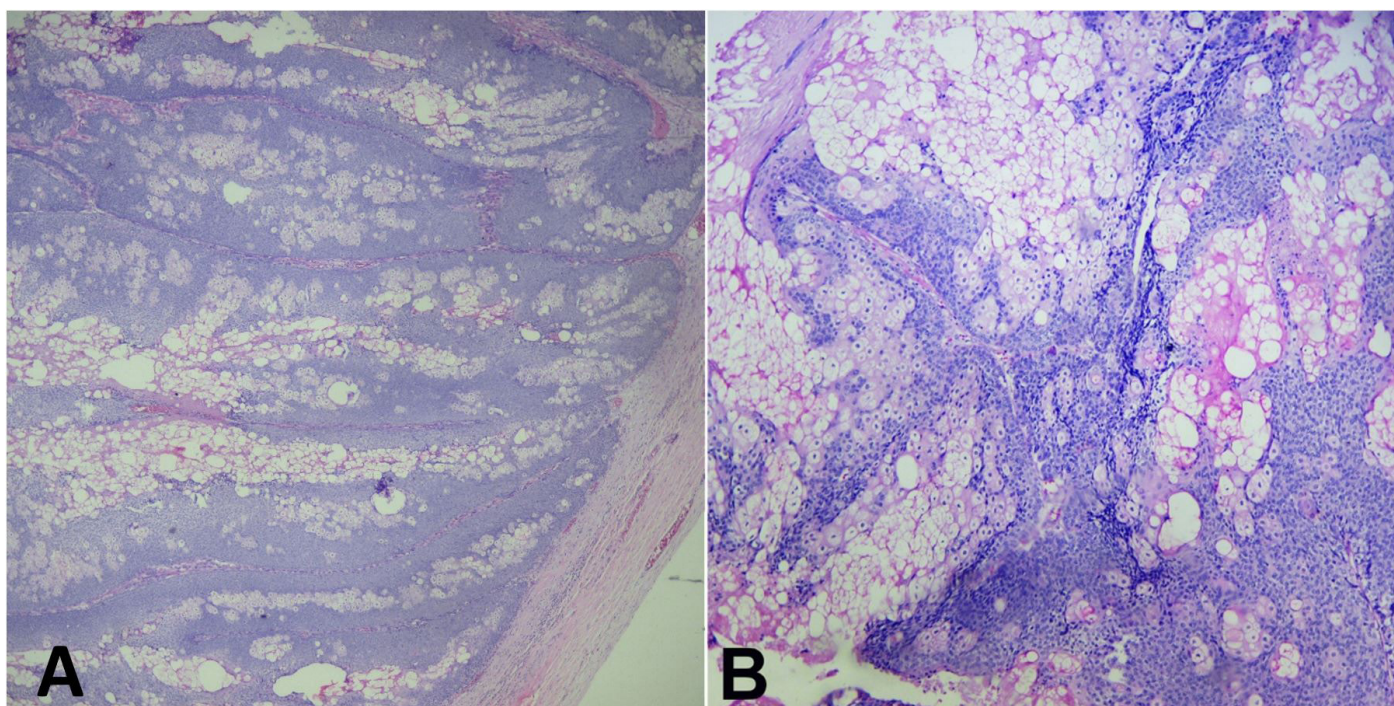
## DISCUSSION

Teratomas are common neoplasms of the human species and can develop in a variety of organs. In the ovary, 95% of teratomas are mature and cystic – the majority of which are composed of differentiated mature tissues and are almost invariably benign.<sup>14</sup> They are morphologically complex tumors containing parts derived from ectoderm (e.g. skin, hair follicles, sebaceous glands), mesoderm (e.g. muscles, urinary epithelium), and endoderm (e.g. lung and gastrointestinal tissue).<sup>15</sup> The pathway for developing this neoplasm is still uncertain, but studies point to a flaw on meiosis II or a pre-meiotic cell with a defective meiosis I. These tumors are bilateral in 10%-17% of cases.<sup>16</sup>

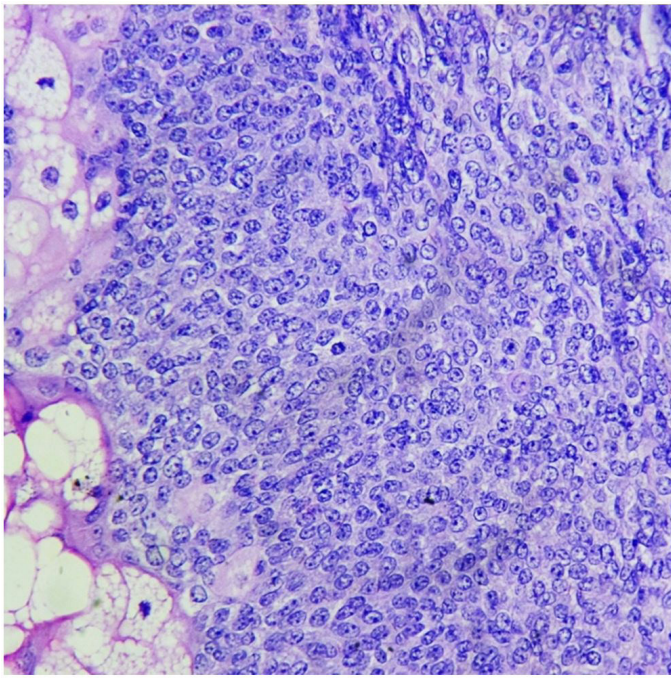
The transformation of a mature cystic teratoma happens when one or more of its components



**Figure 1.** Gross appearance of the specimen after fixation and sampling. Note that most of the internal surface is lined by a smooth surface and in the center of the picture an excrecent and irregular lesion arises, which represents the sebaceous carcinoma.



**Figure 2.** Photomicrographs of the tumor - **A** – Lobular arrangement of the neoplasm, and absence of capsular invasion (H&E, 40X). **B** – Groups of cells with vacuolated cytoplasm (H&E, 100X).



**Figure 3.** Photomicrographs of the tumor showing nuclear crowding, irregular nuclei with prominent nucleoli and a mitotic figure (H&E 400X).

becomes malignant, and that occurs in 0.2%-2% of cases.<sup>17-19</sup> Although all the tissues present in a teratoma can go through malignant transformation, more than three-quarters of them occur in the squamous epithelium, giving rise to a squamous cell carcinoma.

Features that are often seen in association with this transformation are: (i) patient age older than 45 years; (ii) a tumor diameter greater than 10cm; (iii) a rapid growth rate; and (iv) imaging findings, such as intratumoral low-resistance flux on Doppler ultrasound.<sup>16,20</sup>

Histologic evaluation of a sebaceous carcinoma shows malignant cells with various levels of differentiation, which are arranged in lobular architecture and lined by a fibrovascular stroma. On a well-differentiated carcinoma, the cells are vacuolated and have a foamy cytoplasm, while in a poorly differentiated carcinoma the cells are round with large nuclei. Squamous differentiation within a sebaceous carcinoma is not a rare finding. Pleomorphic nuclei, prominent nucleoli, and mitotic figures can be found.

The immunohistochemistry profile of a sebaceous carcinoma is positive for high-molecular-height cytokeratin, and epithelial membrane antigen, and

is negative for low-molecular-height cytokeratin, vimentin, and S100.<sup>21,22</sup>

To date, the treatment for sebaceous carcinoma has been surgical with wide excision and margin evaluation, with no need for adjuvant or neoadjuvant therapy.

The entity in our case – despite its rarity – was a clear diagnosis using histological criteria, but it can be a propaedeutic challenge. During our literature review, we found that different treatments were given to patients with this same diagnosis, with different outcomes that seemed more related to the extent of the disease and to the patients' underlying health conditions.<sup>1-8</sup> Our patient had a good response to the treatment given, although it could be argued that the same outcome could have been achieved without the extended surgical approach that followed the diagnosis. In conclusion, currently there are not enough data to support any particular treatment protocol, which means that medical teams need to address each new case on an individual basis.

The patient has signed the consent declaration. This manuscript has been approved for publication by the Research Ethical Committee of Erasto Gaertner Hospital.

## REFERENCES

1. An HJ, Jung YH, Yoon HK, Jung SJ. Sebaceous carcinoma arising in mature cystic teratoma of the ovary. *Korean J Pathol.* 2013;47(4):383-7. <http://dx.doi.org/10.4132/KoreanJPathol.2013.47.4.383>. PMID:24009635.
2. Betta PG, Cosimi MF. Sebaceous carcinoma arising in benign cystic teratoma of the ovary: case report. *Eur J Gynaecol Oncol.* 1984;5(2):146-9. PMID:6723706.
3. Chumas JC, Scully RE. Sebaceous tumors arising in ovarian dermoid cysts. *Int J Gynecol Pathol.* 1991;10(4):356-63. <http://dx.doi.org/10.1097/00004347-199110000-00008>. PMID:1774106.
4. Changchien CC, Chen L, Eng HL. Sebaceous carcinoma arising in a benign dermoid cyst of the ovary. *Acta Obstet Gynecol Scand.* 1994;73(4):355-8. <http://dx.doi.org/10.3109/00016349409015780>. PMID:8160548.
5. Papadopoulos AJ, Ahmed H, Pakarian FB, Caldwell CJ, McNicholas J, Raju KS. Sebaceous carcinoma arising within an ovarian cystic mature teratoma. *Int J Gynecol Cancer.* 1995;5(1):76-9. <http://dx.doi.org/10.1046/j.1525-1438.1995.05010076.x>. PMID:11578458.

6. Vartanian RK, McRae B, Hessler RB. Sebaceous carcinoma arising in a mature cystic teratoma of the ovary. *Int J Gynecol Pathol.* 2002;21(4):418-21. <http://dx.doi.org/10.1097/00004347-200210000-00014>. PMID:12352193.
7. Ribeiro-Silva A, Chang D, Bisson FW, Ré LO. Clinicopathological and 17 immunohistochemical features of a sebaceous carcinoma arising within a benign dermoid cyst of the ovary. *Virchows Arch.* 2003;443(4):574-8. <http://dx.doi.org/10.1007/s00428-003-0854-7>. PMID:12836022.
8. Venizelos ID, Tatsiou ZA, Roussos D, Karagiannis V. A case of sebaceous carcinoma arising within a benign ovarian cystic teratoma. *Onkologie.* 2009;32(6):353-5. <http://dx.doi.org/10.1159/000217797>. PMID:19521124.
9. Dasgupta T, Wilson LD, Yu JB. A retrospective review of 1349 cases of sebaceous carcinoma. *Cancer.* 2009;115(1):158-65. <http://dx.doi.org/10.1002/cncr.23952>. PMID:18988294.
10. Dores GM, Curtis RE, Toro JR, Devesa SS, Fraumeni JF Jr. Incidence of cutaneous sebaceous carcinoma and risk of associated neoplasms: insight into Muir-Torre syndrome. *Cancer.* 2008;113(12):3372-81. <http://dx.doi.org/10.1002/cncr.23963>. PMID:18932259.
11. Kuzel P, Metelitsa AI, Dover DC, Salopek TG. Epidemiology of sebaceous carcinoma in Alberta, Canada, from 1988 to 2007. *J Cutan Med Surg.* 2012;16(6):417-23. <http://dx.doi.org/10.1177/120347541201600610>. PMID:23149197.
12. Kumabe A, Kawase T, Miura K, et al. Sebaceous carcinoma of the parotid gland: F18 FDG PET/CT findings. *Clin Nucl Med.* 2010;35(4):260-2. <http://dx.doi.org/10.1097/RLU.0b013e3181d18f0d>. PMID:20305416.
13. Gnepp DR. My journey into the world of salivary gland sebaceous neoplasms. *Head Neck Pathol.* 2012;6(1):101-10. <http://dx.doi.org/10.1007/s12105-012-0343-x>. PMID:22430772.
14. Ayhan A, Bukulmez O, Genc C, Karamursel BS, Ayhan A. Mature cystic teratomas of the ovary: case series from one institution over 34 years. *Eur J Obstet Gynecol Reprod Biol.* 2000;88(2):153-7. [http://dx.doi.org/10.1016/S0301-2115\(99\)00141-4](http://dx.doi.org/10.1016/S0301-2115(99)00141-4). PMID:10690674.
15. Bidus MA, Zahn CM and Rose GS. Germ cell, stromal, and other ovarian tumors. In: DiSaia PJ, Creasman WT. *Clinical gynecologic oncology.* 7th ed. Philadelphia: Mosby-Elsevier; 2007. p. 381.
16. Hackethal A, Brueggmann D, Bohlmann MK, Franke FE, Tinneberg HR, Münstedt K. Squamous-cell carcinoma in mature cystic teratoma of the ovary: systematic review and analysis of published data. *Lancet Oncol.* 2008;9(12):1173-80. [http://dx.doi.org/10.1016/S1470-2045\(08\)70306-1](http://dx.doi.org/10.1016/S1470-2045(08)70306-1). PMID:19038764.
17. Westhoff C, Pike M, Vessey M. Benign ovarian teratomas: a population-based case-control study. *Br J Cancer.* 1988;58(1):93-8. <http://dx.doi.org/10.1038/bjc.1988.171>. PMID:3166898.
18. Comerci JT Jr, Licciardi F, Bergh PA, Gregori C, Breen JL. Mature cystic teratoma: a clinicopathologic evaluation of 517 cases and review of the literature. *Obstet Gynecol.* 1994;84(1):22-8. PMID:8008317.
19. Singh P, Yordan EL, Wilbanks GD, Miller AW, Wee A. Malignancy associated with benign cystic teratomas (dermoid cysts) of the ovary. *Singapore Med J.* 1988;29(1):30-4. PMID:2841767.
20. Dos Santos L, Mok E, Iasonos A, et al. Squamous cell carcinoma arising in mature cystic teratoma of the ovary: a case series and review of the literature. *NR Gynecol Oncol.* 2007;105(2):321-4.; published online January 22, 2007. <http://dx.doi.org/10.1016/j.ygyno.2006.12.008>. PMID:17240432.
21. Mulay K, White VA, Shah SJ, Honavar SG. Sebaceous carcinoma: clinicopathologic features and diagnostic role of immunohistochemistry (including androgen receptor). *Can J Ophthalmol.* 2014;49(4):326-32. <http://dx.doi.org/10.1016/j.jcjo.2014.04.004>. PMID:25103648.
22. Ansai S, Takeichi H, Arase S, Kawana S, Kimura T. Sebaceous carcinoma: an immunohistochemical reappraisal. *Am J Dermatopathol.* 2011;33(6):579-87. <http://dx.doi.org/10.1097/DAD.0b013e31820a2027>. PMID:21778832.

**Author contributions:** Lima RB together with Jung JE, Ioshii SO and Kami RM conceived the study and collected the data. Lima RB. Wrote the manuscript. Jung JE and Kami RM were responsible for the histological analysis and report. All authors collectively proofread and approved the manuscript to be published.

**Conflict of interest:** None

**Financial support:** None

**Submitted on:** July 19<sup>th</sup>, 2018

**Accepted on:** September 10<sup>th</sup>, 2018

### **Correspondence**

Renata Bernardini de Lima

Laboratório de Anatomia Patológica - Hospital Erasto Gaertner

Rua Dr. Ovide do Amaral, 201 - Jardim das Américas – Curitiba/PR – Brazil

CEP: 81520-060

Phone: +55 (41) 99918-7796

renabl@gmail.com