

## Comparative histological and histochemical study of flank region skin, in camel, cow and buffalo

Saffia Kareem Wally Al- Umeri      Nabeel Abd Murad Al- Mamoori  
Coll. of Vet. Med. / Univ. of AL-Qadisiyah

email: [Saffia.Alumare@qu.edu.iq](mailto:Saffia.Alumare@qu.edu.iq)      [Nabeel.almamorri@qu.edu.iq](mailto:Nabeel.almamorri@qu.edu.iq)

(Received 1 November 2016, Accepted 20 December 2016)

### Abstract

The skin represents protective cover for the body and making up 16 % of the body weight. The current study included 15 specimens of skin flank region of three animals (cow, buffalo, and camel) fixed in 10 % formalin and then processed through a serial steps for histological examinations, and stained with, Hematoxylin and Eosin, Van Gieson, and Periodic Acid Schiff stains, for description of the histochemical and histological structures of the skin. Results showed the epidermis was composed of four layers. The maximum thickness of epidermis observed in buffalo's skin was  $(6.16 \pm 0.27 \mu)$  and thinnest in camel's skin was  $(2.24 \pm 0.08 \mu)$ . The results revealed that the dermis consist of two layers; papillary and reticular layers which contain primary and secondary hair follicles, and there was great variation in diameter, sebaceous and sweat glands. The thickness of dermis was  $(84 \pm 1.26 \mu, 61.6 \pm 3.7 \mu, \text{ and } 53.6 \pm 2.03 \mu)$  in camel, buffalo and cow respectively. The thickness of papillary layer in buffalo's skin appeared with high thickness in compare with skin of cow and camel, while the flank skin of camel have maximum thickness of reticular layer, corneal, dermis, and total skin  $(68.8 \pm 4.63 \mu, 1.06 \pm 0.13 \mu, 84 \pm 1.26 \mu, 93.6 \pm 2.03 \mu)$  respectively. The sebaceous glands were simple branched and alveolar, present in large size and multi-lobular in skin of buffalo while in camel's skin appeared uni-lobular and small. All sweat glands in the flank region were of apocrine type; also differences were noticed in size and shape of these glands in studied animals. In buffalo it appeared small, single and few, but in camel was aggregation in large number spread in the dermis. In conclusion there are no differences in general structures of skin but thickness of layers varied among all the animals.

**Key words:** Skin, dermis, reticular layer, hair follicles, sweat glands.

## دراسة نسجية وكيميائية نسجية مقارنة لجلد منطقة الخصرة في الجمال والابقار والجاموس

صفية كريم والي العمري      نبيل عبد مراد المعموري  
كلية الطب البيطري / جامعة القادسية

### الخلاصة

يعتبر الجلد هو الغطاء الواقي للجسم ويشكل حوالي 16% من وزن الجسم. تضمنت الدراسة الحالية 15 عينة لجلد منطقة الخصرة من ثلاث حيوانات هي الأبقار والجاموس والجمال ، تم تثبيت العينات في 10% فورمالين وبعد ذلك تم اجراء الخطوات اللازمة لتحضير الشرائح النسجية وصبغت بصبغات الهيماتوكسلين ايبوسين ، فان كيزن و كاشف شف الدوري لغرض الوصف الكيميائي النسيجي و التركيب النسيجي لها. اوضحت النتائج أن البشرة تتكون من اربعة طبقات كما أظهرت الدراسة أن أعلى سمك للأدمة لوحظ في جلد الجاموس وكان  $6.16 \pm 0.27$  مايكروميتر و اقل سمك كان في جلد الجمال بلغ  $2.24 \pm 0.08$  مايكروميتر، ولوحظت الأدمة في هذه الدراسة تتكون من طبقتين هي الطبقة الحليمية والطبقة الشبكية وتحتوي ايضا على جريبات الشعر الابتدائية والثانوية التي ظهر اختلاف كبير في اقطارها. ان سمك الطبقة الحليمية لجلد الجاموس كان اعلى مقارنة بجلد الابقار والجمال بينما الجاموس يمتلك اعلى سمك للطبقات الشبكية ، والمتقرنة ، والادمة ، وسمك الجلد الكلي كان  $(68.8 \pm 4.63, 84 \pm 1.26, 1.06 \pm 0.13, 93.6 \pm 2.03)$  مايكروميتر) على التوالي. وظهرت الغدد الزهمية بشكل غدد كيسية متفرعة بسيطة مصاحبة لجريبات الشعر ولوحظت في الجاموس بأعداد كبيرة ومتعددة الفصوص بينما ظهرت في جلد الجمال أحادية الفص صغيرة وتحيط بجريبات الشعر، اما الغدد العرقية فظهرت في جلد الجاموس مفردة وصغيرة ، بينما لوحظت بشكل مجاميع وبأعداد كبيرة في جلد الجمال ، نستنتج من ذلك ليس هناك اختلاف في التركيب العام للجلد ولكن هناك اختلاف في سمك الطبقات.

**الكلمات المفتاحية:** الجلد ، الادمة ، الطبقة الشبكية ، جريبات الشعر ، الغدد العرقية

## Introduction

Cow, camel and buffalo are important animals for the sources of animal meat and milk. The skin making up 16 % of the body weight classified as thick or thin, represent protective cover for the body. It consists of epidermis, dermis and hypodermis. The dermis was thicker from the epidermis which consist of mainly of multilayer of keratinocytes, hair follicles, sebaceous glands, sweat glands, it plays important role in the temperature regulation of the body. The hypodermis act as energy store and thermal insulating layer and protecting the body from external influence (1, 2, 3, 4). The hair follicles which produce the different types of hair which distribution over the body is established during fetal development and no extra follicles are added after birth (5, 6, 7). The sweat glands produce sweat, there are two main types of it; eccrine, and apocrine sweat glands different in their structure are used to regulate temperature and remove waste by secreting water, sodium salts and also play a major role in the process of water balance and ions and also cooling body by evaporation from the surface of the body. Sebaceous glands are associated with hair follicles and secrete sebum, an oily substance, a form of holocrine secretion, usefulness of these glands are moisturizing skin and hair (8). Because the lake of comparative studies between these animals, conducting this study which aims to description histological show

## Results

The results displayed that camel, cow and buffalo skin were consist of three layers; epidermis, dermis and the hypodermis.

**1-Epidermis:** Composed of stratified squamous epithelium, and main cells called keratinocytes, free of blood vessels consist of four layers arranged from outer to the inner as corneal layer, granulosum layer, spinosum layer and basal layer; this layer consisting of a row of columnar cells with elongated nuclear a dark color, while the spinosum layer consisting of several layers of polyhedral cell (Fig. 1, 2, 3). The thickness of epidermis varied among the studied animals. The maximum thickness ( $6.16 \pm 0.27\mu$ ) was record in buffalo, ( $4.08 \pm 0.23\mu$ )

and find out the differences of the skin of these animals and therefor, know the differences behavior of living adjustment and each carrying different environments.

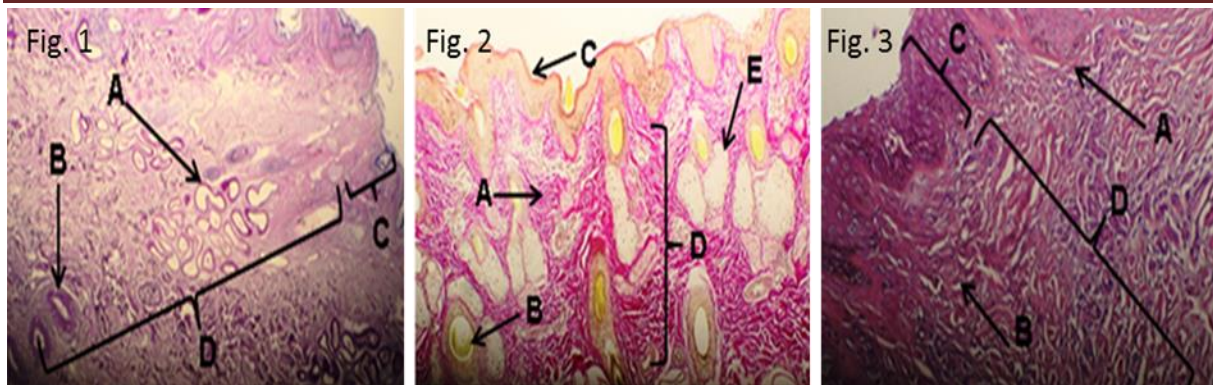
## Materials and methods

Fifteen (15) fresh skin specimens were collecting from the flank region of cows, buffalos and camels, after slaughtering of animals in AL-Diwaniyah's massacre. The hair on the skin was removed by applying depilatory ointment for 7-10 minutes. Cleaned skin specimens were fixed in 10% formalin, and were left in installed material for 48 hour and then processed through a serial steps for histological examinations. Tissue specimens were then dehydrated in graded ethanol series and cleared with xylene and infiltrated with paraffin wax at 56°C melting point. Several methods were used for staining the histological slides; Harris Hematoxylin and Eosin, Van-Gibson, and Periodic Acid – Schiff's' reagent (PAS) (9). The histological measurements were taken by use of calibrated ocular micrometer after compliance with calibrated stage micrometer and using object oriented lens to measure the thickness of, total skin, dermis, epidermis, corneal layer, papillary layer and reticular layer. Data were expressed as means  $\pm$  standard errors ( $M \pm SE$ ).

and  $2.24 \pm 0.08\mu$ ) in cow and camel respectively (Table. 1).

**2-Dermis:** The dermis in all animals were dens irregular connective tissue which was consist of elastic, collagen and reticular fibers, it was divided into two layers: superficial papillary layer is located beneath the epidermis and reticular layer, there is no clear line of demarcation, the reticular was much thicker than papillary layer (Fig. 3). The maximum thickness of papillary layer ( $6.88 \pm 0.73\mu$ ) was record in buffalo, ( $5.44 \pm 0.78\mu$ ) in cow and ( $5.2 \pm 0.76\mu$ ) in camel. The reticular which located in the depth of dermis and extended to the hypodermis and contain primary and secondary hair follicles

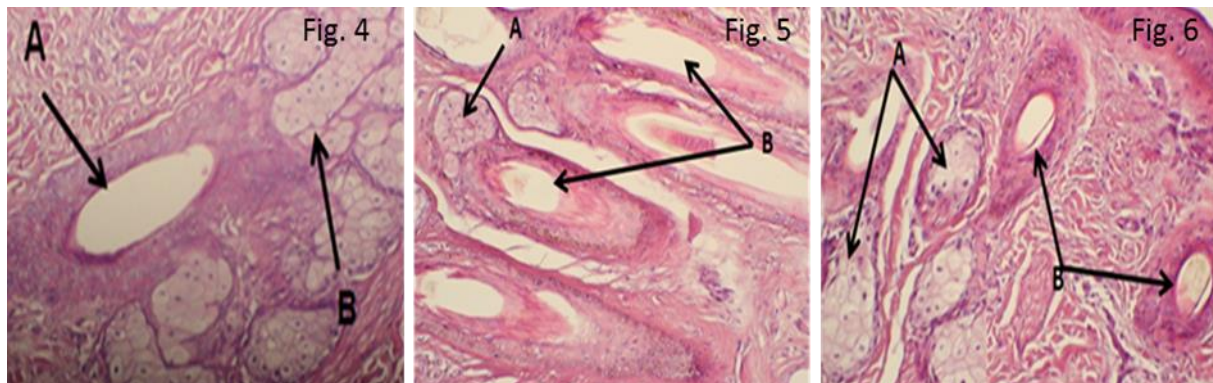




**Fig. (1):** Cross section of camel flank skin showing sweat glands (A), hair follicle (B), epidermis (C), and dermis (D), (PAS stain, X4).

**Fig. (2):** Cross section of cow flank skin showing reticular fiber (A), hair follicle (B), epidermis (C), reticular layers of dermis (D), sebaceous gland (E) (Van Gesion stain, X10).

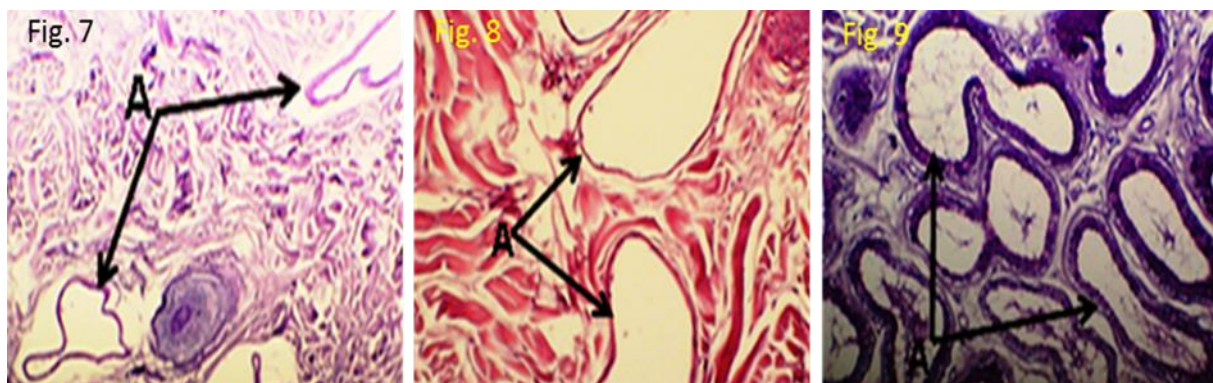
**Fig. (3):** Cross section of buffalo flank skin showing the different layers of skin; papillary layer (A), fibers (B), epidermis (C), reticular layers of dermis (D), (H&E stain, X20).



**Fig. (4):** Cross section through the dermis of buffalo flank skin showing the primary hair follicle (A), multi-lobular sebaceous glands (B), (H&E stain, X40).

**Fig. (5):** Cross section through the dermis of camel flank skin showing the uni-lobular sebaceous glands (A) primary and secondary hair follicle (B) (H&E stain, X20).

**Fig. (6):** Cross section through the dermis of cow flank skin showing the uni-lobular sebaceous glands (A), primary and secondary hair follicle (B) (H&E stain, X20).



**Fig. (7):** Cross section through the deeper layer of the dermis of buffalo flank skin showing the sweat gland small and single (A), (PAS stain, X20).

**Fig. (8):** Cross section through the dermis of cow flank skin showing the sweat gland (A), (H&E stain, X20).

**Fig. (9):** Cross section through the dermis of camel flank skin showing the secretory sweat gland (A), (H&E stain, X20).

noticed the primary larger and deeper than secondary, in the dermis of buffalo observed only the primary hair follicles surrounding by large number of multi lobular sebaceous glands (Fig. 4) while the dermis of camel has one primary follicle and a number of secondary follicle (Fig. 5). The cow skin contains primary of 3-4 secondary hair follicles companied mono lobular sebaceous glands (Fig. 6). Its thickness was ( $68.8 \pm 4.63\mu$ ,  $49.2 \pm 1.2 \mu$ ,  $48.8 \pm 2.65 \mu$ ) in camel, buffalo, and cow respectively (Table 1) (Fig. 3). The thickness of corneal layers were ( $1.06 \pm 0.13\mu$ ,  $1.36 \pm 0.09 \mu$ ,  $0.64 \pm 0.16\mu$ ) in camel, buffalo and cow respectively (Tab. 2). Results were revealed that presence of two types of glands in the dermis of all studied animals which are: sebaceous glands were simple branched alveolar holocrine were always associated and surrounded the hair follicles, observed in buffalo in aggregation as large groups multi-lobular (Fig. 4), while in camel appeared as small uni-lobular separated in the dermis (Fig. 5). In cow the

shape of sebaceous gland similar to camel (Fig. 6). The sweat glands of the skin in this study were of apocrine type, simple coiled sacular glands consist of straight canal and coiled secretary portion, the gland density differs among animals, in buffalo it was few in number, single and showed low gland density (Fig.7), and in cow has development sweat gland (Fig. 8) while were most numerous and form of aggregates wide spread in the dermis of camel skin (Fig. 9). The thickness of dermis was ( $84 \pm 1.26\mu$ ,  $61.6 \pm 3.7\mu$ ,  $53.6 \pm 2.03\mu$ ) in camel, buffalo, cow respectively (Table 2).

**3-Hypodermis:** was located under the dermis, consist of loose connective tissue, collagen, elastic and reticular fibers, and the spaces in this layer were filled with adipose tissue. The thickness of total skin was varied between animals in this study. The maximum and the minimum thicknesses of total skin ( $93.6 \pm 2.03\mu$ ,  $62.6 \pm 3.48\mu$ ) in camel and cow respectively and ( $72 \pm 4.19\mu$ ) in buffalo (Table. 2).

**Table (1): Explain thicknesses of epidermis, papillary and reticular layers of skin flank region of cow, buffalo and camel in micrometer ( $\mu$ ) ( $M \pm SE$ ).**

Layer Animal	Epidermis	Papillary layer	Reticular layer
Camel	2.24±0.08	5.2±0.76	68.8±4.63
Buffalo	6.16±0.27	6.88 ±0.73	49.2±1.2
Cow	4.08±0.23	5.44±0.78	48.8±2.65

**Table (2): Explain thicknesses of corneal layer, total dermis and total skin thickness of flank region skin of cow, buffalo and camel in micrometer ( $\mu$ ) ( $M \pm SE$ ).**

Layer Animal	Corneal layer	Total dermis	Total skin
Camel	1.06±0.13	84± 1.26	93.6±2.03
Buffalo	1.36±0.09	61.6±3.7	72±4.19
Cow	0.64±0.16	53.6±2.03	62.6±3.48

## Discussion

Flank skin in the current study is similar to the skin of former regions of the body; consists of epidermis, dermis and hypodermis. Epidermis is composed of keratinized stratified squamous epithelium consist of four layers; basal, spinosum, granulosum, and corneal layer. It is free of blood vessels, and the oxygen and materials moves here by diffusion from the dermis. These results are in agreement with (10, 11). The results showed that the basal layer consisting of a row of columnar cells with elongated nuclei, while the spinosum layer consisting of polyhedral cells. The

maximum thickness of the epidermis in buffalo is ( $6.16 \pm 0.27\mu$ ) in compare with cow and camel ( $4.08 \pm 0.23$  and  $2.24 \pm 0.08$ ) respectively. It was determined that the number of rows of cells layers constituted this layer in buffalo was more than cow and camel, this is an asymptotic to (12, 13) whom studying the Indian buffalo leather. The corneal layer is contained dead cells in the form of bands, it agreed with (14). There are a differences in thicknesses of epidermis and corneal layer according to species of animal, this result corresponds with the (15). The dermis is thick made up of dense connective



tissue and contain papillary and reticular layer, a superficial papillary layer located outermost and extends to the dermis to supply it with vessels because not contain blood vessels. The difference in thickness of papillary layer depend on the age and anatomical location (16), the study showed presence of direct relationship between the thickness of the papillary layer and thickness of epidermis these results agreement with (17), whereas the reticular layer is located in the depth of dermis and contain large amount of dense irregular connective tissue in parallel to the skin surface in addition to contain elastic fiber fewest than the papillary layer so the reticular layer be firmer from the papillary layer because of the presence of fibrous elements in this layer more than cellular elements, leading to give skin strength and flexibility, these results agreement with findings of (18,19). The study declare that the dermis contains two types of hair follicle primary and secondary follicles, the primary appeared larger than secondary and accompanied sweat gland, sebaceous gland and involuntary muscles while the secondary smaller and numerous number and accompanied sebaceous glands only and surrounded by it. Similar results were reported by (20). Hair follicles are one of skin appendages which produce hairs. Its main structure is similar, primary hair follicle in cow is associated with 3-4 secondary follicles arranged in a parallel fashion to each other and surrounded by the sebaceous glands, this results doesn't agree with (21) in European cattle that having primary only, while in camel the hair follicles found in form of groups consisting of more than 3 primary follicles and several secondary follicles. This is for camel environmental adjustment to able to walk in desert, where exposure to heat of the sun and thus the presence of thick hair helps to protect the animal's body from excess heat in addition to the nature of the animal used to transport materials and for riding a long distances and therefore these loads cause hairless as a results of friction and this may be a reason to increase the number of hair follicle (22), these differences refers of the difference in species. In current study the sebaceous

glands are simple branched or compound alveolar glands with duct derived from epidermis cells and associated with hair follicles noticed in the skin flank due to this region containing hair, because these gland does not exist in the free areas of the hair (23), in the mammals this glands produce an oily sebum by holocrine secretion, sebum keeps the skin moist and soft, acting as a barrier, antifungal, antibacterial and reduce friction with cell nearby, work as thermal insulation, contribute in form vitamin D and prevent the entry of water to the hair and skin, these glands in the three studied species of animals had more the basic structure but different in number, shape and size, observed large and a lot of number in buffalo. There is an inverse relationship between poetic density and size of the gland. The sebaceous gland that multi-lobular and numerous in number in dermis of buffalo, but in skin of camel little and individually, and moderate number in cow, this differences depends on the animal's environment type and different in condition. The results of the histological study showed skin flank for (cow, buffalo and camel) that porcine sweat glands are common in this region and it emerged as simple tubular gland these results similar to (24). The sweat glands secret fluid consists of water and some salts, and usefulness of this secretion is to regulate the degree of the animal's body temperature. It observed developed and in large number in camel, for the purpose of regulating body temperature and enables to withstand and resistance desert conditions. In buffalo the sweat glands limitedly, single and small so prefer wallowing in water because the specific heat of water and also the ability of water to absorb a greater amount of heat from the body of the animal. The hair on buffalo's body is few in amount, helps to this exchange between the water and animal's body. The results showed the hypodermis beneath the dermis, the purpose of it, to attach the skin to underlying the muscles and bones as well as, supplying it with blood vessels and nerves, this layer contain 50% of body fat serves a padding in insulation for the body. The present study showed the existence of direct relationship between the total thickness of

the skin and thickness of the dermis in all study animals. In conclusion; Differences in thicknesses of layers of skin in the studied

animals and variation in the number and size of skin gland is advert to the adaptation of these animals to its surrounding environment.

## References

- 1-Mahout O, Kadima IT, Al-Shahab A, Bello RB, Al-Amir IS, Ambo-Ali AA, Khaled S (2010) An assessment of Omani native sheep fiber production and quality characteristics. *J. Agric. Marine. Sci.*, 15: 9-14.
- 2-Dalman HD (1994) Textbook of Veterinary Histology. Lea and Fibiger. Philadelphia.Pp80- 95.
- 3-Elizabeth A, Fredric L (2010) Comparative Veterinary Histology with Clinical Correlates. Manson Publishing.p:84-88
- 4-Richard W, Hunter J, saving J, Dahl M (2008) *Clinical Dermatology* 4<sup>th</sup> (ed.) Malden Massachusetts USA. Black net publishing, pp: 268.
- 5-Jonquiere LC, Camera J (2003) *Basic Histology*, 10<sup>th</sup> ed., McGraw-Hill Co USA.
- 6-Dalman HD (1993) Textbook of Veterinary Histology. 4<sup>th</sup> ed., Lea and Fibiger, Philadelphia.
- 7-Denis A, Locustae O, Chiavassa GH, Vial J, Lalonde Champ tier de Ribs C, Railhead JJ, Sans N (2008) High resolution MR imaging of the skin : normal imaging features. *J. Radial .Julio.* 89(7 -8 pt1): 873-9.
- 8-Bevell DL, Corbett AD, Holmes S, MacDonald A, Harker M (2007) The absence of apocrine glands in the human axilla has disease pathogen etic implications including axillary hyperhidrosis. *Bra. J. dermatology.* 150 (6): 1278 1286.
- 9-Luna IG (1968) *Manual of Histology Staining Methods of the Armed Force Institute & Pathology.* 3ed McGraw. Hill Book Company. New York. pp: 34-215.
- 10-Howl D (1990) Cornfield cell envelope. *dermatological J.*, 180: 201 -211.
- 11-Fresnel RK, Woodley DT (2001) *The Biology of the Skin.* The Parthenon Publishing Group, PP: 19 35.
- 12-Bressler RS, Bressler CH (1989) Functional anatomy of the skin. *Clip. Pediatric. Med. Surg.* 6: 229-296.
- 13-Katas A, Daghoglus (2009) Examination of structural features of skin in sheep breeds fetuses with histological methods. *Kafkas Univ. Vet. Fak. Derg.*, 15: 391-396
- 14-Genkovski D, Gerchev G (2007) Study of the skin histological structure in ewes from Staroplaninska and Thoroughbred Tsigai. *Biotechnol. Animal Husband.*, 23 (5-6): 191- 197
- 15-Abbasi MM, Gharzi A, karimi H, Khosoravinia H (2008) Effects of sex on histological characteristics of various area of skin in an Iranian native breed of sheep *J. Anim. Vet. Adv.* 7 (11): 1503-05.
- 16-Sorrel M, Caplan AI (2004) Fibroblast heterogeneity: more than skin deep. *J. Cell sci.* 117: 667-675.
- 17-Mobini B (2012) Histology of the skin in an Iranian native breed of sheep at different ages. *J. Vet. Adv.* 2(5): 226-231
- 18-Mir Shabir A, Sathyamoorthy OR, Ramesh G, Balachandran C (2011) Micrometrical studies on the skin of madras red sheep (*Ovis Aries*) in different age groups, *Tamilnadu Journal of Veterinary and Animal Science* 7,23-28.
- 19-Abdul Raheem MH, AL-Hety MS (1997) Histological and morphological study of the skin of the black goat. *Iraqi J. Vet. Sci.* 10:71-95.
- 20-Adams NR, Cornje PB (2003) A review of the biology linking fiber diameter with fleece weight , live weight, and reproduction in Merion Sheep *Aust. J. Agric. Res.* 54: 1-10.
- 21-Adib Moradi M, Sheibani MT (2000) Histological study of hair follicles of Raini goat skin. *J. Fac. Vet. Med.*, 55(2): 75-78.
- 22-Macneill KN, Riddell RH, Ghazarian D (2005) Perianal apocrine adeno carcinoma arising in benign 106 apocrine adenoma first case report and review of the literature . *J. clan . patrol.* 58 (2): 217-219.
- 23-Samuels DA (2007) *Textbook of Veterinary Histology.* Saunders China.
- 24-Ali Abbas Iris (2008) Histological and histochemical study to the native buffalo skin MSc. thesis Veterinary Medicine. Basrah University.