

INVITED REVIEW ARTICLE

Intra-tympanic injections in Meniere's disease

Ologe FE

Department of Otorhinolaryngology, University of Ilorin/University of Ilorin Teaching Hospital, Ilorin, Nigeria

Correspondence: Professor F. E. Ologe, Department of Otorhinolaryngology, University of Ilorin/University of Ilorin Teaching Hospital, Ilorin, Nigeria. Tel: +234 8035848916; Email: foluologe@yahoo.com

Abstract

Meniere's disease is a relatively common, sometimes disabling, disease. Pre-referral anti-vertiginous medication is common practice among family physicians. The objective of this review is to present the next level treatment of Meniere disease, beyond conservative management. Major databases such as the Pubmed were searched for recent publications on the management of Meniere's disease. The findings emphasised that the use of intra-tympanic steroid injections, among other measures, is an extensively researched treatment modality for Meniere's disease that is unresponsive to conservative management. In conclusion, referring physicians need to go beyond anti-vertiginous medications which family physicians usually prescribe. Aside from other medical treatments, intra-tympanic steroid injection is a simple, safe and reliable treatment option which needs to be further deployed in developing world practice.

Keywords: *Hearing loss; Intra-tympanic injection; Meniere's disease; Steroids; Vertigo.*

Introduction

Meniere's disease is a disorder of the inner ear which causes episodes of vertigo, ringing in the ears, a feeling of fullness or pressure in the ear, and fluctuating hearing loss. Prosper Meniere first described the disease in 1861. The endolymphatic sac is thought to maintain the hydrostatic pressure and endolymph homoeostasis for the inner ear, and its dysfunction may contribute to the pathophysiology of Meniere's disease. [1]

Meniere's disease has a prevalence of between 0.08 and 0.50%, [2-4] with the highest prevalence noted in a population-based study in Finland. [4] In the UK, the estimated economic cost of Meniere's disease ranges between £552.5 and £629.3 million per annum. [5] In Nigeria, the prevalence rates of the condition ranges from 0.22% to 0.4% among Ear-Nose-Throat (ENT) out-patients. [6-8] Meniere's disease was diagnosed among 21.6% of a group of

patients who complained of dizziness in Lagos, Nigeria. [9] In addition, pre-referral anti-vertiginous medication for suspected cases of Meniere's disease is common practice among family physicians in Nigeria. [9]

The symptoms of Meniere's disease are largely unpredictable and can adversely impact on the mental health and well-being of affected individuals, thus, significantly affecting the overall quality of life of the patients. [10,11]

Currently, there is no known cure for Meniere's disease as drug treatments are mainly targeted at symptom control while surgical options are controversial with inconsistent results. [12] Therefore, patients are encouraged to identify and avoid specific triggers where possible. Some of the likely trigger factors include changes in atmospheric pressure, specific dietary components

(e.g., salt, caffeine, aspartame, and alcohol) and stress. [13]

Criteria for the diagnosis of Meniere's disease

The initial position paper on the diagnostic criteria for Meniere's disease by the Equilibrium Committee of the American Academy of Otolaryngology-Head and Neck Surgery (AAO-HNS) was published in 1995. [14] The current position paper is jointly formulated by the Classification Committee of the Bárány Society, The Japan Society for Equilibrium Research, the European Academy of Otolology and Neurotology (EAONO), the Equilibrium Committee of the American Academy of Otolaryngology-Head and Neck Surgery (AAO-HNS) and the Korean Balance Society. [15]

There are two categories: (a) Definite Meniere's disease and (b) Probable Meniere's disease.

Definite Meniere's disease

The diagnosis is based on clinical criteria and requires the observation of an episodic vertigo syndrome associated with low- to medium-frequency sensorineural hearing loss and fluctuating aural symptoms (hearing, tinnitus and/or fullness) in the affected ear. The duration of episodes of vertigo is limited to between 20 minutes and 12 hours.

Probable Meniere's disease

This is a broader concept defined by episodic vestibular symptoms (vertigo or dizziness) which are associated with fluctuating aural symptoms occurring in periods ranging between 20 minutes and 24 hours in duration. [15].

Unilateral and Bilateral Meniere's disease

Depending on the duration of disease, the involvement of both ears in Meniere's disease could range from 5 to 50%. [16]

- a) Bilateral Meniere's disease Type 1: This is the most common variant, and it is not characterised by familial or autoimmune history and no migraine. [16]

- b) Bilateral Meniere's disease Type 2: This is the second most frequently observed variant. [17] The patients do not have any autoimmune co-morbid conditions, migraine, or familial history of Meniere's disease. However, affected individuals show a vascular risk profile, particularly high blood pressure and dyslipidemia. [16]
- c) Bilateral Meniere's disease Type 3: All the affected individuals have a familial history of Meniere's disease. They could be subdivided into two subgroups [Type 3a disease characterised by migraine (82% of cases), and Type 3b disease without migraine (18%)]. [16]
- d) Bilateral Meniere's disease Type 4: This is associated with migraine in all cases, but they do not have a familial history of Meniere's disease. [16]
- e) Bilateral Meniere's disease Type 5: This is considered as autoimmune Meniere's disease since all patients have another concurrent autoimmune disease. [16]

Staging of Meniere's Disease

Early Stage - This is characterised by sudden, unpredictable vertigo, hearing loss and tinnitus. Hearing is characteristically restored between attacks and vertigo.

Middle Stage - Episodes of vertigo are less severe, and hearing loss is worse but periodic remission occurs.

Late Stage - Vertigo is less frequent while hearing loss and tinnitus become worse and disorders of balance occur.

Pathology of Meniere's disease

The exact cause and pathophysiology of Meniere's disease are unclear. However, histopathologic examination in patients with Meniere's disease shows a distention of the Reissner's membrane (endolymphatic hydrops) in the cochlea or endolymphatic compartment of the labyrinth. [18,19] (Figure 1)

Risk Factors

Meniere's disease

The risk factors for Meniere's disease include diet, viral infections, migraine, autoimmune diseases, endolymphatic hydrops, endocrine disorders, vascular disorders and trauma. [21,22]

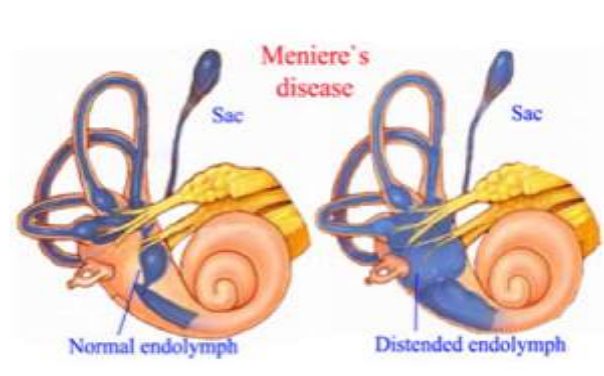


Figure 1: Showing the diseased endolymph²⁰

Other risk factors include a genetic consideration (a genetically induced dysfunction of ionic transport may act as a predisposing factors to develop Meniere's Disease [23]) and allergy (patients with Meniere's disease report a higher rate of allergic disorders than the general population. Type I allergic reaction is thought to be one of the possible reasons that may induce endolymphatic hydrops and lead to Meniere's disease. [24]).

A recent study provided evidence that changes in atmospheric pressure and humidity were associated with symptom exacerbation in Meniere's disease. [25] Lower atmospheric pressure is associated with higher probability of attacks and greater severity of vertigo, tinnitus, and aural fullness in Meniere's disease. [25] High humidity is also suspected to increase the chances of experiencing an attack of Meniere's disease. [25] Therefore, monitoring the weather conditions may reduce the unpredictability of exacerbated symptoms in Meniere's disease. [25] The uncertainty of when attacks may occur is known to contribute to the lowered quality of life among patients significantly. [25]

Investigations

Since histopathological examination (the gold standard) is not possible in a clinical setting, the diagnosis of Meniere's disease is based on clinical diagnostic criteria. [1, 15, 22, 26] The following ancillary investigations are useful:

- Audiological and vestibular assessment is recommended to monitor the clinical course. [22]
- MRI is useful as several differences have been reported in image features between the patients with Meniere's disease and controls by using a quantitative radiomics approach on high-resolution T2-weighted MRI scans of the labyrinth. [26] Cochlear endolymphatic hydrops is occasionally observed in control ears on MRI, as in normal temporal bone specimens. The presence or absence and degree of vestibular endolymphatic hydrops are significantly different between ears with Meniere's disease and control ears. Therefore, endolymphatic hydrops in the vestibule might be a specific predictor of definite Meniere's disease. [27]

Modalities of treatment [22,28]

Essentially, the goal of treatment for Meniere's disease is to control vertigo and preserve existing hearing. Over the years, different surgical procedures for intractable vertigo secondary to Meniere's disease have been described. Although many authors consider these procedures as effective, some others have expressed reservations about the long-term efficacy of the procedures as others believed that vertigo control is achieved more placebo than by the procedure itself. [1]

The treatment modalities include the following:

First Line

- Low salt diet (less than 1.5g sodium per day)
- Oral diuretic therapy
- Liberal water intake
- Avoidance of caffeine and nicotine
- Reduction of stress and anxiety
- Adequate control of blood pressure and insulin levels

Second line

Intra-tympanic steroid therapy

Third line

Ologe FE

Endolymphatic sac decompression (ESD) surgery: This is an excellent non-destructive surgical option for patients with incapacitating Meniere's disease. It is less frequently used today because of improved medical therapies and office-based procedures, but it has significant advantages over other forms of treatment for medically refractory Meniere's disease. [1] This procedure provides a high degree of vertigo control and hearing preservation. [1] Patients undergoing endolymphatic sac shunt procedures may also benefit from steroid instillation at the time of shunt placement. [29]

Triple semicircular canal plugging (TSCP), which reduces vertiginous symptoms in patients with intractable Meniere's disease, is an effective long-term therapy for this disorder. When compared with endolymphatic sac decompression (ESD), the vertigo control rate in TSCP is significantly higher than that of ESD operation. [30] A combined approach of TSCP and cochlear implantation (CI), which could control vertigo efficiently and improve hearing loss and tinnitus, represents an efficient and safe therapy for some advanced cases of Meniere's disease. [31]

Fourth line

Intra-tympanic Gentamycin therapy: This is indicated in intractable vertigo which is related to unilateral Meniere's disease but unresponsive to initial medical therapy. The goal is to reduce the frequency and severity of the vertigo attacks while minimising cochlear toxicity. [32]

Vestibular Nerve Section: The control rate for disabling Meniere's disease with hearing preservation approach 90% using this procedure. [32] The reported complications are minimal and may include 10% of cerebrospinal fluid leak and 3% of wound infection. [33] The fully endoscopic approach to vestibular nerve sections is a safe and efficient technique for the treatment of medically refractory Meniere's disease. This method utilises smaller incisions, minimal cranial openings, and no cerebellar retraction with improved visualisation of the cerebellopontine angle neurovascular structures. [34] A study exploring simultaneous cochlear implant showed encouraging results; thus, ensuring control of both vestibular and cochlear

symptoms during the same therapeutic procedure. [35]

Fifth Line

Labyrinthectomy: This is a highly effective treatment for disabling episodic vertigo in patients who have failed to respond satisfactorily to conservative management or hearing-sparing surgery, as well as patients who have a non-serviceable hearing in the affected ear. [36] Chemical labyrinthectomy is a safer alternative to surgical labyrinthectomy, but the risks of hearing loss are also high (this is important if hearing preservation is a consideration). [32] Cochlear Implant in Meniere's disease can yield good hearing outcomes even following a long delay after labyrinthectomy. [37]

Operative Procedure of Intratympanic Injection [38, 39]

The routes of entry of aminoglycosides and steroids into the inner ear include the round window membrane (primary route), the annular ligament of the oval window and the inner ear vasculature and lymphatic vessels. [32] The concentrations of the medications achieved in the perilymphatic and endolymphatic spaces, as a result of intra-tympanic therapy, are considerably higher than the concentrations achieved via systemic administration, particularly with steroids. [32]

Before intra-tympanic injections are considered, patients are initially treated with lifestyle modifications and medications, including betahistine, diuretics, or vasodilators for at least six months. Patients who fail to improve based on the medical therapies are considered candidates for intra-tympanic injections.

Intra-tympanic dexamethasone is administered in an office setting. The operative procedure of intra-tympanic steroid injection could be performed under a microscope (or endoscopically with 0 degree 2.7mm telescope) with the patient in the supine position. After the confirmation of an intact tympanic membrane and middle ear status, local anaesthesia is administered with a cotton ball soaked with lidocaine 10% pump spray (Xylocaine) or other concentrations as available.

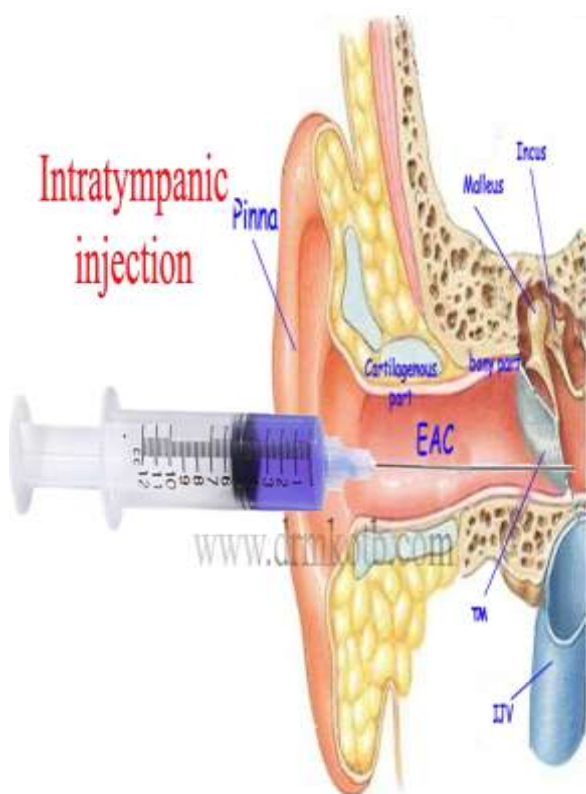


Figure 2: Intra-tympanic Injection⁴⁰

EAC - External Auditory Canal; TM - Tympanic Membrane; IJV - Internal Jugular Vein

This is applied to the tympanic membrane for 20 minutes. While the patient tilts the head 45° to the healthy side, a 25-gauge spinal needle is introduced into the posteroinferior portion of the tympanic membrane, and 0.4-0.5 mL of methylprednisolone (40 mg/mL) is instilled through this site. The patient is instructed to remain in the same position for 30 minutes without swallowing, yawning, sneezing or moving.

The frequency of the injections differs depending on the experience of the surgeon. Some will give the injection on the 1st, 3rd, 5th day up to 7 total injections, one injection every two or three days. [39] Others have given the intra-tympanic dexamethasone injection (ITD) once a week for four consecutive weeks, constituting one ITD course. After the initial ITD course, the patients are observed for Meniere's attacks for six months. If vertigo attacks are not adequately controlled, another ITD course (repeated ITD) is given. During the next six months following the second ITD, it is

important to evaluate vertigo control. If the patients are not satisfied with the effect of vertigo treatment, intra-tympanic gentamycin with modified titration protocol is given. [41] Reports have shown that intra-tympanic dexamethasone injection is a promising first-line conservative treatment for Meniere's disease given that the steroid possesses no risk of inner-ear toxicity. [42]

Intra-tympanic gentamycin, the standard treatment for refractory Meniere's disease, reduces vertigo, but damages vestibular function and can worsen hearing. In a comparative study involving intra-tympanic gentamycin and intra-tympanic corticosteroid (methylprednisolone), 87% reduction in vertigo was recorded in the gentamycin group compared with 90% decrease in the methylprednisolone group. [43] Both drugs were well tolerated with no safety concerns. Therefore, it may be concluded that methylprednisolone injections are non-ablative, effective treatment for refractory Meniere's disease [43] and that permits making a choice between methylprednisolone and gentamycin. [43]

Persistent tympanic membrane perforation has been reported following intra-tympanic steroid injection, but the frequency of this complication is reportedly low (1.6%). [44] Patients with a history of radiation to the head and neck may be at increased risk for a prolonged time for closure of perforation. [44]

In a study evaluating the safety and efficacy of a single intra-tympanic injection of OTO-104, a sustained-exposure dexamethasone, in patients with unilateral Meniere's disease, single intra-tympanic injection of OTO-104 (12 mg dexamethasone) or placebo was given to two different patient groups. OTO-104 was well tolerated; no adverse impact on safety was reported compared with placebo. Although OTO-104 did not significantly affect change from baseline in vertigo rate, it did reduce the number of definitive vertigo days, vertigo severity and average daily vertigo count compared with placebo. [45]

Ologe FE

Sustained-release vehicles for gentamycin delivery may have a role in the management of Meniere's disease patients who have previously failed intra-tympanic gentamycin injections, or those who have already lost serviceable hearing. [46] Their use as first-line treatment over single intra-tympanic injections for patients who do not respond to conservative treatment should be discouraged. [46]

Intra-tympanic dexamethasone (three sessions of weekly intra-tympanic dexamethasone injections using a concentration of 16 mg/mL) temporarily reduces the frequency of vertigo spells during the initial months (the first 6-month period) but does not remove the probability of having further spells in the future. [47] This therapy provides a valuable tool to accomplish a rapid decrease in vertigo spells, and it is considered an alternative to chemical or surgical labyrinthectomy. [47]

Corticosteroids (CS) have long been used to manage Meniere's disease, but their exact mechanism for disease alleviation is relatively uncertain. Glucocorticoid receptors have been shown to exist in the human inner ear, and several studies have suggested that these receptors influence the mechanisms of blood flow, fluid regulation and ion regulation, with recent evidence describing the latter two. [28] Corticosteroids have been shown to up-regulate aquaporin and ion channels in the inner ear and may have a positive effect on labyrinthine blood flow. [28]

In a study comparing the efficacy of combined therapy of intra-tympanic dexamethasone (ITD) and high dosage of betahistine (HDBH) in providing increased vertigo control compared to ITD alone in patients with definite unilateral Meniere's disease (MD); the results demonstrated that complete and substantial vertigo control was significantly higher among patients treated with a combination of HDBH and ITD [ITD protocol consisted of three consecutive daily injections while HDBH comprised 144mg/day (48mg tid)]. [48]

The intra-tympanic application of the ototoxic aminoglycoside, gentamicin, has shown promising

results as an ablative treatment for vertigo associated with Meniere's disease. However, in a study evaluating the efficacy and safety of intra-tympanic gentamicin and to specifically analyse the effect of this treatment on high and low hearing frequencies in patients with unilateral definite Meniere's disease, the results indicated that the number of vertigo spells per month decreased and the subjects experienced less tinnitus. [49] During follow-up care, there was an increase in hearing loss in the low (0.25-, 0.5-, 1-kHz) frequency range (13.3 dB). [49] There was no significant increase in hearing loss in the high (2-, 4-, 8-kHz) frequency ranges. [49] A clinically significant change in speech discrimination score was found in 50 % of the subjects. [49]

In a study of vestibular ablation with intra-tympanic gentamicin, patients underwent 0.5-0.8mL of gentamicin intra-tympanic application at a 30mg/mL concentration. [50] Vestibular ablation was confirmed by the absence of response on cervical vestibular evoked myogenic potentials but no response on caloric tests. Audiometry, electronystagmography with iced water and vestibular evoked myogenic potentials were performed in all the patients. High-grade vertigo control was due to complete saccular and horizontal canal ablation (no response to iced water in electronystagmography and no response on cervical vestibular evoked myogenic potentials). [50] In a group of Nigerian patients 0.75 ml of low-dose (40 mg/ml) buffered gentamicin was injected into the worse affected ear (patients were followed up every two months), and the regime was repeated only if subjective vertigo persisted, appeared to be highly effective. [51]

Conclusion

The referral centres where cases of Meniere's disease first present need to go beyond the use of anti-vertiginous medications. Aside from other medical treatments, intra-tympanic steroid injection is a simple, safe and reliable next level treatment option in Meniere's disease.

Conflict of Interest: None declared.

Meniere's disease

Funding: None required.

Publication History: Submitted 25-April 2017; Accepted 26-May 2017

References

1. García MLF, Segura CLS, Lesser JCC, Pianese CP. Endolymphatic Sac Surgery for Meniere's Disease - Current Opinion and Literature Review. *Int Arch Otorhinolaryngol* 2017; 21(2): 179-183.
2. Nakashima T, Pyykkö I, Arroll MA, Casselbrant ML, Foster CA, Manzoor NF *et al.* Meniere's disease. *Nat Rev Dis Primers* 2016; 2: 16028.
3. Simo H, Yang S, Qu W, Preis M, Nazzari M, Baugh R. Meniere's disease: Importance of socioeconomic and environmental factors. *Am J Otolaryngol* 2015; 36: 393-398.
4. Havia M, Kentala E, Pyykkö I. Prevalence of Meniere's disease in general population of Southern Finland. *Otolaryngol Head Neck Surg* 2005; 133: 762-768.
5. Tyrrell J, Whinney DJ, Taylor T. The cost of Meniere's disease: A novel multi-source approach. *Ear Hear.* 2016; 37: e202-e209.
6. Ibekwe TS, Fasunla JA, Ibekwe PU, Obasikene GC, Onakoya PA, Nwaorgu OG. Migraine and Meniere's disease: two different phenomena with frequently observed concomitant occurrences. *J Natl Med Assoc* 2008; 100(3): 334-338.
7. Ibekwe TS, Ijaluola GT. Meniere's disease: rare or underdiagnosed among Africans. *Eur Arch Otorhinolaryngol* 2007; 264(12): 1399-1403.
8. Okafor BC. Incidence of Meniere's disease. *J Laryngol Otol* 1984; 98(8): 775-779.
9. Somefun OA, Giwa OS, Bamgboye BA, Okeke-Igbokwe II, Azeez AA. Vestibular disorders among adults in a tertiary hospital in Lagos, Nigeria. *Eur Arch Otorhinolaryngol* 2010; 267(10): 1515-1521.
10. Yardley L, Dibb B, Osborne G. Factors associated with quality of life in Meniere's disease. *Clin Otolaryngol Allied Sci* 2003; 28: 436-441.
11. Anderson JP, Harris JP. Impact of Meniere's disease on quality of life. *Otol Neurotol* 2001; 22: 888-894.
12. Pullens B, Verschuur HP, van Benthem PP. Surgery for Meniere's disease. *Cochrane Database Syst Rev* 2013; 2: CD005395.
13. Kirby SE, Yardley L. Physical and psychological triggers for attacks in Meniere's disease: The patient perspective. *Psychother Psychosom* 2012; 81: 396-398.
14. Committee on Hearing and Equilibrium. Guidelines for the diagnosis and evaluation of therapy in Meniere's disease. *Otolaryngol Head Neck Surg* 1995; 113: 181-185.
15. Lopez-Escamez JA, Carey J, Chung WH, Goebel JA, Magnusson M, Mandalà M, *et al.*; Classification Committee of the Barany Society; Japan Society for Equilibrium Research; European Academy of Otolology and Neurotology (EAONO); Equilibrium Committee of the American Academy of Otolaryngology-Head and Neck Surgery (AAO-HNS); Korean Balance Society. Diagnostic criteria for Meniere's disease. *J Vestib Res* 2015; 25(1): 1-7.
16. Frejo L, Soto-Varela A, Santos-Perez S, Aran I, Batuecas-Caletrio A, Perez-Guillen V, *et al.* On Behalf of the Meniere's disease Consortium (MeDiC) Clinical Subgroups in Bilateral Meniere's disease. *Frontiers Neurol* 2016; 7: 182IN 1-10
17. Pathak S, Hatam LJ, Bonagura V, Vambutas A. Innate immune recognition of molds and homology to the inner ear protein, cochlin, in patients with autoimmune inner ear disease. *J Clin Immunol* 2013; 33(7): 1204-1215.
18. Hallpike CS, Cairns H. Observations on the pathology of Meniere's syndrome. *J Laryngol Otol* 1938; 53: 625-655.
19. Foster CA, Breeze RE. Endolymphatic hydrops in Meniere's disease: cause, consequence, or

- epiphenomenon? *Otol Neurotol* 2013; 34: 1210-1214.
20. <http://sunnybrook.ca/uploads/1/departments/otolaryngology/untitled.png>
21. Chiarella G, Petrolo C, Cassandro E. The genetics of Meniere's disease. *Appl Clin Genet* 2015; 8: 9-17.
22. Espinosa-Sanchez JM, Lopez-Escamez JA. Menière's disease. *Handb Clin Neurol* 2016; 137: 257-277.
23. Teggi R, Zagato L, DelliCarpini S, Citterio L, Cassandro C, Albera R *et al.* Genetics of ion homeostasis in Meniere's Disease. *Eur Arch Otorhinolaryngol* 2017; 274(2): 757-763.
24. Pan T, Zhao Y, Ding YJ, Lu ZY, Ma FR. The pilot study of type I allergic reaction in Meniere's disease patients. *Zhonghua Er Bi Yan Hou Tou Jing WaiKe Za Zhi* 2017; 52(2): 89-92.
25. Schmidt W, Sarran C, Ronan N, Barrett G, Whinney DJ, Fleming LE, *et al.* The Weather and Ménière's Disease: A Longitudinal Analysis in the UK. *Otol Neurotol* 2017; 38(2): 225-233.
26. van den Burg EL, van Hoof M, Postma AA, Janssen AML, Stokroos RJ, Kingma H, *et al.* An exploratory study to detect Meniere's disease in Conventional MRI Scans using Radiomics. *Frontiers Neurol* 2016; 7: 1901-1909.
27. Yoshida T, Sugimoto S, Teranishi M, Otake H, Yamazaki M, Naganawa S, *et al.* Imaging of the endolymphatic space in patients with Meniere's disease. *Auris Nasus Larynx* 2017; S0385-8146(17)30142-6.
28. Farhood Z, Lambert PR. The physiologic role of corticosteroids in Ménière's disease. *Am J Otolaryngol* 2016; 37(5): 455-458.
29. Wick CC, Manzoor NF, McKenna C, Semaan MT, Megerian CA. Long-term outcomes of endolymphatic sac shunting with local steroids for Meniere's disease. *Am J Otolaryngol* 2017; S0196-0709(17)30017-0.
30. Zhang D, Fan Z, Han Y, Lv Y, Li Y, Wang H. Triple semicircular canal plugging: a novel modality for the treatment of intractable Meniere's disease. *Acta Otolaryngol* 2016; 136(12): 1230-1235.
31. Zhang DG, Xu L, Han YC, Lyu YF, Luo JF, Li YW, *et al.* Simultaneous triple semicircular canal plugging and cochlear implantation in advanced Meniere's disease. *Zhonghua Er Bi Yan Hou Tou Jing WaiKe Za Zhi* 2017; 52(1): 25-30.
32. Alarcón AV, Hidalgo LOV, Arévalo RJ, Diaz MP. Labyrinthectomy and Vestibular Neurectomy for Intractable Vertiginous Symptoms. *Int Arch Otorhinolaryngol* 2017; 21: 184-190.
33. Silverstein H, Norrell H, Smouha E, Jones R. Combined retrolabretosigmoid vestibular neurectomy. An evolution in approach. *Am J Otol* 1989; 10(03): 166-169.
34. Setty P, Babu S, LaRouere MJ, Pieper DR. Fully Endoscopic Retrosigmoid Vestibular Nerve Section for Refractory Meniere Disease. *J Neurol Surg B Skull Base* 2016; 77(4): 341-349.
35. Canzi P, Manfrin M, Perotti M, Aprile F, Quagliari S, Rebecchi E, *et al.* Translabyrinthine vestibular neurectomy and simultaneous cochlear implant for Meniere's disease. *Acta Neurochir (Wien)* 2017; 159(1): 123-130.
36. Sargent EW, Liao E, Gonda RL Jr. Cochlear patency after transmastoid labyrinthectomy for Meniere's syndrome. *Otol Neurotol* 2016; 37(07): 937-939.
37. Mukherjee P, Eykamp K, Brown D, Curthoys I, Flanagan S, Biggs N, *et al.* Cochlear Implantation in Meniere's Disease With and Without Labyrinthectomy. *Otol Neurotol* 2017; 38(2): 192-198.
38. Liu B, Zhang S, Leng Y, Zhou R, Liu J, Kong W. Intratympanic injection in delayed endolymphatic hydrops. *Acta Otolaryngol* 2015; 135: 1016-1021.
39. Ferri E, Frisina A, Fasson AC, Armato E, Spinato G, Amadori M. Clinical Study Intratympanic

Meniere's disease

- Steroid Treatment for Idiopathic Sudden Sensorineural Hearing Loss after Failure of Intravenous Therapy. *ISRN Otolaryngol* 2012; ID 647271: 1-6.
40. <http://www.drkotb.com/myimages/Intratympanic%20injection.jpg>
41. Liu B, Leng YM, Shi H, Zhou RH, Liu JJ, Zhang S, *et al.* Modified titration intratympanic gentamicin injection for unilateral intractable Meniere's disease. *J Huazhong Univ Sci Technol Med Sci* 2015; 35: 747-751.
42. Liu B, Leng Y, Zhou R, Liu J, Liu D, Zhang, S *et al.* Intratympanic steroids injection is effective for the treatment of drop attacks with Meniere's disease and delayed endolymphatic hydrops: A retrospective study. *Medicine* 2016; 95: 52 1-4.
43. Patel M, Agarwal K, Arshad Q, Hariri M, Rea P, Seemungal BM, *et al.* Intratympanic methylprednisolone versus gentamicin in patients with unilateral Ménière's disease: a randomised, double-blind, comparative effectiveness trial. *Lancet*. 2016; 388(10061): 2753-2762.
44. Topf MC, Hsu DW, Adams DR, Zhan T, Pelosi S, Willcox TO, *et al.* Rate of tympanic membrane perforation after intratympanic steroid injection. *Am J Otolaryngol* 2017; 38(1): 21-25.
45. Lambert PR, Carey J, Mikulec AA, LeBel C. Otonomy Ménière's Study Group. Intratympanic Sustained-Exposure Dexamethasone Thermosensitive Gel for Symptoms of Meniere's Disease Randomized Phase 2b Safety and Efficacy Trial. *Otol Neurotol* 2016; 37(10): 1669-1676.
46. Vlastarakos PV, Iacovou E, Nikolopoulos TP. Is gentamicin delivery via sustained-release vehicles a safe and effective treatment for refractory Meniere's disease? A critical analysis of published interventional studies. *Eur Arch Otorhinolaryngol* 2017; 274(3): 1309-1315.
47. Atrache A, Attrache N, Krstulovic C, Pérez Guillen V, Morera Pérez C, Pérez Garrigues H. Response Over Time of Vertigo Spells to Intratympanic Dexamethasone Treatment in Meniere's Disease Patients. *J Int Adv Otol* 2016; 12(1): 92-97.
48. Albu S, Nagy A, Doros C, Marceanu L, Cozma S, Musat G, *et al.* Treatment of Meniere's disease with intratympanic dexamethasone plus high dosage of betahistine. *Am J Otolaryngol* 2016; 37(3): 225-230.
49. Sam G, Chung DW, van der Hoeven R, Verweij S, Becker M. The effect of intratympanic gentamicin for treatment of Ménière's disease on lower frequency hearing. *Int J Clin Pharm* 2016; 38(4): 780-783.
50. Celis-Aguilar E, Hinojosa-González R, Vales-Hidalgo O, Coutinho-Toledo H. Refractory episodic vertigo: role of intratympanic gentamicin and vestibular evoked myogenic potentials. *Braz J Otorhinolaryngol* 2016; 82(6): 668-673.
51. Olusesi AD, Hassan SB, Oyeyipo Y, Ukwuije UC, Oyeniran O. Chemical labyrinthectomy for the worse ear of adult Nigerians with bilateral Meniere's disease: preliminary report of treatment outcomes. *Eur Arch Otorhinolaryngol* 2015; 272(6): 1383-1387.