

Fascioliasis: A Rare Parasitic Infection-Mimicking Tumor in the Liver: Report of Two Cases

Emine ŞAMDANCI¹, Nurhan ŞAHİN¹, Adile Ferda DAĞLI², Ayşe Nur AKATLI¹, Nasuhi Engin AYDIN³

Department of Pathology, ¹Inönü University, Faculty of Medicine, MALATYA, TURKEY, ²Fırat University, Faculty of Medicine, ELAZIĞ, TURKEY, ³Katip Çelebi University, Faculty of Medicine, İZMİR, TURKEY

ABSTRACT

Fascioliasis is a rarely encountered parasitic infection in Turkey that mainly affects the liver and bile ducts. Other defined localizations of the parasite are the lungs, gastrointestinal system, and subcutaneous fatty tissue. Two cases of female patients who presented to the hospital with abdominal pain and whose physical examination and laboratory findings were normal except peripheral eosinophilia, were detected to have liver masses with necrotic areas. Segmental hepatectomies were performed in both cases with the preliminary diagnosis of liver tumors. Upon microscopic examinations of the resection materials, necrotic granulomatous inflammation with eosinophilic reaction at the periphery and the parasite (*Fasciola hepatica*) were seen. Both cases were reported to be fascioliasis according to these findings. Two cases of fascioliasis mimicking malignancy in the liver are presented here together with literature findings.

Key Words: Fascioliasis, Liver, Hepatectomy, Charcot-Leyden crystals

INTRODUCTION

Fascioliasis is a rare parasitic infection with a very diffuse spread in tropical, subtropical, and temperate climate localizations of the world and is reported in countries that raise sheep and bovines (1). It is more common in autumn and winter in the form of scattered cases in humans. In Turkey, it is most frequently seen in Antalya, Isparta, Burdur, Afyon, Konya, and its surroundings and the lakes region (Göller Bölgesi), although the infection has no regional features (2, 3). Its adult forms are 2-3 cm in length. The definitive hosts are, on the other hand, humans, sheep, goats, bovines, calves, and rabbits. The adult form of *Fasciola hepatica* lives in the liver and bile ducts of the definitive host. Eggs are excreted with the feces of the host. Ciliated miracidia emerge from the eggs in water and infect water snails, which are intermediate hosts. The cercariae leave water snails and attach to a water deposit (such as watercress) and convert into metacercariae cysts and infect humans through the ingestion of plants that are not washed well (4). Because of this, it is suggested that this infection may be seen more commonly in humans, since nature oriented nutrition has gained popularity (4).

CASE REPORTS

Case 1: A 26-year-old female patient presented with abdominal pain, nausea and vomiting. Upon physical examination, a mass was detected in the right upper

quadrant. Abdominal computed tomography (CT) revealed a multicystic mass, 6 cm in diameter in segment 5 of the liver. The gallbladder was found to be hydropic and adhesions were observed. The patient underwent a liver segmentectomy with a preliminary diagnosis of a tumor. Upon macroscopic examination of the material, a multicystic tumor-like lesion with patchy solid areas, 6 cm in diameter in the cross sections of the liver measuring 9x6x4cm was seen (Figure 1).

Case 2: A 52-year-old female patient presented with abdominal pain, nausea, and vomiting. Multiple hypodense lesions, including necrotic areas in segment 6 of the liver were seen in the abdominal CT. Positron emission tomography (PET/CT) was performed. The PET/CT concluded that the lesions in the liver and colon could be malignant. A segment 6 resection, right hemicolectomy, and cholecystectomy were performed. The macroscopic examination revealed many mass lesions that were necrotic and cystic in nature, with the largest diameter being 2.5 cm in the cross sections of the liver. They presented with multiple foci, were necrotic in the middle, each measured approximately 1 cm in diameter, and were seen in the serosa of the colon. Tumor markers were within normal ranges in both cases.

The microscopic examination in both cases revealed structures of granuloma in the shape of necrotic tracts comprised of fibrin, erythrocyte, and eosinophils with

(*Türk Patoloji Derg* 2019, 35:58-60)

Received : 02.03.2016 Accepted : 06.06.2016

Correspondence: Emine ŞAMDANCI

Inönü Üniversitesi Tıp Fakültesi, Patoloji Anabilim Dalı,
MALATYA, TURKEY

E-mail: esamdanci@gmail.com Phone: +90 422 341 06 60 / 3908

eosinophilic reaction in the peripheral region (Figure 2). In addition, a parasite was detected in the lumen of the necrotic tract in one of the cases (Figure 3). Additionally, Charcot-Leyden crystals were observed in the necrotic debris (Figure 4).

With the histomorphological findings, the segmental liver materials in both cases were reported as mass lesions due to *Fasciola hepatica* infection.

DISCUSSION

Fascioliasis is easy to diagnose in countries such as Egypt and Bolivia where the infection is endemic; however, it is difficult to diagnose the disease in countries like Turkey, where cases are only observed sporadically (4). As for the

clinical diagnosis of the disease, one must know the disease and then suspect for it. Its seroprevalence is reported to be 2.78% in the eastern part of Turkey, independent of age, education, and socioeconomic status. In Turkey, it is most frequently seen in Antalya, Isparta, Burdur, Afyon, Konya, and around the lakes region (Göller Bölgesi) (2, 3).

The final hosts of fascioliasis are humans, sheep, goats, bovines, calves, and rabbits. The adult form of *Fasciola hepatica* lives in the liver and bile ducts of the final host and the egg is excreted with the feces. Ciliated miracidia emerge from the eggs in the water and infect water snails or freshwater gastropods, which are intermediate hosts. Cercariae leave the water snails and attach to a water deposit (such as watercress) and convert into metacercariae cysts (4).

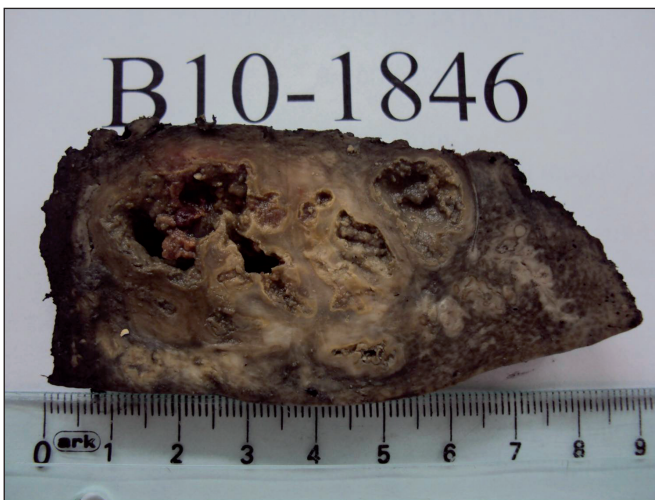

Figure 1: A lesion with patchy solid segments, including multicystic necrotic foci.

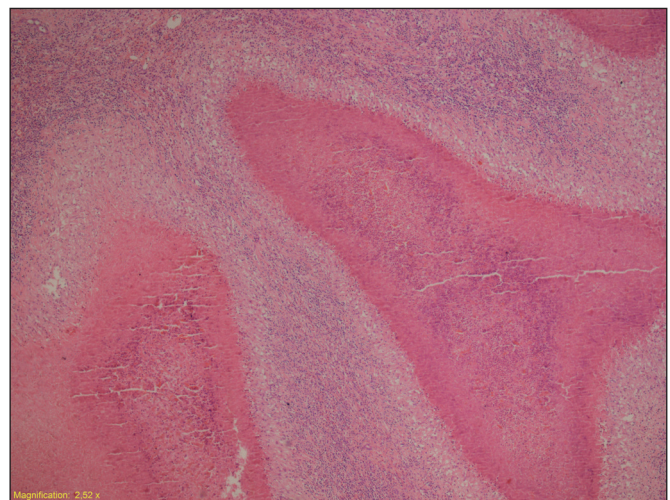


Figure 2: Tract-shaped granulomas, containing necrotic material in their lumens (H&E; x40).

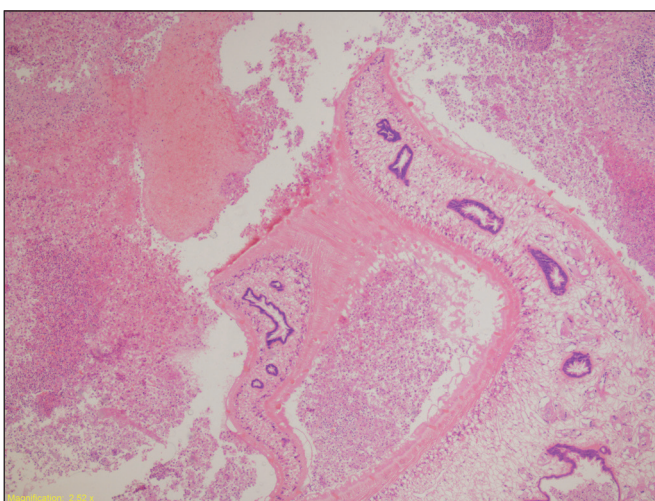


Figure 3: Parasite in the necrotic tract (H&E; x40).

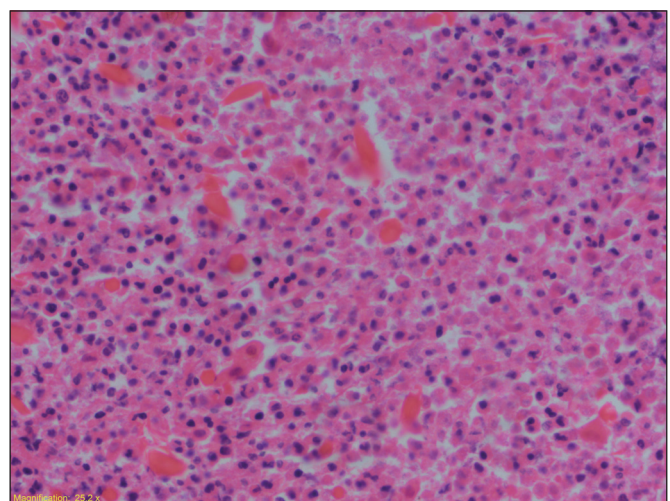


Figure 4: Charcot-Leyden crystals in the necrotic debris (H&E; x400).

The metacercariae emerge from the cysts when humans eat watercress and migrate to the peritoneal cavity through the small bowel wall and penetrate the liver capsule and enter the liver. The larvae reach the main bile ducts and start to spawn after their conversion to adult form (4, 5). Another way to reach the hepatic parenchyma is through the blood or lymphatic circulation (5).

General symptoms are abdominal pain, nausea, vomiting, weight loss, fever, jaundice, tenderness in the location of the liver, and eosinophilia (6). Both of the current cases had abdominal pain. No fever was detected and both patients had peripheral eosinophilia.

CT is helpful in the diagnosis of 90% of the cases with fascioliasis (7). Some characteristic findings are multiple and small hypodense lesions with indefinite borders, microabscesses foci of demonstrating branching and general subcapsular localization of the lesions (8, 9). Although the CT findings of the two cases are similar, due to the rarity of fascioliasis in this region and the absence of clinical suspicion, both were evaluated to be tumors.

The histomorphological appearance is quite characteristic. Granuloma structures in the shape of necrotic tracts comprised of fibrin, erythrocyte, and eosinophils is typical. Eosinophilic infiltration is seen in the periphery of the granulomas. The parasite can be observed in the lumen of the necrotic tract in fortunate cases. In addition, Charcot-Leyden crystals are commonly seen in the necrotic debris (10). The detection of the parasite in one of the cases presented here specified the diagnosis and made it easier to diagnose the case. Specific histomorphological findings of the other case also were diagnostic. Pathologic differentiation from other causes of inflammation (such as tuberculosis or hydatid cyst) is important; however, it is quite easy. The characteristic morphology of hydatid cyst and the absence of necrotic tract formation in the granulomas due to bacterial infections such as tuberculosis are diagnostic.

Two rare cases of fascioliasis that created tumor-like lesions in the liver and were easy to histomorphologically diagnose were presented herein.

REFERENCES

1. Bassily S, Iskander M, Youssef FG, el-Masry N, Bawden M. Sonography in diagnosis of fascioliasis. *Lancet*. 1989; 1:1270-1.
2. Kaplan M, Kuk S, Kalkan A, Demirdag K, Ozdarendeli A. Fasciola hepatica seroprevalence in the Elazig region. *Mikrobiyol Bul*. 2002; 36:337-42.
3. Yilmaz H, Godekmerdan A. Human fasciolosis in Van province, Turkey. *Acta Trop*. 2004; 92:161-2.
4. Cook GC. Manson's Tropical Diseases. 22nd ed. Gordon C. Cook, editor. London: Saunders; 2009
5. Ulger BV, Kapan M, Boyuk A, et al. Fasciola hepatica infection at a University Clinic in Turkey. *J Infect Dev Ctries*. 2014; 8: 1451-5.
6. Maekell EK, John DT, Krotoski WA. Medical parasitology. 8th ed. Philadelphia: WB Saunders;1999: 203-5.
7. Losada H, Hirsch M, Guzmán P, et al. Fascioliasis simulating an intrahepatic cholangiocarcinoma-Case report with imaging and pathology correlation. *Hepatobiliary Surg Nutr*. 2015; 4: E1-7.
8. Han JK, Choi BI, Cho JM, et al. Radiological findings of human fascioliasis. *Abdom Imaging*. 1993;18:261-4.
9. Ince V, Ara C, Koç C, Ersan V, Barut B. Fasciola hepatica mimicking malignancy of the liver and colon: Three case reports. *J Turgut Ozal Med Cent*. 2010;17:207-10.
10. Price TA, Tuazon CU, Simon GL. Fascioliasis: Case reports and review. *Clin Infect Dis*. 1993;17:426-30.