

Clinical significance of positive *Raoultella ornithinolytica* and *Staphylococcus hominis* cultures in a post lobectomy patient. A case report

Evangelina Papakanderaki, Konstantinos Kanakakis, Sotirios Goule, Maria Chounti, Panagiotis Hountis

Department of Cardiothoracic Surgery, Athens Naval and Veterans Hospital, Athens, Greece

Abstract

Raoultella ornithinolytica is an encapsulated, Gram-negative, non-motile aerobic rod which was reclassified from *Klebsiella* genus belonging to the family of Enterobacteriaceae. It is a rare human infection and few cases have been reported in post thoracotomy patients. Here we present a case of a left lower lobectomy patient that was complicated by pleural effusion, high fever with positive sputum cultures of *Raoultella ornithinolytica* and positive pleural fluid cultures of *Staphylococcus hominis*. The disease is related with aquatic life poisoning. There are few cases reported and even fewer postoperatively. The infection is rare in humans therefore the bacteria is still underreported.

Introduction

Raoultella ornithinolytica (RO) is an encapsulated, Gram-negative, nonmotile aerobic rod which belongs to the Enterobacteriaceae family. Its name is a result of the ability of *R. ornithinolytica* to produce ornithine decarboxylase. It was assorted from *Klebsiella* and it is related with fish poisoning and aquatic environments. These bacteria are found in the natural environment: plants, water, soil and insects. RO is a rare human infection and only small number of patients have been reported postoperatively. Fewer cases are reported that relate to pulmonary challenged patients [1]. It is observed that

the effects of RO are greater and more frequent in immunosuppressed and especially in oncological patients. On the other hand coagulase negative staphylococci (CoNS) – as *Staphylococcus hominis* (SH) are a diverse group of Gram-positive cocci, commonly isolated from human skin as normal flora, and recently recognised as a significant cause of nosocomial bloodstream infections. In-dwelling medical devices and critically ill patients have been recognised as the main parameters that rise the number of reported cases. CoNS account for 12%-80% mortality in hospitalised patients and also 16% morbidity has been associated with CoNS bacteraemia [2.] Here we present a case of postoperative fever and positive sputum culture of RO as well as SH cultures of pleural fluid without proven bacteremia, after left lower lobectomy due to non-small cell lung cancer (NSCLC).

Case Report

A 75-year-old male patient with a lung tumor in the inferior left lobe was admitted to our hospital with hemoptysis. He had a history of heavy smoking for about 50 years (100 pack/years). The patient had a history of femoral-popliteal by pass in the right leg and a dual-chamber, rate-modulated pacemaker (DDDR) three and two years ago respectively. During the diagnostic workup an irregular pulmonary left lower shadow possibly representing a mass was identified. Fine needle biopsy (FNB) under CT guidance that was performed was positive for NSCLC. A PET-CT scan showed that there were no other suspicious foci but a dental area was illuminated and this was clinically correlated with an infectious process (Figure 1). Antibiotics were started blindly and after a 7-day course on Amoxicilline clavulanate 625 mgx3 we performed a left lower lobectomy with a double endotracheal tube. He had an uneventful postoperative period for 3 days and in the 4th post-operative day all chest tubes were removed. In the 6th postoperative day the patient had progressively advanced high temperature up to 38°C accompanied with cough, malaise and dyspnea. His ability to mobilize himself was deteriorated. His laboratory exams showed WBC 11.43 K/μl (83% neutrophils) and a CRP 271 (0-7 mg/l). Due to enteric paresis, a gas tube and enema were inserted. Samples were taken from sputum and pleural fluid for microbiological analysis. The sputum sample was positive for *Raoultella ornithinolytica*, whereas the pleural fluid sample was positive for *Staphylococcus hominis*. The treatment was changed to Meropenem 1 grx3 and Ciprofloxacin 400 mgx3 in relation with the antibiogram. Moreover, a drainage tube was inserted to extract the pleural effusion (Figure 2). The patient was progressively improving and was discharged in the 20th postoperative day, having a good clinical condition. The treatment continued with Ciprofloxacin 500 mgx2. Blood cultures were negative.

Corresponding Author: Panagiotis G. Hountis, Department of Cardiothoracic Surgery, Athens Naval and Veterans Hospital Deinokratous 70, 11521 Athens, Greece. Tel. +30.6986004089 - Fax +30.210.2133437.
E-mail: panos_hountis@hotmail.com

Key words: *Raoultella ornithinolytica*; *Staphylococcus hominis*; lung cancer; lobectomy; thoracic surgery.

Received for publication: 19 August 2017

Accepted for publication: 28 January 2018

©Copyright E. Papakanderaki et al., 2018

Tipografia PI-ME Editrice, Italy

Monaldi Archives for Chest Disease 2018; 88:885

doi: 10.4081/monaldi.2018.885

This article is distributed under the terms of the Creative Commons Attribution Noncommercial License (by-nc 4.0) which permits any noncommercial use, distribution, and reproduction in any medium, provided the original author(s) and source are credited.

Discussion

In 1989, Sakazaki *et al.* described the histamine-producing ornithine-positive *Klebsiella oxytoca* and renamed it '*Klebsiella ornithinolytica*' [3]. This unique bacterium was later named as RO; Kanki *et al.* concluded that *R. ornithinolytica* strains and *R. planticola* are isolated at high frequencies from raw fish and have always been the most important histamine-producing bacteria causing histamine poisoning, so-called 'Scombroid Fish Poisoning'. RO has also been isolated from the gut of fish such as tuna, bonito, sardine, and mackerel, ticks, termites and from estuarine water. Its ability to colonize the inner surfaces of indwelling catheters is a major cause of hospital-acquired infections. These mechanisms as well as its ability to form biofilms could play an important role in the environmental dissemination of this bacterium.

With respect to antibiotic susceptibility, RO has been known to be resistant to ampicillin, similar to our findings, and produces chromosomally-encoded class A beta-lactamases [4].

RO has been reported in various different clinical situations mainly in immunosuppressed patients. Some immunocompetent cases of *Roultella ornithinolytica* bacteremia [5] have also been reported. Its isolation must always be considered as an important complication although the prognosis of the patients is quite satisfactory.

In a study by Haruki *et al.* [5] the most common infectious focus was biliary infection in elderly patients with a history of biliary inter-

vention or malignancy. These patients were considered to be at a great risk for this particular infection. Septic arthritis and sepsis in general [6,7] is possibly a major clinical consequence of this bacterial infection [8,9]. Children, especially in immunocompromised conditions are vulnerable in manifesting clinically significant complicated infections [10].

In a retrospective study by Boattini M. *et al.* *Raoultella spp.* were deemed responsible for clinical infections with RO presented as cystitis in 36% of the cases and pneumonia in 24% [11]. The findings of Chun's *et al.* study [12] were that *R. ornithinolytica* bacteremia occurs mainly in patients with underlying malignancies [13]. The overall outcome was not favorable, despite favorable antimicrobial susceptibility test results. The findings of this study contradicted those of other studies that demonstrated that infections from *Raoultella* species have good prognoses.

In a retrospective study from four university hospital centres and 187 *R. ornithinolytica* isolates this was associated with diseases such as osteomyelitis, meningitis, cerebral abscess, mediastinitis, pericarditis, conjunctivitis, and otitis [14,15]. Also, a case report has been reported after pancreaticoduodenectomy [16] as well as in diabetic limbs [17]. It has been also isolated by human saliva and in oral microbiota of healthy patients as well as dentin of infected root canals [18]. Regarding the several conditions studied, there was a higher prevalence in patients with gastritis and patients with periodontal disease [19].

SH on the other hand has been traditionally considered as a saprophytic bacterium of low virulence and a part of the normal human skin flora. Although studies have shown that clinical criteria apply as well and in cases that patient condition deteriorates it should be treated promptly after antibiotic susceptibility testing. Oncological patients, immunosuppressed and patients in ICU as well as septic conditions may predispose to the high possibility that this innocent bacterium may cause serious complications [20]. Our patient was diagnosed immediately after tube removal with pleural effusion and high fever without any sign of rashes or other histamine reaction. We suppose that this infection might be attributed to a residual contaminated parapneumonic fluid. This hypothesis is further proved by the finding of a collection in the pleural cavity, when symptoms first appeared, without any lung involvement. *R. ornithinolytica* should never be considered simply a saprophytic bacterium that occasionally contaminates bronchial lavage or other deep respiratory samples or surgical sites. Regarding our patient if this infection was ignored it might have led to devastating consequences. To the best of our knowledge such a combination in a post lobectomy patient is the first to be reported in the literature.

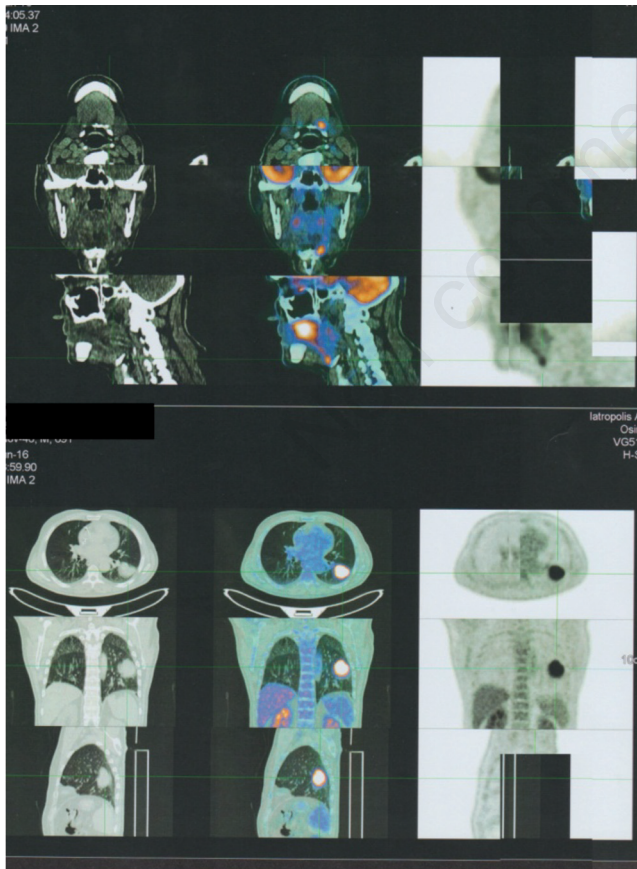


Figure 1. Positron Emission Tomography-CT scan of the patient with the inflammatory loci in the dental area as well as the neoplastic loci in the lung.

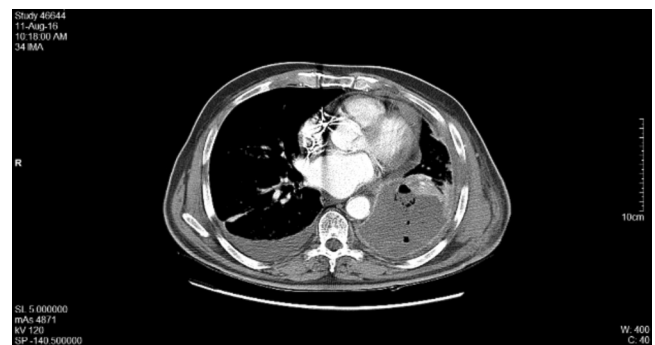

Figure 2. Computerized tomography of the lung showing the post-operative pleural effusion of the left hemithorax.

References

1. Sękowska A, Dylewska K, Gospodarek E, Bogiel T. Catheter-related blood stream infection caused by *Raoultella ornithinolytica*. *Folia Microbiol (Praha)* 2015;60:493-5.
2. Gautam V, Sethuraman N, Kaur R, et al. Changing epidemiology of coagulase-negative staphylococci in normal flora of skin. *Indian J Med Microbiol* 2017;35:277-8.
3. Sakazaki R, Tamura K, Kosako Y, Yoshizaki E. *Klebsiella ornithinolytica* sp. nov., formerly known as ornithine-positive *Klebsiella oxytoca*. *Curr Microbiol* 1989;18:201-6.
4. Kanki M, Yoda T, Tsukamoto T, Shibata T. *Klebsiella pneumonia* produces no histamine: *Raoultella planticola* and *Raoultella ornithinolytica* strains are histamine producers. *Appl Environ Microbiol* 2002;68:3462-6.
5. Haruki Y, Hagiya H, Sakuma A, et al. Clinical characteristics of *Raoultella ornithinolytica* bacteremia: a case series and literature review. *J Infect Chemother* 2014;20:589-91.
6. Sueifan M, Moog V, Rau E, Eichenauer T. Sepsis caused by *Raoultella ornithinolytica* in an immunocompetent patient. *Anaesthesist* 2016;65:129-33.
7. Kaya S, Bayramoğlu G, Sönmez M, Köksal İ. *Raoultella ornithinolytica* causing fatal sepsis. *Braz J Infect Dis* 2015;19:230-1.
8. Seng P, Theron F, Honnorat E, et al. *Raoultella ornithinolytica*: An unusual pathogen for prosthetic joint infection. *ID Cases* 2016;25;5:46-8.
9. Venus K, Vaithilingam S, Bogoch II. Septic arthritis of the knee due to *Raoultella ornithinolytica*. *Infection* 2016;44:691-2
10. Yamakawa K, Yamagishi Y, Miyata K, et al. Bacteremia caused by *Raoultella ornithinolytica* in two children. *Pediatr Infect Dis J* 2016;35:452-3.
11. Boattini M, Almeida A, Cardoso C, et al. Infections on the rise: *Raoultella* spp., clinical and microbiological findings from a retrospective study. *Infect Dis (Lond)* 2016;48:87-91.
12. Chun S, Yun JW, Huh HJ, Lee NY. Clinical characteristics of *Raoultella ornithinolytica* bacteremia. *Infection* 2015;43:59-64.
13. Hadano Y, Tsukahara M, Ito K, et al. *Raoultella ornithinolytica* bacteremia in cancer patients: report of three cases. *Intern Med* 2012;51:3193-5.
14. Seng P, Boushab BM, Romain F, et al. Emerging role of *Raoultella ornithinolytica* in human infections: a series of cases and review of the literature. *Int J Infect Dis* 2016;45:65-71.
15. Schmutz N, Adler T, Schelhorn N, et al. Postoperative osteomyelitis of a distal phalanx caused by *Raoultella Ornithinolytica*. *Handchir Mikrochir Plast Chir* 2016;48:175-8.
16. Bhatt P, Tandel K, Das NK, Rathi KR. New Delhi metallo- β -lactamase producing extensively drug resistant *Raoultella ornithinolytica* isolated from drain fluid following Whipple's pancreaticoduodenectomy. *Med J Armed Forces India* 2015;71(S2):S609-11.
17. Kabbara WK, Zgheib YR. Diabetic foot infection caused by *Raoultella ornithinolytica*. *Am J Health Syst Pharm* 2015;15;72:2147-9.
18. Nakajo K, Nakazawa F, Iwaku M, Hoshino E. Alkali-resistant bacteria in root canal systems. *Oral Microbiol Immunol* 2004;19:3904.
19. Heggendorf FL, Gonçalves LS, Dias EP, et al. Detection of sulphate-reducing bacteria in human saliva. *Acta Odontol Scand* 2013;71:1458-63.
20. Pradipta IS, Sodik DC, Lestari K, et al. Antibiotic resistance in sepsis patients: evaluation and recommendation of antibiotic use. *N Am J Med Sci* 2013;5:344-52.