

# AngioJet® rheolytic thrombectomy for acute superficial femoral artery stent or femoropopliteal by-pass thrombosis

## *Trombectomia reolitica con AngioJet® per trombosi di stent della arteria femorale superficiale o di bypass femoropopliteo*

Francesco Borgia<sup>1</sup>, Luigi Di Serafino<sup>1</sup>, Anna Sannino, Giuseppe Gargiulo, Gabriele Giacomo Schiattarella, Mario De Laurentis, Laura Scudiero, Cinzia Perrino, Federico Piscione, Giovanni Esposito, Massimo Chiariello

**ABSTRACT:** *AngioJet® rheolytic thrombectomy for acute superficial femoral artery stent or femoropopliteal by-pass thrombosis. F. Borgia, L. Di Serafino, A. Sannino, G. Gargiulo, G.G. Schiattarella, M. De Laurentis, L. Scudiero, C. Perrino, F. Piscione, G. Esposito, M. Chiariello.*

Thrombosis of superficial femoral artery (SFA) nitinol stents or polytetrafluoroethylene (PTFE) femoropopliteal by-pass grafts after discontinuation of antiplatelet therapy is an emergent clinical challenge of acute limb ischemia (ALI), requiring immediate percutaneous intervention. Currently, there is no evidence-based approach for the management of such complications. We describe the cases of two patients presenting with ALI due to nitinol stent thrombosis after discontinuation of antiplatelet therapy and the case of a patient presenting with ALI due to PTFE femoropopliteal graft thrombosis in which limb salvage was obtained by AngioJet® rhe-

olytic thrombectomy and re-stenting. In both cases, the thrombus was successfully removed using the Possis AngioJet® mechanical thrombectomy catheter and percutaneous transluminal angioplasty (PTA) was performed to recanalize two femoropopliteal nitinol stents and a femoropopliteal PTFE graft. In both cases, optimal angiographic result was obtained. To the best of our knowledge, these are the first three cases reporting the use of the AngioJet rheolytic thrombectomy in ALI due to stent or graft thrombosis. Taken together, these cases suggest that AngioJet® rheolytic thrombectomy might represent a novel effective strategy in the percutaneous treatment of stent or graft thrombosis determining ALI.

**Keywords:** *acute limb ischemia, AngioJet® rheolytic thrombectomy, stent thrombosis.*

*Monaldi Arch Chest Dis 2010; 74: 76-81.*

Division of Cardiology, Federico II University of Naples, Italy.

<sup>1</sup> First two authors equally contributed to this work.

Corresponding author: Giovanni Esposito MD, PhD; Division of Cardiology; Federico II University; Via Pansini, 5; I-80131 Naples; Italy; Tel: +39 081 746 2216; Fax: +39 081 746 2223; E-mail address: [espogiov@unina.it](mailto:espogiov@unina.it)

## Introduction

Percutaneous transluminal procedures represent an increasingly used and effective treatment of peripheral artery disease (PAD) [1, 2]. The introduction of self-expanding nitinol stents allowed treatment of long lesions/occlusions of the superficial femoral arteries (SFA) improving the long-term results of the endovascular revascularization, with primary patency in SFA occlusions up to 80% at 2 years follow-up [3-5]. Antiplatelet therapy with acetylsalicylic acid is indicated for all patients with PAD undergoing peripheral transluminal angioplasty, while dual antiplatelet therapy, associating clopidogrel with aspirin, is suggested in clinical practice as antithrombotic therapy after peripheral stent implantation. In particular, dual antiplatelet therapy is particularly recommended in high-risk patients with lesions in the femoropopliteal segments and in the smaller diameter tibial arteries [6-8]. SFA nitinol stent thrombosis after discontinuing antiplatelet therapy, although uncommon, is an urgent clinical

complication of acute limb ischaemia (ALI), necessitating immediate percutaneous intervention.

Rheolytic thrombectomy (RT) with AngioJet® (Possis Medical, Inc., Minneapolis, MN, USA) has been previously approved by the Food and Drug Administration for the treatment of acute thrombosis of venous grafts and native coronary arteries. The AngioJet® system consists of a drive unit control console, a pump set and an AngioJet® spiroflex rapid exchange rheolytic thrombectomy catheter. The latter is a dual lumen, sterile, single-use catheter designed to remove thrombi from coronary conduits. High velocity saline jets directed back into the catheter create a localized low-pressure zone at the distal tip (Bernoulli principle), which results in the suction, break-up and removal of thrombus through the outflow lumen.

During percutaneous transluminal coronary angioplasty (PTCA) of venous grafts, RT has been shown to be safe and its use has significantly improved angiographic results, without increasing mortality [9]. Conversely, data regarding the use of

this procedure in native coronary artery are controversial and while one randomized study led in a high volume center (Florence trial) showed the same results obtained for venous grafts [10], Ali *et al.* [11] demonstrated neither an improvement of angiographic results nor an improvement of the mortality by the RT.

Despite no randomized clinical trials support the utility of AngioJet® in other districts, RT could be potentially used during percutaneous transluminal angioplasty (PTA) of other vessels, in particular of femoro-popliteal arteries. Indeed, here we describe the cases of three patients presenting with acute limb ischemia due to nitinol stent or PTFE femoro-popliteal graft thrombosis, in which limb salvage was obtained by AngioJet rheolytic thrombectomy and re-stenting.

The patients were admitted to our Department due to severely reduced walking capacity, rest pedal pain with or without ulcer toe, pointing out the diagnosis of ALI. All patients were aged 73±1 years, presented hypertension and hypercholesterolemia. Two patients had rheumatoid arthritis and history of previous PTA and stent implantation for total occlusion of SFA, while one patient presented a history of right femoro-popliteal PTFE by-pass for ALI followed by PTA and stent implantation of the distal anastomosis.

After the first procedure, all patients were discharged with optimal dual antiplatelet therapy excepted for the second patient who referred history of ASA allergy. Because of the onset of other clinical conditions (see below), two patients discontinued the antiplatelet therapy during the follow-up and presented stent thrombosis which was successfully removed using the Possis AngioJet® catheter. To the best of our knowledge, these are the first three reports on the use of the AngioJet® rheolytic thrombectomy in ALI for stent or PTFE graft thrombosis.

## Case Presentation

### Patient 1

A 72-year-old woman with hypertension, hypercholesterolemia and rheumatoid arthritis was admitted to our Department complaining severely reduced walking capacity (maximum walking distance < than 20 meters), rest right pedal pain and ulcer toe, suggesting the diagnosis of critical lower limb ischemia. At that time the patient's therapy consisted of atorvastatin 10 mg, ASA 175 mg, bisoprolol 2.5 mg, valsartan 160 mg and methotrexate 2.5 mg/die. Autoimmunity evaluation on blood samples showed increased IgG anti-cardiolipin levels in the absence of IgM autoantibodies. Duplex ultrasound demonstrated the occlusion of the proximal right superficial femoral artery. According to symptoms and clinical signs, the patient was classified as Fontaine's stage IV.

Peripheral angiography confirmed the proximal occlusion of SFA (TASC classification type C lesion). After heparin infusion and using crossover technique, PTA with stent implantation of the SFA and popliteal artery was performed (nitinol stents Xpert 8.0x40 mm and 2 Protégé Everflex 7.0x120 mm and 6.0x120 mm), providing an optimal angio-

graphic result and a good runoff to distal vessels. The patient received a loading dose of clopidogrel (300 mg) P.O. and was discharged on dual antiplatelet therapy (ASA 100 mg/die plus clopidogrel 75 mg/die) in addition to her homing therapy. Duplex ultrasound performed two days later showed normal flow of treated segments and downstream.

Seven days after the procedure, the onset of gastrointestinal bleeding (Hb 8.70 g/dl) induced her primary care physician to stop her dual antiplatelet medication. After 15 days, the patient returned to our Department for rest pain and right ALI. Right pedal pulse was absent. The peripheral angiography showed acute stent thrombosis from the proximal right SFA up to popliteal segment (Figure 1, A and B). Thus, anticoagulation with heparin was immediately started and several attempts to open the occluded stent were performed. First, a 0.035-inch J-shaped Terumo stiff guide-wire was used to cross the thrombotic occlusion and then multiple dilatations of the stents within the SFA were performed with a 3.0x40 mm balloon catheter (Amphirion), without any good result. Thus, we decided to operate a mechanical thrombectomy using the Possis AngioJet® catheter (Figure 1C). As a result, mechanical aspiration of the thrombus allowed a good angiographic runoff and then two self-expandable stents (Dyna Link 6.0x100 mm and Protégé Everflex 6.0x60.0 mm) were implanted. After the procedure, the patient reported that pain disappeared and control angiography of the treated arterial segment revealed an optimal angiographic result and a good runoff to patent vessels below the knee (Figure 1, D-E-F). At 1 year follow-up, the ulcer on her toe healed and no stenotic lesions were found at colour Doppler ultrasound.

### Patient 2

A 74-year-old woman with hypercholesterolemia, rheumatoid arthritis and a history of ASA allergy was admitted to our Department with rest pedal pain and duplex ultrasound evidence of left proximal SFA occlusion (Fontaine's stage III). Peripheral angiography confirmed the proximal occlusion of SFA (TASC Classification type C). After heparin infusion, using crossover technique, PTA with stent implantation in the left SFA and popliteal artery was performed (2 nitinol stents, Protégé Everflex 6.0x120 mm) obtaining a good angiographic result. The patient received a loading dose with clopidogrel (300 mg) P.O. and she was discharged on clopidogrel (75 mg/die) without ASA.

At 2-month follow-up, duplex ultrasound scan showed a normal flow through the stents and the downstream segments. The patient referred an improvement of walking capacity and the disappearance of rest symptoms until 4 months later when she returned to our Department for ALI. Notably, patient never stopped antiplatelet therapy with clopidogrel. Pedal pulses were absent and duplex ultrasound indicated an acute thrombosis in the distal SFA/popliteal segment. The angiography confirmed an occlusion of the left SFA 4 cm before the previous implanted stent, up to the upper border of patella (the total length of thrombotic lesion was approximately 20 cm; Figure 2, A and B).

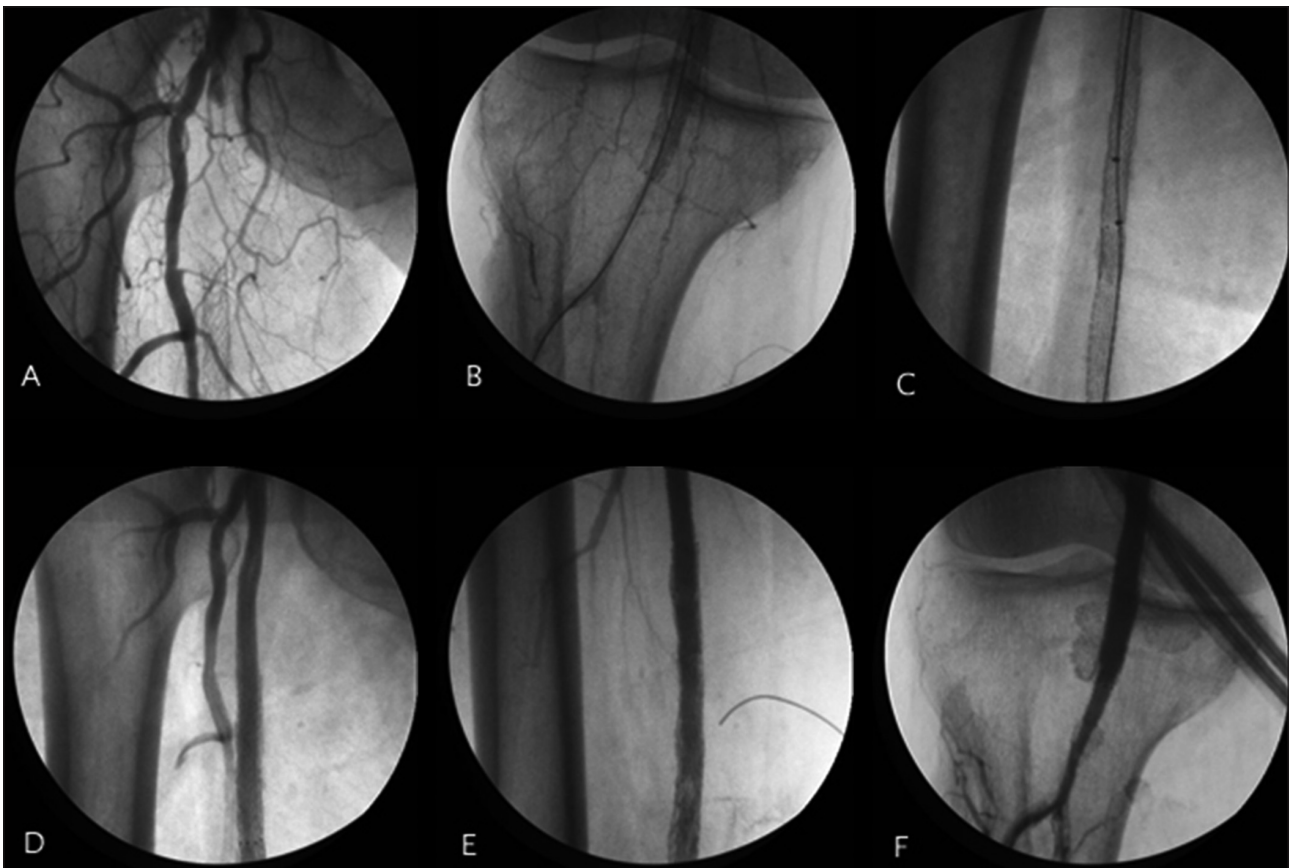


Figure 1. - Proximal thrombotic occlusion of the left superficial femoral artery (A) and slow flow to the popliteal artery at angiography (B). C: AngioJet catheter positioned in the left superficial femoral artery to remove thrombus. D, E, F: thrombus aspiration and vessel patency.

Using crossover technique, PTA of the left SFA was performed. Initially, a 0.035" J-shaped Terumo guide-wire was passed through the thrombotic lumen up to the end of the obstruction; then multiple PTAs were performed, using an Admiral Xtreme Balloon Catheter 5.0x60 mm, without obtaining any good result. Thus, the Possis AngioJet® catheter was passed on the 0.014" guide-wire through the thrombotic lumen (Figure 2C), and the thrombus was aspirated. Once previously stented vessel was reopened, the result was optimized with nitinol self-expanding re-stenting using two Protégé Everflex nitinol stents (6.0x150 mm and 6.0x100 mm), leading to satisfactory angiographic outcome (Figure 2, D-E-F). A month after discharge, pain and walking limitations disappeared. Twelve months later, colour Doppler ultrasound showed patent stent segment and normal flow pattern.

### Patient 3

A 72-year-old man, with atrial fibrillation, hypercholesterolemia and history of right femoro-popliteal PTFE bypass implantation for right ALI, was admitted to our Department because of rest pedal pain and duplex ultrasound evidence of both left proximal SFA and by-pass occlusion with distal collateral flow (Fontaine's stage III).

Peripheral angiography confirmed the proximal occlusion of both SFA and the femoro-popliteal bypass. Moreover, a critical stenosis of the left external iliac artery was found. In order to perform a PTA, 6F long sheaths (Terumo Destination) were posi-

tioned, 5000 U.I. of heparin were administered intravenously and the PTFE graft was then passed with a 0.035" J-Shaped Terumo stiff guide-wire. The critical stenosis of external iliac artery was treated with PTA and stent implantation (Complete 7x40 mm) followed by PTA and stenting of the distal graft anastomosis (Protégé Everflex 7x60 mm). Final angiography revealed optimal result. The patient received a loading dose of clopidogrel (300 mg) P.O. and ASA (500 mg) i.v. and he was discharged with clopidogrel (75 mg/die) and ASA (100 mg/die). Two months later, duplex ultrasounds scan demonstrated a normal flow through the stents and the downstream segments.

After the procedure, the patient was asymptomatic for 4 months under dual antiplatelet therapy. However, he was recommended to stop clopidogrel and to start warfarin anticoagulation therapy in addition to ASA, in order to prevent thromboembolic events because of the persistence of atrial fibrillation. Nevertheless, clopidogrel was incorrectly interrupted before reaching therapeutic range of INR. One month later, he returned to our Department for ALI (Fontaine's stage IV). Pedal pulses were absent and duplex ultrasound showed acute thrombosis of both right PTFE graft and previous implanted stent at the distal anastomosis. Angiography confirmed the complete occlusion of both by-pass and the previously deployed stent at the distal anastomosis (Figure 3A). PTA of right PTFE by-pass was performed by using the crossover technique. A 0.035" J-shaped Terumo stiff guide-wire was crossed

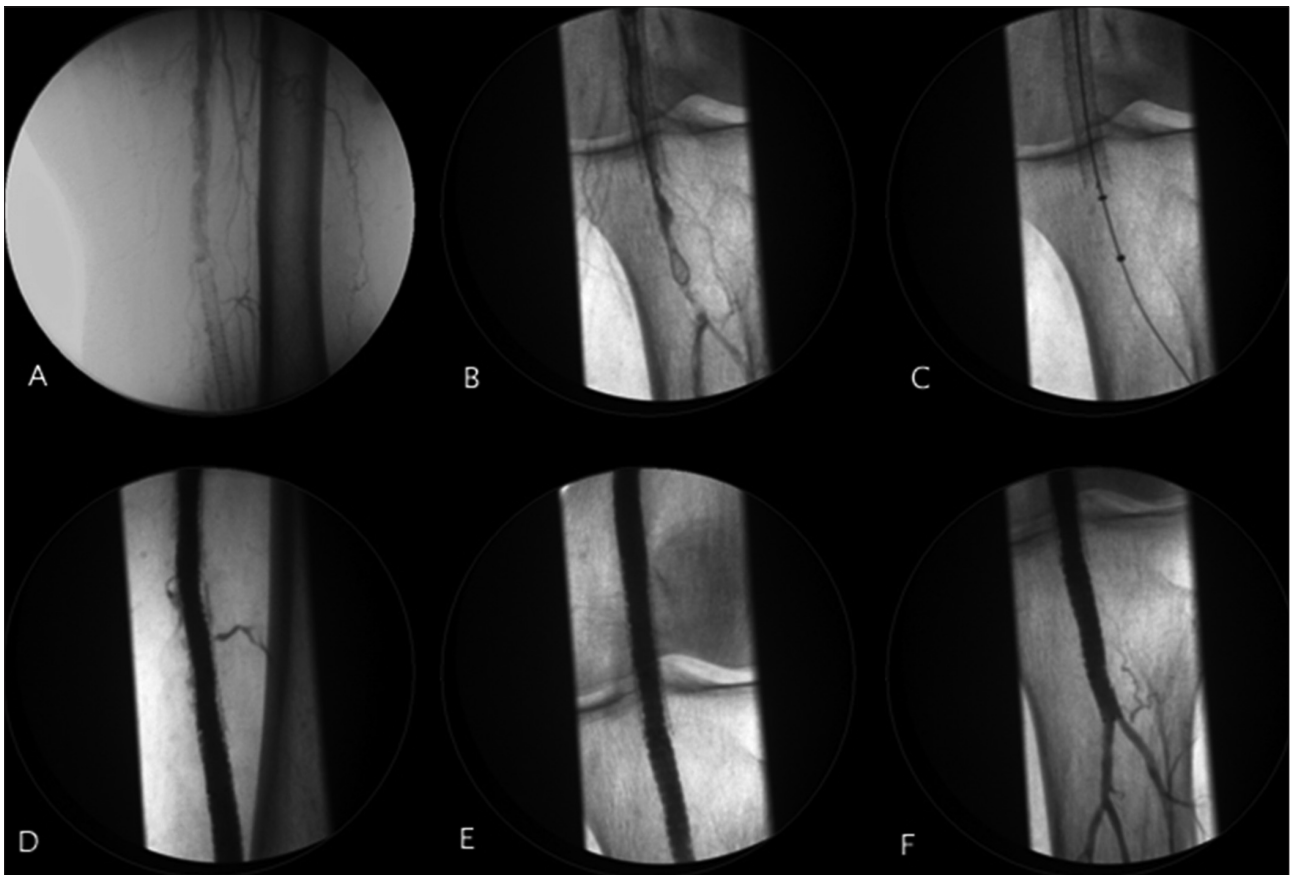


Figure 2. - Thrombotic occlusion of the right superficial femoral artery from the proximal edge of the previously implanted segment (A) to the distal popliteal segment at angiography (B). C: positioning of the AngioJet catheter through the lesion. D, E, F: good angiographic result, with excellent vessel patency at the end of the procedure.

through the lumen up to the distal end of the tibio-peroneal trunks. Using an Admiral Xtreme Balloon Catheter 6.0x40 mm multiple PTAs were performed without reaching any good result. Furthermore, the angiography showed multiple minus images, revealing thrombus persistence (Figure 3B). Thus, a mechanical thrombectomy using Possis AngioJet® was performed using the Spiroflex catheter on a 0.014" guide-wire obtaining an optimal result up to the distal segment of the by-pass. Finally, a new stent (absolute Pro 7.0x60 mm) was implanted in the distal femoral popliteal artery in order to reach a better clinical outcome (Figure 3C). One month after discharge, pain and walking limitations disappeared. Six months later, colour Doppler ultrasound demonstrated patent stent segment and a normal flow pattern.

### Discussion

The primary goals of ALI treatment are to relieve ischemic pain and to prevent limb loss. Primary percutaneous revascularization with new nitinol stents in association to dual antiplatelet therapy is safe and improves late patency rates [1, 3, 5]. Here we describe three cases of SFA stent thrombosis as a consequence of inadequate or prematurely discontinued dual antiplatelet therapy after SFA stenting. It is important to emphasize that much of the supporting evidence for antiplatelet therapy after SFA stenting is extrapolated from what is related to the coronary circulation [6]. Dual antiplatelet therapy for

three to six months after PTA and nitinol stent placement is usually recommended to prevent early stent failure because of thrombosis at the intervention site. Our patients were characterized by high-risk metabolic-profile, with long peripheral lesions (type C TASC classification) and, strikingly, two of them were affected by rheumatoid arthritis, a chronic inflammatory disease associated with pro-atherothrombotic state. Notably, in this setting the discharge of dual antiplatelet therapy for major bleeding (case report 1) or a suboptimal antiplatelet therapy for ASA allergy (case report 2) may have induced the thrombotic event development following the primary SFA stent placement. In addition, the clinical case 3 reflects the different roles of anticoagulation and antiplatelets drugs, and the key role of reaching the therapeutic INR target.

Although it is well known that initial therapeutic strategy for ALI aims at preventing thrombus propagation and worsening of ischemia, which technique should be considered the gold standard during ALI caused by stent thrombosis is still uncertain. Data from randomized studies suggest that catheter directed-thrombolysis is associated to reduced mortality rate and to a less complex surgical procedure when compared to surgical revascularization, despite a higher rate of recurrent ischemia and risk of amputation [12-15]. Several non-randomized studies validated the role of combined percutaneous endovascular approach including mechanical thrombus aspiration, catheter thrombolysis, and percuta-

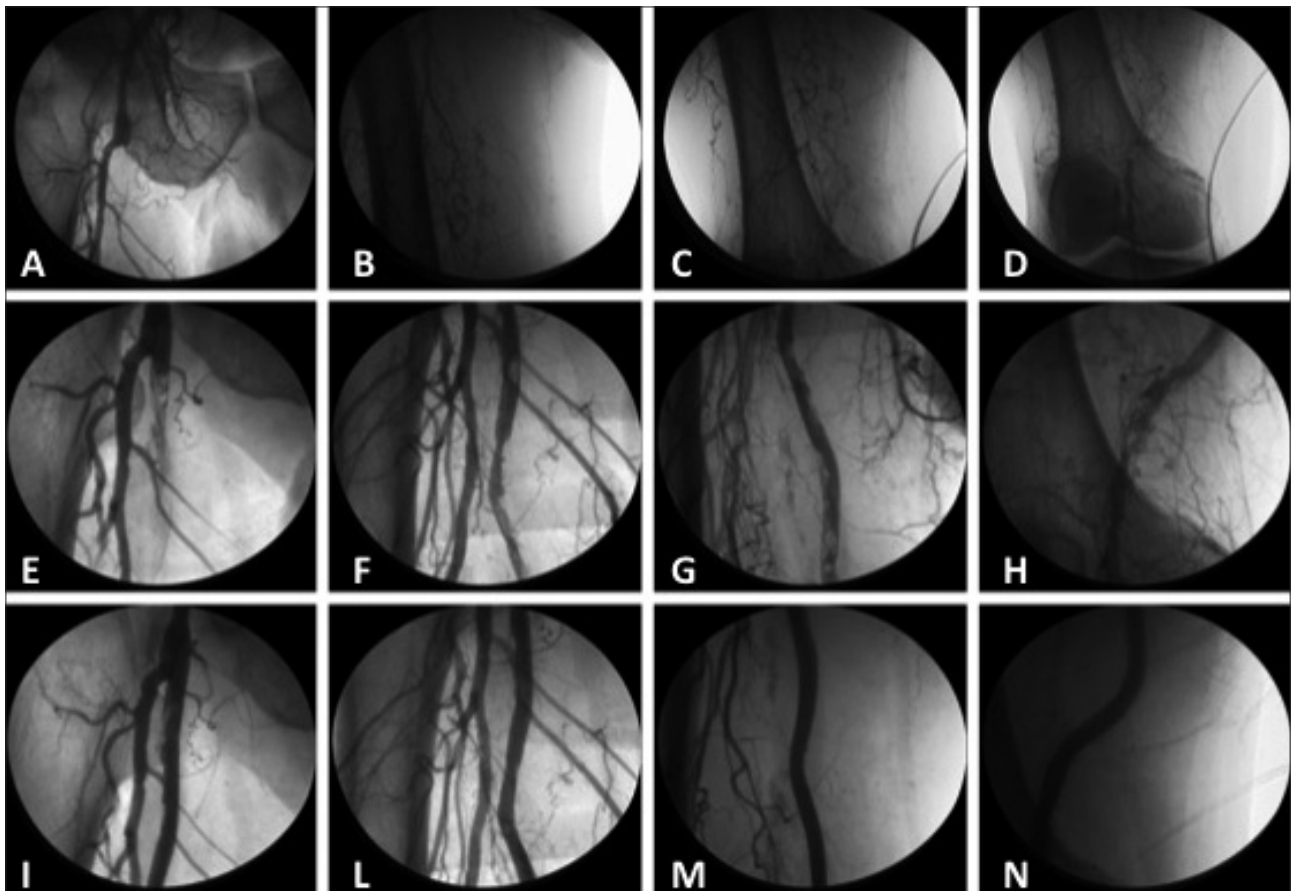


Figure 3. - **A-D**: Complete occlusion of the superficial femoral artery, polytetrafluoroethylene (PTFE) femoro-popliteal bypass grafts and of the previously implanted stent at the distal end of the graft anastomosis. **E-H**: Slow flow and multiple minus images compatible with the presence of thrombi after Plain Old Balloon Angioplasty (POBA) at the proximal and distal anastomosis of bypass. **I-N**: Optimal angiographic result after thrombi aspiration by AngioJet and stent implantation at the distal end of the anastomosis.

neous transluminal angioplasty to treat acute and sub-acute occlusions of native leg arteries [16]. Thus, percutaneous thrombectomy devices represent a non-surgical alternative for the treatment of ALI and they may be used together with fibrinolysis to reduce time and dose of the fibrinolytic agent or as a stand-alone procedure without using pharmacologic thrombolytic agents [17, 18]. However, no data regarding their use for late thrombus removal after peripheral stent implantation are available.

Here we describe, for the first time, the efficacy of percutaneous thrombectomy for treating acute peripheral nitinol-stent thrombosis, suggesting its use not only in native arteries or aortic-coronary grafts, but also in long-stented segment of SFA. The (AngioJet®) rheolytic thrombectomy (AngioJet®) system has shown promising results in terms of safety and efficacy to open thrombotic coronary arteries in acute myocardial infarction, despite it has never been tested in randomized trials. During ALI, the rheolytic thrombectomy system has been shown to be useful together with thrombolytic therapy in order to re-establish blood flow into the native lower extremity arteries [18]. Currently, it is not clear to what extent this technique is applicable for peripheral stent thrombosis. Our reports indicate the efficacy of this mechanical thrombus aspiration system in SFA stent or PTFE prosthesis thrombosis. Indeed, AngioJet® rheolytic thrombectomy has been effective in restoring immediate blood flow in stented

segment, supporting an efficacy and safety profile of the Possis AngioJet catheter and its use in patients with peripheral acute stent-thrombosis. Thus, these cases suggest that AngioJet® rheolytic thrombectomy might represent a novel effective strategy in the percutaneous treatment of stent or graft thrombosis determining ALI.

#### Riassunto

*L'interruzione della terapia antiaggregante, determinante trombosi degli stent in nitinol o dei by-pass femoro-poplitei in politetrafluoroetilene (PTFE) della femorale superficiale, costituisce una problematica emergente nella gestione dei pazienti con ischemia acuta dell'arto (ALI), che necessitano un intervento immediato. Ad oggi, infatti, non esiste alcuna strategia codificata per la gestione di queste complicanze. Descriviamo di seguito due casi di ALI derivanti dalla interruzione della terapia antiaggregante con la conseguente trombosi dello stent in nitinol, ed un caso di ALI conseguente alla trombosi di un by-pass in PTFE; in tutte le circostanze il salvataggio d'arto è stato ottenuto rimuovendo il trombo attraverso trombectomia percutanea di tipo reolitico (AngioJet® rheolytic thrombectomy) e attuando una successiva angioplastica transluminale percutanea (PTA). In tutti i casi, è stato ottenuto un ottimo risultato angiografico. Ad oggi, i casi da noi descritti sono i primi in cui è stato usato l'AngioJet® nel trattamento della ALI*

dovuta a trombosi dello stent o del graft. Nell'insieme, questi casi suggeriscono che la trombectomia percutanea di tipo reolitico con AngioJet® costituisce una valida alternativa nel trattamento della trombosi di stent o graft, determinanti ALI.

#### ABBREVIATIONS LIST

ASA: Acetylsalicylic Acid  
 PAD: peripheral artery disease  
 SFA: superficial femoral arteries  
 ALI: acute limb ischaemia  
 RT: Rheolytic thrombectomy  
 PTCA: percutaneous transluminal coronary angioplasty  
 PTA: percutaneous transluminal angioplasty  
 PTFE, polytetrafluoroethylene

#### References

- Schillinger M, Sabeti S, Loewe C, *et al.* Balloon angioplasty versus implantation of nitinol stents in the superficial femoral artery. *N Engl J Med* 2006; 354 (18): 1879-88.
- Schillinger M, Sabeti S, Dick P, *et al.* Sustained benefit at 2 years of primary femoropopliteal stenting compared with balloon angioplasty with optional stenting. *Circulation* 2007; 115 (21): 2745-9.
- Duda SH, Bosiers M, Lammer J, *et al.* Sirolimus-eluting versus bare nitinol stent for obstructive superficial femoral artery disease: the SIROCCO II trial. *J Vasc Interv Radiol* 2005; 16 (3): 331-8.
- Laird JR. Limitations of percutaneous transluminal angioplasty and stenting for the treatment of disease of the superficial femoral and popliteal arteries. *J Endovasc Ther* 2006; 13 Suppl 2: II30-40.
- Ruef J, Hofmann M, Haase J. Initial clinical experience with the Protege EverFlex long self-expanding nitinol stent in the superficial femoral artery. *J Interv Cardiol* 2006; 19 (6): 544-6.
- Bhatt DL, Flather MD, Hacke W, *et al.* Patients with prior myocardial infarction, stroke, or symptomatic peripheral arterial disease in the CHARISMA trial. *J Am Coll Cardiol* 2007; 49 (19): 1982-8.
- Blinc A, Poredos P. Pharmacological prevention of atherothrombotic events in patients with peripheral arterial disease. *Eur J Clin Invest* 2007; 37 (3): 157-64.
- Lumsden AB, Rice TW. Medical management of peripheral arterial disease: a therapeutic algorithm. *J Endovasc Ther* 2006; 13 Suppl 2: II19-29.
- Kuntz RE, Baim DS, Cohen DJ, *et al.* A trial comparing rheolytic thrombectomy with intracoronary urokinase for coronary and vein graft thrombus (the Vein Graft AngioJet Study [VeGAS 2]). *Am J Cardiol* 2002; 89 (3): 326-30.
- Margheri M, Falai M, Vittori G, *et al.* Safety and efficacy of the AngioJet in patients with acute myocardial infarction: results from the Florence Appraisal Study of Rheolytic Thrombectomy (FAST). *J Invasive Cardiol* 2006; 18 (10): 481-6.
- Ali A, Cox D, Dib N, Brodie B, *et al.* Rheolytic thrombectomy with percutaneous coronary intervention for infarct size reduction in acute myocardial infarction: 30-day results from a multicenter randomized study. *J Am Coll Cardiol* 2006; 48 (2): 244-52.
- Mannava K, Money SR. Current management of peripheral arterial occlusive disease: a review of pharmacologic agents and other interventions. *Am J Cardiovasc Drugs* 2007; 7 (1): 59-66.
- Ouriel K. Comparison of surgical and thrombolytic treatment of peripheral arterial disease. *Rev Cardiovasc Med* 2002; 3 Suppl 2: S7-16.
- Ouriel K, Shortell CK, DeWeese JA, *et al.* A comparison of thrombolytic therapy with operative revascularization in the initial treatment of acute peripheral arterial ischemia. *J Vasc Surg* 1994; 19 (6): 1021-30.
- Ouriel K, Veith FJ, Sasahara AA. Thrombolysis or peripheral arterial surgery: phase I results. TOPAS Investigators. *J Vasc Surg* 1996; 23 (1): 64-73; discussion 74-5.
- Ouriel K. Endovascular techniques in the treatment of acute limb ischemia: thrombolytic agents, trials, and percutaneous mechanical thrombectomy techniques. *Semin Vasc Surg* 2003; 16 (4): 270-9.
- Kasirajan K, Gray B, Beavers FP, *et al.* Rheolytic thrombectomy in the management of acute and subacute limb-threatening ischemia. *J Vasc Interv Radiol* 2001; 12 (4): 413-21.
- Kasirajan K, Ramaiah VG, Diethrich EB. The Trellis Thrombectomy System in the treatment of acute limb ischemia. *J Endovasc Ther* 2003; 10 (2): 317-21.