

Influenza A H1N1 pneumonia in a patient with hairy-cell leukemia

A. Nicolini, A. Perazzo

ABSTRACT: *Influenza A H1N1 pneumonia in a patient with hairy-cell leukemia. A. Nicolini, A. Perazzo.*

Severe pandemic influenza A virus (H1N1) infection is associated with risk factors such as pregnancy, obesity and immunosuppression. Immunocompromised patients are at increased risk of more severe or prolonged infection. We report a case of a hairy cell leukemia patient with H1N1 pneumonia which caused severe and prolonged illness. H1N1 virus pneumonia with meticillin-resistant *Staphylococcus Aerues* (MRSA) coinfection causing Acute Lung In-

jury (ALI) was treated with a double-dose of oseltamivir, a high dose of teicoplanin and a low dose of corticosteroids. Haematological findings included leucopenia, neutropenia, lymphopenia, reduction of γ -globulins and natural killer (NK) cells. Reduction of NK and γ -globulins may explain the development of severe illness and the prolonged illness. Neutropenia may explain the MRSA co-infection. Lymphopenia is directly associated with virus action and is considered to be a marker of the swine influenza in adults. *Monaldi Arch Chest Dis 2010; 73: 2, 92-94.*

Keywords: *Influenza A H1N1 pneumonia, hairy cell leukemia, severe illness, prolonged course.*

Division of Respiratory Diseases, General Hospital, Sestri Levante, Genova, Italy.

Correspondence: Antonello Nicolini, SC Pneumologia, Via Terzi 43, 16039 Sestri Levante (GE), Italy; e-mail: antonello.nicolini@fastwebnet.it

Introduction

Most patients with influenza A H1N1 virus infection present flu-like symptoms with a benign course, although patients with co-morbidities may have a serious clinical presentation with respiratory failure [1]. As previous studies have demonstrated CD8+ T cells are important in the antiviral response to influenza via direct lysis or by the induction of tumour necrosis factor (TNF- α) and interferon (IF- γ) [2]. Altered innate immune responses, excess of CD8+ T cell cytotoxic responses and hypercytokinemia are related to the severity of the influenza infection. There has been speculation that dysregulated TLR-3-dependent CD8+T cells with sustained TLR-3 activation and consequently enhanced inflammation may lead to sustained lung injury in severe influenza infection [3].

Moreover, neutrophils play an important role in the inflammatory reaction, demonstrating a protective effect in the early stage of H1N1 virus infection [4]. The novel virus also affects the immune system, producing a decrease in CD3 and CD4 levels and a decrease in neutrophils and lymphocytes [4]. Leukopenia and lymphopenia less than 800 mm³ are associated with a worsen of the infection and were found in fatal cases of H1N1 virus pneumonia [1].

Other authors have raised the possibility that IL-15 (a cytokine involved in innate and adaptive immune responses and regulating memory CD8+, natural killer and intraepithelial lymphocyte T cells) dependent CD8+ T cells are partly responsible for the pathogenesis of acute pneumonia caused by influenza A virus [2].

Immunosuppressed patients such as those receiving chemotherapy for leukemia, are at increased risk of contracting influenza, together with the risk of more severe or prolonged infection [5-9]. In this regard, two cases of children under intensive chemotherapy due to acute lymphatic leukemia and a case of a 45 year-old female immunosuppressed after a heart transplant, who all developed influenza A H1N1 pneumonia with acute respiratory failure requiring mechanical ventilation, have been recently described [5, 6]. We describe a case of a patient with influenza A H1N1 virus pneumonia affected by hairy-cell leukemia presenting severe H1N1 pneumonia and a prolonged course of illness.

Case report

A middle-aged man (53 years old) affected by lymphatic hairy cell leukemia, treated with splenectomy and with chemotherapy was brought to the hospital because of fever, cough, fatigue, anorexia and dyspnea which had started ten days before. The disease was diagnosed fifteen years prior to admission and chemotherapy (Cladribina) commenced two years ago and was stopped a year later. The last haematological parameters, made four months prior to admission to hospital, as follows: white blood cell counts 4620/mm³, neutrophils 15.8%, lymphocytes 80.4%, C-reactive protein 0.10 mg/dl. Upon admission he was in significant respiratory distress. Physical examination revealed tachypnea (32 respiratory rate), tachycardia (112), fever (38.9°), crackles in both lungs, oxygen saturation on room air 88%. Chest X-ray

showed patchy opacities in both lower lobes predominantly in the left lung (fig. 1). Pharyngeal swab real-time polymerase chain reaction (RT-PCR) for H1N1 influenza virus confirmed the infection with the novel virus.

Arterial failure blood gas sample analysis confirmed respiratory (PaO₂ 66.7, PaCO₂ 38.1, pH 7.48 P/F 317); therefore the patient was strictly monitored and oxygen FiO₂ 31% was administered. Laboratory test revealed leucopenia (white blood cell counts 1960 mm³) neutropenia and lymphopenia and monocytopenia), anaemia (red blood cells 2 970 000/mm³), C-reactive protein of 39.62 mg/dL and lactate dehydrogenase 669 IU/ L, a re-

duction of γ -globulins (γ -globulins 11, 2%, IgG 690 mg/dl, IgA 88 mg/dl, IgM 40 mg/dl) and an albumin/globulin ratio of 0.98. Previous laboratory test (performed four months before the hospital admission) showed normal white cell counts (4620 with 5.8% neutrophils and 80.4% lymphocytes). CT scan of the thorax showed prominent interstitial opacity with ground glass and air bronchogram (fig. 2).

Antiviral therapy with oseltamivir 75 mg twice daily and amoxicillin+clavulanic 1 g three times a day plus levofloxacin 1 g daily i.v. was started. Blood lymphocyte populations were: T cells CD3+ 85% (n.v. 55-84%), CD4+ 37% (n.v. 31-60%), CD8+ 40% (n.v. 13-41%) with CD4/CD8 ratio 0.9 (n.v. 0.9-3.60), B lymphocytes 12% (n.v. 6-25%), NK 3% (n.v. 5-27%). During the following days the condition of the patient worsened and he developed an ALI: Chest-X ray and CT of the thorax showed a much enlarged extent of the lung bilateral opacities and the appearance of a small left pleural effusion. Seven days after admission the patient underwent a fiberbronchoscopy with bronchoalveolar lavage: several virological and bacteriological examinations were carried out. RT-PCR showed persistent H1N1 infection also in bronchoalveolar lavage and methicillin-resistant *Staphylococcus aureus* (MRSA) was found in BAL.

Due to persistent H1N1 infection in lungs and presence of secondary co-infection the therapy was immediately modified: oseltamivir 150 mg twice daily [11], teicoplanin 800 mg daily i.v. and a low dose of corticosteroid (prednisone 25 mg i.v. daily) [12, 13]. The duration of antiviral, antibiotic and low dosage corticosteroid therapy was twelve days. The clinical findings slowly but progressively improved. A week later oxygenation improved (PaO₂ 77 PaCO₂ 39 pH 7.394 in room air) as did leucocytes (7400/mm³) and reactive C protein (1.12 mg/dl); three weeks after admission the patient was discharged.

Discussion

It has traditionally been conceived that danger to the host is created when infection by an influenza type A strain predisposes him to secondary infection by bacterial pathogens and results have revealed that within the first two days of the advent of the first symptoms, considerable changes of both the innate and the adaptive immune responses were found among patients affected by H1N1 virus.

Principal changes are:

- a) increase of absolute monocyte count;

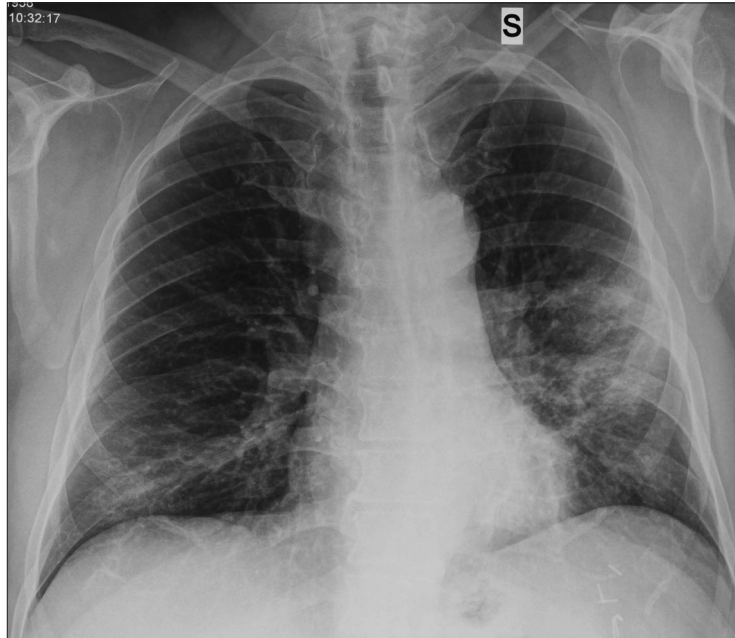


Fig. 1. - Chest X-ray at the admission: bilateral patchy opacities in both lower lobes, predominantly in the left lung.

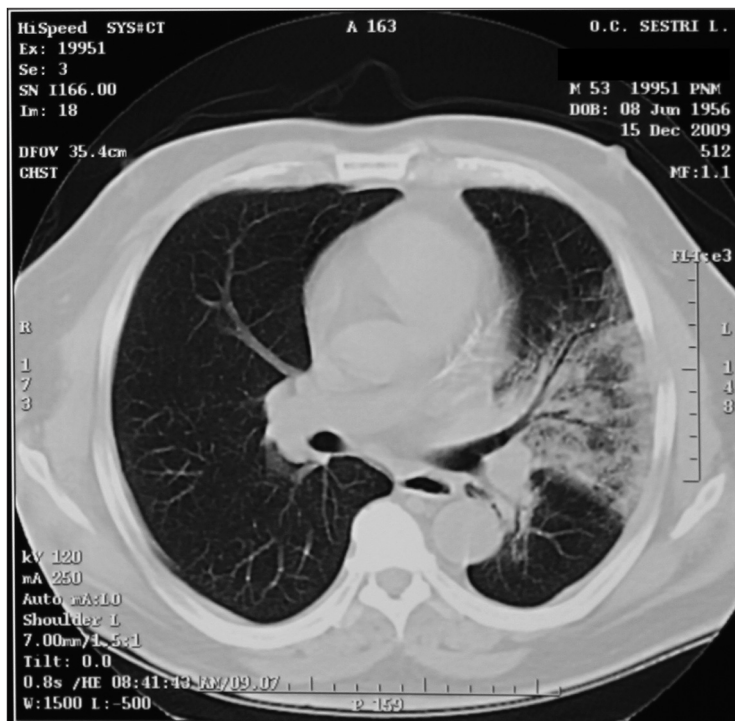


Fig. 2. - Chest CT: Prominent interstitial opacity with ground glass and air bronchogram.

- b) selective defect of TNF α and IFN γ ;
- c) increase of absolute counts of T regs, mainly observed among patients with H1N1 influenza-related pneumonia.

These findings may signify a predisposition to pneumococcal infections [3]. The cell-mediated immune response is extremely important in viral clearance and in promoting recovery: the most important cellular immune response is CD8 T-lymphocyte-mediated-cytotoxic; and the reduction in T-cell number or function will produce an increased magnitude; and duration of infection, as will an excess of CD8+ T cell suppressor responses [7, 6].

Immunocompromised patients, therefore, are at risk of serious influenza-associated complications, as well as prolonged viral shedding associated with the development of oseltamivir resistance [6, 9]. Although little data regarding the immunological effect of the novel influenza A H1N1 virus is available, we would highlight the key points of the reported case presenting some peculiar clinical findings. The patient with B-lymphocyte leukemia and splenectomy had presented with:

- a) reduction of the number of natural killer cells and a low level of total immunoglobulins and IgG, which may explain the development of severe pneumonia, the prolonged course of the illness and the poor effect of the antiviral treatment [12, 13];
- b) neutropenia which may be associated with the development of the coinfection (MRSA), but is not strictly associated with virus infection;
- c) lymphopenia, which was strictly linked to direct virus action and is considered a marker of swine influenza (H1N1) in adults [14, 15].

Finally, the use of prolonged low-dose of corticosteroids in influenza A virus H1N1 associated acute lung injury seems to be associated with a reduction of pulmonary inflammation and fibrosis and with elevation of glucocorticoid receptor expression in the lung [12, 18].

References

1. Cunha BA. Swine influenza (H1N1) pneumonia: clinical considerations. *Infect Dis Clin N A* 2010; 24: 203-28.
2. Nakamura R, Maeda N, Shibata K, Yamada H, Kase T, Yoshikai Y. Interleukin-15 is critical in the pathogenesis of influenza A virus-induced acute lung injury. *J Virol* 2010; 84: 5574-82.
3. Giamellos-Bourboulis E, Raftogiannis M, Antonopoulou A, Baziaka F, Koutoukas P, Savva A, *et al.* *PLoS One* 2009; 4: 8393.
4. Mu YP, Zhang ZY, Chen XR, Xi XH, Lu YF, Tang YW, Lu HZ. Clinical features, treatment and prognosis of the initial cases of pandemic influenza H1N1 2009 virus infection in Shanghai China. *Q J Med* 2010; 103: 311-7.
5. Launes C, Rives S, Català A, Berruoco R, Toll T, Camos M, *et al.* Pandemic influenza A (2009 H1N1) in children with acute lymphoblastic leukaemia. *B J Haematol* 2010; 149: 874-8.
6. Bacal F, Seguro LF, Ogawa T, Mangini S, Fiorelli A, Bocchi E. Influenza A (H1N1) Pneumonia in a immunosuppressed patient after heart transplantation. *Arg Bras Cardiol* 2009; 93: 91-2.
7. Lapinsky SE. H1N1 novel influenza A in pregnant and immunocompromised patients. *Crit Care Med* 2010; 38: e52-7.
8. Marchiori E, Zanetti G, Hochhegger B, Irion K. High-resolution computed tomography findings in an HIV-positive patient with Swine-origin Influenza A (H1N1) virus-associated pneumonia. *Brit J Radiol* 2010; 83: 179.
9. Sullivan SJ, Jacobson RM, Dowdle WR, Poland GA. 2009 H1N1 Influenza. *Mayo Clin Proc* 2010; 85: 64-76.
10. Speers DJ, Williams SH, Pinder M, Moody HR, Hurt AC, Smith DW. Oseltamivir-resistant pandemic (H1N1) 2009 influenza in a severely ill patient: the first Australian case. *M J A* 2010; 192: 166-68.
11. Choi WJ, Kim WY, Kim SH, Oh BJ, Kim W, Lim KS, *et al.* Clinical characteristics of Pneumonia in hospitalized patients with novel influenza A (H1N1) in Korea. *Scand J Infect Dis* 2010; 42: 311-4.
12. Napolitano LM, Park PK, Raghavendran K, Bartlett RH. Non ventilatory strategies for Patients with life-threatening 2009 H1N1 influenza and severe respiratory failure. *Crit Care Med* 2010; 38: 74-90.
13. Quispe-Laime AM, Bracco JD, Barberio PA, *et al.* H1N1 virus associated acute lung injury: response to combination oseltamivir and prolonged corticosteroid treatment. *Int Care Med* 2010; 36: 33-41.
14. Zimmerli W, Schaffner A, Scheidegger C, Scherz R, Spath PJ. Humoral immune response to pneumococcal antigen 23-F in asplenic patient with recurrent fulminant pneumococcaemia. *J Infect* 1991; 22: 59-69.
15. Gordon CL, Johnsson DR, Permezel M, *et al.* Association between severe pandemic 2009 influenza A (H1N1) virus infection and Immunoglobulin G2 subclass deficiency. *Clin Infect Dis* 2010; 50: 672-8.
16. Mu YP, Zhang ZY, Chen XR, *et al.* Clinical features, treatments and prognosis of the initial cases of pandemic influenza H1N1 2009 virus infection in Shanghai China. *Q J Med* 2010; 103: 311-7.
17. Cunha BA, Pherez FM, Schoch P. Diagnostic importance of relative lymphopenia as a marker of swine influenza (H1N1) in adults. *Clin Infect Dis* 2009; 49: 1454-6.
18. Wang XO, Zhou S, Zhou Y, Rong L, Gao L, Xu W. Low dose dexamethasone alleviates Lipopolysaccharide-induced acute lung injury in rats and upregulates pulmonary Glicocorticoid receptors. *Respirology* 2008; 13: 772-80.