

# Endoscopic removal of a right main bronchus glomus tumor

P. Vailati<sup>1,2</sup>, C. Bigliuzzi<sup>1</sup>, G. Casoni<sup>1</sup>, C. Gurioli<sup>1</sup>, L. Saragoni<sup>3</sup>, V. Poletti<sup>1</sup>

**ABSTRACT:** *Endoscopic removal of a right main bronchus glomus tumor. P. Vailati, C. Bigliuzzi, G. Casoni, C. Gurioli, L. Saragoni, V. Poletti.*

Glomus tumours in the respiratory tract are very rare. The majority of the reported cases have been surgically treated.

An approach with rigid bronchoscopy to endobronchial lesions suspected to be carcinoid or other well vascularized tumours, as glomus tumor is, should be considered because it can allow a safe diagnosis and eventually be therapeutic avoiding more invasive and surgical procedures.  
*Monaldi Arch Chest Dis 2004; 61: 2, 117-119.*

**Keywords:** *Glomus, Bronchial, Endoscopic, Removal.*

<sup>1</sup> U.O. Pneumologia interventistica, Dipartimento delle Malattie dell'Apparato Respiratorio e del Torace, Ospedale G.B.Morgagni, Forlì, Italy.

<sup>2</sup> Clinica di Malattie dell'Apparato Respiratorio, Dipartimento di Scienze Mediche, Oncologiche e Radiologiche, Università di Modena e Reggio Emilia, Policlinico di Modena, Modena, Italy.

<sup>3</sup> U.O. di Anatomia Patologica, Dipartimento Oncologico e dei Servizi di Diagnosi, Ospedale G.B.Morgagni, Forlì, Italy.

Correspondence: Venerino Poletti MD, FCCP Dipartimento di Malattie dell'Apparato Respiratorio e del Torace, Ospedale G.B. Morgagni, Forlì, Italy; e-mail: [vepolet@tin.it](mailto:vepolet@tin.it)

## Case report

A 40-year-old man was referred to the Department of Thoracic Diseases for a chest radiography showing a homogeneous opacity with sharp edges in the right lower lung field, identical to a previous one dating back twenty days.

He had a history of previous smoking (11 pack/year) and he had been treated for "asthma" 6 years previously due to recurrent episodes of a mild productive cough and wheezing. He also had a positive prick test for *dermatophagoides*.

At the time of the initial chest radiography he was complaining of a fever, mild productive cough and mild chest pains at the right base for 5 days; he was treated initially with clarithromycin and then with cefepime, with slow clinical improvement.

Physical examination at admission revealed the absence of breath sounds at the right lung basis with consensual dullness at percussion and a decreased vocal fremitus; pulmonary function tests showed no abnormalities. Altered laboratory results were: ESR=45 mm/h; Platelets=496 x10<sup>3</sup>/mmc (normal range 140-400); Ca 19.9=38.4 U/ml (range 0-37); Ca 125=82.7 U/ml (0-35).

A chest CT scan showed an endoluminal mass of 9 mm diameter which arose from the origin of the right main bronchus and grew distally in the truncus intermedius and lower lobe bronchus (fig. 1A), causing atelectasis of the lower lobe. No lymph node enlargement was described.

A rigid bronchoscopy was performed relieving a vascular polilobulate intraluminal protruding tumour, with a smooth surface, which determined the

complete obstruction of the main right bronchus at its origin (fig. 2A). The tumour was excised with an electrocoagulator (Valleylab Inc., Boulder, USA), using a rigid ventilating bronchoscope of 10,5 mm diameter (Storz Inc., Tuttlingen, Germany) to allow coagulation and forceps extraction of the tumour.

During the procedure there was a significant bleeding (>800 ml) but the tumour was completely removed; it was a mass of 6.5 x 1.5 cm with the main tissue fragment measuring 5 x 1,5 cm. (fig. 3). The in-hospital follow-up course was regular; the patient was discharged home on hospital day 4 performing all activities without distress or shortness of breath or hemoptysis.

The pathology report of the removed tissue demonstrated the features of typical glomus tumours; a fairly circumscribed vascular tumour without capsula consisting of groups of small cuboidal cells with bland round nuclei and a clear or faintly eosinophilic cytoplasm.

Immunohistochemistry profile confirmed the diagnosis relieving a strong and diffuse positivity for actin and vimentin, a local but marked positivity for CD31 and negative stains for desmin, keratin, S100, neuro-specific enolase, chromogranin, synaptophysin.

After one month a follow-up fiberoptic bronchoscopy and a chest CT scan were performed; no recurrence of the disease was visible radiologically (fig.1B) or macroscopically (fig. 2B) nor histologically reliable. Endobronchial ultrasonography was also performed with the relief of a normal layered structure of the bronchial wall and absence of lymphadenopathy of the tributary stations.

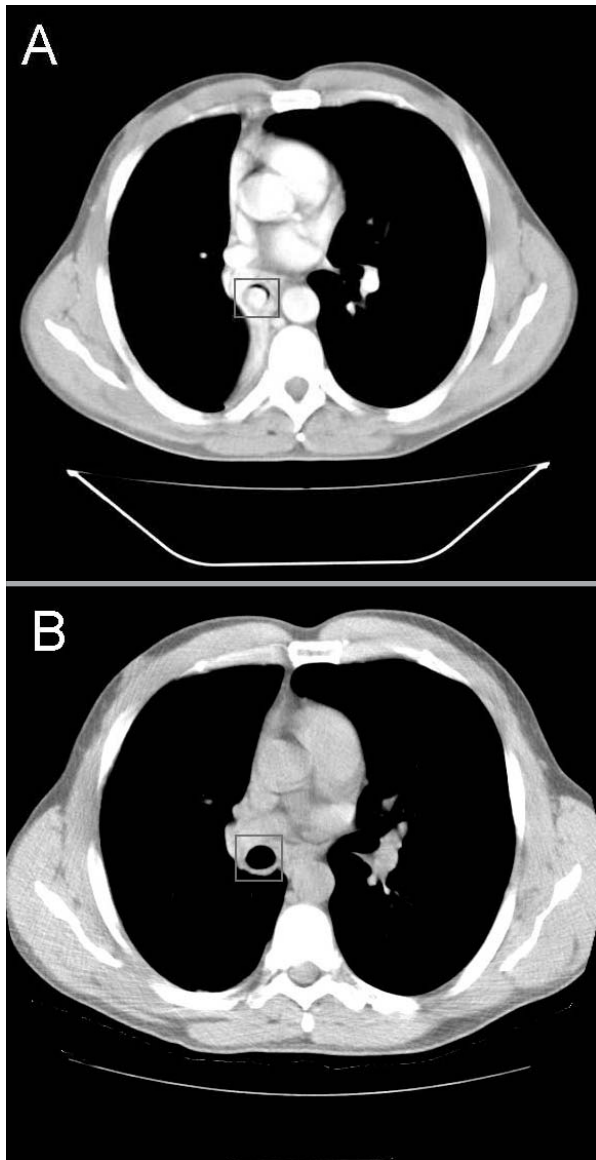


Fig. 1. - Preoperative chest CT (A) disclosed an endobronchial mass, which arose from the origin of the right main bronchus and grew distally in the truncus intermedius and lower lobe bronchus; postoperative chest CT (B) revealed a normal endobronchial appearance with secondary complete resolution of the atelectasis of the lower lobe.

### Discussion

Glomus tumours are lesions that histologically resemble or derive from cells of the neuromyoarterial glomus, or glomus body, an anatomic structure thought to be involved with temperature regulation. Ultrastructurally glomocytes have features of smooth muscle and are thought to be derived from the epithelioid neuromuscular cells associated with the arteriovenous anastomoses of the normal glomus body [1].

Glomus tumours are uncommon with an estimated incidence of 1.6% in 500 consecutive soft tissue tumours [2]. The most common location is the subungueal region of the finger, along with the palm, wrist, forearm, and foot; infrequently they involve unusual sites, including the mediastinum and respiratory tract [1].

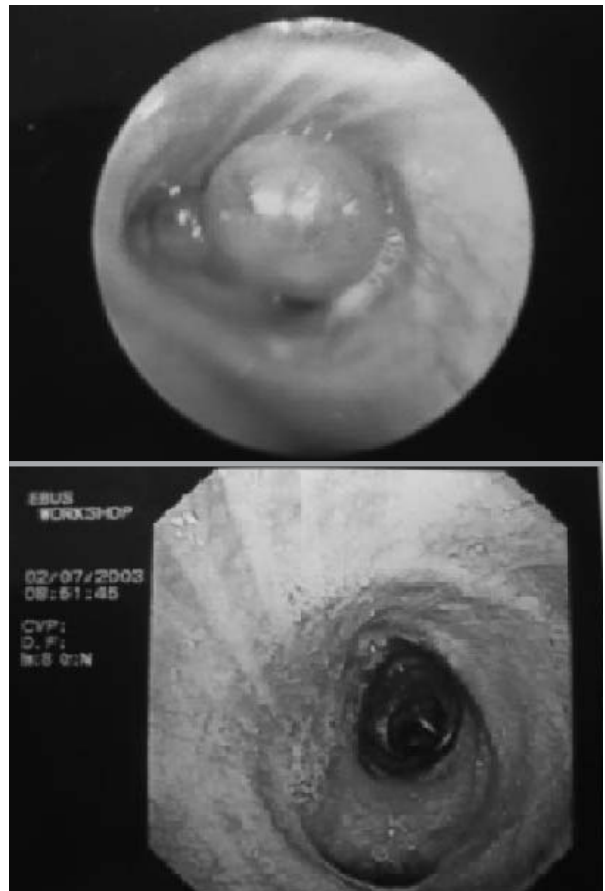


Fig. 2. - Endoscopic appearance before (upper panel) and after (lower panel) the procedure.

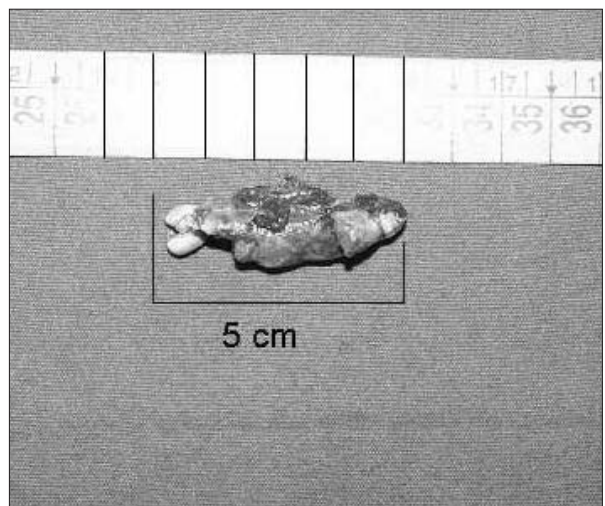


Fig. 3. - Glomus tumour's main fragment measuring 5 x 1.5 cm.

Within the respiratory tract the trachea is the most frequent site of involvement; a review of the literature demonstrated 15 tracheal glomus tumour cases and 10 pulmonary cases reported [1-9].

The majority of the cases reported have been treated surgically, only 3 tracheal cases endoscopically (one case with Nd-Yag Laser excision [4], one case with Laser excision plus radiotherapy [5], one case in a non specified way [6]); the major diameters of the excised tumours were respectively

4.5, 3 and 2.2 cm. Our case is the first one located in a main bronchus successfully treated with electrocauterisation and bronchoscopic removal.

Most cases of lung glomus tumour resemble carcinoid both for clinical-radiological and histological features, thus a diagnostic approach with rigid bronchoscopy at once, instead of fiberoptic bronchoscopy, could be particularly helpful in controlling the bleeding which is generally abundant in both types of tumour.


Because glomus tumors are generally indolent neoplasms their discrimination from more common aggressive neoplasms is important and can also avoid unnecessary treatment. Rigid bronchoscopy permits a safe diagnosis but could mainly show a conservative therapeutic role for endobronchial lesions of large dimensions, like in our case.

Endobronchial ultrasonography could be very useful as an integrated approach to exclude an aggressive behaviour by the lesion, that should always be documented before radical or aggressive management undertaking.

The invasion of the bronchial wall probably should always be evaluated, in fact a case has been reported of a tumour growth through the tracheal wall nevertheless of benign histological appearance [5].

## References

1. Gaertner EM, Steinberg DM, Huber M, *et al.* Pulmonary and mediastinal glomus tumors-report of five cases including a pulmonary glomangiosarcoma: a clinicopathologic study with literature review. *Am J Surg Pathol* 2000; 24: 1105-14.
2. Shugart RR, Soule EH, Johnson EW. Glomus tumor. *Surg Gynecol Obstet* 1963; 117: 334-40.
3. Lange TH, Magee MJ, Boley TM, *et al.* Tracheobronchial glomus tumor. *Ann Thorac Surg* 2000; 70: 292-5.
4. Arapantoni-Dadioti P, Panayiotides J, Fatsis M, *et al.* Tracheal glomus tumour. *Respiration* 1995; 62: 160-2.
5. Koskinen SK, Niemi PT, Ekfors TO, *et al.* Glomus tumor of the trachea. *Eur Radiol* 1998; 8: 364-6.
6. Sheffield E, Dewar A, Corrin B, *et al.* Glomus tumour of the trachea. *Histopathology* 1988; 13: 234-6.
7. Gowan RT, Shamji FM, Perkins DG, *et al.* Glomus tumor of the trachea. *Ann Thorac Surg* 2001; 72: 598-600.
8. Altorjay A, Arato G, Adame M, *et al.* Synchronous multiple glomus tumors of the esophagus and lung. *Hepatogastroenterology* 2003; 50: 687-90.
9. Yilmaz A, Bayramgurler B, Aksoy F, *et al.* Pulmonary glomus tumour: a case initially diagnosed as carcinoid tumour. *Respirology* 2002; 7: 369-71.



Pavia - Palazzo Broletto