

This article is licensed under the Creative Commons Attribution-NonCommercial 4.0 International License (CC BY-NC) (<http://www.karger.com/Services/OpenAccessLicense>). Usage and distribution for commercial purposes requires written permission.

Case Report

Lack of Response to Imatinib in Melanoma Carrying Rare *KIT* Mutation p.T632I

Kristina V. Orlova^a Grigory A. Yanus^{b, c} Svetlana N. Aleksakhina^b
Aigul R. Venina^b Aglaya G. Iyevleva^{b, c} Lev V. Demidov^a
Evgeny N. Imyanitov^{b–e}

^aDepartment of Biotherapy, N.N. Blokhin Russian Cancer Research Center, Moscow, Russia; ^bDepartment of Tumor Growth Biology, N.N. Petrov National Medical Research Center of Oncology, Saint Petersburg, Russia; ^cDepartment of Clinical Genetics, St.-Petersburg Pediatric Medical University, Saint Petersburg, Russia; ^dDepartment of Oncology, I.I. Mechnikov North-Western Medical University, Saint Petersburg, Russia; ^eDepartment of Oncology, St.-Petersburg State University, Saint Petersburg, Russia

Keywords

Melanoma · *KIT* · Mutation · Imatinib

Abstract

Approximately 15% of acral and mucous melanomas carry activating mutations in *KIT* oncogene. There is a diversity of spectrum of *KIT* mutations, with some of them rendering tumors responsive to imatinib, while others being imatinib-resistant or not studied yet. Here we present an acral melanoma patient with *KIT* p.T632I mutation, who failed to respond to imatinib.

© 2019 The Author(s)
Published by S. Karger AG, Basel

Introduction

Mutations in *KIT* oncogene are characteristic for gastrointestinal stromal tumors (GISTs) and for mucous and acral melanoma subtypes. Spectrum of *KIT* mutations in melanomas is slightly different from the one observed in GISTs, with exon 13 mutation p.K642E accounting

for significant share of *KIT*-driven tumors [1]. Some amino acid changes in *KIT* protein render tumors sensitive to imatinib, while others are associated with drug resistance [2]. Given the rarity of both GISTs and mucosal and acral melanomas, the cataloguing of predictive role of various *KIT* mutations represents a challenge. Here we describe a melanoma patient with a rare *KIT* mutation, who failed to respond to imatinib.

Case Report

In February 2015, a 67-year-old woman was diagnosed with T4bN0M0 melanoma of the left heel. Multiple metastatic lesions affecting inguinal lymph nodes and lungs were detected 10 months after the surgery. First-line therapy by dacarbazine (2 cycles) was administered in April 2016 and was accompanied by the disease progression. Second-line therapy (paclitaxel and carboplatin, 2 cycles), being started in June 2016, also failed to stop tumor growth. At the beginning of chemotherapy the patient was also diagnosed with a brain lesion; the metastatic nature of this lesion was initially under the question, therefore this lump was left for observation. During the course of chemotherapy this brain lesion gradually increased in size, therefore the gamma-knife treatment was applied in August 2016. Very few treatment options were left for the patient after the failure of the second-line chemotherapy. The immunotherapy could not be considered due to several limitations: ipilimumab was the only immune checkpoint inhibitor registered in Russia by that time, however it could not be easily administered due to financial constraints; also, there was no available clinical trials utilizing immune-based approaches. Meanwhile, the analysis of tumor tissue, which was removed at primary surgery, revealed a somatic *KIT* mutation p.T632I. This substitution has been repeatedly described in the literature, however no data on its sensitivity to imatinib is available [3, 4]. Similarly, there is no consistent data on the predictive value of other rare *KIT* mutations, which are located in the proximity to codon 632 [2, 5]. The closest known predictive mutation is p.K642E, which is located in the same part of the *KIT* protein (ATP-binding domain, C-helix, residues 631–647) and is clearly associated with tumor responsiveness to imatinib [6–8]. Based on this evidence, the patient was administered imatinib 400 mg twice a day. This treatment was accompanied by grade II anemia and grade II periorbital edema. The condition of the patient worsened during the imatinib therapy, with growing fatigue and ECOG status changing from 0 to 2–3. New metastatic lump was detected in the soft tissue of the left limb and the enlargement of inguinal lymph nodes was observed. Imaging analysis was performed at the 7th week of the therapy and revealed enlargement of tumor lesions (Fig. 1). Based on these data, targeted treatment was discontinued. The patient was offered best supportive care and died in December, 2016 due to further disease progression in soft tissues and lungs.

Discussion

The efficacy of imatinib for the treatment of melanomas carrying *KIT* gene mutation has been repeatedly demonstrated in several clinical studies. However, not all *KIT* mutations render imatinib sensitivity, with melanoma response rates being generally lower than in *KIT*-mutated GISTs; they usually approach to 20–25% when all *KIT* genetic lesions are considered, and reach 35–50% in melanomas with exon 11 and 13 *KIT* mutations [7, 9, 10]. Notably, the relationships between particular *KIT* mutations and tumor responsiveness to imatinib are not always straightforward: even tumors with identical mutations may vary in their sensitivity to

the treatment [7]. In particular, *KIT*-mutated tumors may demonstrate distinct addiction to *KIT* signaling, depending, for example, on the ratio between the affected and the wild-type alleles [7]. Presence of other driver mutations, e.g., in *NRAS* oncogene, may also impair the imatinib efficacy [10]. In addition, down-regulation of apoptotic pathways, intratumoral heterogeneity and plasticity of transformed cells are likely to contribute to melanoma therapy resistance [11–13].

We assume that treatment failure in the described case does not yet preclude administration of imatinib to other patients with *KIT* p.T632I or closely located mutations. However, the treatment responses of tumors with rare *KIT* mutations deserve systematic registration in order to accumulate a critical mass of evidence and guide a drug administration with a better level of precision. Current data on relevant genotype-response correlations for *KIT* mutations are summarized in online supplementary Tables 1–9 (for all online suppl. material, see www.karger.com/doi/10.1159/000495782).

Statement of Ethics

The authors have no ethical conflicts to disclose.

Disclosure Statement

The authors have no conflicts of interest to declare.

Funding Sources

This work has been supported by the Russian Science Foundation (grant 17–15–01384). Funding sources did not influence the conduction of the study or description of its results.

Author Contributions

K.V. Orlova and L.V. Demidov participated in the clinical treatment; S.N. Aleksakhina and A.R. Venina performed molecular testing; G.A. Yanus, A.G. Iyevleva and E.N. Imyanitov wrote the manuscript. All authors critically reviewed and approved the final version of the manuscript.

References

- 1 Ashman LK, Griffith R. Therapeutic targeting of c-KIT in cancer. *Expert Opin Investig Drugs*. 2013 Jan;22(1):103–15.
- 2 Beadling C, Jacobson-Dunlop E, Hodi FS, Le C, Warrick A, Patterson J, et al. *KIT* gene mutations and copy number in melanoma subtypes. *Clin Cancer Res*. 2008 Nov;14(21):6821–8.
- 3 Kong Y, Si L, Zhu Y, Xu X, Corless CL, Flaherty KT, et al. Large-scale analysis of *KIT* aberrations in Chinese patients with melanoma. *Clin Cancer Res*. 2011 Apr;17(7):1684–91.
- 4 Schoenewolf NL, Bull C, Belloni B, Holzmann D, Tonolla S, Lang R, et al. Sinonasal, genital and acrolentiginous melanomas show distinct characteristics of *KIT* expression and mutations. *Eur J Cancer*. 2012 Aug;48(12):1842–52.

- 5 Park E, Yang S, Emley A, DeCarlo K, Richards J, Mahalingam M. Lack of correlation between immunohistochemical expression of CKIT and KIT mutations in atypical acral nevi. *Am J Dermatopathol*. 2012 Feb;34(1):41–6.
- 6 Cassier PA, Blay JY. Molecular response prediction in gastrointestinal stromal tumors. *Target Oncol*. 2010 Mar;5(1):29–37.
- 7 Carvajal RD, Antonescu CR, Wolchok JD, Chapman PB, Roman RA, Teitcher J, et al. KIT as a therapeutic target in metastatic melanoma. *JAMA*. 2011 Jun;305(22):2327–34.
- 8 Laine E, Auclair C, Tchertanov L. Allosteric communication across the native and mutated KIT receptor tyrosine kinase. *PLoS Comput Biol*. 2012;8(8):e1002661.
- 9 Guo J, Si L, Kong Y, Flaherty KT, Xu X, Zhu Y, et al. Phase II, open-label, single-arm trial of imatinib mesylate in patients with metastatic melanoma harboring c-Kit mutation or amplification. *J Clin Oncol*. 2011 Jul;29(21):2904–9.
- 10 Hodi FS, Corless CL, Giobbie-Hurder A, Fletcher JA, Zhu M, Marino-Enriquez A, et al. Imatinib for melanomas harboring mutationally activated or amplified KIT arising on mucosal, acral, and chronically sun-damaged skin. *J Clin Oncol*. 2013 Sep;31(26):3182–90.
- 11 Wu S, Singh RK. Resistance to chemotherapy and molecularly targeted therapies: rationale for combination therapy in malignant melanoma. *Curr Mol Med*. 2011 Oct;11(7):553–63.
- 12 Somasundaram R, Villanueva J, Herlyn M. Intratumoral heterogeneity as a therapy resistance mechanism: role of melanoma subpopulations. *Adv Pharmacol*. 2012;65:335–59.
- 13 Ahmed F, Haass NK. Microenvironment-Driven Dynamic Heterogeneity and Phenotypic Plasticity as a Mechanism of Melanoma Therapy Resistance. *Front Oncol*. 2018 May;8:173.

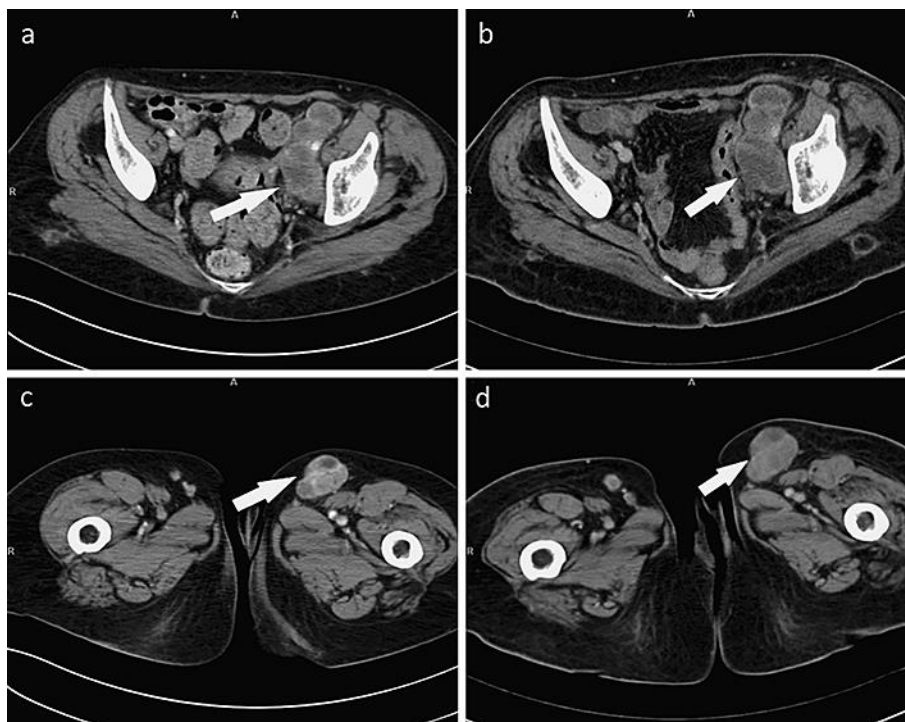


Fig. 1. Imatinib treatment of acral melanoma carrying *KIT* mutation p.T632I. Conglomerates of iliac lymph nodes increased in size from 29 mm × 39 mm (a) to 33 mm × 44 mm (b), and metastatic lumps in inguinal lymph nodes grew from 29 mm × 41 mm (c) to 33 mm × 47 mm (d) within 7 weeks of the therapy.