

Case Report

# Vogt-Koyanagi-Harada Disease-Like Uveitis during Nivolumab (Anti-PD-1 Antibody) Treatment for Metastatic Cutaneous Malignant Melanoma

Shumpei Obata<sup>a</sup> Yoshitsugu Saishin<sup>a</sup> Kazuya Teramura<sup>b</sup>  
Masahito Ohji<sup>a</sup>

<sup>a</sup>Department of Ophthalmology, Shiga University of Medical Science, Otsu, Japan;

<sup>b</sup>Department of Dermatology, Shiga University of Medical Science, Otsu, Japan

## Keywords

Vogt-Koyanagi-Harada disease · Nivolumab · Malignant melanoma · Programmed cell death protein 1 uveitis

## Abstract

Nivolumab is an anti-programmed cell death protein 1 monoclonal antibody that is used to treat metastatic cutaneous malignant melanoma. Although bilateral uveitis has been reported as a side effect of nivolumab administration, there are few reports of Vogt-Koyanagi-Harada disease (VKH)-like uveitis. We report such a case. A 63-year-old woman with metastatic cutaneous malignant melanoma experienced visual loss in both eyes 10 days after her second nivolumab injection. Her decimal best-corrected visual acuity (BCVA) was 0.7 in the right eye and 0.4 in the left eye. Examination revealed bilateral granulomatous keratic precipitates and posterior synechiae in the left eye. Optical coherence tomography showed multiple sites of serous retinal detachment (SRD) in the left eye and wavy retinal pigment epithelium in both eyes. Fluorescein angiography revealed multiple pinpoint-sized areas of leakage in both eyes and active leakage from the disc in her right eye. Indocyanine green angiography (IA) showed choroidal hyperfluorescence due to choroidal vascular leakage, with hypofluorescent dark spots during the late phase. These findings supported a diagnosis of VKH-like uveitis following nivolumab injections. Nivolumab was discontinued because of headache. Anterior chamber

inflammation disappeared 3 weeks after starting topical corticosteroid treatment, and the SRD disappeared within 3 months. Her decimal BCVA recovered to 1.0 in the right eye and to 0.9 in the left eye. Also, the fluorescein angiography and IA findings had improved by 4 months. We concluded that careful follow-up is required after nivolumab treatment because VKH-like panuveitis might develop.

© 2019 The Author(s)  
Published by S. Karger AG, Basel

## Introduction

Vogt-Koyanagi-Harada disease (VKH) is a bilateral, diffuse, granulomatous uveitis. The autoimmune mechanisms are believed to be directed against melanocytes [1, 2]. Nivolumab, a human immunoglobulin G4 monoclonal antibody against human programmed cell death protein 1 (PD-1), has been recently introduced as a targeted therapy for unresectable or metastatic melanoma [3]. Nivolumab has been approved for treatment in patients with nonsurgical or metastatic melanoma, metastatic non-small-cell lung cancer, renal cell carcinoma, classic Hodgkin's lymphoma, squamous cell carcinoma of the head and neck, and urothelial carcinoma [4–7]. Patients with metastatic cutaneous malignant melanoma have been reported to develop uveitis after nivolumab (anti-PD-1 antibody) injection [4, 8–10]. We report a patient with malignant melanoma who developed VKH-like bilateral uveitis shown clearly by specific indocyanine green angiography (IA) during a course of treatment with nivolumab for malignant melanoma.

## Case Presentation

A 63-year-old woman first discovered a black lesion in the femoral area in July 2016. She finally visited a hospital in February 2017, at which time a biopsy showed that the lesion was malignant melanoma. She then underwent positron emission tomography with computed tomography, which showed multiple metastatic lesions in the inguinal, hilar, and mediastinal nodes. The primary lesion was excised in March 2017. Mediastinoscopy revealed that the hilar and mediastinal node lesions were the result of a sarcoid reaction. Hence, in May 2017, she underwent inguinal node dissection with a pathological diagnosis of metastatic melanoma. Not long afterward, it was discovered that her primary malignant melanoma had recurred.

Vemurafenib was started in August 2017, but it was discontinued because it caused fever. Nivolumab was injected in October and November 2017. At 10 days after the second nivolumab injection, the patient suffered visual loss in both eyes. She was referred to an ophthalmologist for evaluation of the bilateral visual obscuration. At the initial examination, her decimal best-corrected visual acuity (BCVA) was 0.7 in the right eye and 0.4 in the left, with an intraocular pressure of 8 mm Hg in the right eye and 11 mm Hg in the left eye. Granulomatous keratic precipitates and cells were found in the anterior chamber in both eyes and posterior synechiae in the left eye. A mild vitreous opacity was found at the inferior quadrant. Fundus examination and optical coherence tomography (OCT) (Cirrus OCT; Carl Zeiss Meditec, Dublin, CA, USA) confirmed the presence of multiple sites of serous retinal detachment (SRD) in the left eye and wavy retinal pigment epithelium in both eyes (Fig. 1). On fluorescein angiography using Spectralis® HRA+OCT equipment (Heidelberg Engineering, Heidelberg, Germany), multiple pinpoint-sized areas of leakage were found in both eyes as well as active leakage from the disc in the right eye (Fig. 1). IA using Spectralis® HRA+OCT revealed findings characteristic of VKH, such as choroidal hyperfluorescence due to choroidal vascular leakage

and hypofluorescent dark spots during the late phase (Fig. 1). HLA typing revealed A24, B61, B48, and DR9.

We assigned a diagnosis of bilateral panuveitis similar to VKH. Nivolumab had been discontinued because of headache by the dermatologist, and we started topical corticosteroid (betamethasone sodium phosphate 0.1%) four times a day and daily topical tropicamide phenylephrine hydrochloride at night.

The granulomatous keratic precipitates and cells in the anterior chamber disappeared 3 weeks after starting the topical treatment, and the multiple SRDs and wavy retinal pigment epithelium gradually disappeared (Fig. 2). At 4 months after starting treatment, her decimal BCVA had recovered to 1.0 in the right eye and to 0.9 in the left eye. Fluorescein angiography showed that the multiple pinpoint-sized leakage sites in both eyes and the active leakage from the disc in the right eye had diminished (Fig. 2). IA revealed that the findings characteristic of VKH (e.g., choroidal hyperfluorescence due to choroidal vascular leakage and hypofluorescent dark spots) had also decreased (Fig. 2). Choroidal thickness was 369.3  $\mu\text{m}$  in the right eye and 663.3  $\mu\text{m}$  in the left eye before treatment. After 4 month of treatment, choroidal thickness was 285.4  $\mu\text{m}$  in the right eye and 218.4  $\mu\text{m}$  in the left eye, measured using Spectralis® HRA+OCT. In addition, her bilateral fundi appeared red and depigmented (Fig. 3), and her hair had lost its natural color and became grayer.

## Discussion and Conclusions

Nivolumab is an anti-PD-1 monoclonal antibody. Activated suppressor T cells inhibit the immune surveillance of neoplastic cells, enhancing tumor growth. Nivolumab inhibits suppressor T cells. Malignant melanoma cells and normal choroidal melanocytes could share a target epitope for T cell recognition. Nivolumab is also directed against normal choroidal melanocytes [3, 7].

The important diagnostic points directing attention to VKH-like uveitis in this patient first became apparent when slit-lamp examination revealed the presence of bilateral granulomatous keratic precipitates and anterior chamber cells. The second major discovery as a manifestation of VKH was the wavy, retinal pigment epithelium, which is caused by multifocal thickened choroidal lesions, and the multiple sites of SRD that were visualized using OCT [11]. Third, IA revealed choroidal hyperfluorescence due to choroidal vascular leakage and hypofluorescent dark spots during the late phase, which is typically seen with VKH. Fourth, the patient had no history of either penetrating ocular trauma before the onset of uveitis or surgery on either eye.

The standard treatment for VKH is high-dose systemic corticosteroids. Since in our case the patient's general condition was poor and nivolumab had been discontinued because of headache by the dermatologist, a topical rather than systemic corticosteroid was administered. The patient's ocular pathology had diminished partially because of discontinuation of nivolumab and partially because of the topical corticosteroid treatment. In other reports, a topical, oral, or subconjunctivally injected corticosteroid was used for treatment. All of those patients, regardless of the administration route, had responded to the treatment [4, 8–10].

To our best knowledge, there have been no reports of IA being used to identify patients with malignant melanoma who developed VKH-like uveitis during the course of nivolumab injections. The characteristic findings of VKH (e.g., choroidal hyperfluorescence due to choroidal vascular leakage and hypofluorescent dark spots) shown by IA diminished (Fig. 1, 2).

We undertook HLA typing [12] and found that the HLA types were A24, B61, B48, and DR9. These HLA types are different from the typical HLA types seen in VKH patients (i.e., HLA-B54, DR4, DR53, and DQ4). HLA types may not be relevant to the onset of VKH-like uveitis caused by nivolumab. Nivolumab may alter patients' immune condition strongly enough for them to develop VKH-like uveitis, even those without the typical HLA types seen in VKH patients. Therefore, we should carefully follow these patients even if they do not have HLA types usually related to VKH.

In other reports, nivolumab was not stopped because of immune-related adverse events of the eyes [4, 9, 10]. However, in one report, nivolumab was stopped because of immune-related adverse events of the eyes. After the decrease in ocular inflammation and complete visual acuity recovery, treatment with nivolumab was re-initiated [8]. We should decide whether nivolumab should be stopped between the ophthalmologist and the dermat-oncologist team. In some reports, only topical prednisolone acetate (1%) without systemic corticosteroid was initiated as the primary therapy [4, 9, 10]; however, in another report, systemic corticosteroid was used after discussion between the ophthalmologist and the dermat-oncologist team [8]. We should decide the treatments with following general and ocular condition.

We have reported a VKH-like bilateral uveitis that occurred during the course of nivolumab injections given to treat metastatic cutaneous malignant melanoma. It is recognized that IA findings are useful for diagnosing and evaluating treatment responses in patients with VKH-like uveitis. As the use of nivolumab may come into more widespread use in the future, uveitis that appears during nivolumab administration must be rapidly recognized based on examination of the eyes. When we see VKH-like uveitis, we should obtain the history of nivolumab treatment. In addition, after nivolumab treatment, we should carefully follow the patient because VKH-like uveitis could develop. We should choose treatments with checking general and ocular condition.

### Acknowledgement

The authors thank Nancy Schatken, BS, MT(ASCP), from Edanz Group (www.edanzediting.com/ac), for editing a draft of the manuscript.

### Statement of Ethics

The authors have no ethical conflicts to disclose.

### Disclosure Statement

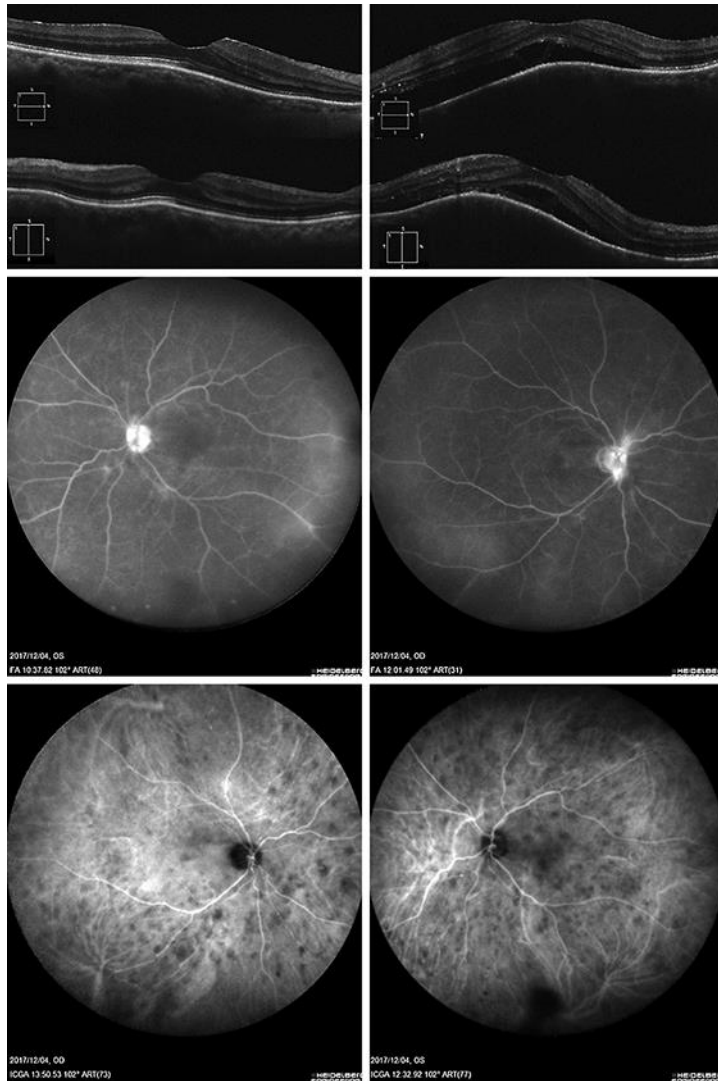
The authors have no conflicts of interest to declare.

### Funding Sources

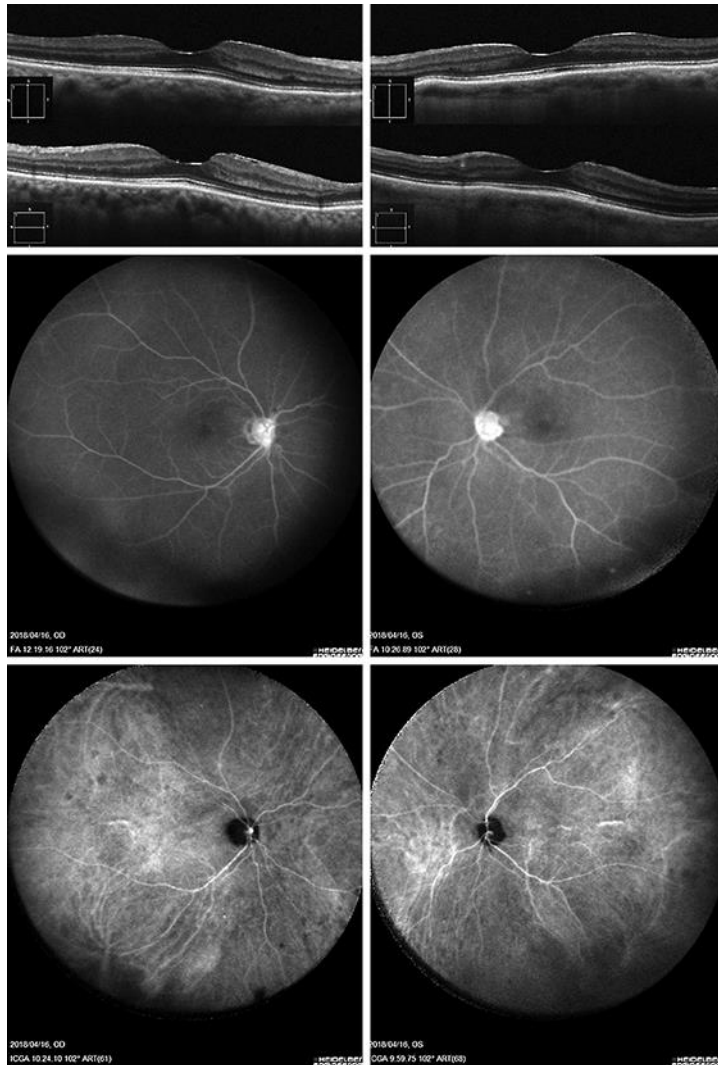
The authors received no financial support for the research, authorship, and/or publication of this article.

## References

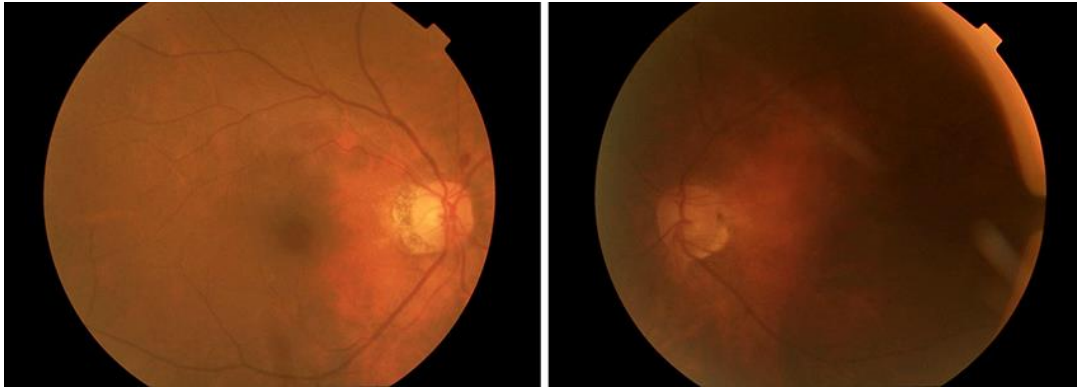
- 1 Moorthy RS, Inomata H, Rao NA. Vogt-Koyanagi-Harada syndrome. *Surv Ophthalmol*. 1995 Jan–Feb;39(4):265–92.
- 2 Sakata VM, da Silva FT, Hirata CE, de Carvalho JF, Yamamoto JH. Diagnosis and classification of Vogt-Koyanagi-Harada disease. *Autoimmun Rev*. 2014 Apr–May;13(4–5):550–5.
- 3 Sunshine J, Taube JM. PD-1/PD-L1 inhibitors. *Curr Opin Pharmacol*. 2015 Aug;23:32–8.
- 4 Matsuo T, Yamasaki O. Vogt-Koyanagi-Harada disease-like posterior uveitis in the course of nivolumab (anti-PD-1 antibody), interposed by vemurafenib (BRAF inhibitor), for metastatic cutaneous malignant melanoma. *Clin Case Rep*. 2017 Mar;5(5):694–700.
- 5 Brahmer J, Reckamp KL, Baas P, Crinò L, Eberhardt WE, Poddubskaya E, et al. Nivolumab versus docetaxel in advanced squamous-cell non-small-cell lung cancer. *N Engl J Med*. 2015 Jul;373(2):123–35.
- 6 Motzer RJ, Escudier B, McDermott DF, George S, Hammers HJ, Srinivas S, et al.; CheckMate 025 Investigators. Nivolumab versus everolimus in advanced renal-cell carcinoma. *N Engl J Med*. 2015 Nov;373(19):1803–13.
- 7 Rajan A, Kim C, Heery CR, Guha U, Gulley JL. Nivolumab, anti-programmed death-1 (PD-1) monoclonal antibody immunotherapy: role in advanced cancers. *Hum Vaccin Immunother*. 2016 Sep;12(9):2219–31.
- 8 Theillac C, Straub M, Breton AL, Thomas L, Dalle S. Bilateral uveitis and macular edema induced by Nivolumab: a case report. *BMC Ophthalmol*. 2017 Dec;17(1):227.
- 9 Baughman DM, Lee CS, Snydsman BE, Jung HC. Bilateral uveitis and keratitis following nivolumab treatment for metastatic melanoma. *Med Case Rep (Wilmington)*. 2017;3(2):8.
- 10 Arai T, Harada K, Usui Y, Irisawa R, Tsuboi R. Case of acute anterior uveitis and Vogt-Koyanagi-Harada syndrome-like eruptions induced by nivolumab in a melanoma patient. *J Dermatol*. 2017 Aug;44(8):975–6.
- 11 Shinoda K, Imamura Y, Matsumoto CS, Mizota A, Ando Y. Wavy and elevated retinal pigment epithelial line in optical coherence tomographic images of eyes with atypical Vogt-Koyanagi-Harada disease. *Graefes Arch Clin Exp Ophthalmol*. 2012 Sep;50(9):1399–402.
- 12 Ohno S, Ishibayashi Y, Ichiishi A, Oguma Y, Kotake S, Matsuda H, et al. Studies of HLA-antigens in Vogt-Koyanagi-Harada's disease and sympathetic ophthalmia. In: Secchi AG, Fregona IA, editors. *Modern trends in immunology and immunopathology of the eye*. Milan: Masson; 1989. p. 452–3.



**Fig. 1.** Right eye (left) and left eye (right). Vertical sections of optical coherence tomography scans before treatment. There are multiple sites of serous retinal detachment in the left eye and wavy retinal pigment epithelium in both eyes. Fluorescein angiography scans before treatment revealed multiple pinpoints of leakage in both eyes as well as active leakage from the disc in the right eye. Indocyanine green angiography also revealed choroidal hyperfluorescence due to choroidal vascular leakage, followed by hypofluorescent dark spots at a later time.



**Fig. 2.** Right eye (left) and left eye (right). Vertical sections of optical coherence tomography scans 4 months after treatment showed fewer serous retinal detachment sites and a reduced amount of wavy retinal pigment epithelium. Fluorescein angiography 4 months after treatment showed reduced fluorescein dye leakage. Indocyanine green angiography 4 months after treatment indicated that the multiple dark spots had almost all disappeared.



**Fig. 3.** Photographs 4 months after treatment showed red depigmented fundus in both eyes.