

Case Report

# Maxillary Zoster and Neurotrophic Keratitis following Trigeminal Block

Yang Kyung Cho<sup>a</sup> JinWoo Kwon<sup>a</sup> Sangeetha Pugazhendhi<sup>b</sup>  
Balamurali K. Ambati<sup>c</sup>

<sup>a</sup>Department of Ophthalmology, St. Vincent's Hospital, College of Medicine, The Catholic University of Korea, Suwon, South Korea; <sup>b</sup>Pacific Clear Vision Institute, PSG Institute of Medical Science and Research, Eugene, OR, USA; <sup>c</sup>Department of ophthalmology, University of Utah School of Medicine, Salt Lake City, UT, USA

## Keywords

Maxillary herpes zoster · Neurotrophic keratitis · Trigeminal nerve block

## Abstract

Herpes zoster ophthalmicus is commonly used to describe viral reactivation from the trigeminal ganglia with ocular involvement. The ophthalmic branch is the most commonly involved, whereas the maxillary and mandibular dermatomes are less commonly affected. Neurotrophic ulcer may occur secondary to intentional or inadvertent damage to the trigeminal nucleus, root, ganglion, or any segment of the ophthalmic branch of this cranial nerve. We report a case of reactivated maxillary herpes zoster combined with neurotrophic keratitis due to percutaneous 2nd and 3rd branch of trigeminal nerve block with alcohol to treat trigeminal neuralgia. A 57-year-old female came to the ophthalmology department complaining of decreased visual acuity and skin vesicle over the right lower lid and cheek. She had undergone right trigeminal nerve block for treatment of trigeminal neuralgia. Clinical examination revealed neurotrophic keratitis and maxillary herpes zoster. She was treated with oral and topical antivirals and vigorous lubrication with eye drops. Her neurotrophic keratitis showed a slow recovery. Although a few cases of herpes zoster following nerve block have been described, it would appear that a case of simultaneous maxillary herpes zoster and neurotrophic keratitis following trigeminal block has not yet been documented. It is possible that trigeminal nerve block may cause reactivation of latent virus and refractory neurotrophic keratitis.

© 2019 The Author(s)  
Published by S. Karger AG, Basel

## Introduction

Herpes zoster is the clinical entity caused by reactivation of the latent varicella zoster virus from sensory ganglia [1]. While any sensory ganglia may be involved, herpes zoster ophthalmicus is commonly used to describe viral reactivation from the trigeminal ganglia with ocular involvement [1]. Among the three divisions of the trigeminal nerve, herpes zoster along the maxillary division of the trigeminal nerve is a rare condition [2, 3]. Generally, the ophthalmic branch is the most commonly involved, whereas the maxillary and mandibular dermatomes are less commonly affected [3].

Factors that decrease immune function, such as human immunodeficiency virus infection, chemotherapy, malignancies, trauma, surgery, and chronic corticosteroid use, may also reactivate the herpes zoster virus [1].

Ophthalmic manifestations of herpes zoster ophthalmicus include lid edema and vesicle formation, conjunctivitis, episcleritis, scleritis, and keratitis [1]. Chronologically, corneal findings are punctate epithelial keratitis, pseudodendrites, stromal keratitis, kerato-uveitis, endothelitis, and neurotrophic keratitis [1]. Herpes zoster ophthalmicus is one of the most common causes of neurotrophic keratopathy [1].

In addition to corneal manifestation, postherpetic neuralgia is a common complication after herpes zoster infection. One treatment of postherpetic neuralgia due to herpes zoster is trigeminal nerve block [4, 5]. However, contrastingly, nerve block can reactivate herpes zoster such as herpes zoster following axillary nerve block [6] and herpes zoster oticus following mandibular block [7]. We report a case of neurotrophic keratitis and reactivation of herpes zoster following trigeminal nerve block to treat trigeminal neuralgia.

## Case Report

A 57-year-old female came to the ophthalmology department complaining of decreased visual acuity. According to patient history and previous medical records, the patient had been known to suffer from trigeminal neuralgia for several decades. She had previously undergone a central nervous system examination to determine the etiologic lesion of trigeminal neuralgia, but was informed of the incidental finding of an epidermoid cyst impinging on the trigeminal nerve.

She underwent brain surgery for partial removal of the epidermoid tumor. After the brain surgery, her trigeminal neuralgia had subsided for several years but had reappeared, causing her to visit the anesthesiology clinic for treatment of the debilitating pain.

She had undergone right trigeminal nerve block (percutaneous block of maxillary, mandibular nerve with alcohol and infraorbital nerve block) for pain treatment. Under the fluoroscopic view, for maxillary nerve block, a needle tip can be located right lateral to the foramen rotundum and pterygopalatine fossa; for mandibular nerve block, a needle tip can be placed at the midportion of the foramen ovale.

Her pain had decreased with right-side facial numbness. After 3 days posttrigeminal block, she presented with vesicles over the right lower lid and cheek. A clinical diagnosis of herpes zoster infection of the maxillary branch of the trigeminal nerve was made. She was started on oral famciclovir 250 mg every 8 h. She noticed progressively decreasing visual acuity around 10 days after trigeminal block, during her treatment with famciclovir.

She was referred to the ophthalmology department of St. Vincent's Hospital. She had never been to an ophthalmologist before this event. On initial examination, her visual acuity

was 0.06 (0.25 with pin-hole correction) in the right eye and 0.16 ( $0.8 \times -3.25$  Dsph;  $-0.50$  Dcyl A  $\times$  94) in the left eye. Intraocular pressure was 13 mm Hg (right eye)/10 mm Hg (left eye). At slit lamp examination, her cornea showed an irregular epithelial defect with Descemet's membrane folding (Fig. 1).

There was no cell reaction in the anterior chamber. Clinically, she was then diagnosed with neurotrophic keratitis by trigeminal block, and less likely herpes zoster keratitis from herpes zoster ophthalmicus involving the ophthalmic branch of the trigeminal nerve.

She was treated with oral famciclovir 750 mg per day, topical 3% acyclovir ointment 5 times per day, and hourly Solcoseryl eye drops (1.4%) and 50% autologous serum eye drops. She showed fast recovery of the right cornea with epithelial closure and her visual acuity was increased to 0.5 within 3 days of treatment.

However, 2 days after epithelial healing, she reappeared with decreased visual acuity of the right eye. Her visual acuity decreased again to 0.02 and the cornea showed central and peripheral geographic epithelial defect with Descemet's folding (Fig. 2).

Along with the previous treatment of oral and topical antiviral and lubrication with Solcoseryl and autologous serum, her lower lacrimal punctum was temporarily occluded with a punctal plug and she was on hourly 5% albumin eye drops. Varicella zoster virus PCR was also done. An HIV serological test was done and the result was negative.

Her cornea showed slower recovery in epithelial healing. Five days after the second outbreak of epithelial keratitis, the epithelial defect slightly decreased but the Descemet's folding remained. Her visual acuity was 0.15.

One month after block, her cornea showed central opacity and faint peripheral linear epithelial irregularity. Endothelial cell damage was observed compared with the contralateral eye. The scar on her cheek remained (Fig. 3).

## Discussion/Conclusion

Trigeminal neuralgia is a severe, intermittent, electric shock-like pain in the face [8]. The exact etiology of trigeminal neuralgia is not certain but is hypothesized to be caused by compression or an underlying condition of the trigeminal nerve, such as tumors, cysts, arteriovenous malformation, and multiple sclerosis [8, 9].

There is a wide range of treatments available. Alcohol nerve injections or neurectomy of the trigeminal nerve is one of the surgical treatments of trigeminal neuralgia, which may be effective if these are the areas affected by pain [8, 9]. Several studies concluded that peripheral alcohol injections have a role in the management of trigeminal neuralgia [8, 9].

In this case report, we report a case of reactivated maxillary herpes zoster combined with neurotrophic keratitis due to percutaneous trigeminal nerve block with alcohol to treat trigeminal neuralgia. The suspected cause of trigeminal neuralgia is epidermoid cyst compression of the cisternal trigeminal nerve.

From patient history and medical records, the nerve block was administered in the 2nd and 3rd branch of the trigeminal nerve. This direct surgical trauma to the maxillary branch of the trigeminal nerve may have caused maxillary zoster reactivation. The alcohol injection is suspected to minimally affect the 1st branch presumptively because it reaches the area through vascular, neurologic, myofascial, and/or lymphatic networks to cause neurotrophic keratitis [10].

As far as we know, this is a rare case report of maxillary herpes zoster following trigeminal nerve block in a patient combined with neurotrophic keratitis. In a typical herpes zoster

infection, only the maxillary area of eruption is very rare [2, 3]. This patient's maxillary zoster is suspected to have been reactivated by direct surgical trauma to the maxillary branch of the trigeminal nerve.

The corneal neurotrophic lesion of this patient was difficult to differentiate with herpes zoster reactivation because the epithelial lesion looked dendritic and geographic in shape. The skin vesicle and scar were limited to the area of the maxillary dermatome; therefore, we diagnosed this as maxillary herpes reactivation in this patient. The varicella zoster virus PCR was negative. This diagnosis is needed because we do not need to use antivirals unnecessarily in neurotrophic keratitis alone.

In this case, this neurotrophic ulcer reoccurred several times, sometimes with fast recovery and other times with slow recovery, even with maximum treatment. Even without direct involvement of the ophthalmic branch, the maxillary and mandibular trigeminal block can affect the adjacent ophthalmic branch, which leads to neurotrophic keratitis. Usually, a herpes zoster neurotrophic ulcer occurs in chronological order, but a surgically induced trigeminal nerve block-induced neurotrophic ulcer begins early [4].

In conclusion, the trigeminal nerve block can reactivate herpes zoster in the area of nerve supply which was blocked, and neuropathy can occur by the indirectly affected adjacent branch of the trigeminal nerve. Because there is no pain sensation in neurotrophic keratitis, patients usually come to the ophthalmologist when they notice considerably decreased visual acuity. Earlier diagnosis and aggressive treatment of neurotrophic keratitis is recommended.

### Statement of Ethics

The authors have no ethical conflicts to disclose.

### Disclosure Statement

The authors have no conflicts of interest to declare.

### Funding Sources

The authors did not receive funding.

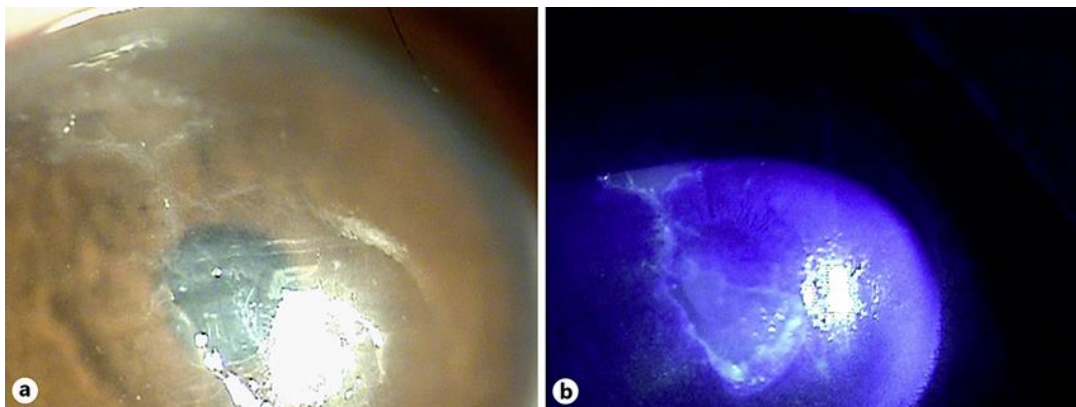
### Author Contributions

Yang Kyung Cho examined the patient, wrote the manuscript, and edited the manuscript. JinWoo Kwon wrote and edited the manuscript. Sangeetha Pugazhendhi wrote and edited the manuscript. Balamurali K. Ambati wrote and edited the manuscript.

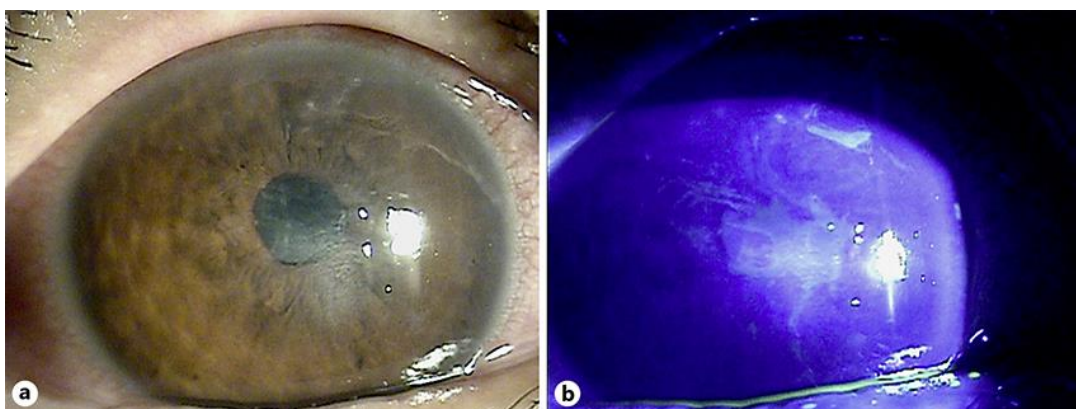
### References

- 1 Krachmer JH, Mannis MJ, Holland EJ. Herpes Zoster Keratitis. In: Krachmer JH, Mannis MJ, Holland EJ, editors. *Cornea*. 3rd ed. St. Louis: Mosby; 2011. p. 985–1000.

- 2 Omoti AE, Omoti CE. Maxillary herpes zoster with corneal involvement in a HIV positive pregnant woman. *Afr J Reprod Health*. 2007 Apr;11(1):133–6.
- 3 Paquin R, Susin LF, Welch G, Barnes JB, Stevens MR, Tay FR. Herpes Zoster Involving the Second Division of the Trigeminal Nerve: Case Report and Literature Review. *J Endod*. 2017 Sep;43(9):1569–73.
- 4 Kodama-Takahashi AK, Sugioka K, Sato T, et al. Neurotrophic Keratopathy after Trigeminal Nerve Block for Treatment of Postherpetic Neuralgia. *Case Rep Ophthalmol Med*. 2018 May;2018:6815407.
- 5 Koshy RC. A V. Successful pain management of post herpetic ophthalmic neuralgia with regional nerve blocks- a case report. *Indian J Anaesth*. 2003;47(4):304–5.
- 6 Percival NJ. Shingles following axillary nerve block. A case report. *J Hand Surg Br*. 1986 Feb;11(1):115–6.
- 7 Maini S, Preece M. Herpes zoster oticus following mandibular block. *J Laryngol Otol*. 2000 Mar;114(3):212–3.
- 8 Tadakamadla J, Mamatha GP. Treatment of trigeminal neuralgia – A review. *J Oral Health Res*. 2010 Jan;1(1):9–18.
- 9 Han KR, Chae YJ, Lee JD, Kim C. Trigeminal nerve block with alcohol for medically intractable classic trigeminal neuralgia: long-term clinical effectiveness on pain. *Int J Med Sci*. 2017 Jan;14(1):29–36.
- 10 Boynes SG, Echeverria Z, Abdulwahab M. Ocular complications associated with local anesthesia administration in dentistry. *Dent Clin North Am*. 2010 Oct;54(4):677–86.

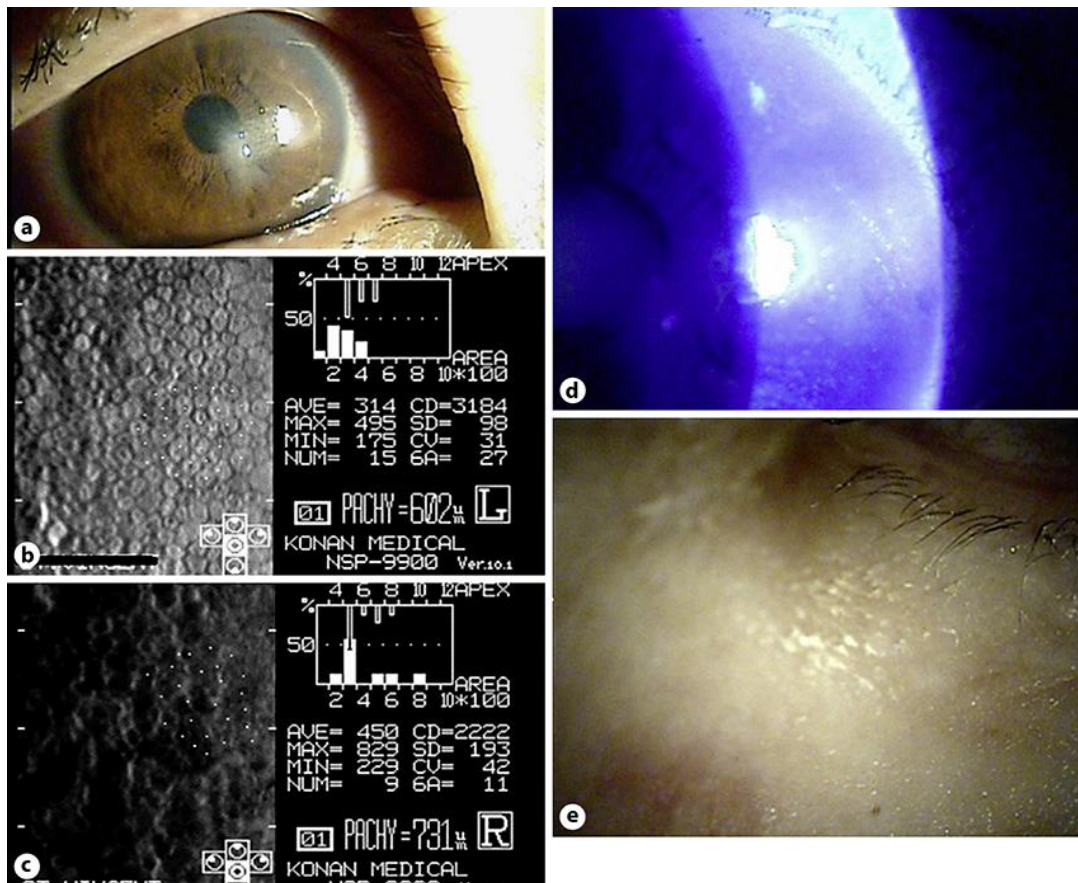


**Fig. 1.** a Epithelial defect and Descemet's membrane folding. b Fluorescein staining of epithelial defect.



**Fig. 2.** a Geographic epithelial defect and recurrent Descemet's membrane folding. b Geographic fluorescein staining of epithelial defect.





**Fig. 3.** **a** Remaining central corneal opacity. **b** Specular microscopy of uninvolved left eye. **c** Specular microscopy of right eye. **d** Peripheral epithelial staining and linear epithelial irregularity. **e** Skin vesicle scar on right cheek.