

computed tomography, rapid prototyping, reverse engineering

Robert KARPIŃSKI, Józef JONAK*, Jacek MAKSYMIUK***

MEDICAL IMAGING AND 3D RECONSTRUCTION FOR OBTAINING THE GEOMETRICAL AND PHYSICAL MODEL OF A CONGENITAL BILATERAL RADIO-ULNAR SYNOSTOSIS

Abstract

The paper presents results of a 3D reconstruction of a congenital bilateral radio-ulnar synostosis. Basics of anatomy and biomechanical analysis of the elbow joint were introduced. Case report of a congenital bilateral radio-ulnar synostosis was presented. Based on the data from computed tomography imaging, the model of a congenital bilateral radio-ulnar synostosis was constructed. Basic information on reverse engineering, rapid prototyping and methods of making physical models are presented. The creation of physical models was aimed at pre-operative planning and conceptualization. Physical models were also used in the educational form at the stage of communication with the patient.

1. INTRODUCTION

Skeletal diseases and injuries are considered as one of the most important problems of modern civilization. The combination of potential technical and medical sciences has enabled the development of biomedical engineering, especially in the field of medical imaging techniques and typical issues in the field of engineering modelling. The effect of these activities is the ability to obtain three-dimensional models, both virtual and physical, of any anatomical structures of living organisms (Skalski & Haraburda, 2009; Karpiński, Jaworski & Zubrzycki, 2016; Kozłowska & Zubrzycki, 2017).

* Department of Machine Design and Mechatronics, Faculty of Mechanical Engineering, Lublin University of Technology, Nadbystrzycka 36, 20-618 Lublin, Poland, r.karpinski@pollub.pl

** Orthopedic Department, Łęczna Hospital, Krasnystawska 52, 21-010 Łęczna, Poland

The use of reverse engineering and rapid prototyping methods is extremely important at the stage of planning of the surgical procedure and plays a significant role in educational process (Holubar, Hassinger & Dozois, 2009; Hurson, Tansey, O'Donnchadha, Nicholson, Rice & McElwain, 2007; McGurk, Potamianos, Amis & Goodger, 1997; Petzold, Zeilhofer & Kalender, 1999). Rapid Prototyping (RP) is a production technology that is currently used in many industries. It is used to create three-dimensional models accurately reproducing structures based on source data from imaging, and then to make their physical counterparts (Zubrzycki & Braniewska, 2017; Frame & Huntley, 2012). In orthopaedics and traumatology of the locomotor system this technique finds application in cases where traditional imaging methods are insufficient, especially in cases where complicated fractures and deformations occur, in which it is necessary to perform a 3D reconstruction (Brown, Firoozbakhsh, DeCoster, Reyna Jr, & Moneim, 2003; Guarino, Tennyson, McCain, Bond, Shea & King, 2007).

The digital record of the results of medical imaging makes it possible to present the reverse engineering process, in which the real model is transformed into a virtual model using the spatial measurement technique. This technique plays a huge role in clinical practice, especially at the stage of planning the surgical procedure and determining its course. The created models are also used as an educational tool. Visualization of anatomical structures through the creation of virtual and material models gives the opportunity to analyze the musculoskeletal structures, classify and assess clinical cases and consider possible treatment options (Mulford, Babazadeh & Mackay, 2016; Bagaria, Deshpande, Rasalkar, Kuthe & Paunipagar, 2011).

In the described case, reconstruction of bone structure congenital bilateral radio-ulnar synostosis on both upper limbs was performed on the basis of image data from computed tomography. The creation of physical models was aimed at pre-operative planning and conceptualization, an attempt to separate the connected bones. Physical models were also used in the educational form at the stage of communication with the patient.

Written informed consent was obtained from the patient for publication of this case report and any accompanying images.

2. ANATOMY OF THE ELBOW JOINT

Human have reached a high stage in his evolutionary development, among other things thanks to the excellent functions of the upper limbs. It was possible because of the complicated structure, which consists of numerous joints, muscles and bones as well as vessels and nerves. The elbow joint and proper connection between the bones of the forearm enables a proper positioning of the hand for precise work.

The elbow joint is a hinge joint that enables flexion and extension of the forearm. It consists of the brachio-ulnar and brachioradial connections that fully support the lateral collateral and medial collateral ligaments. In the proper functioning of the entire upper limb, the proximal radio-ulnar joint plays a significant role. This is a rotary joint in which movements are pronation and supination of the forearm takes place between the head of the radius and the radial notch of the ulna. Stems of the radius and ulna bones form the central radial-cubital joint. Interosseous membrane connecting these two bones by a 3 centimetres distal to the tuberosity of the radius bone and extend over the entire length of the forearm. The distal radio-ulnar joint is a rotating joint formed by the head of the ulna and ulnar indentation of the radius bone. Movements performed in this joint are conversion (pronation) and inverting (supination) of the forearm.

Congenital radio-ulnar synostosis is a rarely occurring anomaly. The case was firstly described by Sandifort in 1797. To this day only 350 cases have been recorded. Its inheritance may be autosomal and dominant (Rizzo, Pavone, Corsello, Sorge & Opitz, 1997).

During the embryonic development, at approximately 5th week, cartilaginous analogues of radial, ulnar and humeral bones are unified for a short time. At about 8th week, forearm bones are placed in pronation, and in this position an ossification begins. If a correct division of ulnar and radial bone doesn't occur, they remain connected. In consequence, the synostosis limits the movements of pronation and supination, what could be noted approximately three years after birth, when the child demonstrates problems with catching a ball and holds toys with the hand directed to the back (Hansen & Andersen, 1970). Congenital radio-ulnar synostosis is bilateral in 60% of cases and occurs at men more often than at women in proportion of 3:2 (Al-Saadi & Havekrog, 2008).

3. CONGENITAL BILATERAL RADIO-ULNAR SYNOSTOSIS CASE REPORT

The paper focuses on a case of a 30-year-old Caucasian female with bilateral congenital radio-ulnar synostosis in proximal parts of both forearms, without other changes or inborn diseases. The patient was diagnosed with double congenital radio-ulnar synostosis 6 months after birth. It was decided to start an observation period of the patient, without any surgical interventions. At the age of 2, limitations in pronation and supination movements of both forearms had been noticed. It manifested with difficulties while playing with other children, holding a pen and performing household activities. After 8 years, a faulty posture was diagnosed, therefore the attending physician recommended exercises for strengthening back muscles as well as respiratory exercises. At the age of 25, the patient started to complain about pain in her right limb, therefore a rehabilitation

and pain relievers were prescribed. Five years later the carpal tunnel syndrome of the right wrist was diagnosed, and a year after that the carpal tunnel release surgery was performed, reducing the pain. However, in this period the patient started observing numbness and cramps in left hand, mainly while writing and combing. An ultrasound scan of both forearms was conducted, resulting in the manifestation of a conflict of tendon and median nerve. A comparative X-ray test was carried out on both forearms with an elbow joint in the postero-anterior (Fig. 1a) and lateral projection (Fig. 1b), illustrating changes typical for the bilateral congenital radio-ulnar synostosis in proximal part of the limb.

Due to persistent pain and numbness complaints of the left hand, magnetic resonance was advised for both wrists, however no changes were stated within median nerves.

At the age of 32, the patient reported the pain in the right hand, hence the idea of performing the electromyography (EMG) exam, which was conducted on median, radial and ulnar nerves. In the examination of the ulnar nerve, a double – sided decrease of amplitude were stated, approximately 2 cm below cubital tunnel, with areas indicating a blockage of conductivity.

In order to assess the exact anatomical changes, a computed tomography (CT) with 3D reconstruction was advised for both forearms (including elbow joints).

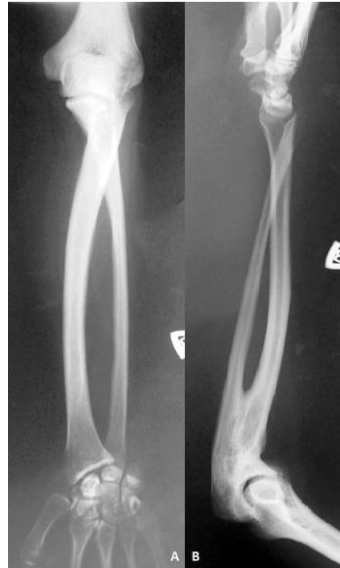

Fig. 1. X-ray image of the left forearm in postero-anterior (a) and lateral (b) projection

4. MEDICAL IMAGING AND 3D RECONSTRUCTION

A computed tomography is a diagnostic method used for non-invasive spatial imaging of patient's internal organs by conducting a sequence of body-section X-Ray images.

Materialise Mimics software allows user to process and edit 2D DICOM images obtained from computed tomography or magnetic resonance imaging scanners in order to generate 3D models. Software can distinguish several structures and tissues of human body, based on their colour in the Hounsfield scale, reflecting an apparent density of discussed tissue(Karpiński, Jaworski & Zubrzycki, 2017; Karpiński, Jaworski, Szala & Mańko, 2017).

If needed, a value of the apparent density can be assigned to a corresponding area of a 3D model in order to obtain a more accurate model for further research, involving finite elements analysis in particular. Furthermore, researchers can evaluate and improve the geometrical model using Remesh tool, e.g. to reduce the number of faces in a polygon mesh or to smooth the surface of the model (Zubrzycki, Karpiński & Górniak, 2016).

4.1. Background on computed tomography

X-ray transmission computer tomography is a type of X-ray spectroscopy. Computed tomography is a non-invasive diagnostic method that allows obtaining layer images of the examined object. It allows the imaging of the spatial distribution of the internal organs of the patient. The test consists of performing the sequence of layered X-ray images in a plane perpendicular to the axis of the body. In computed tomography, a thin transverse cross-section of the body is irradiated at many angles with a narrow X-ray beam, which after passing through the examined object is registered on its other side on the detector panel. X-rays passing through the test object are weakened, which is described as a function of energy of radiation, thickness and a type of the test material. The amount of the beam that has been dispersed or absorbed per unit of thickness of the object exposed to radiation is represented by the linear absorption coefficient. The radiation passing through the tissues is measured with a scintillation counter. The collected data is introduced to computer software where, with the use of appropriate mathematical algorithms, its analysis and reconstruction is performed in the form of an image of the screened layer. Collected radiographic images represent the difference depending on the absorption coefficient of the radiation for particular tissues. Computer tomography images are the most popular source of data on the geometry of human internal structures. When the projection is gathered information about the apparent density of each layer of radiation projection by measuring the coefficient of HU (Hounsfield) (Skalski, Grygoruk, Makuch & Dąbrowska-Tkaczyk, 2015; Ratajczyk, 2012; Budzik, Dziubek & Turek, 2015).

4.2. Developing of the virtual model of the structure

A series of computed tomography scans was conducted, resulting in a set of 2D images of consecutive cross-sections of studied limb, perpendicular to the long axis of the bone. These images were then exported to DICOM file format and implemented in Materialise Mimics software. Based on source files the program calculates cross-sections in two perpendicular planes parallel to the long axis of the bone and the user assigns a frame of reference to each of the three planes.

The process of generating the 3D model starts with applying a filter called Threshold, which highlights tissues on images with a value of radiodensity within specified range. For bones the threshold usually displays areas with density between 226 and 1895 in Hounsfield scale. Next, one can divide the selection in several different masks using Region Growing, which can be helpful in cases of complex structures, when it is convenient to switch between models of parts of the setup, e.g. bones with corresponding joints etc. When the mask of desired tissue is ready, the user orders a process of calculating the 3D model based on the highlighted tissues on layers in three perpendicular planes of the 3D coordinate system (Fig. 2).

The quality of the model is mostly dependent on two factors: a precision of the user in operating on layers and the quality of images themselves. In the discussed case the imperfections of the scan set are noticeable, probably as a result of a resolution of the device and a distance between consecutive layers of scanning, leading to local blurs and softening of the edges. These phenomena resulted in an inability to automatically distinguish wanted bones, hence the necessity to manually separate discussed structures, using tools for mask editing layer by layer or in 3D point cloud and algorithms for Boolean operations on the masks.

Once the model is calculated, it can be processed using 3-matic software tools to obtain a surface of higher quality. Its main function is to apply a polygon mesh on the model, usually composed of triangular faces, and then to assess and modify its properties. Based on the given structure, the mesh could be comprised of varying number of triangles. If further analyses are required, e.g. finite elements analysis, it is crucial to reduce the number of faces to lowest possible value, which could shorten a time required for appropriate analysis (Fig. 3).

Due to inadequacy of the model compared to real structures, which occurred because of the insufficient quality of provided images, it had to be refined. First of all, any sharp edges had to be smoothed to obtain a quality of surface as close to the surface of the corresponding bones as possible. This action resulted in unwanted increase of triangles in the mesh, thus the next step was to rearrange the mesh grid and reduce the number of triangles with preservation of the surfaces. Once the mesh was simplified, the model was ready for exporting to any desired software, including ABAQUS and Comsol for further analyses or as a STEP or STL file for special processing in CAD software.

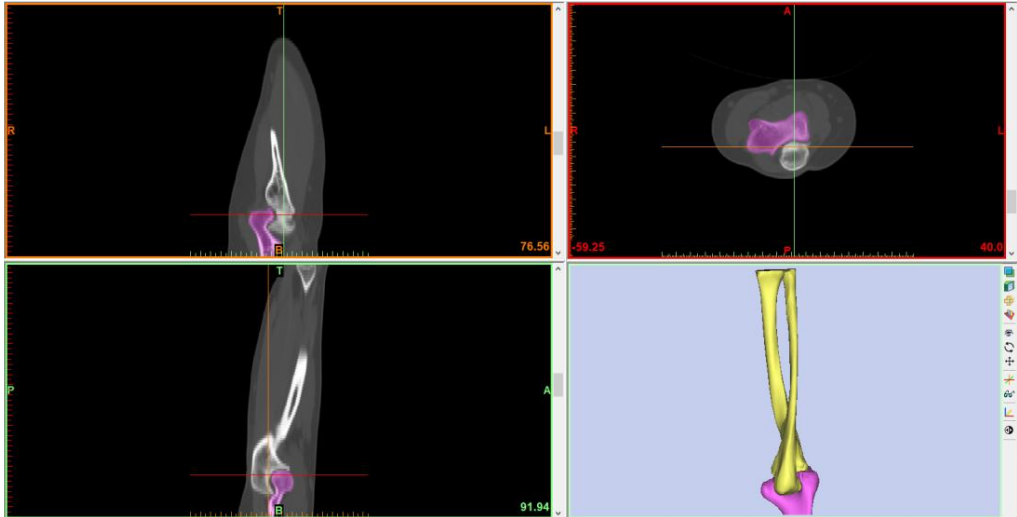


Fig. 2. The layers and a preliminary 3D model of an arm

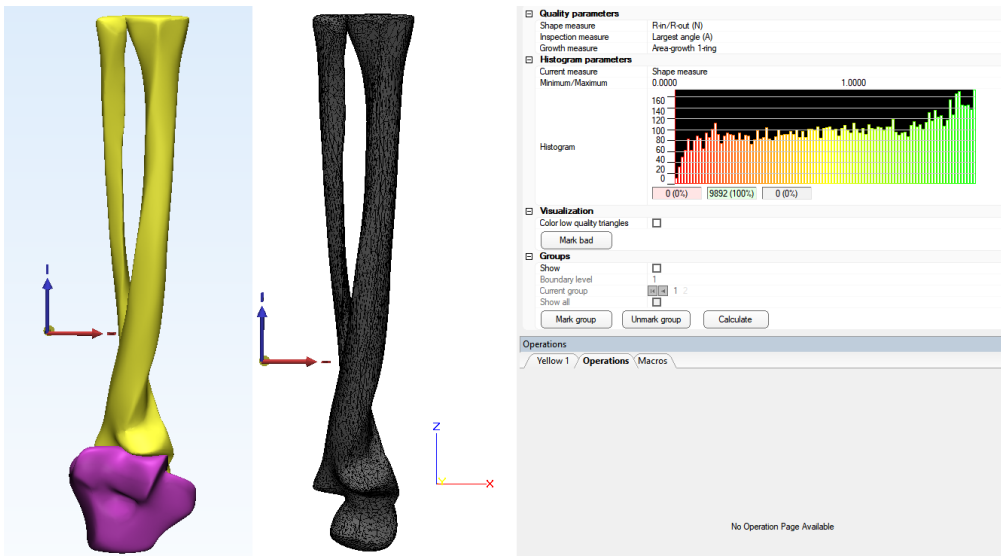


Fig. 3. The model in 3-matic software after smoothing (left) and triangle reducing with a histogram of the mesh (center and right)

4.3. The manufacturing of the physical model

In presented case, at a stage of planning the procedure of surgically dividing bones in the congenital radio-ulnar synostosis, physical models of mentioned condition were used. These models were created on 3D printer using Fused Deposition Modelling technology (FSD) by extruding a thermoplastic filament, layer by layer, on a moving platform, lowered after each layer. After the process, any residues of structural filament, used as support for regular filament, are being removed, either mechanically or under pressure in a washer.

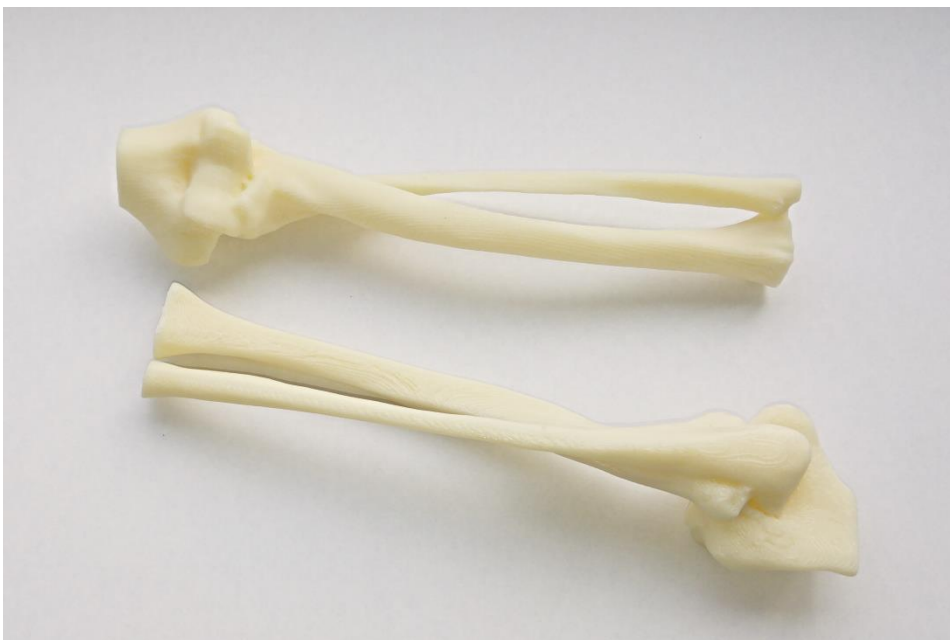

Fig. 4. Physical models of a congenital bilateral radio-ulnar synostosis made by 3D printing method

The input models for 3D printing were represented by triangular mesh grid and saved in STL file format (Stereolithography Interface Specification). They were then manufactured uPrint SE Plus 3D printer using high impact ABS (Acrylonitrile butadiene styrene). Models presented on Fig. 4 were made of thermoplastic filament of diameter 1.75 mm, and a thickness of each layer was 0.2 mm.

5. CONCLUSIONS

The combination of modern methods of medical imaging with the use of virtual engineering modelling allows very accurate representation of the anatomical structures of living organisms. The implementation of virtual models of damaged or afflicted skeletal components, and then the creation of their physical representations is very important at the planning stage of the surgical procedure, during the selection of the necessary instruments and during communication with the patient. In described case of the congenital bilateral radio-ulnar synostosis, the implementation of physical models allowed for individual planning of the separation of connected bones. Earlier preparation for surgery can significantly shorten the duration and reduce the risk of error which in turn reduces its cost as well as the often possible to reduce the degree of surgical intervention.

REFERENCES

- Al-Saadi, Z. S., & Havekrog, B. H. (2008). Congenital radioulnar synostosis. *Ugeskr Laeger*, *170*(40), 3147–3148.
- Bagaria, V., Deshpande, S., Rasalkar, D. D., Kuthe, A., & Paunipagar, B. K. (2011). Use of rapid prototyping and three-dimensional reconstruction modeling in the management of complex fractures. *European journal of radiology*, *80*(3), 814–820.
- Brown, G. A., Firoozbakhsh, K., DeCoster, T. A., Reyna Jr, J. R., & Moneim, M. (2003). Rapid prototyping: the future of trauma surgery? *The Journal of Bone and Joint Surgery*, *85*, 49–55.
- Budzik, G., Dziubek, T., & Turek, P. (2015). Podstawowe czynniki wpływające na jakość obrazów tomograficznych. *Problemy Nauk Stosowanych*, *3*, 077–084.
- Fahlstrom, S. (1932). Radio-ulnar synostosis: historical review and case report. *The Journal of Bone and Joint Surgery*, *14*(2), 395–403.
- Frame, M., & Huntley, J. S. (2012). Rapid prototyping in orthopaedic surgery: a user's guide. *The Scientific World Journal*, *2012*, 838575. doi:10.1100/2012/838575
- Guarino, J., Tennyson, S., McCain, G., Bond, L., Shea, K., & King, H. (2007). Rapid prototyping technology for surgeries of the pediatric spine and pelvis: benefits analysis. *Journal of Pediatric Orthopaedics*, *27*(8), 955–960.
- Hansen, O. H., & Andersen, N. O. (1970). Congenital radio-ulnar synostosis. Report of 37 cases. *Acta Orthopaedica Scandinavica*, *41*(3), 225–230.
- Holubar, S. D., Hassinger, J. P., & Dozois, E. J. (2009). Virtual pelvic anatomy and surgery simulator: an innovative tool for teaching pelvic surgical anatomy. *Studies in Health Technology and Informatics*, *142*, 122–124.
- Hurson, C., Tansey, A., O'Donnchadha, B., Nicholson, P., Rice, J., & McElwain, J. (2007). Rapid prototyping in the assessment, classification and preoperative planning of acetabular fractures. *Injury*, *38*(10), 1158–1162.
- Karpiński, R., Jaworski, Ł., & Zubrzycki, J. (2016). Structural analysis of articular cartilage of the hip joint using finite element method. *Advances in Science and Technology Research Journal*, *10*(31), 240–246. doi:10.12913/22998624/64064
- Karpiński, R., Jaworski, Ł., & Zubrzycki, J. (2017). The design and structural analysis of the endoprosthesis of the shoulder joint. *ITM Web of Conferences*, *15*, 07015. doi:10.1051/itmconf/20171507015

- Karpiński, R., Jaworski, Ł., Szala, M., & Mańko, M. (2017). Influence of patient position and implant material on the stress distribution in an artificial intervertebral disc of the lumbar vertebrae. *ITM Web of Conferences*, 15, 07006. doi:10.1051/itmconf/20171507006
- Kozłowska, E., & Zubrzycki, J. (2017). Using methods of the reverse engineering to carry personalised preoperative stabilisers out on the example of vertebrae of human spine. *ITM Web of Conferences*, 15, 02007. doi:10.1051/itmconf/20171502007
- McGurk, M., Potamianos, P., Amis, A. A., & Goodger, N. M. (1997). Rapid prototyping techniques for anatomical modelling in medicine. *Annals of the Royal College of Surgeons of England*, 79(3), 169–174.
- Mulford, J. S., Babazadeh, S., & Mackay, N. (2016). Three dimensional printing in orthopaedic surgery: review of current and future applications. *ANZ Journal of Surgery*, 86(9), 648–653.
- Petzold, R., Zeilhofer, H. F., & Kalender, W. A. (1999). Rapid prototyping technology in medicine – basics and applications. *Computerized Medical Imaging and Graphics*, 23(5), 277–284.
- Ratajczyk, E. (2012). Rentgenowska tomografia komputerowa (CT) do zadań przemysłowych. *Pomiary Automatyka Robotyka*, 16, 104–113.
- Rizzo, R., Pavone, V., Corsello, G., Sorge, G., & Opitz, J. M. (1997). Autosomal dominant and sporadic radio-ulnar synostosis. *American Journal of Medical Genetics*, 68(2), 127–134.
- Skalski, K., Grygoruk, R., Makuch, A., & Dąbrowska-Tkaczyk, A. (2015). Modelowanie wirtualne i materialne na potrzeby komputerowego wspomaganie zabiegów operacyjnych. In M. Gzik, M. Pawlikowski, M. Lewandowska-Szumiel & M. Wychowański (Eds.), *Biomechanika i Inżynieria Biomedyczna* (pp. 481–498). Akademicka Oficyna Wydawnicza EXIT.
- Skalski, K., & Haraburda, M. (2009). *Komputerowe wspomaganie projektowanie i wytwarzanie implantów stawów człowieka*. Monografia nr 137. Radom: Wydawnictwo Politechniki Radomskiej.
- Zubrzycki, J., & Braniewska, M. (2017). Zastosowanie inżynierii odwrotnej w projektowaniu spersonalizowanego implantu stawu biodrowego. *Mechanik*, 90(1), 46–47.
- Zubrzycki, J., Karpiński, R., & Górniak, B. (2016). Computer aided design and structural analysis of the endoprosthesis of the knee joint. *Applied Computer Science*, 12(2), 84–95.