



# Is Meconium Obstruction Distinguishable from Intestinal Obstruction through Ultrasound?

Seyed Ali Alamdaran<sup>1\*</sup>, Yasmin Davoudi<sup>1</sup>, Sajad Ahmadi<sup>2</sup>, Golam Reza Khademi<sup>3</sup>,  
Alireza Ataei<sup>3</sup>

1. Department of Radiology, Faculty of Medicine, Mashhad University of Medical Sciences, Mashhad, Iran

2. Mashhad University of Medical Sciences, Mashhad, Iran

3. Department of Pediatrics, Faculty of Medicine, Mashhad University of Medical Sciences, Mashhad, Iran

## ABSTRACT

**Background:** Since the treatment of meconium ileus is very different from other types of intestinal obstruction, it is very important to distinguish these two entities. The aim of this study was to assess sonographic findings to differentiate meconium ileus from other types of obstruction.

**Methods:** This study was performed in Dr. Sheikh and Akbar hospitals, Mashhad Medical University of Science, Iran, during 2017- 2018. The imaging signs of 25 newborns (aged 2-8 days) with delayed passage of meconium were documented. These neonates were suspicious of low type intestinal obstruction. In cases with the simple form of meconium ileus and the small left colon syndrome, ultrasonic guided Gastrografin enema was performed for the treatment. In the patients with the failure of medical treatment and in other surgical cases, the appropriate surgical procedure was performed.

**Results:** The subjects in this study were diagnosed with small bowel atresia (n=9), a simple form of meconium ileus (n=6), a complicated form of meconium ileus (n=3), small left colon syndrome (n=3), bowel atresia and duplication (n=1), and Hirschsprung's disease (n=3). The ultrasound findings were as follows: a totally or partially micro-colon in almost all patients, collapsed small bowel in right lower quadrant in all of the patients with bowel atresia, hypoechoic meconium in rectosigmoid in small left colon syndrome and Hirschsprung's disease, hypoechoic tubular or beaded intraluminal inspissated meconium within terminal ileum, and the floating air bubbles (sonographic soap bubble sign) within fluids on proximal dilated loops in meconium ileus cases.

**Conclusion:** Although plain abdominal radiography confirmed bowel obstructions in all patients with delayed passage of meconium, it had a low level of specificity in the diagnosis and cause of obstruction. Abdominal ultrasound had a high level of accuracy in the correct diagnosis of meconium obstructions and its differentiation from other intestinal obstructions. Accordingly, it eliminates the need to do a diagnostic contrast enema in order to differentiate these entities.

**Keywords:** Bowel atresia, Meconium ileus, Newborn, Ultrasound

## Introduction

Meconial obstructions are bowel obstructions caused by inspissated meconium. If the inspissated meconium is in the terminal ileum it is named meconium ileus. On the other hand, if it is in the descending colon, it is called small left colon syndrome. These inspissations can be complicated by bowel perforation and a localized or generalized meconium peritonitis, which is then called complex meconium ileus. These are seen mostly in cases with the cystic fibrosis and are presented with the failure to pass meconium (1).

The failure to pass meconium is a clinically nonspecific finding that is observed in other common causes of infantile bowel obstruction, such as bowel atresia and even Hirschsprung's disease (2). Since the approach to various forms of obstructions is different, their differentiation is important. Complex meconium ileus, bowel atresia, and Hirschsprung's disease need surgical approach; while meconium ileus and small left colon syndrome are treated medically by hyperosmolar Gastrografin contrast enema (1-3).

\* Corresponding author: Seyed Ali Alamdaran, Radiology Department, Akbar Children Hospital, Mashhad, Iran. Tel: +989155112578; Fax: +985138414499; Email: [alamdarana@mums.ac.ir](mailto:alamdarana@mums.ac.ir)

Please cite this paper as:

Alamdaran SA, Davoudi Y, Ahmadi S, Khademi GR, Ataei A. Is Meconium Obstruction Distinguishable from Intestinal Obstruction through Ultrasound? Iranian Journal of Neonatology. 2019 Mar; 10(1). DOI: [10.22038/ijn.2018.30639.1420](https://doi.org/10.22038/ijn.2018.30639.1420)

There has been no evidence about the sensitivities/specificities of imaging modalities in diagnosing bowel atresia, meconium plug syndrome, and meconium ileus (4). Generally, Gastrografin solution enema is used for the differentiation through its infusion into the colon and ileum under fluoroscopic guidance. Gastrografin contrast enema demonstrated empty micro-colon in bowel atresia and the filling defects due to intraluminal inspissated meconium pellets in the terminal ileum and meconium plug syndrome. However, the performance of a contrast enema is laborious and is accompanied by considerable ionizing radiation (5).

In the literature, there were only two old case reports about the usage of ultrasound in the diagnosis of meconium ileus (6, 7). These reports contain only a few cases with imprecise non-detailed findings. The aim of this study was to assess sonographic findings of meconium obstruction and compare the findings with small bowel atresia and other obstruction etiologies. Furthermore, the study was targeted toward the evaluation of ultrasound efficacy in differentiating these entities.

## Methods

This prospective descriptive cross-sectional study was conducted from June 2017 to June 2018 in Dr. Sheikh and Akbar Children hospitals at Mashhad Medical University of Science, Mashhad, Iran. Twenty five consecutive newborns (aged 2-8 days) referring to the radiology department with delayed passage of meconium within 48 h were enrolled in this study. The cases were suspicious of low intestinal obstruction based on clinical and radiological findings. Anorectal malformations and unstable stature were excluded from the study.

Clinical findings consisted of the delayed passage of meconium, abdominal distention, and bilious vomiting. The radiologic signs of low intestinal bowel obstruction in plain abdominal X-ray were abdominal distention, nonrectal gas, longitudinal or sausage-shaped dilated bowel loops, and soap bobble pattern.

The patients then underwent ultrasound examination using a Voluson E6 or Samsung Model H60 with a 10-12 MHz linear superficial probe. The meticulous ultrasound examination of abdomen and bowels, especially terminal ileum and colon were performed by a pediatric radiologist. It was aimed to find meconium obstruction (meconium ileus or meconium plug syndrome) or other pathologies, such as

abdominal or pelvic free fluid, displaced mesenteric vessels, and the level of obstruction, diameter of dilated proximal loop, floating gas bubbles in dilated loop, inspissated meconium in ileum or left colon, microcolon, gas in colon, meconium pseudo-cyst, peritoneal calcification, and duplication cyst.

Afterwards, in simple cases of meconium ileus or small left colon syndrome, ultrasonic guided Gastrografin enema was performed for better diagnosis or treatment. In patients with the failure of medical treatment, in complicated cases or in other surgical cases, the appropriate surgical procedure was performed. Finally, ultrasound and radiological findings during image-guided treatment and contrast enema, as well as surgical findings, were recorded and analyzed.

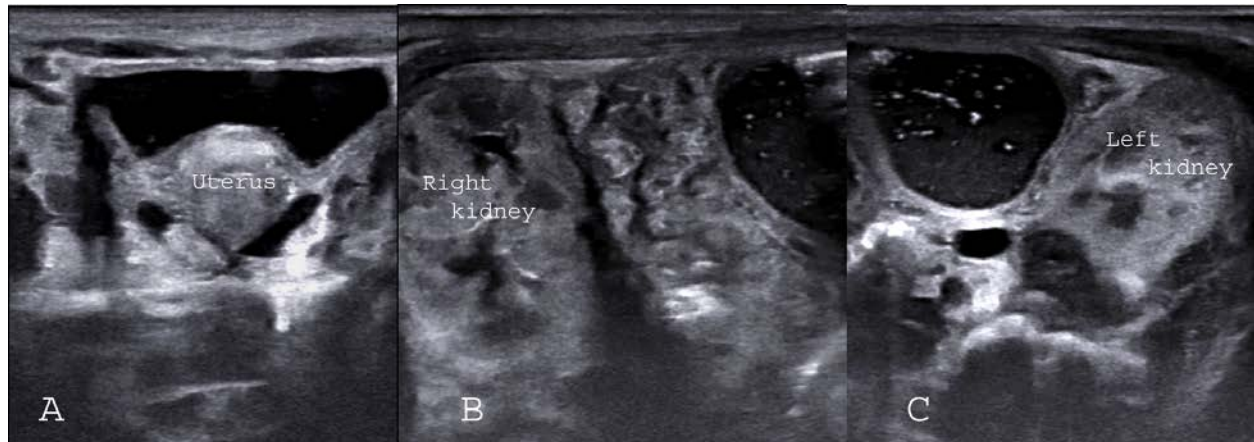
## Results

In 25 patients with the delayed passage of meconium and the suspected meconium obstruction, an initial plain abdominal radiograph was taken. The abdominal X-ray demonstrated abdominal distention, as well as the level of obstruction and sausage-shaped dilated bowel loops in all patients.

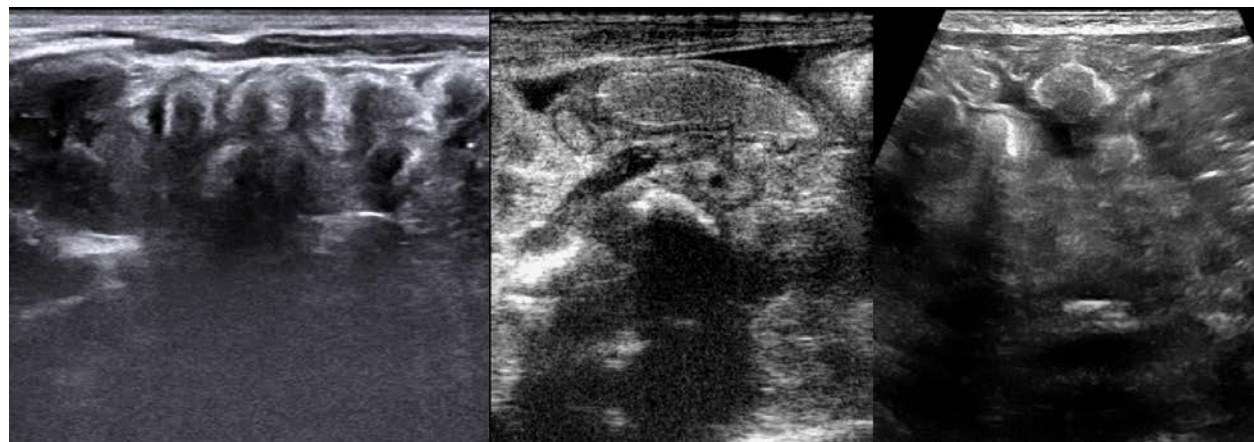
The radiographic "soap bubble" sign was only observed in 4 cases of meconium ileus in the right lower quadrant. The ultrasound finding of the micro colon was a small collapsed loop posterior to the bladder or anterior to the kidneys with the mean transverse diameter of 5-6 mm (Figure 1). Gas bubbles were seen in left colon in Hirschsprung's disease case.

The meconium in small left colon syndrome was seen as a completely hypoechoic material in descending colon and rectosigmoid. A similar pattern was seen in Hirschsprung's disease patients and one case of jejunal atresia probably due to the mixture of mucus and meconium. The collapsed small bowel loops were found in the right abdominal area between ascending colon and proximal dilated loop in all of the cases with bowel atresia (Figure 1). The abnormal mesenteric pathway was visible in one case with bowel atresia. Inspissated meconium in meconium ileus was observed in six patients with meconium ileus as an isoechoic/mildly hypoechoic tubular or beaded intraluminal material in contrast with the associated bowel wall (Figure 2).

All patients showed dilated proximal loops, except for the case with meconium peritonitis. Floating air bubbles were observed in the fluids of the proximal dilated loops and no air was seen in bowel loops containing inspissated meconium.



**Figure 1.** Three images of bowel atresia: micro colon in rectum, anterior to kidneys, collapsed small bowel, and dilated proximal loop contains soap bubble



**Figure 2.** Three images of inspissated meconium within terminal ileum with three different ultrasound devices

This sonographic soap bubble sign was detected in all patients with a simple form of meconium ileus. This sign was also observed in one case with ileal atresia (Figure 1).

In patients with meconium ileus, fluid in the dilated proximal loops had a homogenous echotexture and in bowel atresia cases, it had a heterogeneous echo pattern. The diffuse calcification of peritoneum was seen in meconium peritonitis case, and a cyst containing debris (meconium pseudo-cyst) was detected in two other cases with complicated meconium ileus.

Simultaneous jejunal atresia and duplication cyst was detected in one of our case with intestinal obstruction.

A small amount of free pelvic fluid was seen in all patients. The maximum AP diameter of the fluid packet was 8 mm in the pelvis and 5 mm between the loops. There was no need to do a diagnostic contrast enema in all patients in order to differentiate meconium obstructions from bowel atresia. Tables 1 summarizes the absence or presence of imaging signs of meconium obstructions our cases.

**Table 1.** Absence or presence of imaging signs of meconium obstructions in 24 newborns with delayed passage of meconium and bowel obstruction

Imaging modality	Imaging signs	Final diagnosis of the patients	
		Meconium obstruction	Other obstruction
Plain abdominal X-ray	Presence of radiologic signs of meconium obstruction	4	1
	Absence of radiologic signs of meconium obstruction	8	11
Ultrasound	Presence of ultrasound signs of meconium obstruction	12	1
	Absence of ultrasound signs of meconium obstruction	0	11

In the simple form of meconium ileus, post contrast enema plain abdominal X-ray demonstrated an unused colon (micro-colon) and inspissated meconium pellets within the terminal ileum and cecum. All the patients with the simple form of meconium ileus and small left colon syndrome successfully responded to the clearing of meconium using an ultrasound-guided solution enema except for one patient who had numerous loops with inspissated meconium. This case underwent enterotomy and intraluminal irrigation.

The surgical approach was necessary in 13 cases with small bowel atresia, a complicated form of meconium ileus, Hirschsprung's disease, duplication cyst, and 1 case with nonresponse to Gastrografin enema. The final diagnosis of patients, who had delayed passage of meconium and probably low bowel obstruction (based on clinical and X-ray findings), revealed 9, 6, 3, 3, 1, 3 cases of small bowel atresia, simple form of meconium ileus, complicated form of meconium ileus, small left colon syndrome, bowel atresia and duplication, Hirschsprung's disease, respectively. Overall, half of the investigated cases suffered from meconium obstruction and another half had other types of obstruction.

## Discussion

Failure to pass meconium within the first 48 h of life and vomiting are the clinical signs of intestinal obstruction. In such a situation, radiologic studies are usually required (8). The plain abdominal X-ray is the first radiologic step in the evaluation of newborns suspicious of intestinal obstruction in order to rule out bowel obstruction and differentiate between high and low levels of bowel obstruction (9, 10).

In high intestinal obstruction, few large bubble gases were visible in the upper abdomen while there were multiple sausage-shaped air-filled loops in the low intestinal obstruction. The supplementary next step was to use upper gastrointestinal study for high obstruction and a contrast enema in newborns with suspected low intestinal obstruction. Duodenal web or atresia, malrotation, and jejunal atresia were the most common causes of high intestinal obstruction that are revealed in the upper gastrointestinal series (11). The contrast enema study revealed the typical findings of Hirschsprung's disease, intestinal rotational anomalies, unused colon (microcolon) due to ileal atresia or meconium ileus, and or intraluminal filling defects due to inspissated meconium pellets within the terminal

ileum or left colon (5). The simple form of meconium obstruction may be relieved medically by contrast enema; however, rotational anomalies and bowel atresia required surgical intervention in Hirschsprung's disease (6).

Nowadays, the role of ultrasound is increased in pediatric bowel obstruction for the determination and cause of obstruction. The hypertrophic pyloric stenosis, rotational anomalies, and bowel duplication have characteristic sonographic findings. The sonographic findings of hypertrophic pyloric stenosis are completely identified with high sensitivity and specificity. In the rotation and fixation anomalies of malrotation and non-rotation, there has been an emphasis on the inversion of mesenteric vessels, and abnormal route of mesenteric vessels, as well as whirlpool sign (12, 13). Multi-layered wall (an inner mucosa - submucosa layer surrounded by an outer smooth-muscle layer) with the gut signature sign is characteristic sonographic findings of bowel duplication (14).

In the literature, there are only two old case reports on the role of ultrasound in the diagnosis of meconium ileus (6, 7). Neal et al. described meconium ileus as the multiple loops of bowel filled with very echogenic thick meconium (6). Barki et al. reported a case with an echogenic mass in abdomen whose final diagnosis was meconium ileus (7). In the current study, meconium plaques were seen as tubular or beaded fixed intraluminal material. Compared with the adjacent bowel wall, these plaques had an iso/hypoechogenicity. This tubular or beaded hypoechoic meconium is not detected in patients with bowel atresia, and a few small collapsed loops in right lower quadrant area were seen in these patients instead. Furthermore, in the ultrasound examination of the investigated patients with meconium ileus, dilated proximal loops were filled with a homogenous fluid and air bubbles floating inside the fluid. This floating air bubbles are only seen in the fluid of dilated loops, and not in the inspissated meconium in the obstructed bowel. This could be the possible cause for the soap bubble appearance in a plain abdominal X-ray. The soap bubble appearance in abdominal X-ray was explained in the literature as the mixture of swallowed air and meconium fluid due to an underlying disease, such as Cystic Fibrosis (5). Next, fluid in dilated loops consisted of a viscid meconium liquid. It could also be a probable reason for non-formation of air-fluid levels in these patients in erect X-ray exam (9). In contrast, in bowel atresia, dilated loops are filled by a heterogeneous fluid without floating air bubble.

The collapsing micro-colon is seen in all our patients with bowel atresia and meconium ileus anterior to both kidney and the pelvic cavity. The colon change diameter on the transitional area is easily observed in Hirschsprung's disease patients. Meconium cyst, peritoneal calcification, and duplication cyst were other sonographic findings in our patients. In the literature, half of the neonates with a meconium ileus had complications (5). We also had three complicated cases, but plain X-ray was unable to demonstrate meconium cyst or peritoneal calcification that were easily visible in ultrasound.

Although abdominal plain X-ray documented bowel obstructions in all patients, it had low specificity in the diagnosis of the cause of obstruction. The soap bubble sign was seen in 4 out of 24 patients with intestinal obstruction. It was also unable to show peritoneal calcification in patients with meconium peritonitis. On the contrary, abdominal ultrasound showed meconium material in the left colon or right lower quadrant, the meconium cyst and peritoneal calcification in all the patients with meconium obstruction. In one patient with jejunal atresia, hypoechoic material was seen in the recto-sigmoid area, which was due to the combination of mucus and meconium in the stool (false positive result).

The abnormal mesenteric route was visible in one case with mid bowel atresia. This sign is not specific for rotational anomaly and was reported in other abdominal pathologies, such as an internal hernia, adhesion, and bowel obstruction (12, 13). All cases of intestinal atresia had specific ultrasonographic findings and there was no need to do a diagnostic contrast enema in any of our patients to differentiate bowel atresia from meconium obstruction.

Briefly, the visualization of hypoechoic impacted meconium in rectosigmoid, terminal ileum, or pseudo-cysts is the hallmark of meconium obstruction. Furthermore, collapsed colon and terminal ileum are the characteristic signs of bowel atresia. The current study was a preliminary study with few cases, which introduced different diagnostic approach in newborns with delayed passage of meconium. It is suggested to conduct further studies with more cases for better sonographic characterization of obstruction types and determination of its accuracy and pitfalls.

## Conclusion

Although plain abdominal X-ray confirmed

bowel obstructions in all patients with delayed passage of meconium, it had low specificity in diagnosing the level and the cause of obstruction. On the contrary abdominal ultrasound had a high accuracy for correct differentiation of meconium obstruction from other types of intestinal obstruction and to eliminate the need to perform a diagnostic contrast enema for this differentiation.

## Acknowledgments

The authors wish to thank the staff of radiology, surgery, and neonatal intensive-care unit of Akbar and Dr. Sheikh hospitals.

## Conflicts of interests

None.

## References

1. Karimi A, Gorter RR, Sleeboom C, Kneepkens CM, Heij HA. Issues in the management of simple and complex meconium ileus. *Pediatr Surg Int*. 2011; 27(9):963-8.
2. Burke MS, Ragi JM, Karamanoukian HL, Kotter M, Brisseau GF, Borowitz DS, et al. New strategies in nonoperative management of meconium ileus. *J Pediatr Surg*. 2002; 37(5):760-4.
3. Alamdaran SA, Mohamadipour A, Joodi M, Shojaeian R, Khademi G, Jafari SA, et al. Ultrasound- guided Hydrostatic (hydrocolonic) treatment of meconium ileus: a preliminary report. *Int J Pediatr*. 2018; 6(8):8111-8.
4. Carroll AG, Kavanagh RG, Ni Leidhin C, Cullinan NM, Lavelle LP, Malone DE. Comparative effectiveness of imaging modalities for the diagnosis of intestinal obstruction in neonates and infants: a critically appraised topic. *Acad Radiol*. 2016; 23(5):559-68.
5. Rescorla FJ, Grosfeld JL, West KJ, Vane DW. Changing patterns of treatment and survival in neonates with meconium ileus. *Arch Surg*. 1989; 124(7):837-40.
6. Neal MR, Seibert JJ, Vanderzalm T, Wagner CW. Neonatal ultrasonography to distinguish between meconium ileus and ileal atresia. *J Ultrasound Med*. 1997; 16(4):263-6.
7. Barki Y, Bar-Ziv J. Meconium ileus: ultrasonic diagnosis of intraluminal inspissated meconium. *J Clin Ultrasound*. 1985; 13(7):509-12.
8. Loening-Baucke V, Kimura K. Failure to pass meconium: diagnosing neonatal intestinal obstruction date: *Am Fam Physician*. 1999; 60(7):2043-50.
9. Gupta AK, Guglani B. Imaging of congenital anomalies of the gastrointestinal tract. *Indian J Pediatr*. 2005; 72(5):403-14.
10. Hernanz-Schulman M. Imaging of neonatal gastrointestinal obstruction. *Radiol Clin North Am*. 1999; 37(6):1163-86.
11. Reid JR. Practical imaging approach to bowel obstruction in neonates: a review and update. *Semin*

- Roentgenol. 2012; 47(1):21-31.
12. Alamdaran SA, Hashemi J, Layegh P, Taghawi M. The diagnostic value of ultrasonography in pediatric intestinal malrotation. *Growth*. 2015; 5:3-8.
  13. Taghavi M, Alamdaran SA, Feizi A. Diagnostic value of ultrasound and gastrointestinal series findings in detection of pediatric intestinal malrotation. *Iran J Radiol*. 2018, 15(2):e15089.
  14. Cheng G, Soboleski D, Daneman A, Poenaru D, Hurlbut D. Sonographic pitfalls in the diagnosis of enteric duplication cysts. *Am J Roentgenol*. 2005; 184(2):521-5.