

**WHAT IS NEW ABOUT INTERCORONARY ARTERIAL CONTINUITY?**

Cem Bostan, Ugur Coskun, Alev Arat Ozkan, Tevfik Gurmen

**Russ J Cardiol** 2014, 1 (105), Engl.: 58-59**Key words:** Intercoronary arterial continuity, coronary circulation.

Department of Cardiology, Istanbul University Institute of Cardiology, Istanbul, Turkey.

**Corresponding author.** Cem Bostan, MD, Istanbul University Institute of Cardiology, Department of Cardiology, Cardiologist, Instructor, Haseki, Aksaray

34350, Istanbul/ Turkey, Tel: +90 532 517 25 57, Fax: +90 216 469 37 96, e-mail: bostancem@yahoo.com

ICC - Intercoronary arterial continuity, LAD - left anterior descending artery, LV - left ventricular, RCA - distal right coronary artery, PDA - posterior descending artery.

Received June 03, 2013.

Revision received June 04, 2013.

Accepted June 11, 2013.

**ЧТО НОВОГО ВО ВНУТРИСОСУДИСТОЙ АРТЕРИАЛЬНОЙ ПРЕЕМСТВЕННОСТИ?**

Cem Bostan, Ugur Coskun, Alev Arat Ozkan, Tevfik Gurmen

**Российский кардиологический журнал** 2014, 1 (105), Англ.: 58-59**Ключевые слова:** внутрисосудистая артериальная преемственность, коронарное кровообращение.

Intercoronary arterial continuity (ICC) or “coronary arcade” are thought to arise from embryonic plexuses. These connections are distinct from collaterals being larger in diameter ( $\geq 1$  mm), extramural and straight. Furthermore, the structure of them is typical of an epicardial artery with a well-defined muscular layer whereas collateral vessels resemble arterioles. [1] The incidence of ICC was found to be 0.002%. [2]

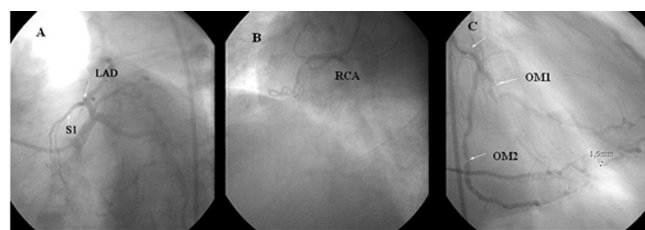
We report of a unique case with a novel connection between diagonal branch of left anterior descending artery (LAD) and distal right coronary artery (RCA). Left ventricular function is preserved despite totally occluded LAD and RCA.

A 56 years old male with no history of ischemic cardiopathy, presented with palpitation. He was smoker and his father had sudden death at 54 years of age. Physical examination was normal. Electrocardiography was within normal limits except for frequent unifocal ventricular extra systoles. Echocardiography revealed normal left ventricular (LV) functions with ejection fraction of 60%. After a positive treadmill exercise test indicating high risk, he was referred to coronary angiography. He had 3-vessel disease with LAD occlusion distal to the diagonal branch, with late antegrade visualization of distal LAD, RCA occlusion at proximal segment and 80% stenotic lesions in proximal parts of both well-developed obtuse marginals (Fig.1 A, B, C). Left coronary injection showed a communication of 1.9 mm diameter between diagonal branch of LAD and the posterior branch of RCA. (Fig.2 A, B). He was referred to surgery.

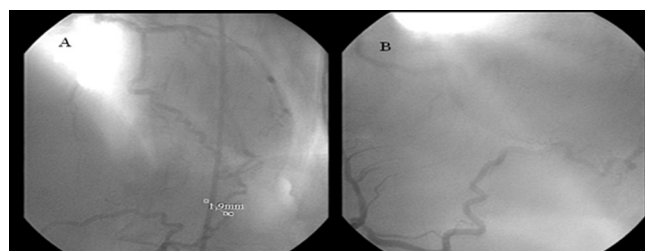
This case presents a novel connection between coronaries which definitely played a protective role in preserving LV function despite two totally occluded major arteries. ICC has been reported as the anatomical cause of bidirectional flow. Its presence was demonstrated in patients with and without coronary narrowing. Two types

were described: 1) most common was between the anterior and posterior arteries in the distal portion of the posterior interventricular groove, and 2) between distal RCA and circumflex arteries in the posterior atrioventricular groove. [1 This is the first case between diagonal branch of left anterior descending artery and the right coronary artery out of grooves.

The functional significance of these connections is unclear and some authors speculated that they would represent a potential “self-cure” for obstructive disease. [1, 2] However Donaldson et al reported a case with >95% narrowing of the RCA in which LAD- posterior descending artery (PDA) continuity didn't prevent extensive transmural



**Figure 1.** LAD was occluded distal to the diagonal branch (A); RCA was occluded proximally (B); both well developed obtuse marginal branches of circumflex artery had critical lesions (C).



**Figure 2.** Inter coronary continuity: diagonal side (1.9 mm in diameter) (A); and right posterior descending side (B).

ral infarction in the distribution of the PDA, so that the theoretical protective role of “the potential self-cure” was questioned [2]. There are also some reports declaring that these connections can induce ischemia by steal phenomenon. [3, 4] The present case clearly demonstrates protective role of the existing continuity supplying RCA area.

In conclusion, ICC, a rare variant of coronary circulation, can be found between different parts of coronary circulation not only in the grooves of the heart but also in the epicardial surface as in the presented case. The potential protective role of this connections and factors influencing protective potency deserves further evaluation.

### References

1. Fournier JA, Cortacero JA, Díaz de la Llera L, et al. [Distal intercoronary communication. A case report and medical literature review]. *Rev Esp Cardiol*. 2003 Oct;56(10):1026-8.
2. Ozlü MF, Ozcan F, Sen N, Çağlı K. An intercoronary connection serving as a safety valve for the left ventricle. *Turk Kardiyol Dern Ars*. 2010 Sep;38(6):416-8.
3. Ulus T, Görenek B, Yazıcı HU, Ozduman H. Intercoronary continuity between the right and circumflex coronary arteries causing myocardial ischemia. *Turk Kardiyol Dern Ars*. 2011 39:576-78.
4. Karabay KÖ. Intercoronary continuity between the right and circumflex coronary arteries causing myocardial ischemia. *Turk Kardiyol Dern Ars*. 2012 Mar;40(2):201; author reply 201-2.