



Research Article



The Ameliorative Effects of Allopurinol on Paraquat-Induced Pulmonary Fibrosis in Rats

Saeedeh Shariati¹, Mohammad Javad Khodayar^{1,2*} , Aliasghar Hemmati³, Mehdi Goudarzi¹, Milad Kiani¹, Anahita Rezaei⁴

¹Toxicology Research Center, Ahvaz Jundishapur University of Medical Sciences, Ahvaz, Iran.

²Department of Toxicology, School of Pharmacy, Ahvaz Jundishapur University of Medical Sciences, Ahvaz, Iran.

³Department of Pharmacology, School of Pharmacy, Ahvaz Jundishapur University of Medical Sciences, Ahvaz, Iran.

⁴Department of Pathology, Faculty of Veterinary Medicine, Shahid Chamran University, Ahvaz, Iran.

Article Info

Article History:

Received: 7 April 2018

Revised: 24 September 2018

Accepted: 28 September 2018

ePublished: 18 March 2019

Keywords:

-Paraquat
-Pulmonary fibrosis
-Allopurinol
-Antifibrotic
-Rats

ABSTRACT

Background: Pulmonary fibrosis is described as a chronic idiopathic inflammatory disease of the interstitial lungs. It is associated with a potentially fatal prognosis, and patients show insignificant response to treatment. To treat paraquat (PQ)-induced pulmonary injury and fibrosis, multiple approaches have been used. We aimed to determine the effects of allopurinol (Allo), a xanthine oxidase inhibitor, on PQ-induced pulmonary fibrosis in rats.

Methods: A total of 30 female Sprague-Dawley rats were divided randomly into five groups (200±20 g). Group 1 (control) and group 2 (PQ group) were intraperitoneally administered PQ (20 mg/kg) once on day seven without any treatment, while groups 3–5 orally received 50, 100, and 200 mg/kg of Allo seven days before and three weeks following the administration of PQ, respectively. The animals were sacrificed three weeks after PQ administration. For the histopathological analysis and assessment of serum malondialdehyde (MDA) and hydroxyproline (HP) contents, the animals' blood and lungs were collected.

Results: The PQ group showed significantly higher lung HP, serum MDA, and lung index in comparison with the control. Treatment with Allo, especially at 100 and 200 mg/kg, decreased HP, MDA, and lung index significantly, compared to the PQ group. Allo could prevent inflammatory cell infiltration, presence of fibroblasts, and PQ-related alveolar thickening.

Conclusion: The results revealed that Allo has potential protective effects on PQ-related pulmonary fibrosis, and the role of xanthine oxidase in the exacerbation of PQ-induced pulmonary fibrosis was confirmed.

Introduction

Pulmonary fibrosis is described as a chronic idiopathic inflammatory disease of the interstitial lungs. It is associated with a potentially fatal prognosis, and patients often show insignificant response to treatment.^{1,2} Nevertheless, the pathophysiology of this disease remains undetermined. The lower-airway accumulation of activated inflammatory cells is assumed to produce dangerous quantities of reactive oxygen species (ROS), leading to lung damage.

The content of the extracellular matrix is increased by activated fibroblasts, which in turn destroys the normal structure of the lungs and decreases vital gas exchange.^{3,4} A studied model of fibrogenesis is experimental paraquat (PQ)-induced lung fibrosis, which has been endorsed by many studies.⁵⁻⁸ This pulmonary fibrosis model is similar to the model in humans, assessing the potential effects of therapeutic agents. PQ, as a quaternary nitrogen

herbicide, is used for controlling broadleaf weed worldwide. The molecular mechanism of PQ toxicity is not completely understood, making it difficult to treat toxicities of the central nervous system, kidneys, heart, and liver. However, pulmonary fibrosis and lung damage are recognized as the most common causes of mortality and injury.⁹⁻¹³

In the mid 1950's, allopurinol (Allo) was synthesized for the production of new antineoplastic agents. Nevertheless, its inhibitory effects on xanthine oxidase (XO) were reported, reducing both serum uric acid and urinary contents.¹⁴ In 1966, the Food and Drug Administration approved Allo for gout treatment. Administration of this drug remains the most effective approach for primary and secondary hyperuricemia.¹⁵ Allo is recognized as a competitive inhibitor and a substrate for XO enzymes at low concentrations, while it is a noncompetitive inhibitor at higher concentrations.

*Corresponding Author: Mohammad Javad Khodayar, E-mail: khodayar-mj@ajums.ac.ir

©2019 The Authors. This is an open access article and applies the Creative Commons Attribution (CC BY), which permits unrestricted use, distribution and reproduction in any medium, as long as the original authors and source are cited. No permission is required from the authors or the publishers.

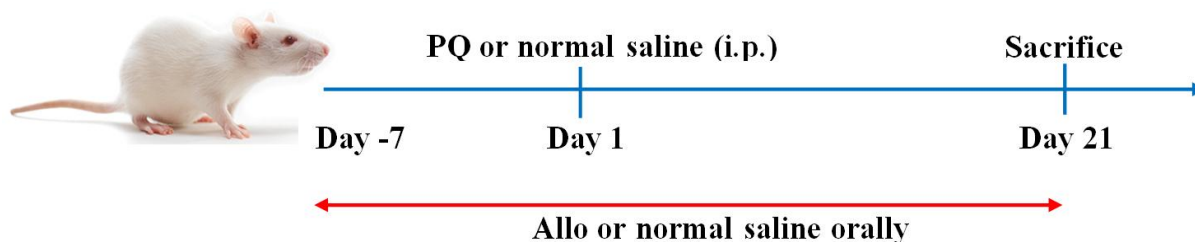


Figure 1. The experimental protocol of the study. Female rats were pretreated with 50, 100, and 200 mg/kg of Allo or normal saline orally seven days before and three weeks after the administration of PQ. PQ or normal saline was administered on day one at a single dose intraperitoneally (i.p.).

Its formation, besides its long persistence in tissues, largely accounts for its pharmacological activity. Furthermore, it has been reported that XO inhibition exerts antioxidant properties.¹⁶ The XO enzyme forms superoxide ($O_2^{\bullet-}$) and hydrogen peroxide (H_2O_2), which is majorly involved in chronic heart failure, different inflammatory diseases, and vascular and tissue damage.¹⁷⁻²⁰ In animal models, as well as small-scale clinical trials in humans, Allo has exhibited positive therapeutic effects. XO-derived ROS has been introduced as a mediator of proinflammatory gene expression and inflammatory signal transduction pathways.¹⁶ Therefore, this study examined the effects of Allo on the fibrogenic activity of PQ in a pulmonary fibrosis model.

Materials and Methods

Chemicals

Jalinous Pharmaceutical Company (Tehran, Iran) provided Allo in this study. Sigma–Aldrich Co. (St. Louis, MO, USA) supplied PQ (methyl viologen), thiobarbituric acid (TBA), chloramine T, trichloro acetic acid (TCA), L-hydroxyproline (HP), dimethyl benzaldehyde, and tetraethoxypropane (TEP). All other chemicals were of an analytical grade.

Animals

The animal house of Ahvaz Jundishapur University of Medical Sciences (AJUMS) provided 30 female eight-week-old Sprague–Dawley rats (200 ± 20 g), which were kept in a 12:12 h light-dark cycle inside polypropylene cages with free access to standard rat chow and drinking water under controlled temperature ($20 \pm 2^\circ C$). In our study, the procedures for animals were in line with the guidelines of AJUMS Animal Ethics Committee.

Experimental design

After randomly dividing the animals into five experimental groups (six per group), they were treated as follows: group 1 (control); group 2 (PQ group), PQ (20 mg/kg/5 ml in normal saline, i.p.); and groups 3–5, oral administration of 50, 100, and 200 mg/kg of Allo, respectively seven days before and three weeks after PQ administration.² (Figure 1)

Sample Collection

Xylazine (10 mg/kg), as well as ketamine (90 mg/kg), was used to anesthetize the rats at the end of the experiment

(day 28). Blood samples from the jugular vein were collected. After isolating, weighing, and washing the lungs with saline rapidly, centrifugation was carried out to separate the serum at 3000 rpm for 10 minutes; then, it was stored at $-80^\circ C$ until further analysis.

MDA assay

MDA reaction with TBA was measured to determine lipid peroxidation, as explained by Esterbauer and Cheeseman.²¹ Briefly, after mixing the serum sample (0.5 mL) with TCA (2.5 mL; 10% w/v) and centrifuging for 10 minutes at 3000 rpm, 2 mL of the supernatant was added to the test tube of TBA solution (1 mL; 0.67% w/v). A solution with a pink color emerged after keeping the mixture for 10 minutes in boiling water. The mixture was left to cool down, and then, a spectrophotometer (UV-1650 PC, Shimadzu, Japan) was used to read absorbance at 532 nm. In this study, serum MDA is presented as $\mu mol/L$, and tetraethoxypropane (TEP) is considered as the standard.

HP assay

A colorimetric assay was used to quantify the left lung total collagen content and HP content of the lungs.^{22,23} For this purpose, after homogenizing the minced lobes of the left lung in 6 M HCl and hydrolyzed at $130^\circ C$ for five hours, NaOH was used to adjust pH to 6.5–7.0, and distilled water was used to adjust the sample volume to 30 mL. After mixing chloramine T solution (1.0 ml; 0.05 mol/L) with the sample solution (1.0 ml) and incubation for 20 minutes at room temperature, 1.0 ml of 20% dimethyl benzaldehyde solution was added and then incubated for 20 minutes at $60^\circ C$. Absorbance was measured at 550 nm. According to HP standards, the values were presented as mg HP per g wet lung weight.

Histopathological examination

After dissecting a section of the lung (5 μm) and its fixation in 10% phosphate-buffered formaldehyde, it was stained with hematoxylin and eosin (H&E staining). Connective tissues, recruitment of inflammatory cells, and collagen deposition were evaluated in the lungs.

Statistical analysis

Values are presented as mean \pm SD. For comparisons, one-way ANOVA and Tukey's test were applied in this study. The significance level was 0.05.

Results

Lung index

Body weight was calculated every week during the experiment. The lung index was measured after sacrificing the animals as the wet lung weight ratio to body weight (mg/g). The lung indices were 6.74 ± 0.17 and 7.44 ± 0.25 mg/g, respectively in the control and PQ groups. The Allo (100 and 200 mg/kg) and control groups showed no significant differences (Figure 2).

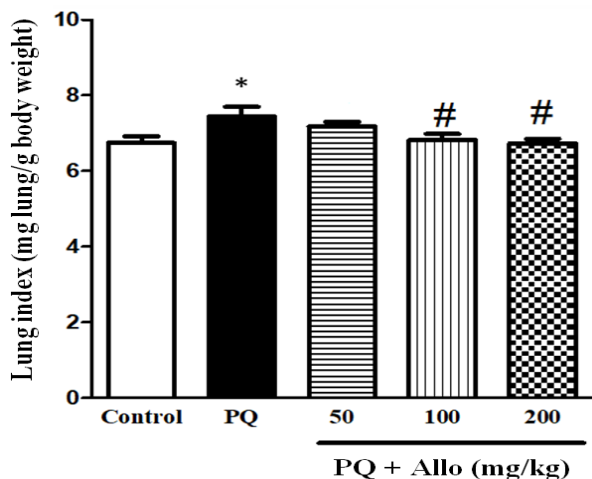


Figure 2. Effects of Allo pretreatment at 50, 100, and 200 mg/kg on the lung index in a model of PQ-induced pulmonary fibrosis. Values are presented as mean ± SD (n = 6). *P < 0.05 and #P < 0.05, significant differences vs. the control and PQ groups, respectively.

MDA levels

The serum MDA content (lipid peroxidation index) increased in rats exposed to PQ in comparison with the controls (P < 0.001). The serum MDA levels were 1.24 ± 0.15 and 2.78 ± 0.31 μmol/lit in the control and PQ groups, respectively; Allo-pretreated rats showed a reduction in MDA level (Figure 3).

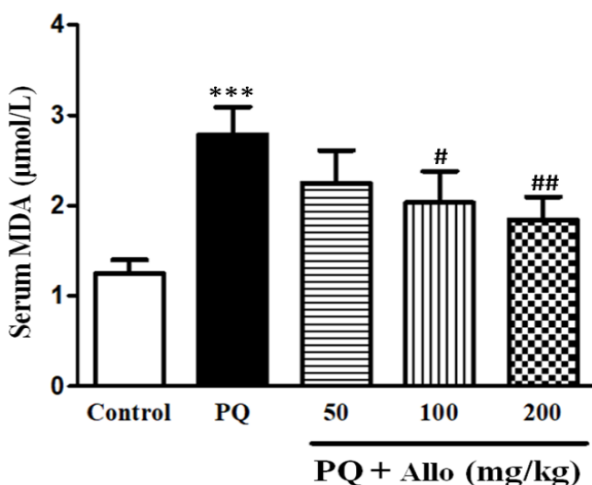


Figure 3. Effects of Allo pretreatment at 50, 100, and 200 mg/kg on serum MDA content in PQ-induced pulmonary fibrosis. Values are presented as mean ± SD (n = 6). ***P < 0.001, significant difference vs. control group; #P < 0.05 and ##P < 0.01, significant difference vs. PQ group.

HP Content

The lung HP content as an index of collagen accumulation was 1.69 ± 0.26 and 5.79 ± 0.53 mg/g tissue in the control and PQ groups, respectively (Figure 4). Treatment with Allo in doses 100 and 200 mg/kg significantly decreased lung HP in comparison with PQ group.

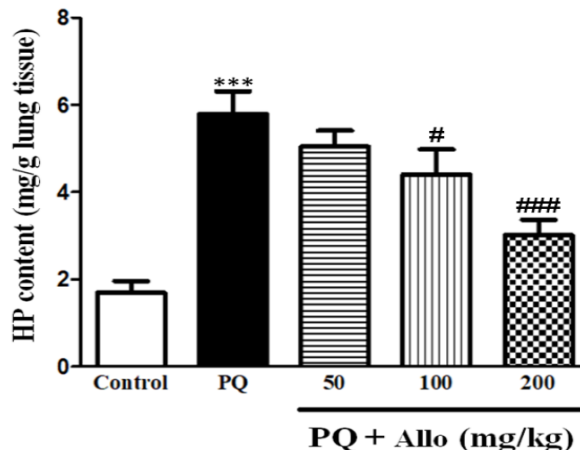


Figure 4. Effects of Allo pretreatment (50, 100, and 200 mg/kg) on lung HP content in a PQ-induced pulmonary fibrosis model. Data are presented as mean ± SD (n = 6). ***P < 0.001, significant difference vs. control group; #P < 0.05 and ###P < 0.001, significant difference vs. PQ group.

Histological Changes

According to the Photomicrographic analysis, grade 0 and grade 8 were more prominent in the control and PQ groups, respectively, based on the infiltration of fibroblasts, inflammatory cells, and extracellular matrix. The pretreated rats indicated grades 6-7 at 50 mg/kg, while grades 4-5 were more prevalent in the photomicrographs at 100 and 200 mg/kg (Figure 5).

Discussion

There are two phases in pulmonary toxicity with PQ. The first involves injury and destruction of alveolar epithelial cells, resulting in hemorrhage and edema, while the second one involves the infiltration of inflammatory cells into the alveolar space and septa, as well as alveolar cell differentiation into fibroblasts associated with collagen production.^{9,10,24,25} PQ can reach the lung through the circulation after ingestion, and accumulates in alveoli. This herbicide can produce a large amount of ROS through its interaction with lung and other organs. ROS can oxidize surrounding lipids and induce lipid peroxidation. Excessive ROS consumes reducing molecules such as glutathione, which can lead to more damage to the lungs and other organs. The amount of oxygen present in the alveoli can induce the production of PQ+ from PQ++ (PQ) by reductases (e.g. NADPH), and reduced form of PQ (PQ+) lead to the generation of superoxide anions (O₂^{•-}). Superoxide anion may be finally transformed into hydrogen peroxide and hydroxyl radicals with other pulmonary reductases and ferrous ion (Fe²⁺).^{13,26-31}

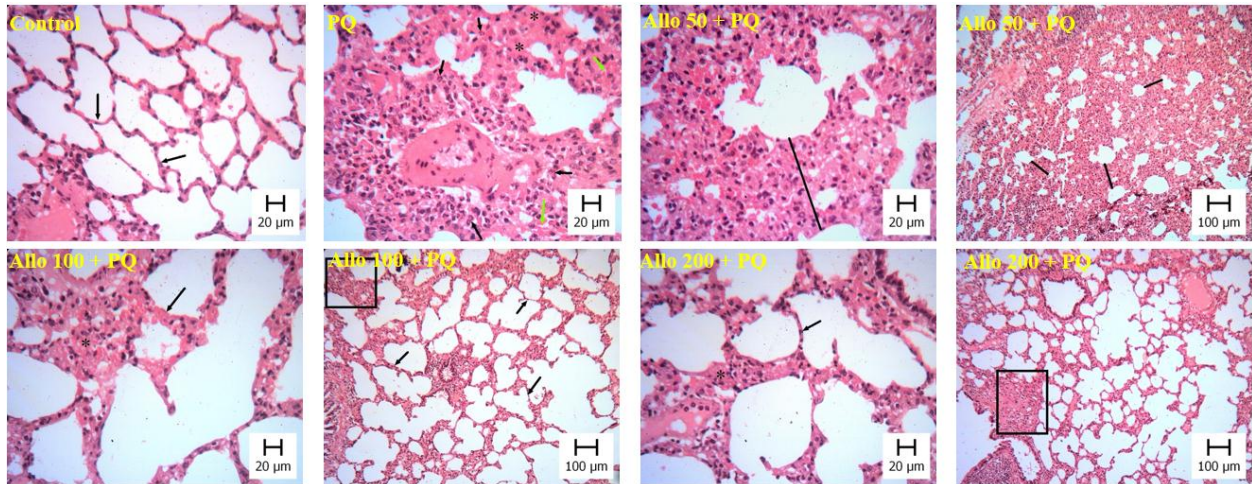


Figure 5. These figures are representative of the role of Allo in lung damage induced by PQ. After collecting lung tissues 21 days after PQ administration, they were stained with H&E. The groups included: control, PQ, PQ pretreated with Allo 50 mg/kg (Allo 50+PQ), PQ pretreated with Allo 100 mg/kg (Allo 100+PQ), and PQ pretreated with Allo 200 mg/kg (Allo 200+PQ). Lung parenchyma is intact and preserved in the control group. Group PQ shows extensive interstitial infiltration and fibrosis. PQ-induced histological changes were markedly prevented in the Allo-pretreated groups at 100 and 200 mg/kg.

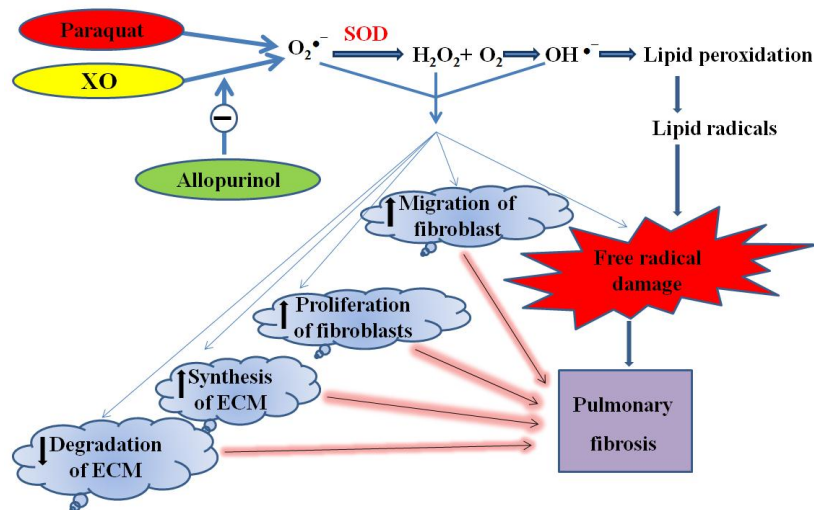


Figure 6. Graphical abstract of the possible protective effects of allopurinol (Allo) against paraquat (PQ)-induced pulmonary fibrosis. SOD: Superoxide dismutase; ECM: Extracellular matrix; XO: Xanthine oxidase.

These oxidative species can readily obtain hydrogen atoms from alveolar lipids so as to result in alveolar cell injury.²⁷ It seems that XO increases superoxide anions production mediated by PQ.³²

PQ increased lung HP, serum MDA and lung index. These effects confirm that PQ induce oxidative stress by elevation in MDA levels, inflammation by infiltration of inflammatory cells in lung alveoli and fibrosis by elevation of tissue HP and presence of fibroblasts. Treatment with Allo, especially in receiving groups of 100 and 200 mg/kg decreased HP, MDA and lung index. The fibroblast and inflammatory cell infiltration, as well as alveolar thickening as a result of PQ, could be prevented by Allo. Although XO inhibition is the most accepted mechanism of Allo activity, its antioxidative activity and potential as a free radical scavenger are also known. Allo prevents glutathione oxidation and lipid peroxidation, which is related to exhaustive physical

exercise.^{16,33-38} It has been reported that XO inhibitors suppress oxidative stress and inflammation in liver damage induced by carbon tetrachloride and cirrhosis,³⁹ as well as doxorubicin-induced cardiotoxicity in rats.⁴⁰ As shown in Figure 6, PQ induces oxidative stress and consequently oxidative damage which lead to pulmonary fibrosis. Allo prevents PQ fibrotic effects possibly through suppression of superoxide anion generation.

Conclusion

The present findings showed that PQ administration leads to lung fibrosis in rats by increasing oxidative stress. Allo prevents fibrosis dose-dependently through its antioxidant properties.

Acknowledgments

This study was granted by the Toxicology Research Center of AJUMS.

Conflict of interests

The authors claim that there is no conflict of interest.

References

- Nalysnyk L, Cid-Ruzafa J, Rotella P, Esser D. Incidence and prevalence of idiopathic pulmonary fibrosis: Review of the literature. *Eur Respir Rev.* 2012;21(126):355-61. doi:10.1183/09059180.00002512
- Khodayar MJ, Kiani M, Hemmati AA, Rezaie A, Zerafatfard MR, Nooshabadi MRR, et al. The preventive effect of atorvastatin on paraquat-induced pulmonary fibrosis in the rats. *Adv Pharm Bull.* 2014;4(4):345-9. doi:10.5681/apb.2014.050
- Fernandez IE, Eickelberg O. New cellular and molecular mechanisms of lung injury and fibrosis in idiopathic pulmonary fibrosis. *Lancet.* 2012;380(9842):680-8. doi:10.1016/S0140-6736(12)61144-1
- Wolters PJ, Collard HR, Jones KD. Pathogenesis of idiopathic pulmonary fibrosis. *Annu Rev Pathol.* 2014;9(1):157-79. doi:10.1146/annurev-pathol-012513-104706
- Griffin M, Smith L, Wynne J. Changes in transglutaminase activity in an experimental model of pulmonary fibrosis induced by paraquat. *Br J Exp Pathol.* 1979;60(6):653-61.
- Yang W, Zhao X, Liang R, Chen D. Effects of small rna interference targeting mammalian target of rapamycin on paraquat-induced pulmonary fibrosis in rats. *Zhonghua Wei Zhong Bing Ji Jiu Yi Xue.* 2017;29(9):830-5. doi:10.3760/cma.j.issn.2095-4352.2017.09.013
- Sun H, Zhang J, Kang J, Liu Q, Huang P, Jiang L, et al. Identification of paraquat-induced lung injury and fibrosis in mice via intraperitoneal injection in various dose and exposure time. *Am J Respir Crit Care Med.* 2017;195:A4421.
- Smith LL. The toxicity of paraquat. *Adverse Drug React Acute Poisoning Rev.* 1988;7(1):1-17.
- Vongphouttha C, Zhu J, Deng S, Tai W, Wu W, Li Z, et al. Rapamycin protects against paraquat-induced pulmonary epithelial-mesenchymal transition via the wnt/ β -catenin signaling pathway. *Exp Ther Med.* 2018;15(3):3045-51. doi:10.3892/etm.2018.5795
- Mohammadi-Karakani A, Ghazi-Khansari M, Sotoudeh M. Lisinopril ameliorates paraquat-induced lung fibrosis. *Clin Chim Acta.* 2006;367(1-2):170-4. doi:10.1016/j.cca.2005.12.012
- Hua X-F, Li X-H, Li M-M, Zhang C-Y, Liu H-J, Sun T, et al. Doxycycline attenuates paraquat-induced pulmonary fibrosis by downregulating the $\text{tgf-}\beta$ signaling pathway. *J Thorac Dis.* 2017;9(11):4376-86. doi:10.21037/jtd.2017.10.42
- Gawarammana IB, Buckley NA. Medical management of paraquat ingestion. *Br J Clin Pharmacol.* 2011;72(5):745-57. doi:10.1111/j.1365-125.2011.04026.x
- Pourgholamhossein F, Rasooli R, Pournamdari M, Pourgholi L, Samareh-Fekri M, Ghazi-Khansari M, et al. Pirfenidone protects against paraquat-induced lung injury and fibrosis in mice by modulation of inflammation, oxidative stress, and gene expression. *Food Chem Toxicol.* 2018;112:39-46. doi:10.1016/j.fct.2017.12.034
- Elion GB. The purine path to chemotherapy. *Science.* 1989;244(4900):41-7. doi:10.1126/science.2649979
- Pea F. Pharmacology of drugs for hyperuricemia. In: Ronco C, Rodeghiero F editors. *Hyperuricemic Syndromes: Pathophysiology and therapy.* Karger Publishers; 2005. p. 35-46.
- Pacher P, Nivorozhkin A, Szabó C. Therapeutic effects of xanthine oxidase inhibitors: Renaissance half a century after the discovery of allopurinol. *Pharmacol Rev.* 2006;58(1):87-114. doi:10.1124/pr.58.1.6
- Berry CE, Hare JM. Xanthine oxidoreductase and cardiovascular disease: Molecular mechanisms and pathophysiological implications. *J Physiol.* 2004;555(3):589-606. doi:10.1113/jphysiol.2003.055913
- Harrison R. Structure and function of xanthine oxidoreductase: Where are we now? *Free Radic Biol Med.* 2002;33(6):774-97. doi:10.1016/S0891-5849(02)00956-5
- Harrison R. Physiological roles of xanthine oxidoreductase. *Drug Metab Rev.* 2004;36(2):363-75. doi:10.1081/DMR-120037569
- Barreira JC, Ferreira IC, Oliveira MBP, Pereira JA. Antioxidant activities of the extracts from chestnut flower, leaf, skins and fruit. *Food Chem.* 2008;107(3):1106-13. doi:10.1016/j.foodchem.2007.09.030
- Esterbauer H, Cheeseman KH. Determination of aldehydic lipid peroxidation products: Malonaldehyde and 4-hydroxynonenal. *Methods Enzymol.* 1990;186:407-21. doi:10.1016/0076-6879(90)86134-H
- Kesava Reddy G, Enwemeka CS. A simplified method for the analysis of hydroxyproline in biological tissues. *Clin Biochem.* 1996;29(3):225-9. doi:10.1016/0009-9120(96)00003-6
- Javad-Mousavi SA, Hemmati AA, Mehrzadi S, Hosseinzadeh A, Houshmand G, Nooshabadi MRR, et al. Protective effect of berberis vulgaris fruit extract against paraquat-induced pulmonary fibrosis in rats. *Biomed Pharmacother.* 2016;81:329-36. doi:10.1016/j.biopha.2016.04.027
- Vijayarajnam G, Corrin B. Experimental paraquat poisoning: A histological and electron-optical study of the changes in the lung. *J Pathol.* 1971;103(2):123-9. doi:10.1002/path.1711030207
- Smith LL, Rose MS. A comparison of the effects of paraquat and diquat on the water content of rat lung and the incorporation of thymidine into lung DNA. *Toxicology.* 1977;8(2):223-30. doi:10.1016/0300-483X(77)90011-7

26. Dinis-Oliveira R, Pontes H, Bastos M, Remiao F, Duarte J, Carvalho F. An effective antidote for paraquat poisonings: The treatment with lysine acetylsalicylate. *Toxicology*. 2009;255(3):187-93. doi:10.1016/j.tox.2008.10.015
27. Sun B, Chen YG. Advances in the mechanism of paraquat-induced pulmonary injury. *Eur Rev Med Pharmacol Sci*. 2016;20(8):1597-602.
28. Liu X-L, Liu X-R, Lu C-Z. Acute lung injury mechanism and therapy induced by paraquat poisoning. *Journal of Acute Disease*. 2017;6(6):260-3. doi:10.4103/2221-6189.221289
29. Blanco-Ayala T, Andérica-Romero A, Pedraza-Chaverri J. New insights into antioxidant strategies against paraquat toxicity. *Free Radic Res*. 2014;48(6):623-40. doi:10.3109/10715762.2014.899694
30. Cheresh P, Kim S-J, Tulasiram S, Kamp DW. Oxidative stress and pulmonary fibrosis. *Biochim Biophys Acta Mol Basis Dis*. 2013;1832(7):1028-40. doi:10.1016/j.bbadis.2012.11.021
31. Li G-p, Yang H, Zong S-b, Liu Q, Li L, Xu Z-l, et al. Diterpene ginkgolides meglumine injection protects against paraquat-induced lung injury and pulmonary fibrosis in rats. *Biomed Pharmacother*. 2018;99:746-54. doi:10.1016/j.biopha.2018.01.135
32. Sakai M, Yamagami K, Kitazawa Y, Takeyama N, Tanaka T. Xanthine oxidase mediates paraquat-induced toxicity on cultured endothelial cell. *Basic Clin Pharmacol Toxicol*. 1995;77(1):36-40. doi:10.1111/j.1600-0773.1995.tb01911.x
33. Vinña J, Gomez- Cabrera MC, Lloret A, Marquez R, Minana JB, Pallardó FV, et al. Free radicals in exhaustive physical exercise: Mechanism of production, and protection by antioxidants. *IUBMB Life*. 2000;50(4- 5):271-7. doi:10.1080/713803729
34. Gois PH, Canale D, Volpini RA, Ferreira D, Veras MM, Andrade-Oliveira V, et al. Allopurinol attenuates rhabdomyolysis-associated acute kidney injury: Renal and muscular protection. *Free Radic Biol Med*. 2016;101:176-89. doi:10.1016/j.freeradbiomed.2016.10.012
35. Gois PHF, Martines MS, Ferreira D, Volpini R, Canale D, Malaque C, et al. Allopurinol attenuates acute kidney injury following bothrops jararaca envenomation. *PLoS Negl Trop Dis*. 2017;11(11):e0006024. doi:10.1371/journal.pntd.0006024
36. Matata BM, Elahi MM. Oxidative stress: Clinical and biomedical implications: Nova Biomedical Books. New York: Hauppauge; 2007.
37. Shukor NAA, Ablat A, Muhamad NA, Mohamad J. In vitro antioxidant and in vivo xanthine oxidase inhibitory activities of pandanus amaryllifolius in potassium oxonate- induced hyperuricemic rats. *Int J Food Sci Tech*. 2018;53(6):1476-85. doi:10.1111/ijf s.13728
38. Mohamed Isa SSP, Ablat A, Mohamad J. The antioxidant and xanthine oxidase inhibitory activity of plumeria rubra flowers. *Molecules*. 2018;23(2):400. doi:10.3390/molecules23020400
39. Aldaba-Muruato LR, Moreno MG, Shibayama M, Tsutsumi V, Muriel P. Protective effects of allopurinol against acute liver damage and cirrhosis induced by carbon tetrachloride: Modulation of nf-kb, cytokine production and oxidative stress. *BBA-Gen Subjects*. 2012;1820(2):65-75. doi:10.1016/j.bbagen.2011.09.018
40. Krishnamurthy B, Rani N, Bharti S, Golechha M, Bhatia J, Nag TC, et al. Febuxostat ameliorates doxorubicin-induced cardiotoxicity in rats. *Chem Biol Interact*. 2015;237:96-103. doi:10.1016/j.cbi.2015.05.013