



Case Report of a Vanished Aspirated Foreign Body; Cough may be more Helpful

Seyed Javad Sayedi¹, Mohammad Gharavi², Ali Khakshour³, Mahboubeh Davoudi Kang⁴,
*Iman Kashani⁵, Reza Jafarzadeh Esfehiani⁶

¹Associate Professor in Pediatric Critical Care, Neonatal Research Center, Akbar Hospital, Faculty of Medicine, Mashhad University of Medical Sciences, Mashhad, Iran.

²Associate Professor in Anesthesiology, Dr. Sheikh Hospital, Mashhad University of Medical Sciences, Mashhad, Iran.

³Associate Professor in Pediatrics, Dr. Sheikh Hospital, Mashhad University of Medical Sciences, Mashhad, Iran.

⁴MSc Nursing, Pediatric Emergency Department, Dr. Sheikh Hospital, Mashhad University of Medical Sciences, Mashhad, Iran.

⁵Fellowship in Pediatric Anesthesia, Dr. Sheikh Hospital, Mashhad University of Medical Sciences, Mashhad, Iran.

⁶Department of Medical Genetics, Mashhad University of Medical Sciences, Mashhad, Iran.

Abstract

Foreign body aspiration is a potentially life-threatening event especially in those who are younger than 5 years old. Aspiration could be presented as a spectrum, ranging from absolutely asymptomatic event to more severe events including choking, respiratory distress and cyanosis or even death. Although foreign bodies in lung may not be visualized on X-ray, X-ray radiography is considered as a first step in localizing aspirated foreign bodies. Bronchoscope as rigid or flexible optic fiber is the main device used in removing aspirated foreign bodies.

However, in some cases, as the present case report, previous foreign bodies which were localized in lung could travel back to the mouth and be ingested. In this report, we discussed a case of foreign body aspiration in a 10 year-old girl referred to Dr. Sheikh Hospital, Mashhad, Iran, whose foreign body located in the lower lobe of the left lung returned and was ingested before bronchoscopy after some episodes of severe coughing.

Key Words: Bronchoscopy, Children, Cough, Foreign body aspiration.

*Please cite this article as: Sayedi SJ, Gharavi M, Khakshour A, Davoudi Kang M, Kashani I, Jafarzadeh Esfehiani R. Case Report of a Vanished Aspirated Foreign Body; Cough may be more Helpful. *Int J Pediatr* 2019; 7(5): 9363-67. DOI: [10.22038/ijp.2018.36214.3160](https://doi.org/10.22038/ijp.2018.36214.3160)

*Corresponding Author:

Iman Kashani (M.D), Dr. Sheikh Hospital, Mashhad University of Medical Sciences, 1358- 91735, Mashhad, Iran. Fax: +98 5137277470

Email: imankashani@gmail.com

Received date: Nov.26, 2018; Accepted date: Jan 22, 2019

1- INTRODUCTION

Foreign body aspiration (FBA) is a life threatening medical condition especially in children below the age of 5 years. FBA is considered as an important cause of death in pediatric population. In the United States, approximately 1500 people die from FBA annually (1, 2). Neonates and toddlers are curious to discover new objects around them and almost always try to taste them. If parents or child nurses witness the aspiration, medical investigations may be less required in contrast to the circumstances where there is no witness and the child presents with respiratory complications or even choking (3). Approximately 40% of FBA cases are not witnessed by parents and children present confusing symptoms other than known signs of aspiration (4). In older patients FBA may also be undiagnosed and patients may undergo various treatments for other medical conditions including recurrent pneumonia, asthma, bronchiectasis and even malignancies prior to the diagnosis of foreign body aspiration (5). The most common manifestation of FBA is choking and coughs while other signs and symptoms of FBA may include vomiting, whizzing, drooling, neck pain and stridor (3). In the present report, we discuss a rare case of FBA in a 10 year-old girl presented with cough. During the admission period the patient began coughing severely and the aspirate foreign body returned up to the mouth and was ingested.

2- CASE REPORTS

A 10 year-old female referred to Dr. Sheikh hospital, Mashhad, Iran, who used a sewing needle instead of toothpick and was witnessed to suddenly swallow the needle after some episodes of unexpected cough. However, the patient was symptom-free when presented to the pediatric emergency ward. In the first chest X-ray, aspirated needle was visualized in the lower zone of the left lung (**Figure.1**). The patient was then admitted in pediatric service. The patient was candidate for flexible optic fiber bronchoscopy because rigid bronchoscopy was not considered to be suitable for reaching lower lung segments. Consequently, the patient was transferred to pediatric pulmonary disease ward for bronchoscopy. Thirty minutes after arriving at the ward, the patient suddenly began to cough. These powerful rigorous coughs made the needle come up to her mouth which she then swallowed back spontaneously. Emergency abdominal X-ray showed that the needle had passed the pylorus (**Figure.2**). According to the pediatric surgery consultation, patient was put on regular diet and a controlled abdominal X-ray was scheduled for the next day. The next radiograph revealed that the needle passed the small intestine and it was shown in the colon (**Figure.3**). In the second day of admission, the needle was expelled uneventfully without any bleeding and the patient was discharged in good condition. All patient's lab tests during hospital stay were normal. The one month follow up after discharge revealed no complication.

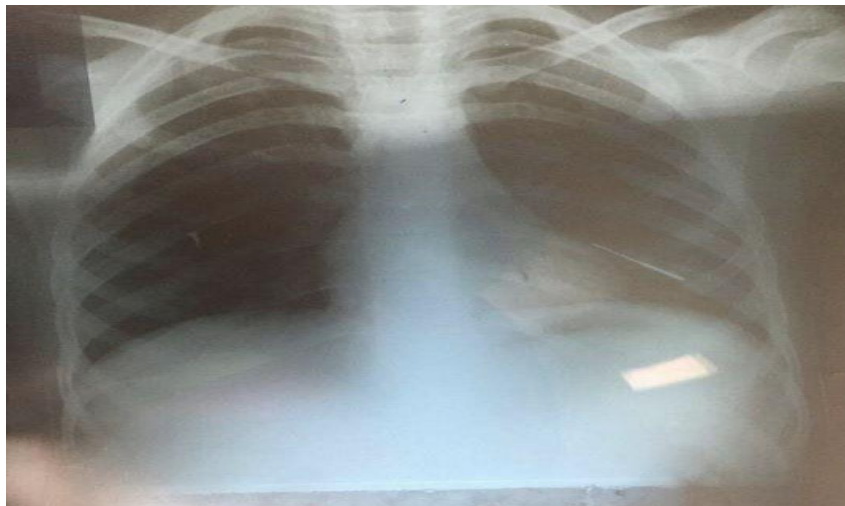


Fig.1: The first chest X-ray of the patient visualizing the swallowed needle in the lower zone of the left lung.

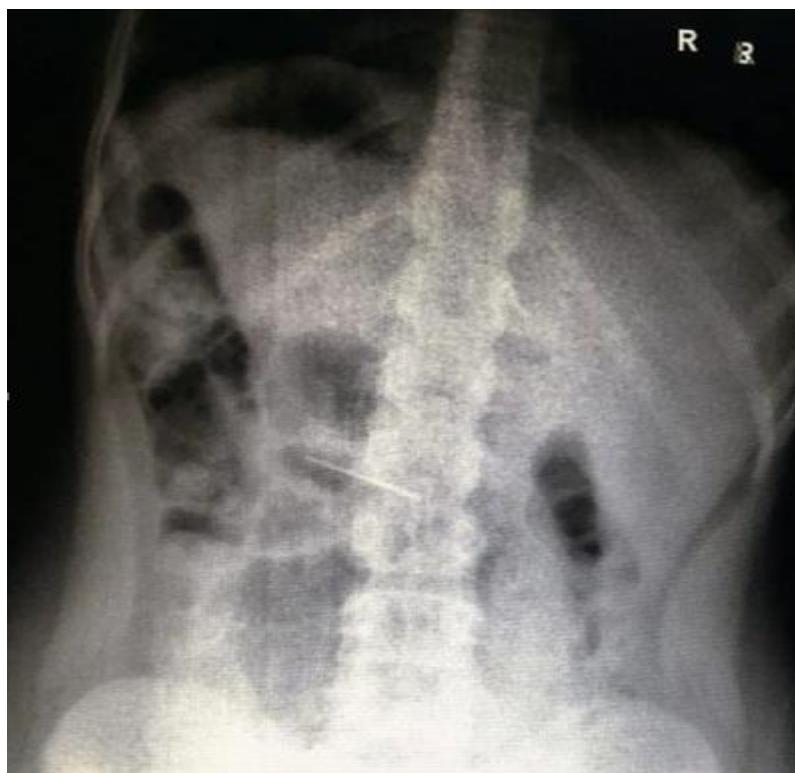

Fig.2: Abdominal X-ray showing the needle had passed the pylorus.

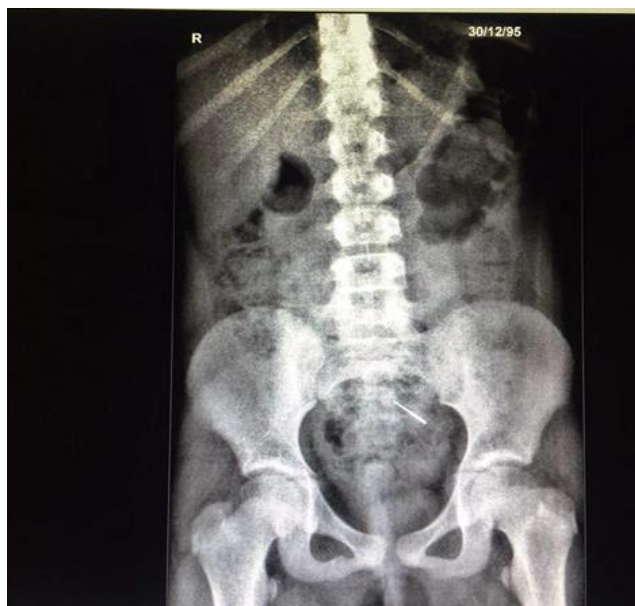

Fig.3: Follow up abdominal X-ray after 24 h revealed that the needle passed the small intestine and was in the colon.

3- DISCUSSION

Foreign Body Aspiration could be a mysterious medical condition with various presentations ranging from simple and well known manifestations of aspiration, including choking and coughs, to even rare complications including emphysema or pneumomediastinum (5). FBA patients may present in all age groups but toddlers and children in specific ages are more likely to aspirate foreign bodies. A retrospective study about FBA demonstrated that most cases of FBA are observed in children between the age of 7 months and 14 years-old and boys were most likely to aspirate foreign bodies, among which 36% were younger than 3 years-old. The aforementioned study also revealed that the most common presentations of FBA were choking (74%) and cough (73%) (3), several reports have been published about asymptomatic presentation of FBA in chest X-rays. Gharedaghi et al. reported a case of Palm kernel aspiration in a 10 year-old child who presented with choking and wheezing and clear chest X-rays and was discharged (6). The patient was admitted again with

severe respiratory distress and lung collapse 12 h after discharge and unfortunately expired (6). The most common scenario of FBA is a sudden onset of choking and cyanosis in a child that was playing with objects around him/her. Immediate diagnosis of FBA in children is mandatory for preventing unwanted complications and even death. Rigid bronchoscopy is a desired technique for visualizing and removing aspirated objects. However, in such cases in which the aspirated object has passed down to the lower lobes of lung, optic fiber bronchoscopy will be more helpful (5). Aspiration of sharp objects including needles is more dangerous and outcomes may be more obscure. Sharp objects aspiration can be harmful and injury to respiratory tract or respiratory mucous may happen during passing down or removing these objects (7). Scarf pin-related hijab syndrome in Muslim women is a similar condition which has been previously discussed by Baram et al. This report emphasized that most of the aspirated pins impact in the left main bronchus as seen in our case (8). They

recommended rigid bronchoscopy for removing pins. In some cases, in which the exact location of foreign body is ambiguous, performing other imaging techniques including computed tomography will be helpful for localizing the object and providing further guidance for possible surgeries (5).

4- CONCLUSION

Aspiration of sharp objects in children is always a petrifying scenario for clinicians. However, in some children as the present case report, natural defense mechanisms or respiratory reflexes against aspiration including cough might be helpful, although they are not always successfully to rescue. Clinician should consider gastrointestinal tract as a possible location for vanished lung foreign bodies. We should always consider these respiratory reflexes' help as "casual" and occasional. It is not rational to postpone emergency procedures waiting for this mechanism, but if it happens, it could be helpful.

5- Key points of practice

- Foreign body aspiration is a common finding in pediatric emergency.
- Gastrointestinal tract should be considered as a possible destination for vanished foreign body in lung.

6- CONFLICT OF INTEREST: None.

7- REFERENCES

1. Hoseini M, Mostafavi SMS, Rezaei N, Boluri EJ. Orthodontic wire ingestion during treatment: reporting a case and review the management of foreign body ingestion or aspiration (emergencies). *Case Rep Dent.* 2013;2013:426591.
2. Srivastava G. Airway foreign bodies in children. *Clin Pediatr Emerg Med.* 2010;11(2):67-72.
3. Orji F, Akpeh J. Tracheobronchial foreign body aspiration in children: how reliable are clinical and radiological signs in the diagnosis? *Clin Otolaryngol.* 2010;35(6):479-85.
4. Sayedi SJ, Shojaeian R, Bani Hassan M, Khakshour A. A Case of Pulmonary Foreign Body Reviewed as Mass. *Int J Pediatr.* 2016;4(8):2281-86.
5. Emami SM, Shurideh Yazdi M, Jafarzadeh Esfehaneh R. Subcutaneous Emphysema in a Healthy Child: An Unusual Clue for the Diagnosis of Foreign Body Aspiration. *Iran J Neonatol.* 2017;8(3):75-7.
6. Gharedaghi J, Moshfegh M, Koolaei nejad K, Marashi SM, Yousefi nejad. Fatal Foreign Body Aspiration in Two-Years-Old Child. *IJFM.* 2012;18(2):127-32.
7. Tanriverdi F, Kurtoglu Celik G, Pamukcu Gunaydin G. The lucky patient who aspirated a needle. *Turkish J Emer Med.* 2015;15(3):142-4.
8. Baram A, Kakamad FH, Bakir DA. Scarf pin-related hijab syndrome: A new name for an unusual type of foreign body aspiration. *Journal Int Med Res.* 2017;300060517711086.