

ORIGINAL PAPER

ASSOCIATION OF KIRSCHNER WIRES AND SHAPE-MEMORY STAPLE IN FOUR-CORNER ARTHRODESIS

Florin GROSEANU¹✉, Stefan CRISTEA¹

¹ University of Medicine and Pharmacy Carol Davila Bucharest, St. Pantelimon Emergency Hospital, Romania

Received 27 Nov 2018, Accepted 16 Jan 2019

<https://doi.org/10.31688/ABMU.2019.54.1.15>

ABSTRACT

Background. Wrist arthrosis is a painful disease that is responsible for a reduced wrist function and upper limb dysfunction. Proposed by Watson in 1984, scaphoidectomy and four-corner arthrodesis has good results in scapho-lunate advanced collapse (SLAC) and scaphoid non-union advanced collapse (SNAC) treatment.

Objectives. The purpose of this study was to analyze the results of four-corner arthrodesis using Kirschner wire and shape-memory staples.

Methods. 12 patients (12 wrists) were operated by scaphoidectomy and four-corner arthrodesis according to Watson technique, using Kirschner wires fixation for capito-luno-hamato fusion and shape-memory staples for hamato-triquetral fusion. The mean age of the patients was 64.7 years, and the period of follow-up was 2.1 years.

Results. The results were evaluated using preoperative data, surgery protocols and clinical postoperative data obtained at follow-up: pain, patient's satisfaction, force, range of motion, X-ray imaging. The fusion was achieved in all cases in a mean time of 2.4 months for all involved articulations. The mean postoperative

RÉSUMÉ

Notre expérience dans l'association entre les broches Kirschner et les agraffes à mémoire dans l'arthrodèse des quatre os

Introduction. L'arthrose du poignet est une maladie responsable de la diminution des mouvements du poignet et de la fonction du membre supérieur. Proposée par Watson en 1984, la scaphoïdectomie et l'arthrodèse des quatre os a de bons résultats dans le traitement du collapsus avancé des lésions scaphoïdo-lunaires et le collapsus avancé de la pseudarthrose de l'os scaphoïde.

Objectifs. Cette étude avait pour but d'analyser les résultats d'une série d'arthrodèses des quatre os en utilisant l'ostéosynthèse à l'aide de broches et d'agraffes à mémoire.

Méthodes. 12 patients (12 poignets) ont été opérés par scaphoïdectomie et arthrodèses des quatre os selon la technique de Watson en utilisant des broches capito-hamato-lunaires et des agraffes hamato-triquetrales, avec un âge moyen de 64,7 ans au moment de l'intervention. Le recul moyen a été de 2,1 ans (minimum 6 mois-maximum 3.8 ans).

✉ Address for correspondence:

Florin GROSEANU
University of Medicine and Pharmacy Carol Davila Bucharest, St. Pantelimon
Emergency Hospital, Romania
Address: Sos. Pantelimon No 340, Sector 2, Bucharest, Romania
Email: drgroseanufloirin@yahoo.com

range of motion was 26.25° of extension, 24.16° of flexion, 16.11° of radial inclination and 18.89° of cubital inclination. After surgery, compared to the unaffected contralateral side, grip strength was 62.8%.

Conclusions. Combination of K-wires and shape-memory staple for four-corner arthrodesis is very efficient in treating SLAC and SNAC lesions.

Keywords: four-corner arthrodesis, K-wires, shape-memory staple.

Abbreviations: SLAC = scapho-lunate advanced collapse, SNAC = scaphoid non-union advanced collapse, DISI = dorsal intercalated segment instability, K-wires = Kirschner wires

INTRODUCTION

Wrist arthrosis is a painful disease that is responsible for a reduced wrist function and upper limb dysfunction. The most frequent cause is the posttraumatic rupture of scaphoido-lunar ligament, that produces scapho-lunate advanced collapse (SLAC) lesions. SLAC treatment depends on many factors: stage of arthrosis, patient's demands, surgeon's experience. The techniques used in these cases are represented by: radial styloidectomy, wrist denervation, proximal row carpectomy, complete or partial wrist arthrodesis (capitate-lunate, three-corner, four-corner).

Proposed by Watson¹ in 1984, scaphoidectomy and four-corner arthrodesis have good results in SLAC and scaphoid non-union advanced collapse (SNAC) treatment. In certain cases, the arthrodesis can be limited to the lunar-capitate articulation, especially in cases with ulnar-minus variant, because a too much rigid triquetrum can produce ulnar-carpal impingement; in these cases, reduction of apposition surfaces can lead to non-union^{2,3}.

Over the years, many types of osteosynthesis have been suggested. Because the postoperative results are not always satisfactory, the optimal technique still represents a matter of discussion: Kirschner wires (K-wire)^{1,4,5}, shape-memory staples, screws, locking or non-locking plates.

THE OBJECTIVE OF THE STUDY was to analyze the results of four-corner arthrodesis using Kirschner wires and shape-memory staples in a group of patients.

Résultats. Pour évaluer les résultats on a utilisé les données cliniques pré-opératoires, les comptes-rendus opératoires, les renseignements cliniques post-opératoires obtenus lors de la révision: douleur, satisfaction globale du patient, force, les mobilités, les radios. Toutes les arthrodèses ont consolidé dans un temps moyen de 2,4 mois. L'amplitude des mouvements post-opératoires a été en moyenne de 26,25° d'extension, de 24,16° de flexion, de 16,11° d'inclinaison radiale et de 18,89° d'inclinaison cubitale. La force de préhension en pré-opératoire était de 47.46% et en post-opératoire de 62.8%.

Conclusions. L'association broches-agraffes à mémoire pour l'arthrodèse des quatre os est très efficace dans le traitement des lésions SLAC et SNAC.

Mots-clés: Arthrodèse des quatre os, broches Kirschner, agraffes à mémoire.

MATERIAL AND METHODS

We performed a retrospective study on 12 patients (12 wrists) operated between 2012-2014 in the Orthopaedic and Trauma Clinic of St. Pantelimon Emergency Hospital, Bucharest, Romania, by scaphoidectomy and four-corner arthrodesis according to Watson's technique, using Kirschner wires fixation for capito-luno-hamato fusion and shape-memory staples (EasyClip, Stryker) for hamato-triquetral fusion. The mean age of the patients was 64.7 years (46-81 years), the follow-up period was 2.1 years (6 months-3.8 years). In the study were included all patients with degenerative or posttraumatic radio-scaphoid and midcarpal arthrosis. The exclusion criteria were the presence of neurologic diseases, radio-lunate arthrosis, acute or chronic wrist infection.

Pathologies were represented by 2 posttraumatic arthrosis (scapho-lunate dissociation), 1 SNAC, 7 SLAC and 2 chondrocalcinosis.

The approach was longitudinal, in line with the 3rd metacarpal, over the third extensor compartment. In all cases, the posterior interosseous nerve was transected. After capsulotomy, we have done scaphoid excision and then cartilage excision of luno-capitate, hamato-triquetrale and capito-hamate articulations. Correction of dorsal intercalated segment instability (DISI) was done using one of the following two procedures: either associating antero-posterior shift, wrist extension and axial compression, or joystick lunate manipulation using a temporary Kirschner wire. Osteosynthesis was done by Kirschner wires fixation for capito-lunate and hamato-lunate fusion and shape-memory staple for hamato-triquetrale fusion (Fig. 1).

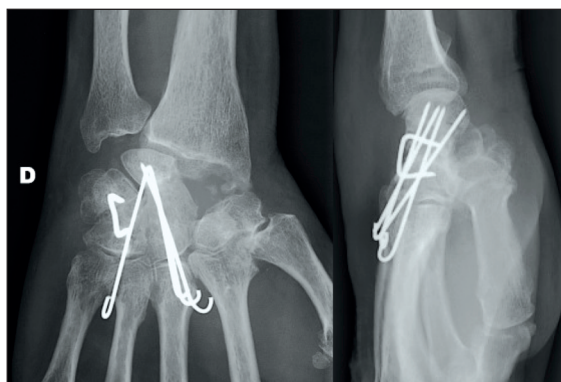

Figure 1. Case 1 using 4 Kirschner wires and 1 staple.

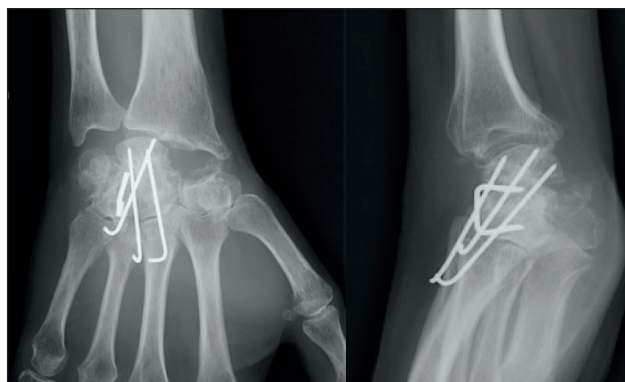


Figure 2. Case 2 using 3 Kirschner wires and 1 staple.

In 11 cases we have used spongiform graft taken from the excised scaphoid. The wires were curved and placed in the intermetacarpal spaces, to avoid a conflict with extensor tendons. After surgery, the wrist was immobilized in an antebrachial-palmar cast for 2 weeks and then in a removable orthosis for other 6 weeks.

The results were evaluated using preoperative data, surgery protocols and clinical postoperative data obtained at follow-up: global patient's satisfaction, Mayo pain scale (1-no pain; 2- pain with forceful solicitations; 3- pain in day-life activity; 4- invalidating pain), grip strength (Jamar), bilateral pre- and postoperative wrist motion (flexion, extension), pre- and postoperative X-ray in posterior-anterior and lateral views, Computed Tomography or Nuclear Magnetic Resonance Imaging.

RESULTS

In 9 cases we found no postoperative pain (75%), the patients being very satisfied with this intervention. In 2 cases (16.67%) we found pain with forceful demands, and in one case (8.33%) pain was present in day-life activity.

The fusion was achieved in all cases, in a mean time of 2.4 months (2-4 months) for all involved articulations (Fig. 2). The mean postoperative range of motion was 26.25° of extension (0° -35°), 24.16° of flexion (0° - 40°), 16.11° of radial inclination (10° - 30°) and 18.89° of cubital inclination (10° - 30°). Before surgery, grip strength was 47.56% compared to the unaffected side. After surgery, grip strength was 62.8% compared to the unaffected side.

Dorsal intercalated segment instability (DISI) correction was perfect in 10 cases; in 2 cases we found a radio-lunate unbalance. The case with DISI of 10° had an arch of movement from 30° of extension to 40° of flexion, and pain with force solicitations. In the case with residual 30° of DISI, motion

was extremely diminished (0° of extension and 20° of flexion), with pain in day-life activity.

Material ablation was done in 8 cases (wires), including 2 cases for pin migration, one case for conflict with extensor tendons and one case for broken wire. In one case, we have associated staple with wires ablation.

Complications were caused by distal pin migration (1 case), proximal pin migration (1 case) blocking radio-lunate movement and 1 case with broken wire in the 5th metacarpal but without articular involvement. In one patient we found extensor synovitis, caused by wire conflict with extensor tendons and pain in the medial side (staple); after tendons synovectomy and ablation of material the wrist became pain-free.

DISCUSSION

Made popular by Watson¹ in 1984, scaphoidectomy and four-corner arthrodesis has good results in the treatment of SLAC and SNAC lesions. For the best efficacy, the radio-lunate articulation must be intact.

This method must be intended to correct lunate flexion (DISI deformation), to achieve alignment and to avoid the contact between radius and capitate in wrist extension. The best results in terms of wrist mobility and force are obtained if the capitate-lunate fusion is achieved in slight extension⁶. This intervention is contra-indicated in cases of crystalline or inflammatory arthritis³.

Used by Watson^{1,4} in his own technique, Kirschner wires were abandoned after the poor results reported by certain surgeons: pin migration, tract pin infection and especially the prolonged immobilization in brachial-antebrachial-palmar-digital cast. Regarding infections, the complications due to this method are not higher than other methods of osteosynthesis and the arch of movement is usually higher⁷.

The complications rate found in our study is not higher than that reported by other studies and especially no infections on wire tract, which give us the conviction that wire-staple association could be used successfully in four-corner arthrodesis, even though our study included only a small number of patients. DISI correction, that was achieved intraoperatively, was maintained for all the period, until the final follow-up.

Staples osteosynthesis (multiple shape-memory or quadripode staples) can be used for four-corner arthrodesis, but their rigidity is insufficient and it must be often associated with screws supplementation. Le Corre et al⁸ found in their study 24.3% cases of implant failure and in 18% cases the reoperation was necessary, 75% of their patients being satisfied by the intervention. Ardouin et al⁹ found out 37.8% cases of implant failure and pain was absent in only 43% patients. When staples are disposed in the sagittal plan, they can cause an impingement between the radius and the proximal coin of the staple¹⁰; before staple osteosynthesis, it is mandatory to remove all cartilages from articular surfaces and to carefully prepare the four bones apposition¹¹, otherwise the complications rates are very high^{4,9,12}.

Screws fixation can be used in proximal-distal or distal-proximal manner. Headless screws can be hidden in carpal bones. The advantage of this kind of osteosynthesis is the possibility of early rehabilitation, but the disadvantage is that they affect lunate cartilage (proximal to distal screws)¹³ and wrist arch of movement is lower. Maire et al¹⁴, evaluating 10 arthrodeses using two screws fixation, found out good results in terms of pain relief, force, return to work, but bad results in terms of mobility. In the literature, we found out a complications rate as high as 20%, in terms of delayed union and especially non-union^{13,14}.

Many plates designs are available for bones fixation: Spider, X-pode, H-plate, bioresorbable. They permit early rehabilitation and they need almost 4 weeks of immobilization. The complications rate associated with plates fixation are as high as 55%, especially implant failure and non-union, because it is impossible to achieve compression between the four bones¹⁵⁻¹⁸. Le Corre et al⁸ found out 60% of implant failures and 14% reinterventions; patients' lack of satisfaction was encountered in 40% of cases. In a study made on 18 patients, Kendall¹⁸ found out 15 patients with non-union and patients' unsatisfaction rate up to 50%; the arch of movement was 46% and force 56% of contralateral wrist.

Pamelin et al¹¹, in a study of 18 patients, found out reduced mobility in 8 cases, in whom X-ray has shown an impingement between the plate and the dorsal radius rim; in 6 cases it was necessary to remove the plate and to stabilize the fusion by staples.

David et al¹⁷ showed in their study that articular movement was reduced with 50% and the force was reduced with 40% face of contralateral wrist. 75% of patients have had pain, varying from minimal to invalidating and permanent. X-ray imaging demonstrated many cases with incomplete fusion. Up to 50% of patients had complications (in 15% severe complications, leading to reoperation or plate removal)¹⁷.

Ardouin et al⁹ noted in their study a rate of implant failure of 60% and 14% cases of reintervention. Complications rate was 55% and only 50% patients were satisfied with the results.

Plate osteosynthesis does not need cartilage resection, but the technique must be very rigorous in regard to plate position at the four bones intersection; the plate must be stabilized with as many screws as possible, to avoid micromotion during daily activity, because it can produce screw failure¹¹. Their use is limited by their elevated cost, the difficulty to correct DISI² and the impingement between plate and radius². Often, it is necessary to remove the plate, in order to avoid long-term complications.

There is no consensus in the literature regarding the arch of movement necessary for day-life activity. Watson¹ thought that 31° of flexion and 30° of extension represent a good result for patient's demands. Palmer et al¹⁹ showed that 5° of flexion and 30° of extension are almost suitable with a good quality of life, while Ryu et al²⁰ sustained that 40° of each represents the goal for the arthrodesis. Our belief is that 20° of flexion and 30° of extension are compatible with an almost normal life.

CONCLUSIONS

We propose the combination of K-wires and shape-memory staple for four-corner arthrodesis, this technique being reproducible, simple, cheap and very efficient in treating SLAC and SNAC lesions. The clinical results depend on the correction of DISI and on the alignment of radio-lunate articulation. Complications' rate is smaller than other methods of osteosynthesis and it requires only antebrachial-palmar-digital immobilization.

Compliance with Ethics Requirements:

„The authors declare no conflict of interest regarding this article“

„The authors declare that all the procedures and experiments of this study respect the ethical standards in the Helsinki Declaration of 1975, as revised in 2008(5), as well as the national law. Informed consent was obtained from all the patients included in the study“

„No funding for this study“

REFERENCES

1. Watson HK, Ballet FL. The SLAC wrist: scapholunate advanced collapse pattern of degenerative arthritis. *Journal of Hand Surgery Am.* 1984;9(3):358-365.
2. Garcia-Elias M. Carpal instability, in Green's Operative Hand Surgery, 6th ed., 2010(1):465-522.
3. Amadio PC, Shin AY. Arthrodesis and arthroplasty of small joints of the hand, in Green's Operative Hand Surgery, 6th ed., 2010(1): 389-406.
4. Watson HK, Weinzweig J, Guidera PM, Zeppieri J, Ashmead D. One thousand intercarpal arthrodesis. *Journal of Hand Surgery Br.* 1999;24(3): 307-315.
5. Hammas S, Bertrand M, Coulet B, Gadblad G, Rigout C, Allieu Y. Scaphoïdectomie et arthrodesè des quatre os internes du poignet, in: Herzberg G, editor, Arthrose périscaphoïdienne. Montpellier, Sauramps; 2006: 179-198.
6. Dagrègorio G, Saint-Cast Y, Fouque PA, Raimbeau G, Le Bourg M. Influence de l'angle de fusion capito-lunaire sur le résultat fonctionnel de l'intervention de Watson réalisée dans 58 cas de collapsus carpiens avancés. *La Main.* 1998; 3(4):363-372.
7. De Smet L, Deprez P, Duerinckx J, Degreef I. Outcome of four-corner arthrodesis for advanced carpal collapse: circular plate versus traditional techniques. *Acta Orthopaedica Belgica.* 2009;75(3):323-7.
8. Le Corre A, Ardouin L, Loubersac T, Gaisne E, Bellemère P. Retrospective study of two fixation methods for 4-corner fusion: shape-memory staple vs. dorsal circular plate. *Chirurgie de la Main.* 2015; 34(6):300-306.
9. Ardouin L, Bellemère P, Chaise F, et al. L'arthrodèse des 4 os, étude rétrospective comparant deux moyens de fixation: agrafe à mémoire de forme ou cupule vissée? *Chirurgie de la Main.* 2013; 32(6):446.
10. Shapiro JS. Power staple fixation in hand and wrist surgery: new applications of an old fixation device. *Journal of Hand Surgery Am.* 1987;12(2): 218-227.
11. Pamelin E, Rosello M, Spingardi O, Zoccolan A. L'arthrodèse des quatre os par agrafe et par plaque vissée: notre expérience. *Chirurgie de la Main.* 2012;31(6):403.
12. Benkeddache Y, Gottesman H, Fourrier P. Multiple stapling for wrist arthrodesis in the nonrheumatoid patient. *Journal of Hand Surgery Am.* 1984; 9A:256-260.
13. Henry M. Internal headless compression screw method for 4-corner fusion. *Journal of Hand Microsurgery.* 2009;1(1): 45-49.
14. Maire N, Facca S, Gouzou S, Liverneaux P. Arthrodesè des quatre os par vis-broche à compression: à propos d'une série de dix cas. *Chirurgie de la Main.* 2012;31(6): 403.
15. Pauchard N, Breton A, Jager T, et al. Résultats préliminaires des arthrodeses des quatre os par plaque verrouillée. A propos de 30 cas. *Chirurgie de la Main.* 2012;31(6): 403.
16. Alech Tournier F, Vogels J, Benassayag M, et al. La plaque Xpode: une avancée dans l'arthrodèse partielle des os du carpe? *Chirurgie de la Main.* 2012;31(6): 404.
17. David E, Lebeau N, Moughabghab M. Analyse rétrospective à moyen terme d'une série de 30 arthrodeses des 4 os internes par plaque Xpode. *Chirurgie de la Main.* 2013;32(6): 476.
18. Kendall CB, Brown TR, Millon SJ. Results of four-corner arthrodesis using dorsal circular plate fixation. *Journal of Hand Surgery Am.* 2005;30: 903-907.
19. Palmer AK, Werner FW, Murphy D, Glisson R. Functional wrist motion: a biomechanical study. *Journal of Hand Surgery.* 1985;10A:39-46.
20. Ryu JY, Cooney WP 3rd, Askew LJ, An KN, Chao EY. Functional ranges of motion of the wrist joint. *Journal of Hand Surgery.* 1991;16A:409-419.