

REVIEW

The current role of echocardiography in acute aortic syndrome

Arturo Evangelista MD PhD FESC¹, Giuliana Maldonado MD², Domenico Gruosso MD¹, Laura Gutiérrez MD¹, Chiara Granato MD¹, Nicolas Villalva MD¹, Laura Galian MD¹, Teresa González-Alujas MD PhD¹, Gisela Teixido MD PhD¹ and Jose Rodríguez-Palomares MD PhD¹

¹Cardiovascular Imaging Department, University Hospital Vall d'Hebron, CIBER-CV, Barcelona, Spain

²Cardiovascular Imaging Department, Instituto del Corazon, Quironsalud Teknon, Barcelona, Spain

Correspondence should be addressed to A Evangelista: arturevangelistamasip@gmail.com

Abstract

Acute aortic syndrome (AAS) comprises a range of interrelated conditions caused by disruption of the medial layer of the aortic wall, including aortic dissection, intramural haematoma and penetrating aortic ulcer. Since mortality from AAS is high, a prompt and accurate diagnosis using imaging techniques is paramount. Both transthoracic (TTE) and transoesophageal echocardiography (TEE) are useful in the diagnosis of AAS. TTE should be the first imaging technique to evaluate patients with thoracic pain in the emergency room. Should AAS be suspected, contrast administration is recommended when images are not definitive. TEE allows high-quality images in thoracic aorta. The main drawback of this technique is that it is semi-invasive and the presence of a blind area that limits visualisation of the distal ascending aorta near. TEE identifies the location and size of the entry tear, secondary communications, true lumen compression and the dynamic flow pattern of false lumen. Although computed tomography (CT) is the most used imaging technique in the diagnosis of AAS, echocardiography offers complementary information relevant for its management. The best imaging strategy for appropriately diagnosing and assessing AAS is to combine CT, mainly ECG-gated contrast-enhanced CT, and TTE. Currently, TEE tends to be carried out in the operating theatre immediately before surgical or endovascular therapy and in monitoring their results. The aims of this review are to establish the current role of echocardiography in the diagnosis and management of AAS based on its advantages and limitations.

Key Words

- ▶ acute aortic syndrome
- ▶ aortic dissection
- ▶ transoesophageal echocardiography
- ▶ transthoracic echocardiography
- ▶ echocardiography in aortic surgery

Introduction

Acute aortic syndrome (AAS), an acute process affecting the aortic wall with disruption of the media layer, carries high rates of morbidity and mortality. Essentially, it involves three entities: aortic dissection, intramural haematoma and penetrating ulcer (1). The incidence of AAS is approximately 50–150 cases (2, 3) per million population per year, 80% of which are dissections,

15% intramural haematomas (IMH) and 5% penetrating ulcers (PAU) (4). The diagnosis of classic aortic dissection is based on the demonstration of an intimal flap that divides the aorta in two, the true and false lumina. IMH is characterised by circular or crescentic thickening of the aortic wall >5mm and PAU presents as an image of crater-like outpouching with jagged edges in the



aortic wall, generally associated with extensive aortic atheroma. There are two classifications according to the extent of aortic involvement (5): the DeBakey and Stanford classification.

Diagnosis

AAS has a high mortality rate and early medical and surgical treatment is crucial. Therefore, rapid and accurate diagnostic techniques, which can be applied in critically ill patients, are essential (6). The diagnosis of aortic dissection can be made with similar accuracy using different imaging techniques such as TEE, CT or MRI (7, 8). CT is the most used imaging technique in the diagnosis of aortic dissection (77%) (9), given that it is available 24 h a day even in remote community hospitals and allows whole aorta visualisation and most of the AAS complications. However, the use of transthoracic echocardiography (TTE) and transoesophageal echocardiography (TEE) are often required to obtain crucial information.

Role of TTE and TEE in the diagnosis of aortic dissection

Echocardiography has become the most used imaging test in the clinical evaluation of cardiovascular disease and plays an important role in the diagnosis of aortic diseases. Among imaging techniques, echocardiography has the advantage that it can be performed at the patient's bedside or in any hospital department (emergency, intensive unit, operating room), without the need to transfer the patient who is often in an unstable haemodynamic situation. While TTE should be used routinely in the emergency and critical units, TEE requires a greater knowledge and experience, especially when the patient is not anaesthetised.

Transthoracic echocardiography (TTE)

TTE permits adequate assessment of several aortic segments, particularly the aortic root and proximal ascending aorta (9) and, in most cases, the aortic arch, proximal descending aorta and abdominal aorta. All scanning planes should be used including the left and right parasternal long-axis views, the suprasternal, two-chamber and subcostal views. In some series, sensitivity in the diagnosis of ascending aorta dissection

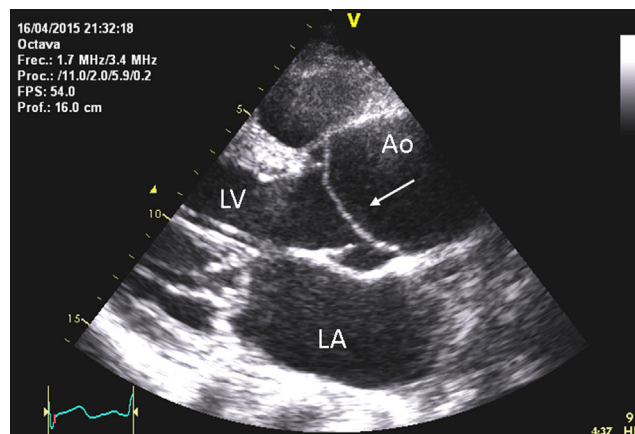


Figure 1

Type A aortic dissection diagnosed by TTE. Arrows show the intimal flap in the aortic root. Ao, Aorta; LA, left atrium; LV, left ventricle.

was 78–90% but only 31–55% in descending aortic dissection (10). Specificity for type A aortic dissection was reported to range from 87 to 96% and for type B dissection 60–83% (11). TTE is most useful when the flap is located in the aortic root (Fig. 1 and Video 1).

Video 1

Type A aortic dissection diagnosed by TTE. View Video 1 at <http://movie-usa.glencoesoftware.com/video/10.1530/ERP-18-0058/video-1>.

Contrast TTE increases sensitivity and specificity for type A aortic dissection to 93 and 97% respectively, which is similar to TEE in the diagnosis of type A aortic dissection, although it is limited in type B involvement (sensitivity 84% and specificity 94%), mainly in the presence of non-extended dissection (12) (Fig. 2 and Videos 2, 3). Given its availability and additional information on cardiac condition, contrast TTE may be used as the initial imaging modality in the emergency setting when TTE information is not definitive. However, a negative TTE does not rule out aortic dissection, and other imaging techniques must be considered. Furthermore, the contrast provides little for the diagnosis of intramural aortic haematoma; therefore, if the suspicion is high, the practice of CT should be indicated. As specified in a previous publication (12), the mechanical index should be set between 0.6 and 0.9 to optimise contrast enhancement visualisation in the aorta. Several boluses should be injected to obtain complete information on the ascending aorta, arch, proximal descending aorta and abdominal aorta, using similar windows to conventional echocardiographic studies.

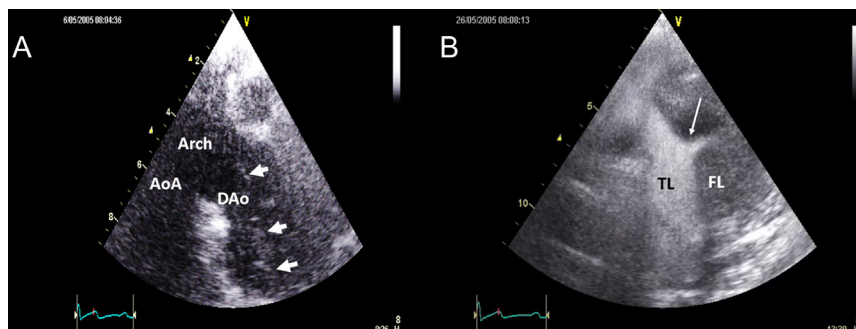


Figure 2

Type B dissection. (A) By TTE suprasternal view, a faint line in descending thoracic aorta could be identified (arrows). (B) By contrast TTE, two lumina are well visualised, true (TL) and false lumen (FL). Arrow shows the flow through the intimal tear from the true lumen (TL) to the false lumen (FL). Aao, ascending aorta; Dao, descending aorta.

Video 2

Type B dissection by TTE suprasternal view, a faint line in descending thoracic aorta could be identified. View Video 2 at <http://movie-usa.glencoesoftware.com/video/10.1530/ERP-18-0058/video-2>.

Video 3

Type B dissection by contrast TTE, two lumina are well visualised, true and false lumen. View Video 3 at <http://movie-usa.glencoesoftware.com/video/10.1530/ERP-18-0058/video-3>.

Transoesophageal echocardiography (TEE)

TEE is currently considered one of the reference techniques in aortic dissection diagnosis (7, 8, 13). The proximity of the oesophagus to the aorta, without interference from the chest wall or lung, permits high-quality images to be obtained. TEE permits identification of the intimal flap in most type A dissections (Fig. 3 and Video 4) and type B (Fig. 4 and Video 5) (14). Several studies have demonstrated the accuracy of TEE in the diagnosis of aortic dissection with sensitivity of 86–100%, specificity 90–100% and a negative predictive value of 86–100% (15, 16).

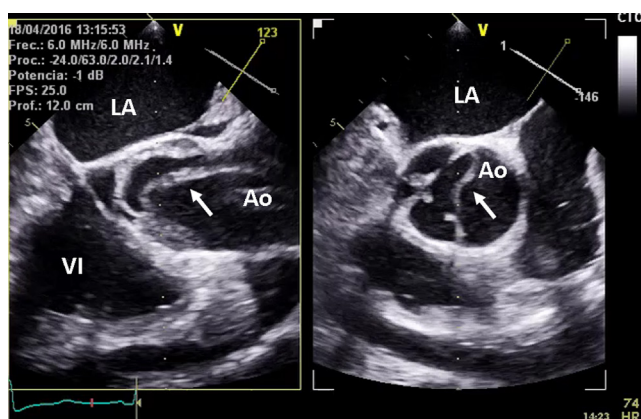


Figure 3

Type A dissection diagnosed by TEE in ascending aorta. Intimal flap is well defined (arrows) in longitudinal (left) and transverse planes (right).

However, TEE is semi-invasive and requires sedation and may cause a rise in systemic pressure from retching and gagging. Although isolated cases of aortic rupture during the procedure have been reported, the incidence in prospective series is very low, being more related to the intrinsic risk of the disease than the procedure itself, as these events also occur during CT or MRI. However, adequate sedation with strict blood pressure control is mandatory. One of the main limitations of TEE in the diagnosis of aortic dissection is the presence of ultrasound artefacts in ascending aorta which are common (17), particularly when dilated. Linear reverberation images, some of which may mimic an intimal flap are observed in 44–55% of studies. Artefacts in the aortic root are a reverberation from the anterior wall of the left atrium, are typically located twice as far from the transducer as the posterior aortic wall, and their movement is parallel to the posterior aortic wall but with double displacement amplitude. In the middle third of the ascending aorta, they are due to reverberations from the posterior wall of the right pulmonary artery and are located at twice the distance from the right pulmonary artery posterior wall as from the posterior aortic wall. The assessment of location and movement of these intraluminal images by M-mode echocardiography is the best way to differentiate between intimal flap and imaging reverberations (Fig. 5).

Video 4

Type A dissection diagnosed by TEE in ascending aorta. Intimal flap is well defined in longitudinal and transverse planes. View Video 4 at <http://movie-usa.glencoesoftware.com/video/10.1530/ERP-18-0058/video-4>.

Video 5

Type B dissection diagnosed by colour Doppler TEE showing a turbulent flow through a secondary tear from the true lumen to false lumen. View Video 5 at <http://movie-usa.glencoesoftware.com/video/10.1530/ERP-18-0058/video-5>.

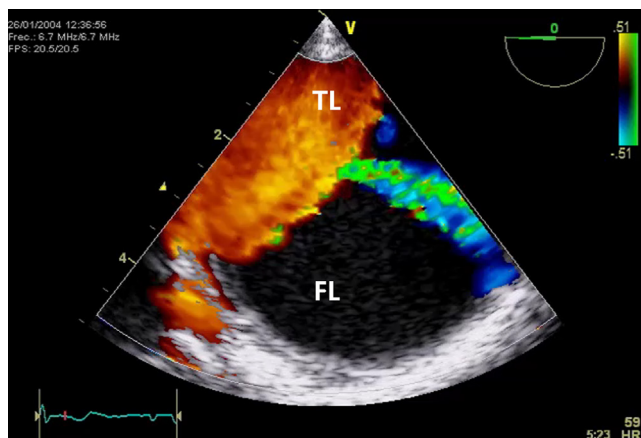


Figure 4

Type B dissection diagnosed by colour Doppler TEE showing a turbulent flow through a secondary tear from the true lumen (TL) to false lumen (FL).

TEE is clearly superior to TTE in the diagnosis of IMH and PAU. IMH may sometimes be mistaken for an intraluminal thrombus or a dissection with thrombosed false lumen. Displacement of intimal calcification caused by accumulation of blood within the aortic media is useful for the differential diagnosis; the inner margin of intramural haematoma is smooth and aortic thickening occurs beneath the bright echo-dense intima. IMH is quite easily differentiated from classical aortic dissection with flow in two lumina. However, the diagnosis can be difficult when the false lumen of dissection is totally thrombosed (18).

Diagnosis of PAU by echocardiography is based on the image of crater-like outpouching of the aortic wall, in many cases associated with an atheroma plaque (19). By TEE, it is crucial to displace the transducer very slowly and visualise the circumference (360°) of the entire thoracic aorta to avoid a false-negative diagnosis. Diagnosis of PAU is easier by CT than by TEE. However, TEE allows

better aetiological classification of the PAU, considering ulcerated plaques, chronic intimal disruption from IMH or penetrating atherosclerotic ulcer, all of which have a different prognosis (Fig. 6A and B).

Anatomical and functional findings of aortic dissection

In addition to an adequate diagnosis, TEE permits assessment of the main anatomical and functional aspects of interest for the management of aortic dissection.

Intimal tear

The intimal tear appears as a discontinuity of the intimal flap. TEE permits identification of the tear in 78–100% of cases (20). The location and size of the primary entry tear directly influences therapeutic options and has prognostic implications. The main intimal tear usually has a diameter >5 mm; in fact, >7–10 mm are easily visualised by 2D echocardiography and are frequently located in the proximal part of the ascending aorta in type A dissections and immediately below the origin of the left subclavian artery in type B dissections. In 10% of cases, the main intimal tear are located in blind TEE areas, the abdominal aorta or distal ascending aorta, and in these cases, contrast may suggest where the entry tear is located. 3D echocardiography is very useful to quantify the intimal tear area (Fig. 7) (21).

Secondary communications

Using colour Doppler, multiple small communications (<3 mm) between the two lumina can be visualised, especially in the descending aorta; most of these

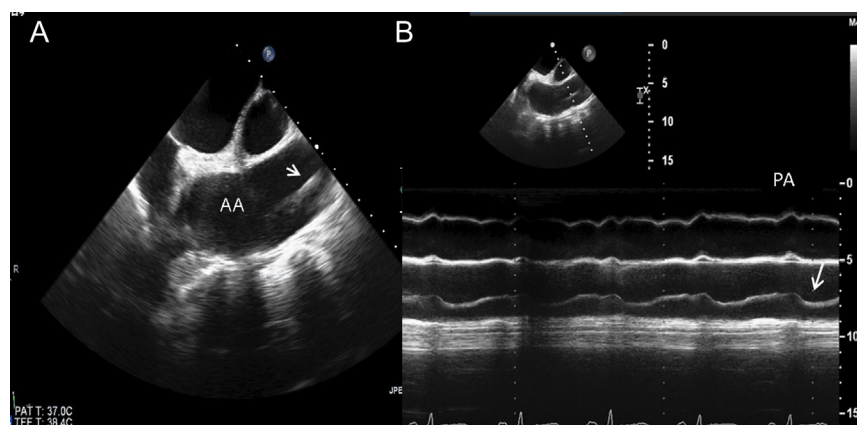


Figure 5

In (A), a linear intraluminal ascending aorta (AA) image (arrow) by TEE in longitudinal view mimicking an intimal flap. In (B), M-mode echocardiography shows this image (arrow) to be a reverberation from the pulmonary artery wall (PA).

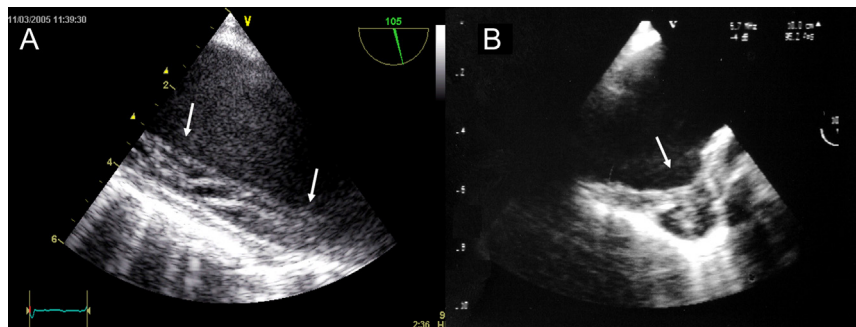


Figure 6
(A) Intramural haematoma (arrows) in descending aorta diagnosed by TEE in longitudinal plane. (B) Penetrating aortic ulcer (arrow) in the proximal descending aorta.

communications might correspond to the origin of intercostal or visceral arteries (Fig. 4 and Video 5). These secondary communications have no prognostic implications; although in absence of distal discharge of the false lumen, they may partially decompress the true lumen.

True lumen identification

Identification of the true lumen is of special clinical interest, since it allows understanding of dynamic aspects for the management of aortic dissection. If the aortic arch is involved, the surgeon needs to know whether the supra-aortic vessels originate from the false or true lumen. Similarly, when the descending aorta dissection affects visceral arteries and ischaemic complications arise, it is necessary to identify the false lumen prior to surgery or endovascular treatment such as intima fenestration or stent-graft implantation. The signs that permit the identification of true lumen are specified in Table 1 (Fig. 8) (9).

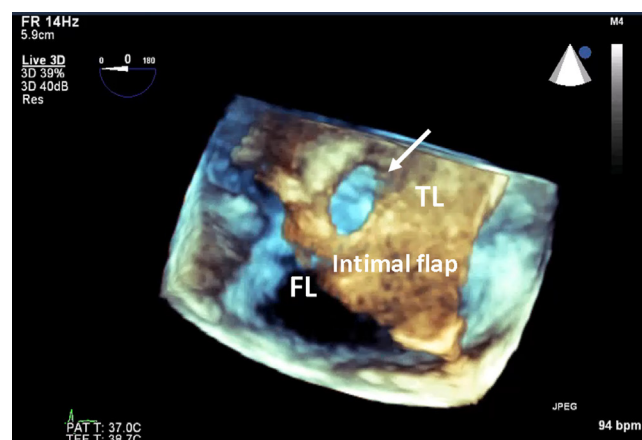


Figure 7
Large intimal tear visualised by 3D-TEE (arrow) in proximal descending aorta.

Diagnosis of AAS complications

Appropriate AAS complications diagnosis during the initial study may affect therapeutic decisions in the acute phase. TTE may be used as the initial modality in the emergency setting. Intimal flap in the proximal ascending aorta, pericardial effusion/tamponade, significant aortic regurgitation and left ventricular function can be easily assessed by TTE.

Pericardial effusion

This frequent complication in type A AAS occurs in 40% of cases and tamponade in 12% (22). The presence of pericardial effusion may suggest rupture of the false lumen in the pericardium, although it may be secondary to irritation of the adventitia produced by aortic haematoma or small effusion from the wall. In any event, the presence of pericardial effusion in an AAS is an indicator of poor prognosis. Echocardiography is the best diagnostic technique for assessing the presence of cardiac tamponade (Fig. 9 and Video 6).

Video 6

TTE showing a intimal flap in aortic root and anterior pericardial effusion (PE) with moderate compression of the right ventricle. View Video 6 at <http://movie-usa.glencoesoftware.com/video/10.1530/ERP-18-0058/video-6>.

Periaortic haematoma

The incidence of periaortic haematoma is similar in acute type A and type B aortic syndrome (26.6 vs 27.4%, $P=0.92$) (22) and has been related to an increase in mortality. CT is the technique of choice for the diagnosis of periaortic haematoma and pleural effusion. TEE is limited in the diagnosis of this complication as it is only made with an increase in distance greater than 10 mm between the oesophagus and aorta (23).

Table 1 Differentiation between true and false lumina.

	True lumen	False lumen
Size	True < false	Most often: false > true lumen
Pulsation	Systolic expansion	Systolic compression
Flow direction	Systolic antegrade flow	Systolic antegrade flow reduced or absent, or retrograde flow
Communication flow	From true to false lumen in systole	
Contrast echo flow	Early and fast	Delayed and slow

Aortic regurgitation

Aortic regurgitation is a frequent complication, occurring in 40–76% of cases of type A aortic dissection. The diagnosis and quantification can be made by TTE and TEE. However, TEE provides better information regarding possible mechanisms that influence aortic regurgitation (Fig. 10, Table 2 and Video 7), which may greatly help the surgeon in deciding whether to replace or repair the aortic valve (24).

Video 7

TEE showing the intimal flap prolapsing through the aortic valve to the left ventricle. View Video 7 at <http://movie-usa.glencoesoftware.com/video/10.1530/ERP-18-0058/video-7>.

Arterial vessel involvement

The diagnosis of main arterial vessel involvement is important since visceral or peripheral malperfusion syndrome is associated with higher morbidity and mortality. The incidence of peripheral (10.1 vs 6.2%) or mesenteric ischaemia (6.4 vs 6.2%) is similar in type A and type B aortic syndrome (22). TEE permits the diagnosis of coeliac trunk involvement by dissection or compression. Similarly, accuracy in the diagnosis of supra-aortic trunks involvement by TEE is better under anaesthesia (25) (Table 3). Nevertheless, CT provides by far more precise and detailed anatomical information and is irreplaceable for diagnosing renal and iliac artery disease.

TEE, like CT, can diagnose two types of circulation disorders of arterial branches with important therapeutic implications: dissection or dynamic obstruction of the arterial trunk ostia. Dynamic compression of the true lumen by the false lumen requires emergent treatment closing the entry tear (Fig. 11 and Video 8).

Video 8

Severe compression of the TL causing visceral and peripheral ischaemia. View Video 8 at <http://movie-usa.glencoesoftware.com/video/10.1530/ERP-18-0058/video-8>.

Involvement of the coronary arteries in dissection has been considered to be 10–15%, with the right coronary artery being most frequently affected (6). CT and TEE show the most proximal segment of the coronary arteries; thus, it can be verified whether the coronary ostium originates in the false lumen or whether coronary dissection is present.

Diagnostic strategy

TTE, a rapid procedure which can be performed at the patient's bedside, should be carried out in all patients admitted to the emergency room with thoracic pain since early diagnosis improves management and prognosis. Sensitivity and specificity of TTE in the diagnosis of AAS are acceptable with visualisation of the intimal flap in several segments of the aorta, mainly the aortic root

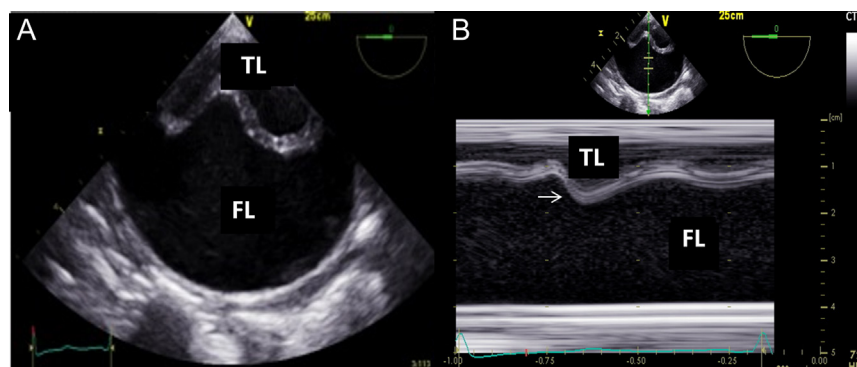


Figure 8

(A) Type B dissection by TEE; (B) M-mode TEE identifying movement of the intimal flap (arrow) with expansion of the true lumen (TL) in systole.

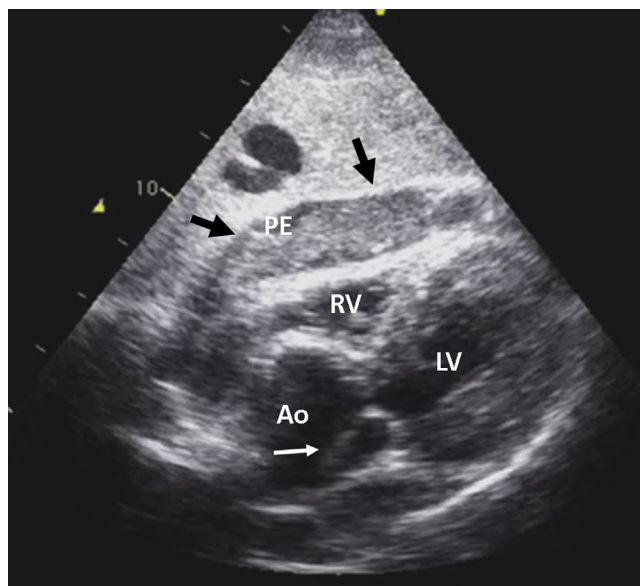


Figure 9
TTE showing an intimal flap in aortic root (white arrow) and anterior pericardial effusion (PE) (black arrows) with moderate compression of the right ventricle (RV). LV, left ventricle; LA, left atrium.

and abdominal aorta. In addition, contrast enhancement significantly improves TTE accuracy in the visualisation of the two lumina. Therefore, contrast enhancement is often useful in doubtful cases with no definitive intimal flap visualisation. It is important to note that when contrast TTE fails to show abnormalities, another imaging technique must be applied for AAS to be definitively ruled out, given that TTE is unable to visualise the entire aorta, IMH and PAU.

In unstable patients, if the diagnosis of type A dissection by TTE or contrast TTE is definitive, surgical treatment

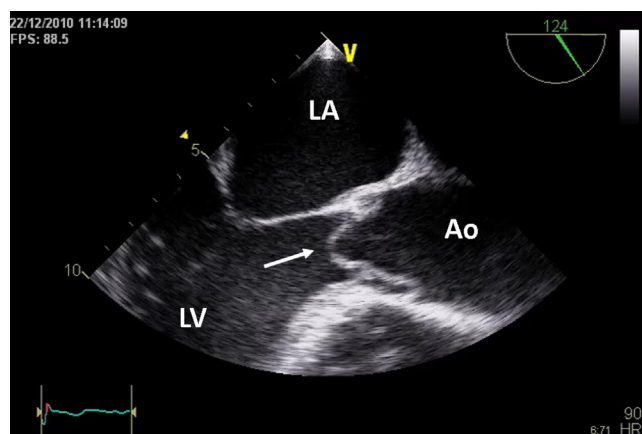


Figure 10
TEE showing the intimal flap prolapsing through the aortic valve (arrow) to the left ventricle (LV).

Table 2 Mechanisms of significant aortic regurgitation in aortic dissection.

- Dilation of the aortic annulus secondary to dilation of the ascending aorta.
- Rupture of the annular support and tear in the implantation of one of the valvular leaflets.
- Asymmetrical dissections, the haematoma itself may displace a sigmoid below coaptation level.
- Prolapse of the intima in the outward tract of the left ventricle through the valvular orifice.
- Previous aortic valve disease.

could be directly indicated, provided intraoperative TEE under anaesthesia is performed just prior to surgery to confirm the diagnosis. In the rest of cases, including when type B dissection is suspected, CT or TEE should be performed according to patients stability, complications and examiner experience. CT allows whole aorta visualisation, arterial branch involvement and periaortic haemorrhage, and TEE allows better information on entry tear location and size, false lumen flow and aortic regurgitation severity and mechanisms (Fig. 12) (6, 9).

Role of echocardiography in therapeutic management

Preoperative echocardiography provides the surgeon with important information for choosing the operative technique. In addition, perioperative echocardiographic imaging enables intraoperative monitoring and the detection of possible postoperative complications.

Type A AAS

Acute type A aortic dissection is a cardiovascular emergency with a high potential for death. Rapid surgical treatment is indicated to prevent fatal complications. Surgical treatment aims to exclude the primary tear by replacing the ascending aorta and aortic arch if necessary. Surgical mortality is high (15–35%), even in centres of excellence. In cases with significant aortic insufficiency, valvular repair or replacement should be considered.

TEE is fundamental for deciding on the surgical strategy in cases of aortic regurgitation (9). Mechanisms of aortic regurgitation related to aortic dissection are shown in Table 2 (Fig. 10). Ideally, aortic root repair with valve preservation should be considered using reimplantation techniques (David) or remodelling (Yacoub) (26). However, if the anatomical lesions of the root are significant, to avoid re-interventions it is better to perform complete replacement with the Bentall technique

Table 3 Usefulness of imaging techniques in the diagnosis of AAS.

Diagnostic performance	TTE	TEE	CT	MRI	Angio
Sensitivity in AD diagnosis	++	+++	+++	+++	++
Specificity in AD diagnosis	++	+++	+++	+++	+++
Ability to detect IMH	+	++	+++	+++	-
Ability to detect PAU	-	++	+++	+++	+++
SAA extension	+	++	+++	+++	++
Site of intimal tear	-	++	+++	+	++
Presence and mechanisms of aortic regurgitation	+++	+++	-	++	++
Coronary artery involvement	-	++	+++	+	+++
Left ventricular function	+++	+++	+	++	+++
Pericardial tamponade	+++	+++	++	++	-
Branch vessel involvement malperfusion	-	+	+++	++	+++

Bold indicates the best approach in clinical practice.

AD, aortic dissection; angio, angiography; CT, computed tomography; IMH, intramural haematoma; MRI, magnetic resonance imaging; PAU, penetrating aortic ulcer; TEE, transoesophageal echocardiogram; TTE, transthoracic echocardiogram.

that involves valved composite graft and reimplantation of the coronary arteries.

If the diameters of the proximal ascending aorta and aortic root are normal, without structural alterations of the aortic valve leaflets, a tubular graft is often anastomosed on the crest of the sinotubular junction. Replacement of the segment where the primary tear is located is essential to avoid long-term complications due to progressive dilation of the false lumen (27). If the descending aorta has to be treated, TEE is very useful for monitoring endovascular stent implantation.

Type B AAS

CT and TEE provide complementary information in the preoperative assessment of endovascular treatment. CT is more accurate in the measurement of aortic diameters and the distance between the ostium and arterial trunks.

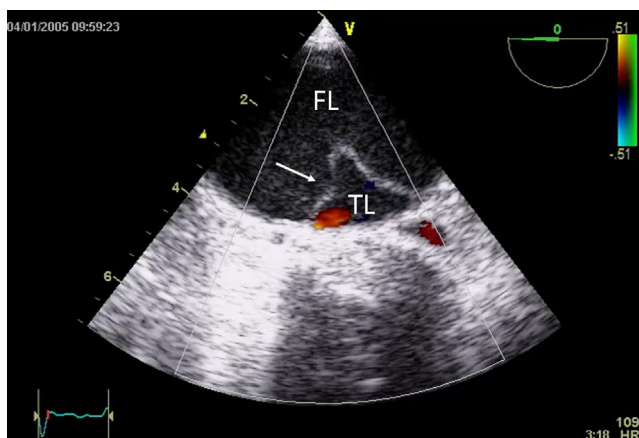


Figure 11
Severe compression of the TL (arrow) causing visceral and peripheral ischaemia.

TEE is useful in the operating theatre both before and after stent-graft deployment (28, 29). Intraoperative TEE is highly useful during endovascular therapy of the descending thoracic aorta, especially in type B aortic dissection, since it provides additional information to angiography/fluoroscopy for guiding correct stent-graft placement (30). Prior to stent-graft deployment, TEE is crucial for guidewire repositioning from the false to the true lumen and for correct guidewire entrance into elephant trunk prostheses in patients with previous aortic arch surgery (9). After stent-graft deployment, colour Doppler or contrast TEE may detect peri-stent leaks (Fig. 13 and Video 9), which can be promptly resolved by balloon dilation or further stent-graft implantations. Most of these leaks are not usually visible on angiography.

Video 9

Control after thoracic endovascular treatment by contrast TEE showing a lack of correct apposition of the distal part of the stent with the presence of a thrombus and a type I endoleak. View Video 9 at <http://movie-usa.glencoesoftware.com/video/10.1530/ERP-18-0058/video-9>.

Prognosis and follow-up

The short- and long-term prognosis of patients with successful initial treatment of acute aortic dissection are heterogeneous, with a reported event-free survival rate of 70% at 5 years and 50% at 10 years, respectively. TEE performed before discharge identifies several predictors of complications such as significant dilation of the arch or descending thoracic aorta (>45 mm), large entry tear (10 mm), compression of the true lumen and partial false

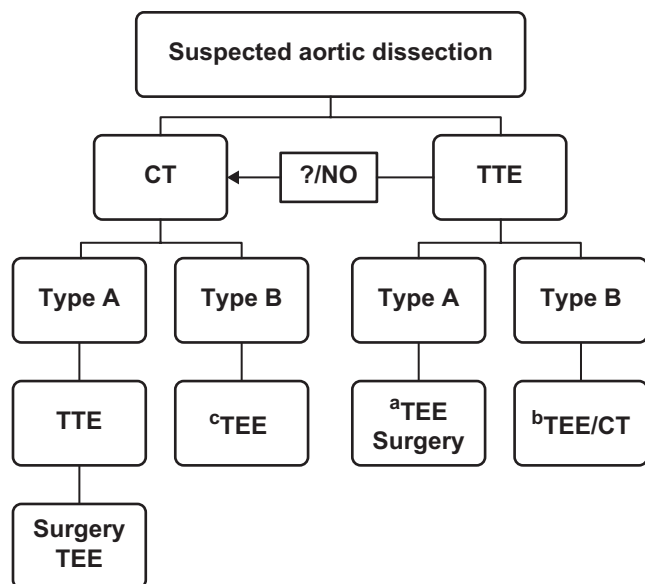


Figure 12

Diagnostic algorithm of acute aortic syndrome. ^aDefinitive diagnosis of type A dissection by TTE permits a haemodynamically unstable patient to be sent directly to the operating theatre, providing TEE confirm findings before surgery under general anaesthesia. If TTE is doubtful or negative a CT should be indicated. ^bCT vs TEE depending on local availability, patient haemodynamic or symptomatic status and physician experience. TEE is preferred when transferring the patient to the radiology department could compromise adequate control of haemodynamic instability. CT is better than TEE when visceral/peripheral ischaemia is suspected. ^cTEE is indicated at 1–3 days to complete false lumen dynamic information.

lumen thrombosis (31). This last predictor is particularly significant in the presence of a large entry tear and slow flow in false lumen due to the absence of distal discharge. However, TEE has a less important role in the follow-up of patients with aortic dissection since CT or MRI can visualise the whole aorta and measure the maximum aorta diameter with better accuracy than TEE.

IMH can heal or evolve to aneurysm formation or even dissection. In addition to maximum aortic diameter, some TEE information such as echolucent areas has been related to dissection and enlargement evolution. IMH regressed completely in 34% of patients, progressed to aortic dissection in 12%, aneurysm in 20% and pseudoaneurysm in 24% (32). Owing to their wide field of vision permitting identification of landmarks, MRI and CT are superior to TEE for defining this dynamic evolution.

Conclusions

Advances in TTE imaging quality and the use of contrast enhancement improve sensitivity and specificity in the

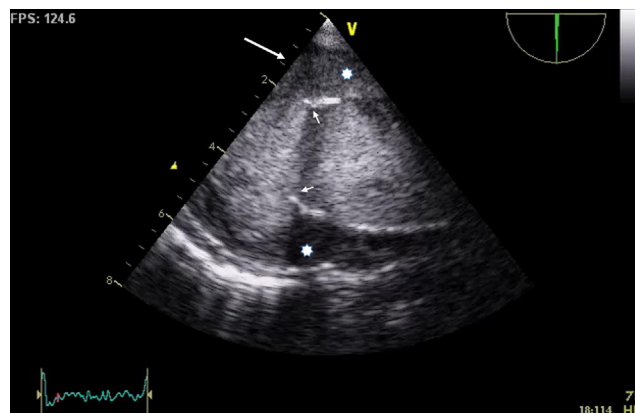


Figure 13

Control after thoracic endovascular treatment by contrast TEE showing a lack of correct apposition of the distal part of the stent with the presence of a thrombus (*) and a type I endoleak (large arrow). A small arrow marks the distal part of the stent.

diagnosis of aortic dissection. However, the low negative predictive value of TTE does not permit dissection to be ruled out, and further tests will be required if the exam is negative. The best imaging strategy for appropriately diagnosing and assessing AAS is the combination of CT and TTE. Currently, TEE tends to be carried out in the operating theatre immediately before surgical or endovascular therapy and in monitoring their results. TEE should define entry tear location, mechanisms and severity of aortic regurgitation and true lumen compression. In some specific complications, such as periaortic haematoma or involvement of the abdominal arterial trunks, additional information by CT is advisable.

TEE has predictor value by the identification of large entry tear, true lumen compression and partial thrombosis of the false lumen with slow flow and large entry tear. TEE is highly useful during aortic surgery and endovascular therapy.

Declaration of interest

The authors declare that there is no conflict of interest that could be perceived as prejudicing the impartiality of this review.

Funding

This review did not receive any specific grant from any funding agency in the public, commercial or not-for-profit sector.

Acknowledgments

The authors are indebted to Christine O'Hara for help with the English version of the manuscript.

References

- 1 Nienaber CA, Clough RE, Sakalihasan N, Suzuki T, Gibbs R, Mussa F, Jenkins MP, Thompson MM, Evangelista A, Yeh JS, *et al.* Aortic dissection. *Nature Reviews: Disease Primers* 2016 **2** 16071. (<https://doi.org/10.1038/nrdp.2016.71>)
- 2 Landenhed M, Engström G, Gottsäter A, Caulfield MP, Hedblad B, Newton-Cheh C, Melander O & Smith JG. Risk profiles for aortic dissection and ruptured or surgically treated aneurysms: a prospective cohort study. *Journal of the American Heart Association* 2015 **4** e001513. (<https://doi.org/10.1161/JAHA.114.001513>)
- 3 Tsai TT, Nienaber CA & Eagle KA. Acute aortic syndromes. *Circulation* 2005 **112** 3802–3813. (<https://doi.org/10.1161/CIRCULATIONAHA.105.534198>)
- 4 Evangelista Masip A. Progress in the acute aortic syndrome. *Revista Española de Cardiología* 2007 **60** 428–439. (<https://doi.org/10.1157/13101646>)
- 5 Erbel R, Aboyans V, Boileau C, Bossone E, Bartolomeo RD, Eggebrecht H, Evangelista A, Falk V, Frank H, Gaemperli O, *et al.* ESC guidelines on the diagnosis and treatment of aortic diseases: document covering acute and chronic aortic diseases of the thoracic and abdominal aorta of the adult. The Task Force for the Diagnosis and Treatment of Aortic Diseases of the European Society of Cardiology (ESC). *European Heart Journal* 2014 **35** 2873–2926. (<https://doi.org/10.1093/eurheartj/ehu281>)
- 6 Goldstein SA, Evangelista A, Abbara S, Arai A, Asch FM, Badano LP, Bolen MA, Connolly HM, Cuéllar-Calabria H, Czerny M, *et al.* Multimodality imaging of diseases of the thoracic aorta in adults: from the american society of echocardiography and the European association of cardiovascular imaging: endorsed by the society of cardiovascular computed tomography and society for cardiovascular magnetic resonance. *Journal of the American Society of Echocardiography* 2015 **28** 119–182. (<https://doi.org/10.1016/j.echo.2014.11.015>)
- 7 Evangelista A, Carro A, Moral S, Teixidó-Turà G, Rodríguez-Palomares JF, Cuéllar H & García-Dorado D. Imaging modalities for the early diagnosis of acute aortic syndrome. *Nature Reviews: Cardiology* 2013 **10** 477–486. (<https://doi.org/10.1038/nrcardio.2013.92>)
- 8 Bhave NM, Nienaber CA, Clough RE & Eagle KA. Multimodality imaging of thoracic aortic diseases in adults. *JACC: Cardiovascular Imaging* 2018 **11** 902–919. (<https://doi.org/10.1016/j.jcmg.2018.03.009>)
- 9 Evangelista A, Rabasa JM, Mosquera VX, Barros A, Fernández-Tarrio R, Calvo-Iglesias F, Ferrera C, Rozado J, López-Ayerbe J, Garrote C, *et al.* Diagnosis, management and mortality in acute aortic syndrome: results of the Spanish Registry of Acute Aortic Syndrome (RESA-II). *European Heart Journal: Acute Cardiovascular Care* 2016 **7** 602–608. (<https://doi.org/10.1177/2048872616682343>)
- 10 Evangelista A, Flachskampf FA, Erbel R, Antonini-Canterin F, Vlachopoulos C, Rocchi G, Sicari R, Nihoyannopoulos P, Zamorano J, European Association of Echocardiography, *et al.* Echocardiography in aortic diseases: EAE recommendations for clinical practice. *European Journal of Echocardiography* 2010 **11** 645–658. (<https://doi.org/10.1093/ejehocard/jeq056>)
- 11 Granato JE, Dee P & Gibson RS. Utility of echocardiography in suspected ascending aortic dissection. *American Journal of Cardiology* 1985 **56** 123–129. ([https://doi.org/10.1016/0002-9149\(85\)90579-X](https://doi.org/10.1016/0002-9149(85)90579-X))
- 12 Erbel R, Engberding R, Daniel W, Roetlandt J, Visser C & Rennollet H. Echocardiography in diagnosis of aortic dissection. *Lancet* 1989 **1** 457–461. ([https://doi.org/10.1016/S0140-6736\(89\)91364-0](https://doi.org/10.1016/S0140-6736(89)91364-0))
- 13 Evangelista A, Avegliano G, Aguilar R, Cuellar H, Igual A, González-Alujas T, Rodríguez-Palomares J, Mahía P & García-Dorado D. Impact of contrast-enhanced echocardiography on the diagnostic algorithm of acute aortic dissection. *European Heart Journal* 2010 **31** 472–479. (<https://doi.org/10.1093/eurheartj/ehp505>)
- 14 Shiga T, Wajima Z, Apfel CC, Inoue T & Ohe Y. Diagnostic accuracy of transesophageal echocardiography, helical computed tomography and magnetic resonance imaging for suspected thoracic aortic dissection. Systematic review and meta-analysis. *Archives of Internal Medicine* 2006 **166** 1350–1356. (<https://doi.org/10.1001/archinte.166.13.1350>)
- 15 Flachskampf FA, Wouters PF, Edvardsen T, Evangelista A, Habib G, Hoffman P, Hoffman R, Lancellotti P, Pepi M & Donal E. Recommendations for transoesophageal echocardiography: EACVI update 2014. *European Heart Journal: Cardiovascular Imaging* 2014 **15** 353–365. (<https://doi.org/10.1093/ehjci/jeu015>)
- 16 Meredith EL & Masani ND. Echocardiography in the emergency assessment of acute aortic syndromes. *European Journal of Echocardiography* 2009 **10** i31–i39. (<https://doi.org/10.1093/ejehocard/jen251>)
- 17 Pepi M, Campodonico J, Galli C, Tamborini G, Barbier P, Doria E, Maltagliati A, Alimento M & Spirito R. Rapid diagnosis and management of thoracic aortic dissection and intramural haematoma: a prospective study of advantages of multiplane vs biplane transoesophageal echocardiography. *European Journal of Echocardiography* 2000 **1** 72–79. (<https://doi.org/10.1053/euje.2000.0002>)
- 18 Evangelista A, Garcia del Castillo H, González-Alujas MT, Domínguez Oronoz R, Salas A & Soler-Soler J. Diagnosis of ascending aorta dissection by transesophageal echocardiography. Utility of M-mode in the detection of artifacts. *Journal of the American College of Cardiology* 1996 **27** 102–107. ([https://doi.org/10.1016/0735-1097\(95\)00414-9](https://doi.org/10.1016/0735-1097(95)00414-9))
- 19 Erbel R, Oelert H, Meyer J, Puth M, Mohr-Katoly S, Hausmann D, Daniel W, Maffei S, Caruso A, Covino FE, *et al.* Effect of medical and surgical therapy on aortic dissection evaluated by transesophageal echocardiography. Implications for prognosis and therapy. The European Cooperative Study Group on Echocardiography. *Circulation* 1993 **87** 1604–1615. (<https://doi.org/10.1161/01.CIR.87.5.1604>)
- 20 Vilacosta I, San Roman JA, Aragoncillo P, Ferriere's J, Mendez R, Graupner C, Battle E, Serrano J, Pinto A & Oyonarte JM. Penetrating atherosclerotic aortic ulcer: documentation by transesophageal echocardiography. *Journal of the American College of Cardiology* 1998 **32** 83–89. ([https://doi.org/10.1016/S0735-1097\(98\)00194-6](https://doi.org/10.1016/S0735-1097(98)00194-6))
- 21 Evangelista A, Salas A, Ribera A, Ferreira-González I, Cuellar H, Pineda V, González-Alujas T, Bijnsens B, Permanyer-Miralda G & García-Dorado D. Long-term outcome of aortic dissection with patent false lumen. *Circulation* 2012 **125** 3133–3141. (<https://doi.org/10.1161/CIRCULATIONAHA.111.090266>)
- 22 Evangelista A, Aguilar R, Cuellar H, Thomas M, Laynez A, Rodríguez-Palomares J, Mahía P, González-Alujas T & García-Dorado D. Usefulness of real-time three-dimensional transoesophageal echocardiography in the assessment of chronic aortic dissection. *European Journal of Echocardiography* 2011 **12** 272–277. (<https://doi.org/10.1093/ejehocard/jeq191>)
- 23 Mukherjee D, Evangelista A, Nienaber CA, Sechtem U, Suzuki T, Trimarchi S, Llovet A, Myrmet T, O'Gara PT, Fang J, *et al.* Implications of periaortic hematoma in patients with acute aortic dissection (from the International Registry of Acute Aortic Dissection). *American Journal of Cardiology* 2005 **96** 1734–1738. (<https://doi.org/10.1016/j.amjcard.2005.07.098>)
- 24 Movsowitz HD, Levine RA, Hilgenberg AD & Isselbacher EM. Transesophageal echocardiographic description of the mechanisms of aortic regurgitation in acute type A aortic dissection: implications for aortic valve repair. *Journal of the American College of Cardiology* 2000 **36** 884–890. ([https://doi.org/10.1016/S0735-1097\(00\)00766-X](https://doi.org/10.1016/S0735-1097(00)00766-X))
- 25 Orihashi K, Matsuura Y, Sueda T, Watari M, Okada K, Sugawara Y & Ishii O. Aortic arch branches are no longer a blind zone for transesophageal echocardiography: a new eye for aortic surgeons. *Journal of Thoracic and Cardiovascular Surgery* 2000 **120** 466–472. (<https://doi.org/10.1067/mtc.2000.108289>)

- 26 David TE & Feindel CM. An aortic valve-sparing operation for patients with aortic incompetence and aneurysm of the ascending aorta. *Journal of Thoracic and Cardiovascular Surgery* 1992 **103** 617–621.
- 27 Ehrlich MP, Ergin MA, McCullough JN, Lansman SL, Galla JD, Bodian CA, Apaydin A & Griep RB. Results of immediate surgical treatment of all acute type A dissections. *Circulation* 2000 **102** (Supplement III) 248–252. (https://doi.org/10.1161/01.CIR.102.suppl_3.III-248)
- 28 Cao P, De Rango P, Czerny M, Evangelista A, Fattori R, Nienaber C, Rousseau H & Schepens M. Systematic review of clinical outcomes in hybrid procedures for aortic arch dissections and other arch diseases. *Journal of Thoracic and Cardiovascular Surgery* 2012 **144** 1286–1300.e2. (<https://doi.org/10.1016/j.jtcvs.2012.06.013>)
- 29 Jonker FHW, Patel HJ, Upchurch GR, Williams DM, Montgomery DG, Gleason TG, Braverman AC, Sechtem U, Fattori R, Di Eusanio M, *et al.* Acute type B aortic dissection complicated by visceral ischemia. *Journal of Thoracic and Cardiovascular Surgery* 2015 **149** 1081.e1–1086.e1. (<https://doi.org/10.1016/j.jtcvs.2014.11.012>)
- 30 Nienaber CA, Kische S, Rousseau H, Eggebrecht H, Rehders TC, Kundt G, Glass A, Scheinert D, Czerny M, Kleinfeldt T, *et al.* Endovascular repair of Type B aortic dissection. Long-term results of the randomized investigation of stent grafts in Aortic Dissection Trial. *Circulation: Cardiovascular Interventions* 2013 **6** 407–416. (<https://doi.org/10.1161/CIRCINTERVENTIONS.113.000463>)
- 31 Tsai TT, Evangelista A, Nienaber CA, Myrmet T, Meinhardt G, Cooper JV, Smith DE, Suzuki T, Fattori R, Llovet A, *et al.* Partial thrombosis of the false lumen in patients with acute Type B aortic dissection. *New England Journal of Medicine* 2007 **357** 349–359. (<https://doi.org/10.1056/NEJMoa063232>)
- 32 Evangelista A, Dominguez R, Sebastia C, Salas A, Permanyer-Miralda G, Avegliano G, Elorz C, González-Alujas T, García Del Castillo H & Soler-Soler J. Long-term follow-up of aortic intramural hematoma. *Circulation* 2003 **108** 583–589. (<https://doi.org/10.1161/01.CIR.0000081776.49923.5A>)

Received in final form 25 February 2019

Accepted 6 March 2019