

Fatty Liver Caused by Glycogen Storage Disease Type IX: A Small Series of Cases in Children

Catarina Leuzinger Dias^a Inês Maio^b José Ricardo Brandão^c Edite Tomás^d
Esmeralda Martins^{a, e} Ermelinda Santos Silva^{a, b}

^aInstituto de Ciências Biomédicas Abel Salazar, Porto, Portugal; ^bGastroenterology Unit, Paediatrics Division, Child and Adolescent Department, Centro Materno-Infantil do Norte, Centro Hospitalar Universitário do Porto, Porto, Portugal; ^cPathologic Anatomy Division, Hospital Geral de Santo António, Centro Hospitalar Universitário do Porto, Porto, Portugal; ^dPaediatrics Division, Centro Hospital de Tâmega e Sousa, Porto, Portugal; ^eMetabolic Diseases Unit, Pediatrics Division, Child and Adolescent Department, Centro Materno-Infantil do Norte, Centro Hospitalar Universitário do Porto, Porto, Portugal

Keywords

Glycogen storage disease type IX · Non-alcoholic fatty liver disease · Steatohepatitis · Children

Abstract

Background: The prevalence of non-alcoholic fatty liver disease (NAFLD) affecting children and adolescents has increased dramatically in recent years. This increase is most probably related to the obesity pandemic and the high consumption of fructose. However, hepatic steatosis has some rare causes (e.g., some metabolic diseases) of which clinicians should be aware, particularly (but not only) when patients are non-obese or non-overweight. Differential diagnosis is notably important when pathologies have a specific treatment, such as for glycogenosis type IX (GSD-IX). **Aims:** To contribute to the knowledge on the differential diagnosis of NAFLD in paediatric age and to the clinical, biochemical, molecular, and histological characterisations of GSD-IX, a rare metabolic disorder. **Methods:** We performed a retrospective study of a small series of cases ($n = 3$) of GSD-IX diagnosed in the past 6 years, who were currently being followed up in the Units of Gastroenterology or Metabolic Dis-

eases of the Paediatric Division of our hospital and whose clinical presentation was NAFLD in paediatric age. **Results:** Three male patients were diagnosed with NAFLD before 2 years of age, 2 with confirmed diagnosis before the age of 3 years (alanine aminotransferase [ALT], liver ultrasound, and molecular analysis) and 1 whose diagnosis was confirmed at 11 years (ALT, liver ultrasound, liver histology, and molecular analysis). None of the patients were obese or overweight, and the daily fructose consumption was unknown. The outcome was favourable in all 3 patients, with follow-up periods ranging from 2 to 6 years. **Conclusion:** The decision on how far the search for secondary causes of NAFLD should go can be difficult, and GSD-IX must be on the list of possible causes.

© 2019 Sociedade Portuguesa de Gastrenterologia
Published by S. Karger AG, Basel

Fígado gordo causado por glicogenose tipo IX: Uma pequena série de casos em crianças

Palavras Chave

Glicogenose tipo IX · Fígado gordo não-alcoólico · Esteatohepatite · Crianças

Resumo

Introdução: A prevalência de fígado gordo não-alcoólico (NAFLD) afetando crianças e adolescentes, aumentou enormemente nos últimos anos. Este aumento está muito provavelmente relacionado com a pandemia de obesidade e o elevado consumo de frutose. No entanto, a esteatose hepática pode ser causada por algumas entidades raras (por exemplo, doenças metabólicas) para as quais os clínicos devem estar alertados, particularmente (mas não só) quando os doentes não são obesos nem têm excesso de peso. O diagnóstico diferencial é especialmente importante quando as patologias têm um tratamento específico, como é o caso da Glicogenose tipo IX (GSD-IX). **Objetivos:** Contribuir para o conhecimento dos diagnósticos diferenciais de NAFLD em idade pediátrica, e contribuir para a caracterização clínica, bioquímica, molecular e histológica da GSD-IX, uma doença metabólica rara. **Metodologia:** Estudo retrospectivo de uma pequena série de casos ($n = 3$) de GSD-IX diagnosticados nos últimos 6 anos, atualmente em seguimento nas Unidades de Gastrenterologia ou de Doenças Metabólicas do Serviço de Pediatria do nosso hospital, e cuja forma de apresentação clínica foi NALFLD em idade pediátrica. **Resultados:** Três doentes de sexo masculino foram diagnosticados com NAFLD antes dos 2 anos de idade, dois com diagnóstico confirmado antes dos 3 anos (alanina aminotransferase [ALT], ecografia hepática, e estudo molecular), e um cujo diagnóstico foi confirmado aos 11 anos (ALT, ecografia e histologia hepáticas, e estudo molecular). Nenhum dos doentes era obeso ou tinha excesso de peso, e o consumo diário de frutose era desconhecido. A evolução foi favorável nos três doentes, com um tempo de seguimento que variou entre 2 e 6 anos. **Conclusões:** A decisão sobre até onde a pesquisa de causas secundárias de NAFLD deve ir pode ser difícil, e a GSD-IX deve estar na lista de causas possíveis.

© 2018 Sociedade Portuguesa de Gastrenterologia
Published by S. Karger AG, Basel

Introduction

Non-alcoholic fatty liver disease (NAFLD) is currently the most common cause of fatty liver both in children and adults [1, 2] and is already the most common cause of chronic liver disease in children and adolescents [3]. Unfavourable lifestyles leading to obesity and a high-fructose diet may be the causes [4]. NAFLD is characterised by fatty infiltration of the liver (more than 5% of hepatocytes) in the absence of secondary causes, such as alcohol or drug consumption, infections, malnutrition, and ge-

netic/metabolic diseases. Therefore, the diagnosis of NAFLD is one of exclusion, and it is particularly important to exclude diseases with specific treatment [5]. Among the metabolic diseases to be considered are some glycogen storage diseases (GSDs) [6].

The GSDs are a group of inherited metabolic disorders that result from a defect in any of the various enzymes required for the synthesis or degradation of glycogen (Fig. 1). They are divided into two groups: GSDs with liver involvement (GSD-0, I, III, IV, VI, IX) or those associated with neuromuscular disease or both. The glycogen storage disease type IX (GSD-IX) is one of the most common forms of GSD (25% of cases; estimated frequency of 1/100,000) and result from a defect in an enzyme required for the degradation of glycogen. The enzymatic blockage leads to elevated pyruvate levels, which will be converted to lactate and acetylcoenzyme A. The latter is the starting point of the liver lipogenesis pathway with fatty acids and triglyceride synthesis. Although the main substrate accumulated in the target organs is glycogen, there may be a predominance of lipids, particularly in the liver [7, 8].

GSD-IX is both genetically and clinically heterogeneous. It is caused by deficiency in hepatic phosphorylase kinase (PhK), which is composed of four subunits (α , β , γ , and δ) with each one encoded by a different gene. GSD-IX subtypes are identified according to the affected subunit (GSD-IXa, GSD-IXb, GSD-IXc, and GSD-IXd) and exhibit different modes of transmission: X-linked recessive for the PHKA2 gene (subtype α , 75% of all GSD-IX) and autosomal recessive for the PHKB (subtype β) and PHKG2 (subtype γ) genes. The correlation genotype-phenotype is not clear but patients with PHKG2 mutations (GSD-IXc) have been reported to have the most severe phenotypes, and the most common subtype (GSD-IXa) has been characterised with a wide variability. Even if the majority of the patients have a benign course in the long term, with mild symptoms in childhood improving with age, some may progress to liver cirrhosis [9, 10] or develop liver adenomas and hepatocarcinoma in adulthood [11].

Case Report

We describe a small series of cases ($n = 3$) of GSD-IX, subtype α (GSD-IXa), diagnosed and managed in our outpatient clinic in the past 6 years and whose clinical presentation was fatty liver during paediatric age. Data were collected from clinical records. We analysed the clinical, analytical, histological, and molecular genetics parameters.

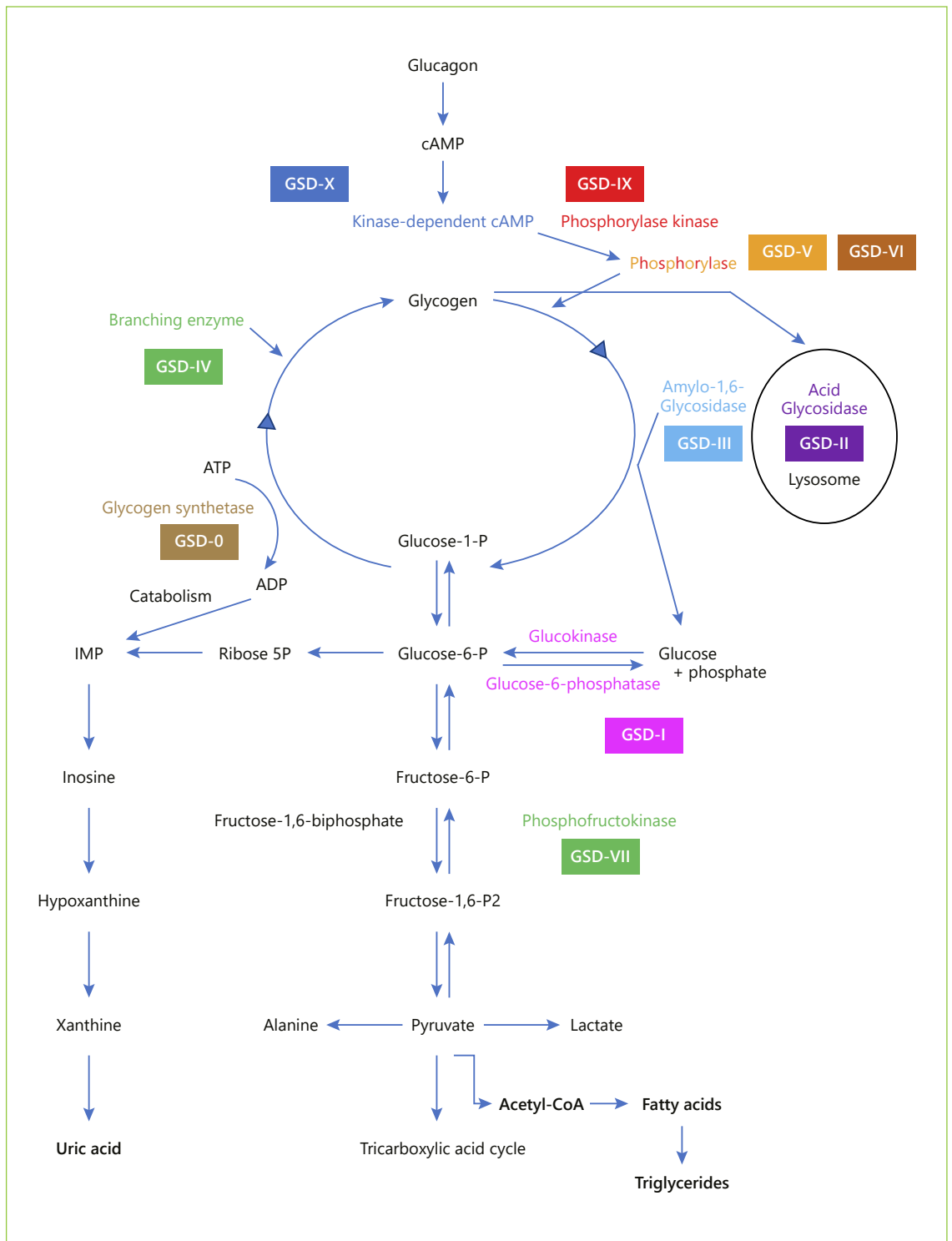


Fig. 1. Simplified scheme for the synthesis and degradation of glycogen and its enzymatic defects in several types of glycogenesis.

Table 1. Baseline clinical and analytical features of patients at admission to the referral centre

	Case 1	Case 2	Case 3	Reference values
<i>Clinical features</i>				
Sex	M	M	M	
Age (year of birth)	11 years (2000)	15 months (2010)	18 months (2013)	
Parental consanguinity	no	no	no	
Family history	negative	negative	negative	
Weight, kg/percentile	43.6/p50–85	11.0/p50–85	11.0/p50	
Length or height, cm/percentile	150.5/85	80/p50–85	82/p50	
BMI, kg/m ² /percentile	19.25/p50–85	17.2/p50–85	16.4/p50–85	
Hepatomegaly	no	yes (5 cm)	yes (3.5 cm)	
Splenomegaly	no	no	no	
<i>Biochemical parameters</i>				
Total bilirubin, mg/dL	0.28	0.16	0.26	0.20–1.00
Conjugated bilirubin, mg/dL	0.10	0.06	0.10	0.00–0.20
AST, IU/L	26	150	158	10–34
ALT, IU/L	16	219	60	10–44
γGT, IU/L	13	35	24	10–66
CPK, IU/L	136	95	NA	24–204
Glucose, mg/dL	77	66	74	70–105
Bicarbonates, mmol/L	17.5	17.9	15.4	22.0–29.0
Lactate, mmol/L	1.2	1.28	1.63	0.5–2.20
Uric acid, mg/dL	4.7	3.4	4.0	2.0–5.5
Total cholesterol, mg/dL	174	174	196	0–200
LDL cholesterol, mg/dL	94	116	136	0–130
HDL cholesterol, mg/dL	70	13	25	35–55
VLDL cholesterol, mg/dL	10	45	35	3–56
Triglycerides, mg/dL	50	227	174	40–160
<i>Other exams performed after</i>				
Hepatitis A, B, and C	negative	negative	negative	
CMV	IgG + IgM –	IgG – IgM –	IgG+ IgM –	
EBV	IgG + IgM –	IgG – IgM –	IgG + IgM –	
Serum alpha-1-antitrypsin, mg/dL	normal	normal	normal	
Serum ferritin, ng/mL	22	NA	NA	12.8–454
Transferrin saturation rate, %	10	NA	NA	15–45
Serum caeruloplasmin, mg/dL	26	NA	NA	16–36
24-h urinary copper, μmol/d	1.086	ND	ND	0.040–0.050
Copper in liver tissue, μg/g	24.82	ND	ND	<40
Sweat test	ND	normal	ND	
LAL activity (in leucocytes)	normal	ND	normal	
<i>Molecular studies</i>				
PhKA2 gene	mutation c.1054C>T (p.352X) exon 11 in hemizyosity	mutation c.892C>T (p.R298X) exon 9 in hemizyosity	mutation c.706G>T (p.E236*) exon 7 in hemizyosity	

BMI, body mass index; CMV, cytomegalovirus; EBV, Epstein-Barr virus; LAL, lysosomal acid lipase; NA, non-available; ND, not done.

Results

Case 1

A male infant, the first and only child of a healthy non-related couple, was born after a 40-week pregnancy, with

a weight of 3,080 g (p10–50) and a length of 48.5 cm (p10). At 18 months of age, he was hospitalised for bacterial pneumonia, and had hepatosplenomegaly and elevated transaminases (aspartate aminotransferase [AST]: 67 IU/L; alanine aminotransferase [ALT]: 53 IU/L). AST

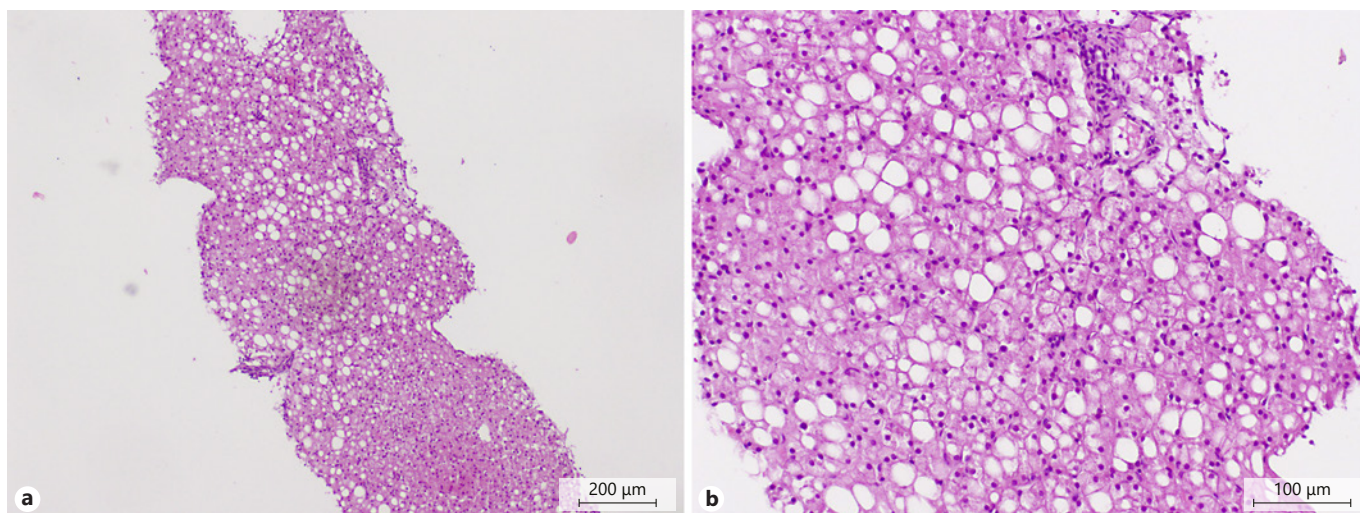


Fig. 2. a, b Liver histology in case 1 (at 11 years of age) showing macro- and micro-steatosis; hepatocytes with preserved morphology, and dimensions within normal ranges, without inflammatory infiltrate or fibrosis (H&E 100×).

and ALT eventually normalised, but hepatosplenomegaly persisted and led to admission to our outpatient clinic when he was 25 months old. Upon admission, complementary investigation was normal and included creatine phosphokinase, alpha-1-antitrypsin, hepatitis C virus antibodies, ceruloplasmin, serum ferritin, transferrin saturation, and serum lipids. Throughout the following years, spleen dimensions returned to normal, but the liver remained slightly enlarged with hyper-echogenicity. When the patient was 5 years old, the enzymatic activity in the leucocytes for glycogen storage disease type III (GSD-III) was normal. He was discharged by his attending physician, and performing annual abdominal ultrasound examinations was recommended.

By the age of 11 years, the abdominal ultrasound maintained a diffuse liver hyper-echogenicity, a pattern suggesting steatosis. The laboratory tests performed are presented in Table 1. Liver histology revealed macro- and micro-steatosis without inflammatory infiltrates or fibrosis (Fig. 2). The copper level in the liver tissue was normal. The molecular study confirmed the previously described mutation c.1054C>T (p. 352X) exon 11 in hemizyosity on the PHKA2 gene. Dietary measures were prescribed. Currently, at 18 years of age, the patient is asymptomatic; transaminases and other liver function tests remain normal; the liver maintains a pattern of steatosis in ultrasound with no adenomas; and the spleen is in the upper limit of normal size. His mother has normal ALT and has not undergone liver ultrasound or molecular study.

Case 2

A male infant, the second child of a healthy non-related couple, was born after a 37-week pregnancy with a weight of 2,750 g (p10–50) and a length of 46.5 cm (p10–50). He developed physiological jaundice that resolved within a week without phototherapy. During his first months, he had several episodes of wheezing, which were treated with montelukast and fluticasone in aerosol. At 11 months of age, during a wheezing episode, his transaminases (AST 158 IU/L; ALT 155 IU/L) and triglycerides (180 mg/dL) were elevated. At 15 months, he was admitted to our hospital for hepatomegaly (6 cm below the costal grid, smooth surface, and thin edge) and persistently elevated transaminases; abdominal ultrasound showed an enlarged and hyperechogenic liver with a steatosis pattern; the spleen was normal in size. The laboratory tests highlighted the slightly low fasting glycemia and bicarbonate, discreetly increased triglycerides and normal serum uric acid (Table 1). Cardiac evaluation was normal. Molecular study showed a previously described causal mutation on the PHKA2 gene [c.892C>T (p. R298X – exon 9)] with a hemizyosity pattern, confirming GSD-IXa. Dietary measures were prescribed. Two years later, hepatomegaly remained the same, although the transaminases normalised. Bicarbonates were slightly low and uric acid elevated. Currently, at 8 years old, he has no signs of progression to chronic liver disease or adenomas. His older sister (16 years old) is asymptomatic, with normal ALT and liver ultrasound. His mother has normal

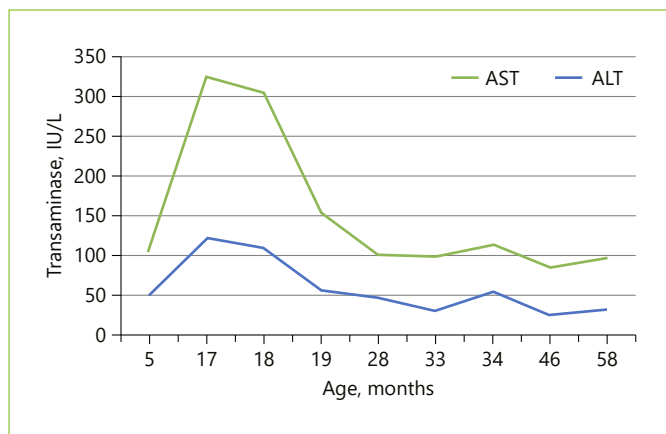


Fig. 3. Transaminases during follow-up in case 2.

ALT and has not undergone liver ultrasound or molecular study.

Case 3

A male infant, the first and only child of a healthy non-related couple, was born after a 39-week high-risk pregnancy due to placental displacement, with a weight of 3,300 g (p10–50) and a length of 51 cm (p50). In the first week, he developed jaundice (total bilirubin 17.3 mg/dl) that was treated with phototherapy. During the first 8 months, he had multiple infections: urinary tract infection caused by *Escherichia coli*, acute gastroenteritis, fever of undetermined origin, septicaemia caused by *Neisseria meningitidis*, upper respiratory infection caused by *Coronavirus*, cystitis caused by *Proteus mirabilis*, acute bronchiolitis followed by acute otitis media and an episode of bacteraemia of unknown origin. This overwhelming number of infections led to an investigation on humoral and the cellular immunity defects. A study performed out of context of infection excluded a complement deficiency and revealed normal serum immunoglobulins and immunophenotyping of lymphocytes. Throughout all these infectious episodes, the patient had palpable hepatomegaly and consistently elevated transaminases. At 18 months, abdominal ultrasound showed an enlarged liver with a pattern suggestive of steatosis and a normal-sized spleen. Table 1 presents the laboratory tests performed. One year later, molecular study confirmed the new and unrecognized mutation c.706G>T (p. E236*) exon 7 in hemizygoty in the PhKA2 gene, which leads to the production of a truncated protein. Diet measures were prescribed. Recurrent infections ceased after the first year of life. Currently, at 5 years of age, the patient is doing well, with

slight hepatomegaly (2 cm below the costal margin) and normal ALT (Fig. 3) and other liver function tests, and maintains a liver steatosis pattern on ultrasound. His mother is a carrier of heterozygosity, with normal ALT and liver pattern on ultrasound.

Discussion/Conclusion

NAFLD is one of the comorbidities of obesity, and its incidence is increasing dramatically. In addition, NAFLD has been associated with a certain dietary pattern, even without obesity or overweightness. Nonetheless, fatty liver can also be secondary to a large number of other entities [5]. Therefore, a child with fatty liver, regardless of the child's body mass index, is a challenging issue. The challenges are in the following order: when to suspect NAFLD, how to confirm the diagnosis, how to accomplish its staging, and how to rule out secondary causes.

None of our 3 patients was obese or overweight. However, we were not able to establish with reasonable accuracy their daily consumption of fructose. All 3 had hepatomegaly and elevated transaminases. For this reason, they underwent an abdominal ultrasound that confirmed an enlarged liver with hyper-echogenic pattern. These findings were suggestive of fatty liver.

ALT is currently the best screening method for fatty liver in children aged ≥ 10 years, with 88% sensitivity and 26% specificity for values > 2 times the normal value [12]. Liver ultrasound may show a suggestive pattern, although sensitivity is low. Liver histology is the gold standard for diagnosis, but it is too invasive as a screening method and has some limitations [13]. Magnetic resonance imaging (MRI) and spectroscopy (MRS) were validated and have showed to be accurate to detect and quantify hepatic steatosis in both adults [14] and children [15]. In fact, MRI-estimated proton density fat fraction is currently the most accurate test to quantify liver steatosis and can already be considered the gold standard [16]. However, it is usually unavailable and cannot be considered a 'non-invasive' procedure in young children because it requires sedation. For staging NAFLD, liver histology is still the best method for distinguishing NAFL from non-alcoholic steatohepatitis and for revealing the presence or absence of advanced fibrosis/cirrhosis, whereas some non-invasive methods are still in development [16].

Only 1 of our 3 patients (case 1) had fatty liver confirmed through histology at 11 years old, when his age and the increased level of 24-h urinary copper prompted us to investigate for Wilson's disease [17]. In the other 2

(cases 2 and 3), the diagnosis was presumptive and based on increased ALT and suggestive liver pattern in the ultrasound. The execution of MRI or MRS and liver biopsy was not considered because the benign clinical status of the patients did not justify the performance of invasive examinations. Moreover, the confirmation of a secondary cause that can be associated with lipids accumulation in the liver, such as GSD-IXa [7, 8], reinforces this presumption.

The guidelines are scarce concerning the ruling out of secondary causes of fatty liver. The North American Society of Pediatric Gastroenterology, Hepatology and Nutrition (NASPGHAN) guidelines for diagnosis and treatment of NAFLD (2017) do not provide enough orientation to a cost-benefit approach regarding who should be screened and when for each listed genetic/metabolic disease [13]. Furthermore, the GSD-IX is not even mentioned on their list as a secondary cause of fatty liver.

In this case series, we prioritised the exclusion of diseases with specific treatment and considered the patient's age. When the patient reached the age of 11 years, we searched for Wilson's disease, juvenile haemochromatosis, lysosomal acid lipase deficiency [18], and GSD types VI and IX. In patient 2, the hypothesis of drug hepatotoxicity by montelukast was considered, and it could have explained the increased transaminases but not the hepatomegaly and steatosis. In patient 3, we considered the hypothesis of congenital immunodeficiency with liver injury but were not able to confirm it. For the last 2 patients, lysosomal acid lipase deficiency was also considered but was tested only in patient 3. The diagnosis of GSD-IXa was confirmed by molecular study in all patients. All patients had pathogenic mutations of X-linked transmission in the PHKA2 gene. In case 2, a new mutation was found, which results in a premature stop codon. This new mutation was accepted as a causal mutation.

The clinical presentation of GSD-IXa is generally milder than that of other GSDs (and similar to GSD-VI), and its symptoms (hepatomegaly, growth retardation, elevated transaminases, hypertriglyceridaemia, and sometimes ketosis and hypotonia) typically improve with age, as it is usually asymptomatic in adulthood [19]. However, the genetic variants in PHKA2 have a broad phenotypic spectrum, including progression to cirrhosis [9, 10] and the development of hepatic adenomas [11] as well as less common phenotypes with kidney dysfunctions due to renal tubular acidosis and central nervous system involvement with delayed cognitive and speech abilities [20]. Thus far, our patients' clinical course has been benign, including the oldest.

The treatment includes dietary measures, namely, a high-protein diet (2–3 g/kg) with restriction of simple (added) sugars, avoidance of prolonged fasting, and supplementation of raw corn starch in the most severe phenotypes to maintain glucose concentrations and prevent ketosis overnight. In situations of greater stress, water infusion with maltodextrin (5 g/100 mL) is recommended. Rarely, hyperuricaemia or metabolic acidosis must be addressed. Untreated children may have undesirable repercussions, such as morning sickness, which affects school performance, and growth retardation, which causes psychological distress [21]. All our patients had low serum bicarbonates at presentation (later normalised), but none had hyperlactacidaemia or growth failure. Moreover, hyperuricaemia was not a problem in any of them.

Although the majority of patients are male, females may also exhibit symptoms, either in autosomal recessive forms or in the X-linked transmission subtype (GSD-IXa), because of the lyonisation phenomenon [22, 23]. Therefore, the mother, sisters, and daughters of male patients should be screened. In addition to the usual (milder) symptoms, women may have polycystic ovary syndrome. The transition to adulthood should include an adequate surveillance plan for cirrhosis, adenomas, and hepatocarcinoma.

In summary, making the decision of when and how to search for secondary causes of NAFLD can be challenging. To serve this purpose, more appropriate and cost-effective guidelines are needed. GSD-IX should be included in these guidelines because liver involvement can range in a spectrum from steatosis to steatohepatitis, with or without variable degrees of fibrosis/progression to liver cirrhosis. As several genetic/metabolic diseases can be among the secondary causes of NAFLD, the development of a next-generation sequencing panel, including all those diseases, can be a useful tool in the management of these patients [24].

Statement of Ethics

The authors have no ethical conflicts to disclose.

Disclosure Statement

The authors have no conflicts of interest to declare.

Author Contributions

Dr. Catarina Leuzinger Dias collected and analysed data and elaborated the manuscript, which is based on her Master thesis of medicine. Dr. Inês Maio, Dr. José Ricardo Brandão, Dr. Edite

Tomás, and Prof. Doutora Esmeralda Martins collected and analysed data and then evaluated and approved the manuscript. Dr. Ermelinda Santos Silva elaborated the study design, collected and analysed data, and evaluated and approved the manuscript.

References

- 1 Nobili V, Socha P. Pediatric nonalcoholic fatty liver disease: current thinking. *J Pediatr Gastroenterol Nutr.* 2018 Feb;66(2):188–92.
- 2 Mann JP, Valenti L, Scorletti E, Byrne CD, Nobili V. Nonalcoholic fatty liver disease in children. *Semin Liver Dis.* 2018 Feb;38(1):1–13.
- 3 Anderson EL, Howe LD, Jones HE, Higgins JP, Lawlor DA, Fraser A. The Prevalence of non-alcoholic fatty liver disease in children and adolescents: a systematic review and meta-analysis. *PLoS One.* 2015 Oct;10(10):e0140908.
- 4 Mosca A, Nobili V, De Vito R, Crudele A, Scorletti E, Villani A, et al. Serum uric acid concentrations and fructose consumption are independently associated with NASH in children and adolescents. *J Hepatol.* 2017 May;66(5):1031–6.
- 5 Kneeman JM, Misdraji J, Corey KE. Secondary causes of nonalcoholic fatty liver disease. *Therap Adv Gastroenterol.* 2012 May;5(3):199–207.
- 6 Chen MA, Weinstein DA. Glycogen storage diseases: diagnosis, treatment and outcome. *Transl Sci Rare Dis.* 2016;1(1):45–72.
- 7 Bali DS, Goldstein JL, Fredrickson K, Rehder C, Boney A, Austin S, et al. Variability of disease spectrum in children with liver phosphorylase kinase deficiency caused by mutations in the PHKG2 gene. *Mol Genet Metab.* 2014 Mar;111(3):309–13.
- 8 Bali DS, Goldstein JL, Fredrickson K, Austin S, Pendyal S, Rehder C, et al. Clinical and molecular variability in patients with PHKA2 variants and liver phosphorylase b kinase deficiency. *JIMD Rep.* 2017;37:63–72.
- 9 Johnson AO, Goldstein JL, Bali D. Glycogen storage disease type IX: novel PHKA2 missense mutation and cirrhosis. *J Pediatr Gastroenterol Nutr.* 2012 Jul;55(1):90–2.
- 10 Tsilianidis LA, Fiske LM, Siegel S, Lumpkin C, Hoyt K, Wasserstein M, et al. Aggressive therapy improves cirrhosis in glycogen storage disease type IX. *Mol Genet Metab.* 2013 Jun;109(2):179–82.
- 11 Roscher A, Patel J, Hewson S, Nagy L, Feigenbaum A, Kronick J, et al. The natural history of glycogen storage disease types VI and IX: long-term outcome from the largest metabolic center in Canada. *Mol Genet Metab.* 2014 Nov;113(3):171–6.
- 12 Schwimmer JB, Newton KP, Awai HI, Choi LJ, Garcia MA, Ellis LL, et al. Paediatric gastroenterology evaluation of overweight and obese children referred from primary care for suspected non-alcoholic fatty liver disease. *Aliment Pharmacol Ther.* 2013 Nov;38(10):1267–77.
- 13 Vos MB, Abrams SH, Barlow SE, Caprio S, Daniels SR, Kohli R, et al. NASPGHAN clinical practice guideline for the diagnosis and treatment of nonalcoholic fatty liver disease in children: recommendations from the expert committee on NAFLD (ECON) and the North American Society of Pediatric Gastroenterology, Hepatology and Nutrition (NASPGHAN). *J Pediatr Gastroenterol Nutr.* 2017 Feb;64(2):319–34.
- 14 Murphy P, Hooker J, Ang B, Wolfson T, Gamst A, Bydder M, et al. Associations between histologic features of nonalcoholic fatty liver disease (NAFLD) and quantitative diffusion-weighted MRI measurements in adults. *J Magn Reson Imaging.* 2015 Jun;41(6):1629–38.
- 15 Schwimmer JB, Middleton MS, Behling C, Newton KP, Awai HI, Paiz MN, et al. Magnetic resonance imaging and liver histology as biomarkers of hepatic steatosis in children with nonalcoholic fatty liver disease. *Hepatology.* 2015 Jun;61(6):1887–95.
- 16 Wong VW, Adams LA, de Lédinghen V, Wong GL, Sookoian S. Noninvasive biomarkers in NAFLD and NASH - current progress and future promise. *Nat Rev Gastroenterol Hepatol.* 2018 Aug;15(8):461–78.
- 17 Socha P, Janczyk W, Dhawan A, Baumann U, D’Antiga L, Tanner S, et al. Wilson’s Disease in Children: A Position Paper by the Hepatology Committee of the European Society for Paediatric Gastroenterology, Hepatology and Nutrition. *J Pediatr Gastroenterol Nutr.* 2018 Feb;66(2):334–44.
- 18 Himes RW, Barlow SE, Bove K, Quintanilla NM, Sheridan R, Kohli R. Lysosomal acid lipase deficiency unmasked in two children with nonalcoholic fatty liver disease. *Pediatrics.* 2016 Oct;138(4):e20160214.
- 19 Burda P, Hochuli M. Hepatic glycogen storage disorders: what have we learned in recent years? *Curr Opin Clin Nutr Metab Care.* 2015 Jul;18(4):415–21.
- 20 Burwinkel B, Amat L, Gray RG, Matsuo N, Muroya K, Narisawa K, et al. Variability of biochemical and clinical phenotype in X-linked liver glycogenosis with mutations in the phosphorylase kinase PHKA2 gene. *Hum Genet.* 1998 Apr;102(4):423–9.
- 21 Schippers HM, Smit GP, Rake JP, Visser G. Characteristic growth pattern in male X-linked phosphorylase-b kinase deficiency (GSD IX). *J Inherit Metab Dis.* 2003;26(1):43–7.
- 22 Cho SY, Lam CW, Tong SF, Siu WK. X-linked glycogen storage disease IXa manifested in a female carrier due to skewed X chromosome inactivation. *Clin Chim Acta.* 2013 Nov;426:75–8.
- 23 Blanco Sánchez T, Canedo Villarroya E, Martínez Zazo A, Pérez González B, Pedrón Giner C. Afectación hepática de paciente portadora en heterocigosis de una mutación en el gen PHKA2. *An Pediatr (Barc).* 2016;85:267–8. Spanish.
- 24 Nicastro E, D’Antiga L. Next generation sequencing in pediatric hepatology and liver transplantation. *Liver Transpl.* 2018 Feb;24(2):282–93.