

IMAGES AND VIDEOS

Severe mitral regurgitation due to atrial tachyarrhythmia: cure by DC cardioversion

Jack Parnell BSc BMBS, Mehak Tahir MD and Benoy N Shah MD MRCP FESC

Wessex Cardiac Centre, University Hospital Southampton, Southampton, UK

Correspondence should be addressed to B N Shah: benoy.shah@uhs.nhs.uk

Summary

A 62-year-old man admitted with palpitations had a 12-lead ECG that revealed atrial flutter with 2:1 AV block (rate 150bpm). Transthoracic echocardiography (TTE) revealed normal left ventricular size with impaired systolic function and severe MR (Fig. 1, panels A, B and Videos 1, 2). No MV prolapse was seen. The admitting doctor informed the patient that mitral valve surgery was the likely outcome. However, after senior review, the patient was commenced on rate-control, diuretic and anticoagulant medications. He was discharged and returned 6 weeks later for direct current cardioversion, which successfully restored sinus rhythm. TTE 2 months later showed normal LV function and trivial MR (Fig. 1, panel C and Video 3). This case highlights the importance of understanding the mechanism underlying MV dysfunction. The mitral annulus is a thin fibrofatty ring that geometrically resembles a parabola; its sphincteric contraction reduces MV annular area by ~25% during the cardiac cycle, facilitating normal leaflet coaptation (1). Consequently, the onset of atrial flutter – and loss of annular contraction – resulted in MR, and this was exacerbated by the rapid heart rate, which reduces the normal ventricular closing forces on the valve leading to incomplete mitral leaflet coaptation. Clinicians are reminded that atrial arrhythmias with high heart rates can disrupt normal MV function, producing MR which can be

resolved by treating the underlying abnormality (i.e. atrial arrhythmia) (2, 3) and thus avoiding unnecessary cardiac surgery.

Video 1

Apical four-chamber view, demonstrating incomplete leaflet coaptation between the anterior mitral valve leaflet (AMVL) and posterior mitral valve leaflet (PMVL). L, lateral wall; LA, left atrium; LV, left ventricle; S, septum. View Video 1 at <http://movie-usa.glencoesoftware.com/video/10.1530/ERP-19-0007/video-1>.

Video 2

Apical four-chamber view demonstrating severe mitral regurgitation on colour Doppler imaging (arrows). View Video 2 at <http://movie-usa.glencoesoftware.com/video/10.1530/ERP-19-0007/video-2>.

Video 3

Apical four-chamber view demonstrating trivial mitral regurgitation on colour Doppler imaging (arrows) after restoration of sinus rhythm. View Video 3 at <http://movie-usa.glencoesoftware.com/video/10.1530/ERP-19-0007/video-3>.

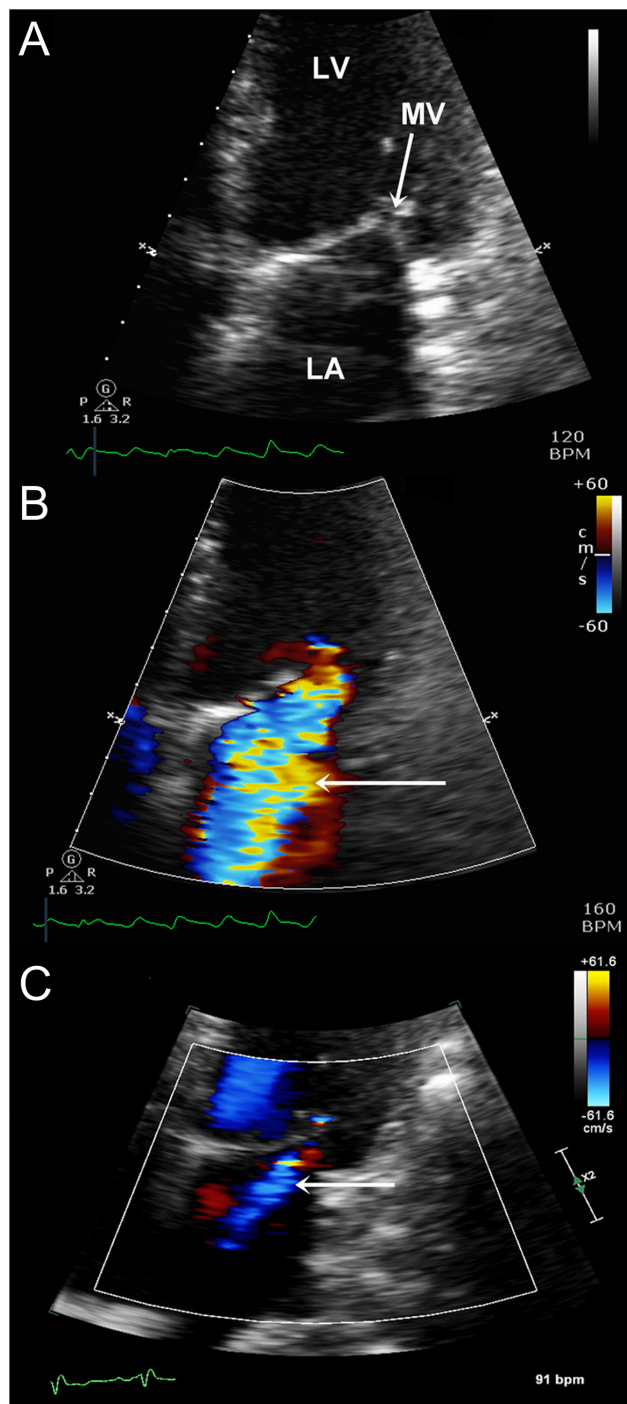


Figure 1

Incomplete mitral valve closure (white arrow) seen in the apical four-chamber view (panel A), which resulted in severe MR on colour Doppler imaging (panel B). Repeat echocardiography 2 months after successful restoration of sinus rhythm, there was only trivial residual MR (panel C).

Declaration of interest

The authors declare that there is no conflict of interest that could be perceived as prejudicing the impartiality of this article.

Funding

This work did not receive any specific grant from any funding agency in the public, commercial, or not-for-profit sector.

Patient consent

Written informed consent was obtained from the patient.

Author contribution statement

J P and M T wrote the first draft, which was revised by B N S. B N S is the guarantor for the article.

References

- 1 Levine RA, Hagège AA, Judge DP, Padala M, Dal-Bianco JP, Aikawa E, Beaudoin J, Bischoff J, Bouatia-Naji N, Bruneval P, *et al.* Mitral valve disease – morphology and mechanisms. *Nature Reviews Cardiology* 2015 **12** 689–710. (<https://doi.org/10.1038/nrcardio.2015.161>)
- 2 Gertz ZM, Raina A, Saghy L, Zado ES, Callans DJ, Marchlinski FE, Keane MG & Silvestry FE. Evidence of atrial functional mitral regurgitation due to atrial fibrillation: reversal with arrhythmia control. *Journal of the American College of Cardiology* 2011 **58** 1474–1481. (<https://doi.org/10.1016/j.jacc.2011.06.032>)
- 3 Kihara T, Gillinov AM, Takasaki K, Fukuda S, Song JM, Shiota M & Shiota T. Mitral regurgitation associated with mitral annular dilation in patients with lone atrial fibrillation: an echocardiographic study. *Echocardiography* 2009 **26** 885–889. (<https://doi.org/10.1111/j.1540-8175.2009.00904.x>)

Received in final form 4 March 2019

Accepted 20 March 2019

Accepted Manuscript published online 20 March 2019