

This article is licensed under the Creative Commons Attribution-NonCommercial 4.0 International License (CC BY-NC) (<http://www.karger.com/Services/OpenAccessLicense>). Usage and distribution for commercial purposes requires written permission.

## Case Report

# Corneal Perforation after Nd:YAG Capsulotomy: A Case Report and Literature Review

Maroun Khreish Rana Hanna Liron Berkovitz Beatrice Tiosano

Department of Ophthalmology, Hillel-Yaffe Medical Center, Hadera, Israel

## Keywords

Capsulotomy · Corneal perforation · YAG laser · Systemic sclerosis

## Abstract

**Background:** Nd:YAG capsulotomy is the treatment of choice for posterior capsular opacification after cataract surgery. We report a case of corneal perforation following Nd:YAG capsulotomy in a patient with systemic scleroderma. **Case Presentation:** A 69-year-old woman presented with acute onset of blurred vision 2 weeks following Nd:YAG laser capsulotomy for posterior subcapsular opacification. On examination, her best-corrected visual acuity was 1/120, and bio-microscopy revealed a central full-thickness corneal laceration. Conservative treatment consisted of topical ocular antibiotics, cycloplegics, hypotensive drops and a soft therapeutic contact lens. Her final visual acuity improved to 6/18 with resolution of the corneal laceration. **Conclusion:** The possibility of corneal perforation after Nd-YAG capsulotomy in patients with systemic scleroderma and connective tissue disease should be borne in mind when treating such patients.

© 2019 The Author(s)  
Published by S. Karger AG, Basel

## Background

Cataract is responsible of more than one-half of cases of low vision worldwide. It is reported to develop in 18% of people between the ages of 65 and 74 years and in 46% of people between 75 and 85 years. Cataract surgery is the most commonly performed ocular surgery

worldwide [1, 2]. The most frequent postoperative complication of cataract surgery is posterior capsule opacification (PCO), with a reported incidence of 20.7% at 2 years and 28.5% at 5 years after the procedure. PCO develops as remaining lens epithelial cells proliferate and migrate into the space between the posterior surface of the intraocular lens (IOL) and the posterior capsule [3, 4]. Yag laser capsulotomy is the treatment of choice for PCO. The complications of YAG laser capsulotomy include: damage to the IOL, increased intraocular pressure (IOP), retinal hemorrhage, iritis, vitreous prolapse, corneal injury, vitritis, pupil blockage, hyphema, cystoid macular edema, retinal detachment, IOL dislocation and exacerbation of endophthalmitis [5].

Systemic sclerosis (SSc) is a connective tissue disease of unknown etiology with multi-organ involvement and a wide range of clinical manifestations [6]. Ocular involvements of SSc include: telangiectasia and dermal sclerosis of the eyelids, a tear deficiency of varying severity, infection, telangiectasia, sludging of the blood column in conjunctival vessels, and punctate defects of the iris pigment epithelium. No evidence of corneal involvement has been mentioned in previously published studies [7].

Corneal perforation during or after Nd:YAG laser capsulotomy is a rare complication, with only one case of corneal perforation during Nd:YAG laser capsulotomy having been reported [8]. Here, we describe what we believe to be the first report of corneal perforation 2 weeks following Nd:YAG laser capsulotomy.

### Case Presentation

A 69-year-old woman presented to our hospital with a gradual reduction in vision of the left eye 1 year after uncomplicated cataract surgery of that eye. On examination, her best-corrected visual acuity (BCVA) was 6/18 in the right eye and 6/24 in the left eye, and the slit-lamp examination (SLE) revealed a very mild ocular surface disease in both eyes and PCO in the left eye. The patient was not using any topical or systemic treatment.

Nd:YAG laser capsulotomy using a Zeiss Visulas YAG II 532 s device (total energy of 30–35 mJ, and the inverted D method) was performed on the left eye. The procedure was done without the use of a contact lens.

Following the non-eventful procedure, an optically clear visual axis with a clear cornea was observed, and the IOP was 17 mm Hg. Standard treatment with dexamethasone drops four times a day for 4 days was initiated, she was referred for follow-up 1 week later.

The patient returned to our clinic 2 weeks later complaining of pain and decreased vision in her left eye. Upon further questioning, she reported using topical steroids liberally to relieve pain. On examination, her BCVA was 1/120 in the left eye, and the SLE revealed a central full-thickness corneal perforation measuring 0.5 × 0.5 mm with a shallow anterior chamber and a positive Seidel test. Anterior segment optical coherence tomography demonstrated a disrupted corneal perforation with a full-thickness central gap (Fig. 1). We prescribed topical ocular antibiotics, cycloplegics, and hypotensive medications and bandaged the eye with a soft therapeutic contact lens. At the follow-up visit 1 week later, her BCVA had improved to 6/36 in the left eye. The SLE revealed that the corneal perforation had decreased in size and that the anterior chamber had deepened. A passive positive Seidel sign was still present. She received additional treatment with oral doxycycline, vitamin C and topical ocular serum drops. At the final follow-up 12 weeks after her left eye capsulotomy, the patient was pain free, her BCVA was 6/18, and she had a paracentral corneal scar, a normal depth anterior chamber and a negative Seidel sign. A repeated anterior segment optical coherence tomography dem-

onstrated a deep stromal scar with bridging continuous superficial stromal and epithelial layers (Fig. 2).

## Discussion

Nd:YAG laser posterior capsulotomy is a safe procedure for treating PCO, although it is not free from complications, such as elevated IOP, cystoid macular edema and retinal detachment. Our literature review failed to discover any prior report on late corneal perforation as a complication of Nd:YAG laser treatment. A possible explanation for this unusual sequela is the patient's excessive use of topical steroids which may have damaged the corneal epithelium's regenerative capabilities which, in turn, might have led to the development of an ulcer and even perforation. Indeed, over 3 decades ago, Petroutsos et al. [9] suggested that topical steroids can reduce epithelial healing and damage the cornea. An additional contributing mechanism to our patient's corneal perforation could have been the collateral damage due to a possible focusing error. Since the procedure had been performed without the use of a magnifying lens, while taking into consideration the lack of experience of the operator, the cornea might have been accidentally struck and the force of the resulting "shock wave" could have led to its perforation, as had been demonstrated in a rabbit model [10].

SSc is an autoimmune connective tissue disease characterized by thickening of the skin as a result of the accumulation of collagen and of injuries to small arteries. The pathophysiology remains unknown. One theory states that antigens from the human leukocyte antigen (HLA) histocompatibility complex, including HLA-B8, HLA-DR5, HLA-DR3, HLA-DR52, and HLA-DQB2, are involved. Horie et al. [11] reported a case of a woman with progressive SSc who developed bilateral peripheral corneal ulcer and corneal perforation in one eye. HLA-DR protein-positive monocytes that infiltrated subepithelial tissues as well as T cell-positive reactions were documented in that case. Our patient was positive for SSc, which together with the above-cited possible associations with SSc, might have synergistically contributed to the development of the corneal perforation.

## Conclusion

Nd:YAG laser capsulotomy is an important tool which can be applied in an outpatient setting to treat PCO after cataract surgery. We suggest raising the level of awareness that connective tissue disease can affect the corneal structure. In addition, the use of topical steroids after the procedure and its potential side effects, especially in patients with connective tissue and ocular surface disease, should be considered carefully. For patients with SSc who are candidates for laser capsulotomy, it is especially important to bear in mind the ocular anatomy and the importance of careful aiming of the laser beam and to focus the laser pulses on the posterior lenticular capsule. Our patient's corneal perforation following the Nd:YAG laser procedure responded well to conservative treatment, and the cornea of the operated eye has remained intact.

## Acknowledgment

We thank Esther Eshkol, MA, for editorial assistance.

### Statement of Ethics

This study protocol adheres to the tenets of the Declaration of Helsinki and was approved by the local institutional review board. Written informed consent was obtained from the patient for publication of this case report and the accompanying images. A copy of the written consent is available for review by the editor of this journal.

### Disclosure Statement

The authors have no conflicts of interest to declare.

### Funding Sources

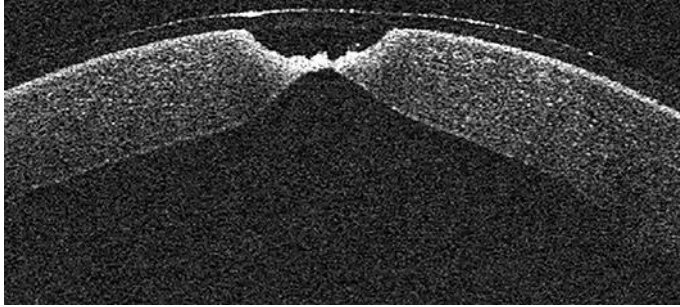
Internal departmental resources.

### Author Contributions


*M.K.* and *R.H.*: equal contribution of patient management, conception of the paper, data analysis and interpretation manuscript drafting and literature search. *L.B.*: co-writing of the manuscript, literature search. *B.T.*: design of the paper, co-writing of the manuscript, literature search, manuscript editing and revision as well as final approval. All authors read and approved the final manuscript.

### References

- Congdon N, Vingerling JR, Klein BE, West S, Friedman DS, Kempen J, et al.; Eye Diseases Prevalence Research Group. Prevalence of cataract and pseudophakia/aphakia among adults in the United States. *Arch Ophthalmol*. 2004 Apr;122(4):487–94.
- Billotte C, Berdeaux G. Adverse clinical consequences of neodymium:YAG laser treatment of posterior capsule opacification. *J Cataract Refract Surg*. 2004 Oct;30(10):2064–71.
- Powe NR, Schein OD, Gieser SC, Tielsch JM, Luthra R, Javitt J, et al.; Cataract Patient Outcome Research Team. Synthesis of the literature on visual acuity and complications following cataract extraction with intraocular lens implantation. *Arch Ophthalmol*. 1994 Feb;112(2):239–52.
- Nakazawa M, Ohtsuki K. Apparent accommodation in pseudophakic eyes after implantation of posterior chamber intraocular lenses. *Am J Ophthalmol*. 1983 Oct;96(4):435–8.
- Karahan E, Er D, Kaynak S. An overview of Nd:YAG laser capsulotomy. *Med Hypothesis Discov Innov Ophthalmol*. 2014;3(2):45–50.
- Pattanaik D, Brown M, Postlethwaite AE. Vascular involvement in systemic sclerosis (scleroderma). *J Inflamm Res*. 2011;4:105–25.
- West RH, Barnett AJ. Ocular involvement in scleroderma. *Br J Ophthalmol*. 1979 Dec;63(12):845–7.
- Türkcü FM, Yüksel H, Cingü K, Cınar Y, Murat M, Çaça I. Corneal perforation during Nd:YAG laser capsulotomy: a case report. *Int Ophthalmol*. 2013 Feb;33(1):99–101.
- Petroutsos G, Guimaraes R, Giraud JP, Pouliquen Y. Corticosteroids and corneal epithelial wound healing. *Br J Ophthalmol*. 1982 Nov;66(11):705–8.
- Vaikoussis E, Bisogiannis Z, Margaritis L. Corneal endothelial damage after Nd:YAG laser anterior capsulotomy. An experimental study on rabbits. *Doc Ophthalmol*. 1993;83(4):279–86.
- Horie K, Nishi M, Sawa M, Mochizuki M. [A case of peripheral corneal ulcer accompanied by progressive systemic sclerosis]. *Nippon Ganka Gakkai Zasshi*. 1992;96:922–9.



**Fig. 1.** Anterior chamber optical coherence tomography of the left eye 2 weeks after it underwent YAG laser capsulotomy.



**Fig. 2.** Anterior chamber optical coherence tomography of the left eye in Figure 1, 12 weeks after corneal perforation.