



Volume 2 | Issue 4


Article 8

2016

Retrograde Pedal Access For Revascularization Of Infrapopliteal Arterial Occlusive Disease In Critical Limb Ischemia (CLI) Patients As A Primary Approach.

Ahmed Amro, Alaa Gabi, Shahed Elhamdani, Haytham Aljoudi, and Mehیار El-Hamdani

Follow this and additional works at: <https://mds.marshall.edu/mjm>

 Part of the [Cardiology Commons](#), [Other Analytical, Diagnostic and Therapeutic Techniques and Equipment Commons](#), [Surgical Procedures, Operative Commons](#), and the [Therapeutics Commons](#)



This work is licensed under a [Creative Commons Attribution 4.0 License](#).

Recommended Citation

Amro, Ahmed; Gabi, Alaa; Elhamdani, Shahed; Aljoudi, Haytham; and El-Hamdani, Mehیار (2016) "Retrograde Pedal Access For Revascularization Of Infrapopliteal Arterial Occlusive Disease In Critical Limb Ischemia (CLI) Patients As A Primary Approach.," *Marshall Journal of Medicine*: Vol. 2: Iss. 4, Article 8.

DOI: <http://dx.doi.org/10.18590/mjm.2016.vol2.iss4.8>

Available at: <https://mds.marshall.edu/mjm/vol2/iss4/8>

DOI: <http://dx.doi.org/10.18590/mjm.2016.vol2.iss4.8>

Open Access |

References with DOI

1. Nehler MR, Duval S, Diao L, Annex BH, Hiatt WR, Rogers K, et al. Epidemiology of peripheral arterial disease and critical limb ischemia in an insured national population. *J Vasc Surg.* 2014;60(3):686-95 e2. <http://dx.doi.org/10.1016/j.jvs.2014.03.290>
2. Second European Consensus Document on chronic critical leg ischemia. *Eur J Vasc Surg.* 1992;6 Suppl A:1-32.
3. Fernandez N, McEnaney R, Marone LK, Rhee RY, Leers S, Makaroun M, et al. Predictors of failure and success of tibial interventions for critical limb ischemia. *J Vasc Surg.* 2010;52(4):834-42. <http://dx.doi.org/10.1016/j.jvs.2010.04.070>
4. Gray BH, Diaz-Sandoval LJ, Dieter RS, Jaff MR, White CJ. SCAI expert consensus statement for infrapopliteal arterial intervention appropriate use. *Catheter Cardiovasc Interv.* 2014;84(4):539-45. <http://dx.doi.org/10.1002/ccd.25395>
5. Gray BH, Grant AA, Kalbaugh CA, Blackhurst DW, Langan EM, 3rd, Taylor SA, et al. The impact of isolated tibial disease on outcomes in the critical limb ischemic population. *Ann Vasc Surg.* 2010;24(3):349-59. <http://dx.doi.org/10.1016/j.avsg.2009.07.034>
6. Dobrow EM, Mittleider D. Retrograde tibiopedal access for the treatment of critical limb ischemia. *Tech Vasc Interv Radiol.* 2015;18(2):66-75. <http://dx.doi.org/10.1053/j.tvir.2015.04.003>
7. Aboyans V, Desormais I, Lacroix P, Salazar J, Criqui MH, Laskar M. The general prognosis of patients with peripheral arterial disease differs according to the disease localization. *Journal of the American College of Cardiology.* 2010;55(9):898-903. <http://dx.doi.org/10.1016/j.jacc.2009.09.055>
8. Sadek M, Ellozy SH, Turnbull IC, Lookstein RA, Marin ML, Faries PL. Improved outcomes are associated with multilevel endovascular intervention involving the tibial vessels compared with isolated tibial intervention. *J Vasc Surg.* 2009;49(3):638-43; discussion 43-4. <http://dx.doi.org/10.1016/j.jvs.2008.10.021>
9. Fernandez N, McEnaney R, Marone LK, Rhee RY, Leers S, Makaroun M, et al. Multilevel versus isolated endovascular tibial interventions for critical limb ischemia. *J Vasc Surg.* 2011;54(3):722-9. <http://dx.doi.org/10.1016/j.jvs.2011.03.232>
10. Mustapha JA, Diaz-Sandoval LJ. Balloon angioplasty in tibioperoneal interventions for patients with critical limb ischemia. *Tech Vasc Interv Radiol.* 2014;17(3):183-96. <http://dx.doi.org/10.1053/j.tvir.2014.08.007>
11. Spinosa DJ, Leung DA, Harthun NL, Cage DL, Fritz Angle J, Hagspiel KD, et al. Simultaneous antegrade and retrograde access for subintimal recanalization of peripheral arterial occlusion. *J Vasc Interv Radiol.* 2003;14(11):1449-54. <http://dx.doi.org/10.1097/01.rvi.0000096764.74047.21>
12. Botti CF, Jr., Ansel GM, Silver MJ, Barker BJ, South S. Percutaneous retrograde tibial access in limb salvage. *J Endovasc Ther.* 2003;10(3):614-8. <http://dx.doi.org/10.1177/152660280301000330>
13. El-Sayed H, Bennett ME, Loh TM, Davies MG. Retrograde pedal access and endovascular revascularization: a safe and effective technique for high-risk patients with complex tibial vessel disease. *Ann Vasc Surg.* 2016;31:91-8. <http://dx.doi.org/10.1016/j.avsg.2015.09.015>
14. Walker CM, Mustapha J, Zeller T, Schmidt A, Montero-Baker M, Nanjundappa A, et al. Tibiopedal access for crossing of infrainguinal artery occlusions: a prospective multicenter observational study. *J*

Endovasc Ther. 2016. <http://dx.doi.org/10.1177/1526602816664768>

15. Montero-Baker M, Schmidt A, Braunlich S, Ulrich M, Thieme M, Biamino G, et al. Retrograde approach for complex popliteal and tibioperoneal occlusions. *J Endovasc Ther.* 2008;15(5):594-604. <http://dx.doi.org/10.1583/08-2440.1>

16. Bazan HA, Le L, Donovan M, Sidhom T, Smith TA, Sternbergh WC, 3rd. Retrograde pedal access for patients with critical limb ischemia. *J Vasc Surg.* 2014;60(2):375-81. <http://dx.doi.org/10.1016/j.jvs.2014.02.038>

17. Kwan TW, Shah S, Amoroso N, Diwan R, Makker P, Ratcliffe JA, et al. Feasibility and safety of routine transpedal arterial access for treatment of peripheral artery disease. *J Invasive Cardiol.* 2015;27(7):327-30.

Retrograde pedal access for revascularization of infrapopliteal arterial occlusive disease in critical limb ischemia (CLI) patients as a primary approach

Ahmed Amro, MD¹, Shahed Elhamdani, MS2², Alaa Gabi, MD³, Haytham Aljouidi, MD³, Mehیار El-Hamdani, MD, FACC, FSCAI³

Author Affiliations:

1. Department of Internal Medicine, Marshall University Joan C. Edwards School of Medicine, Huntington, West Virginia
2. Joan C Edwards School of Medicine, Marshall University, Huntington, West Virginia
3. Department of Cardiovascular Services, Marshall University Joan C. Edwards School of Medicine, Huntington, West Virginia

The authors have no financial disclosures to declare and no conflicts of interest to report.

Corresponding Author

Ahmed Amro, MD
Joan C. Edwards School of Medicine
Marshall University
Huntington, West Virginia
Email: amro@marshall.edu

Abstract

Introduction:

We are presenting three cases (out of similar several cases) where tibio-pedal approach was performed as an initial primary approach for limb salvage in patients with CLI secondary to Infra-popliteal (IP) disease. We consider this approach to be a necessary evolution in endovascular intervention.

Discussion:

Retrograde pedal access is safe and feasible, with high technical success rate and a relatively low procedural complication rate, with low 30 days mortality and low rate of major adverse cardiac events. Freedom from major adverse limb events and limb salvage are both high at 1 year follow up. It allows quick therapy and short procedure time with less observation time in the hospital. A retrograde approach utilizing pedal access improves the crossing success of lesions as well as facilitates the use of some atherectomy devices to remove large plaque burden and modify the compliance of severely calcified infra-popliteal vessels. Using the retrograde approach will minimize the classic complications of the antegrade femoral approach.

Conclusion:

Retrograde tibio-pedal arterial access, as an initial primary approach for endovascular intervention in CLI patients confined to IP vessels, is an effective, safe, and feasible approach with a high technical success rate and a relatively low procedural complication rate.

Keywords

CLI, Critical limb ischemia, PAD, pedal access, retrograde access, Rutherford stage IV-VI, retrograde as primary approach, limb salvage

Introduction

Retrograde tibio-pedal endovascular intervention is being used in conjunction with and as an alternative approach to conventional antegrade femoral intervention for limb salvage in CLI patients (Rutherford class IV-VI).

We are presenting three cases (out of similar several cases) where tibio-pedal approach was performed as an initial primary approach for limb salvage in patients with CLI secondary to Infra-popliteal (IP) disease. We consider this approach to be a necessary evolution in endovascular intervention.

Case Description

Case 1: A 70-year-old female patient with history of diabetes mellitus, hypertension, hyperlipidemia and peripheral artery disease status post superficial femoral artery intervention presented with severe leg pain at rest, an unhealed foot ulcer and Rutherford classification VI. Her pre-intervention angiogram showed a severe anterior tibial artery stenosis (80-90%) as shown in Figure 1. Subsequent retrograde anterior tibial access, rotational atherectomy, and angioplasty were performed as shown in Figure 2, 3 and 4.

Figure 1

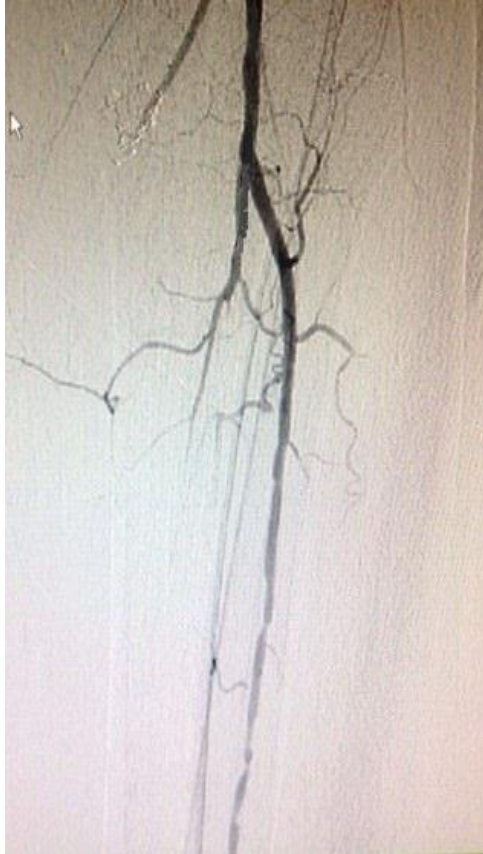

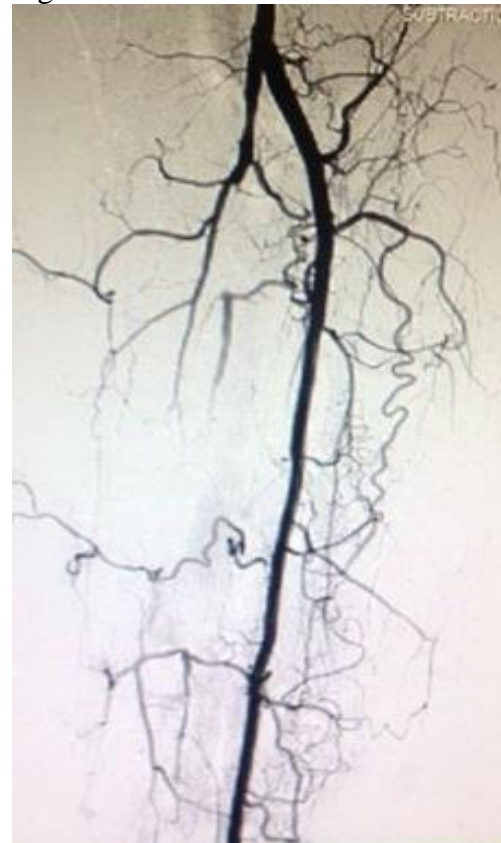
Figure 2

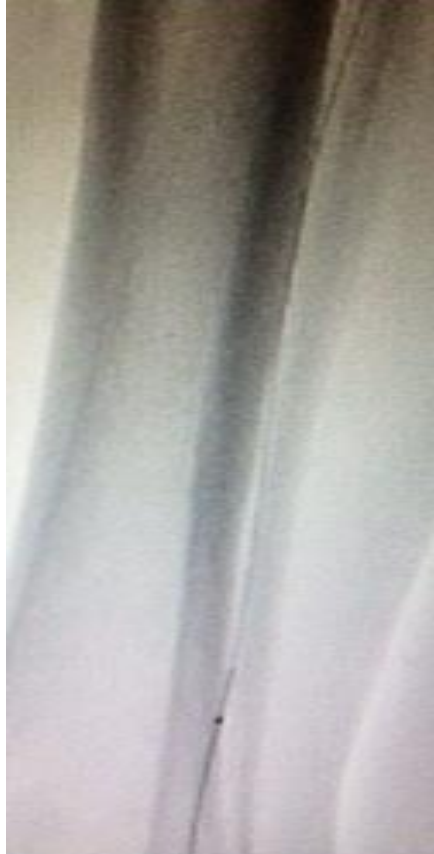

Figure 3

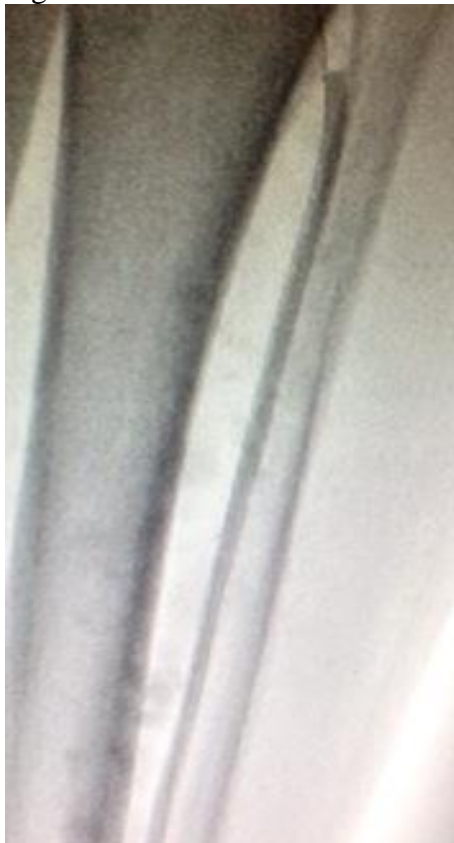

Figure 4



Case 2: A 76-year-old female patient with history of diabetes mellitus, hypertension, hyperlipidemia, coronary artery disease, and a long history of smoking presented with severe resting left leg pain, an unhealed left foot ulcer and a Rutherford classification VI. Pre-intervention angiogram showed a severe complex stenosis (99%) involving the left anterior tibial artery and tibio-peroneal trunk as shown in Figure 5. Using a retrograde anterior tibial artery approach, we performed orbital atherectomy and balloon angioplasty to the anterior tibial artery and the tibio-peroneal trunk in retrograde fashion as shown in Figure 6 and 7.

Figure 5

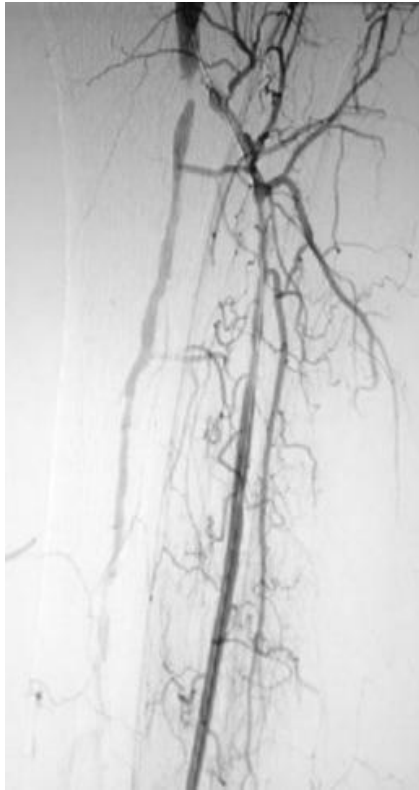
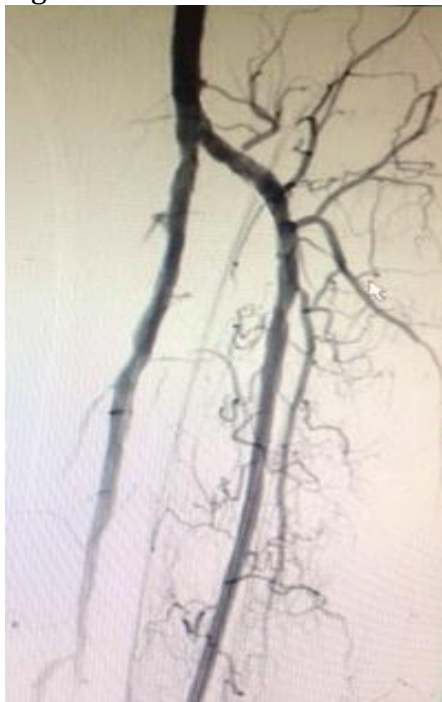


Figure 6



Figure 7



Case 3: A 67-year-old male patient with history of diabetes mellitus, hypertension, hyperlipidemia, hypertension, coronary artery disease and peripheral arterial disease status post superficial femoral artery intervention, and a long history of smoking presented with severe leg pain at rest and Rutherford classification IV. His pre-intervention angiogram showed a 70% stenosis of the proximal anterior tibial artery and a severely calcified lesion (80-90%) in the left tibial peroneal trunk as shown in Figure 8. Following retrograde anterior tibial access, orbital atherectomy and angioplasty to anterior tibial artery and tibio-peroneal trunk in retrograde fashion were performed as shown in Figure 9 and 10.

Figure 8

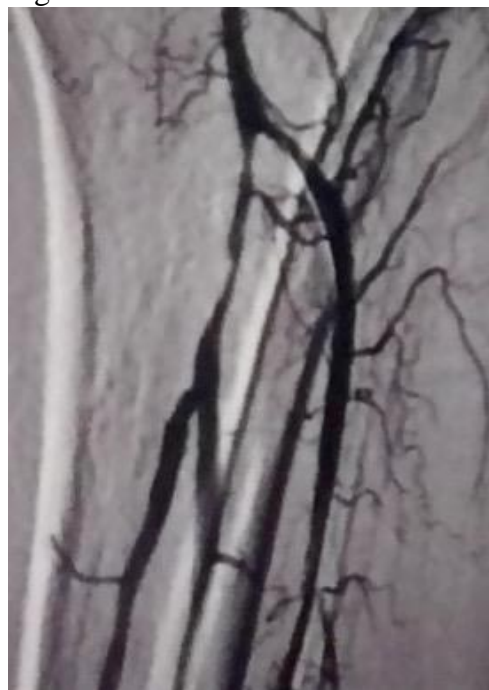
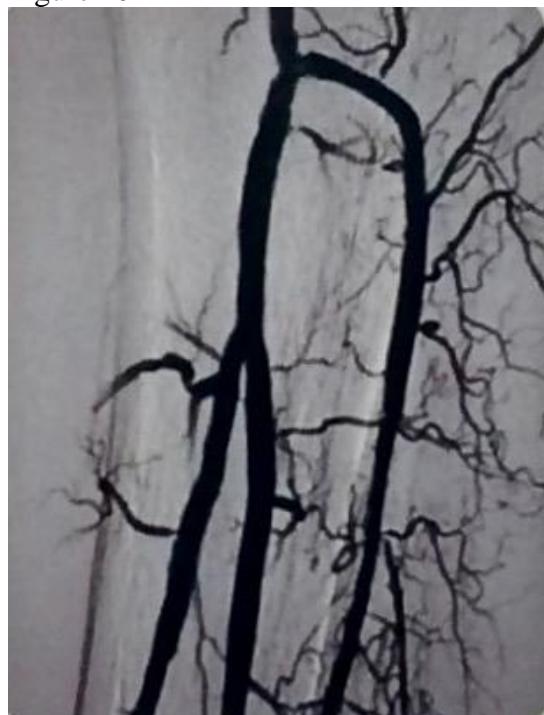
Figure 9



Figure 10



Procedure/ Technique

The anterior tibial artery was accessed as an initial primary approach via ultrasound guidance. A 4 Fr Glidesheath was inserted. A standard cocktail of antithrombotic and spasmolytic therapy was used (heparin, verapamil, nitroglycerine and lidocaine) through the access sheath followed by intravenous cocktail therapy (heparin, verapamil and nitroglycerin) through out the procedure as per standard protocol. Regalia wire was used to cross the lesions and in some cases to navigate through tibio-peroneal trunk as antegrade approach from a retrograde anterior tibial access. The Regalia wire was exchanged for a 0.018" CSI Viperwire over 0.18 exchange catheter. Orbital atherectomy was carried out using a Diamondback 360 peripheral device 1.25 mm solid crown. After orbital atherectomy of the anterior tibial artery, balloon dilatation was performed using a 3mm*200mm Vascutrak balloon catheter. In case 3, orbital atherectomy and angioplasty was performed to the tibioperoneal trunk and posterior tibial artery in antegrade fashion through a retrograde anterior tibial access. After final angiogram, the pedal sheath was removed, and hemostasis was secured. Total procedure time in each one of the three cases was around 10-15 minutes from access to sheath removal. All patients were discharged home 6 hours after procedure without immediate complications. .

Discussion

Critical limb ischemia (CLI) develops in 11.08% of patients with peripheral artery disease (PAD).¹ CLI (Rutherford class IV-VI) is a terminal stage of PAD and is defined by the presence of resting pain and/or tissue loss for at least 2 to 4 weeks. Objective threshold measurements to define CLI include the following: a flat waveform on pulse volume recording, a low or absent pedal flow on duplex ultrasonography, an ankle brachial index equal to or less than 0.4, an ankle systolic pressure equal to or less than 50 mm Hg, or a toe pressure equal to or less than 30 mm Hg.²⁻⁵ However, due to the associated medial calcifications in the settings of long standing hypertension, diabetes mellitus, and end stage renal disease, these measurements may be falsely elevated and further careful clinical work up might be deemed necessary.⁶

CLI is associated with a high risk of cardiovascular events and limb loss (amputation), which creates a major socioeconomic burden. The key goal of CLI treatment is to prevent amputation. Generally, CLI is usually divided to Aorto-iliac (AI), Femoro-popliteal (FP), and Infra-popliteal (IP), but less than 10% of patients with CLI have significant disease in all 3 levels.⁷ CLI secondary to isolated IP disease is mainly seen in elderly, diabetics, or ESRD/Dialysis patients.⁵ These patients are at high risk of amputation compared to those with FP and IP together.⁸ Endovascular therapy has been well established as an appropriate first-line therapeutic treatment option for the treatment of CLI. CLI patients secondary to IP disease have a higher incidence of limb loss, presumably due to more extensive distal disease with poor runoff to the foot as well as severe comorbidities.^{8,9} These patients usually have severely calcified arteries, which used to be one of the most common challenges in patients with CLI secondary to IP disease. These severely calcified lesions have heterogeneous distributions of calcium densities that lead to heterogeneous distributions of resistance (unequal distribution of pressure vectors), which during intervention lead to increase the risk of dissection, plaque rupture, and embolization.¹⁰

With the advancement of new technologies including multiple atherectomy devices as well as vast array of balloons, we are able to overcome some of these challenges and achieve more success using a retrograde approach. A retrograde approach utilizing pedal access improves

the crossing success of lesions as well as facilitates the use of some atherectomy devices to remove large plaque burden and modify the compliance of severely calcified infra-popliteal vessels. Since 2003 when the retrograde Tibio-pedal access approach was originally described by Botti et al and spinosa et al^{11,12}, several single-center case series have been reported using this approach as an alternative for limb salvage in CLI patients. Retrograde tibio-pedal arterial access approach for endovascular intervention in CLI patients has been well described in the literature as an effective, safe, and feasible approach with a high technical success rate and a relatively low procedural complication rate.^{6,13,14} However, it is currently still considered as an alternative endovascular approach for limb salvage in patients with CLI after failed antegrade femoral artery access approach or for patients who are not candidates for antegrade approach such as those with hostile groins, infected groins, morbid obesity, or other comorbidities.

Rational in using retrograde tibio-pedal access as an initial primary approach in CLI patients confined to IP vessels is as follows. This approach allows quick therapy and short procedural time with less observation time in the hospital. The success of the procedure may be in part influenced by better pushability of wires, balloons, and devices due to relatively smaller artery diameter and close proximity of the chronic total occlusion (CTO) segment of the artery to the access site. Furthermore, as collateral vessels usually arise in caudal angles, the likelihood of entering these vessels is less with the retrograde method than the antegrade approach. The distal segments of the CTO cap in tibial vessels are likely to have more favorable shape and composition (less calcium composition) than the proximal cap; this makes it easier to cross the lesions successfully in a retrograde fashion.^{15,16} Also, in addition to all of the above, this approach is safer in morbidly obese patients or patients with hostile or infected groin who are not candidates for antegrade femoral approach. Using the retrograde approach will minimize the classic complications of the antegrade approach as: retroperitoneal bleeding, hematoma, pseudoaneurysm and AV fistula. Retrograde tibio-pedal access is safe with a low 30-day mortality and low rate of major adverse cardiac events. Freedom from major adverse limb events and limb salvage are both high at 1 year follow up.^{13,17}

Rational for using retrograde tibio-pedal access as an alternative or adjuvant to antegrade approach is as follows. Tibial arteries are small in diameter, which make them prone to vasospasm and thrombus formation. Although these challenges have been reduced significantly with the use of different protocols developed to minimize these complications, the risk might still be a concern. Risks and benefits have to be assessed carefully on an individual bases. Using dual antiplatelet (DAPT) and statin therapy to maintain vessels patency, vessel wall integrity, and reduce cardiac morbidity is crucial. Mastering the technique of tibio-pedal access is a limiting step. Attaining duplex ultrasound knowledge and interpretation, defining access site suitability, and avoiding interruption of communicating arteries and collaterals is crucial. The possibility of multiple sticks to gain access may promote vessel spasm, thrombosis, AV fistula formation, pseudo-aneurysm development, and obliteration of the runoff and potentially worsening outcomes. These complications are rarely seen in well-developed and experienced institutions.

Conclusion

Retrograde tibio-pedal arterial access approach has shown to achieve high limb salvage rates with low morbidity and mortality utilizing highly skilled operators and advancements in current resources. Retrograde tibio-pedal arterial access, as an initial primary approach for

endovascular intervention in CLI patients confined to IP vessels, is an effective, safe, and feasible approach with a high technical success rate and a relatively low procedural complication rate.

References

1. Nehler MR, Duval S, Diao L, Annex BH, Hiatt WR, Rogers K, et al. Epidemiology of peripheral arterial disease and critical limb ischemia in an insured national population. *J Vasc Surg.* 2014;60(3):686-95 e2.
2. Second European Consensus Document on chronic critical leg ischemia. *Eur J Vasc Surg.* 1992;6 Suppl A:1-32.
3. Fernandez N, McEnaney R, Marone LK, Rhee RY, Leers S, Makaroun M, et al. Predictors of failure and success of tibial interventions for critical limb ischemia. *J Vasc Surg.* 2010;52(4):834-42.
4. Gray BH, Diaz-Sandoval LJ, Dieter RS, Jaff MR, White CJ. SCAI expert consensus statement for infrapopliteal arterial intervention appropriate use. *Catheter Cardiovasc Interv.* 2014;84(4):539-45.
5. Gray BH, Grant AA, Kalbaugh CA, Blackhurst DW, Langan EM, 3rd, Taylor SA, et al. The impact of isolated tibial disease on outcomes in the critical limb ischemic population. *Ann Vasc Surg.* 2010;24(3):349-59.
6. Dobrow EM, Mittleder D. Retrograde tibiopedal access for the treatment of critical limb ischemia. *Tech Vasc Interv Radiol.* 2015;18(2):66-75.
7. Aboyans V, Desormais I, Lacroix P, Salazar J, Criqui MH, Laskar M. The general prognosis of patients with peripheral arterial disease differs according to the disease localization. *Journal of the American College of Cardiology.* 2010;55(9):898-903.
8. Sadek M, Ellozy SH, Turnbull IC, Lookstein RA, Marin ML, Faries PL. Improved outcomes are associated with multilevel endovascular intervention involving the tibial vessels compared with isolated tibial intervention. *J Vasc Surg.* 2009;49(3):638-43; discussion 43-4.
9. Fernandez N, McEnaney R, Marone LK, Rhee RY, Leers S, Makaroun M, et al. Multilevel versus isolated endovascular tibial interventions for critical limb ischemia. *J Vasc Surg.* 2011;54(3):722-9.
10. Mustapha JA, Diaz-Sandoval LJ. Balloon angioplasty in tibioperoneal interventions for patients with critical limb ischemia. *Tech Vasc Interv Radiol.* 2014;17(3):183-96.
11. Spinosa DJ, Leung DA, Harthun NL, Cage DL, Fritz Angle J, Hagspiel KD, et al. Simultaneous antegrade and retrograde access for subintimal recanalization of peripheral arterial occlusion. *J Vasc Interv Radiol.* 2003;14(11):1449-54.
12. Botti CF, Jr., Ansel GM, Silver MJ, Barker BJ, South S. Percutaneous retrograde tibial access in limb salvage. *J Endovasc Ther.* 2003;10(3):614-8.
13. El-Sayed H, Bennett ME, Loh TM, Davies MG. Retrograde pedal access and endovascular revascularization: a safe and effective technique for high-risk patients with complex tibial vessel disease. *Ann Vasc Surg.* 2016;31:91-8.
14. Walker CM, Mustapha J, Zeller T, Schmidt A, Montero-Baker M, Nanjundappa A, et al. Tibiopedal access for crossing of infrainguinal artery occlusions: a prospective multicenter observational study. *J Endovasc Ther.* 2016.
15. Montero-Baker M, Schmidt A, Braunlich S, Ulrich M, Thieme M, Biamino G, et al. Retrograde approach for complex popliteal and tibioperoneal occlusions. *J Endovasc Ther.* 2008;15(5):594-604.
16. Bazan HA, Le L, Donovan M, Sidhom T, Smith TA, Sternbergh WC, 3rd. Retrograde pedal access for patients with critical limb ischemia. *J Vasc Surg.* 2014;60(2):375-81.
17. Kwan TW, Shah S, Amoroso N, Diwan R, Makker P, Ratcliffe JA, et al. Feasibility and safety of routine transpedal arterial access for treatment of peripheral artery disease. *J Invasive Cardiol.* 2015;27(7):327-30.