



**BJP**

**Bangladesh Journal of Pharmacology**

**Research Article**

**Hepatoprotective activity of fruit  
extract of *Garcinia pedunculata***

## Hepatoprotective activity of fruit extract of *Garcinia pedunculata*

Ravi Mundugaru<sup>1</sup>, Madhan Chakkravarthy Varadharajan<sup>2</sup> and Ravishankar Basavaiah<sup>3</sup>

<sup>1</sup>Department of Pharmacology and Toxicology, SDM Centre for Research in Ayurveda and Allied Sciences, Udipi 574 118, India; <sup>2</sup>Department of Research and Development, (DRD), Biomedical Research Unit and Laboratory Animal Centre (BRULAC), Saveetha University Thandalam, Chennai 602 105, India; <sup>3</sup>Department of Pharmacology and Toxicology, SDM Centre for Research in Ayurveda and Allied Sciences, Udipi 574 118, India.

### Article Info

Received: 8 August 2014  
Accepted: 1 September 2014  
Available Online: 1 October 2014  
DOI: 10.3329/bjp.v9i4.19910

### Cite this article:

Mundugaru R, Varadharajan MC, Basavaiah R. Hepatoprotective activity of fruit extract of *Garcinia pedunculata*. Bangladesh J Pharmacol. 2017; 12: 483-87.

### Abstract

The objective of this study is to explore the hepatoprotective activity of fruits of *Garcinia pedunculata* in paracetamol-induced liver toxicity in rats. Paracetamol-induced hepatotoxicity was evaluated by an increase in serum transaminases and alkaline phosphatase activity. Histopathological observation showed extensive disturbance in the liver cytoarchitecture in comparison to normal control liver sections. Pre-treatment with aqueous extract of fruits of *G. pedunculata* prevented the paracetamol-induced increase in serum transaminases, alkaline phosphatase and histopathological changes. Based on the above observation it can be concluded that *G. pedunculata* pretreatment exhibited significant hepatoprotective activity against paracetamol-induced hepatotoxicity.

## Introduction

The liver is a vital organ, supports almost every organ in the body and is vital for survival. Because of its multidimensional function the liver is also prone to many diseases. The most common diseases are hepatitis, alcohol damage, fatty liver, cirrhosis, cancer and drug induced liver damage (Graham et al., 2013). However the liver has great capacity to regenerate and has a large reserve capacity. In most cases the liver only produces symptoms after extensive damage.

Paracetamol is used as an antipyretic and analgesic (Larson et al., 2005; Rumack et al., 1975). At recommended doses and for a limited course of treatment the side effects of paracetamol are mild but the overdose of paracetamol can cause fatal hepatic damage, gastrointestinal complication, renal failure, asthma and skin reactions (Patiri et al., 2007).

*Garcinia pedunculata* is a medicinal plant commonly known as amlavetasa and available particularly in Assam, Arunachal Pradesh and West Bengal regions. It has been indicated for many ailments such as chronic

catarrh, asthma, cough, bronchitis, fever and as a cardiogenic (Kagyung et al., 2010). The phytochemical studies have shown the dried fruit rinds and pericarp of *G. pedunculata* contains benzophenones, pedunculol, hydroxy citric acid, garcinol and cambogin (Sahu et al., 1989). The plant has been screened for its *in vitro* antioxidant activity and found to possess an excellent antioxidant property and anti-inflammatory activity (Jayaprakasha et al., 2006; Mundugaru et al., 2014). There are no documented studies available regarding hepatoprotective activity of the aqueous extract of fruits of *G. pedunculata*. Therefore, the present study has been undertaken to evaluate the hepatoprotective activity.

## Materials and Methods

### Plant material and extract preparation

Fruits of *G. pedunculata* were collected from the region of Assam in India during March of 2012. It was authenticated in Pharmacognosy Laboratory, SDM Centre for Research in Ayurveda and Allied Sciences, Udipi. Voucher specimen (No. 13100501) has been



deposited for further future reference. The powder of *G. pedunculata* was prepared in the Pharmacy attached to SDM College Ayurveda, Udupi, from authenticated plant material. The powder obtained from a single batch was used throughout the experimental study. Five hundred grams of fruit powder of *G. pedunculata* was soaked in 2L of distilled water for twenty four hours; it was filtered and concentrated by evaporation. The concentrated extract was used for hepatoprotective activity.

#### Experimental animals

Wistar albino rats of either sex weighing  $200 \pm 50$  g were obtained from animal house attached to Department of Pharmacology, SDM Centre for Research in Ayurveda and Allied Sciences, Udupi. The experimental protocol was approved by the Institutional Animal Ethics Committee under the reference no. SDMCRA/ IAEC-2012-13DGM 02ab. The animals were fed with normal rat diet and water *ad libitum* throughout the study period. The animals were acclimatized for two weeks at the laboratory condition prior to the experimentation. The animals were maintained at controlled lighting of 12:12 hours light and dark cycle, temperature of 25°C and relative humidity of approximately  $50 \pm 5\%$ .

#### Acute oral toxicity test

The acute oral toxicity study was carried out as per OECD guidelines 425 using AOT software. The aqueous extract of fruits of *G. pedunculata* was made into a suspension in 0.5% gum acacia and dosed in the following order 175, 550, and 2,000 mg/kg body weight. After the dosing the animals were observed for 14 days for mortality. The dose at which the animal dies, that particular dose is repeated two times to determine its toxic potential. If mortality was not observed at 2,000 mg/kg, dosing was stopped and LD<sub>50</sub> was determined by using AOT software.

#### Evaluation of hepatoprotective activity

Control group were administered with normal tap water at a dose of 5 mL /kg in 0.5% gum acacia, the standard group were administered with silymarin 50 mg/kg as a suspension with 0.5% gum acacia and

Group III was administered with aqueous extract of *G. pedunculata* at a dose of 400 mg/kg as a suspension with 0.5% gum acacia, served as test group. The group specific drugs were administered for nine consecutive days. On seventh day one hour after administration of group specific drugs the liver was damaged by intraperitoneal injection of paracetamol at a dose of 1 g/kg in three divided doses. All the animals were sacrificed 48 hours after administration of paracetamol (Yoshigurki et al., 1992). The hepatoprotective effect of extract was evaluated by the assay of serum biochemical markers such as SGOT, SGPT and ALP according to standard methods (Bradly et al., 1972; Wilkinson et al., 1996).

#### Histopathological studies

The animals were sacrificed and the abdomen was cut open to isolate the liver. The liver was washed with normal saline and for histopathological study biopsy specimen was fixed in 10% formalin solution and then the liver tissue was embedded in paraffin. The section was cut into 5  $\mu$ m thickness and stained with hematoxyline-eosin stain and mounted in diphenylxyline. The histopathological changes of liver tissue were observed under compound microscope and their microphotographs were taken (Bancroft et al., 2002).

## Result

Acute oral toxicity study did not reveal any mortality in any dose up to 2,000 mg/kg of aqueous extract of fruits of the plant *G. pedunculata*. This indicates that LD<sub>50</sub> is much more than 2,000 mg/kg and hence 1/5<sup>th</sup> of dose was selected for the present hepatoprotective study.

The damage caused by the treatment of overdose of paracetamol to the structure integrity of liver cells is assessed by the determination of biochemical parameters such as SGOT, SGPT and alkaline phosphatase activities. The levels of SGOT, SGPT and alkaline phosphatase was significantly increased ( $p < 0.001$ ) in the paracetamol treated group in comparison to normal control group. Aqueous extract of fruits of *G. pedunculata* showed significant reduction in the SGOT,

Table I

#### Efficacy of fruit extract of *Garcinia pedunculata* on serum transaminases and alkaline phosphatase activities

Group	Serum SGOT (IU/L)	Serum SGPT (IU/L)	Serum alkaline phosphatase (IU/L)
Normal (0.5% gum acacia)	129.9 $\pm$ 15.8	58.7 $\pm$ 13.8	279.1 $\pm$ 17.8
Paracetamol control (1 g/kg)	1555.2 $\pm$ 205.3 <sup>a</sup>	411.9 $\pm$ 57.9 <sup>a</sup>	611.5 $\pm$ 60.2 <sup>a</sup>
Extract (400 mg/kg) plus paracetamol (1 g/kg)	963.8 $\pm$ 114.1 <sup>c</sup>	190.3 $\pm$ 21.1 <sup>c</sup>	240.0 $\pm$ 21.3 <sup>b</sup>
Silymarin (50 mg/kg) plus paracetamol (1 g/kg)	700.5 $\pm$ 86.9 <sup>b</sup>	332.1 $\pm$ 85.2	156.0 $\pm$ 24.8 <sup>b</sup>

Data expressed in mean  $\pm$  SEM, <sup>a</sup> $p < 0.01$  in comparison to normal control group; <sup>b</sup> $p < 0.01$ , <sup>c</sup> $p < 0.05$  in comparison to paracetamol control group

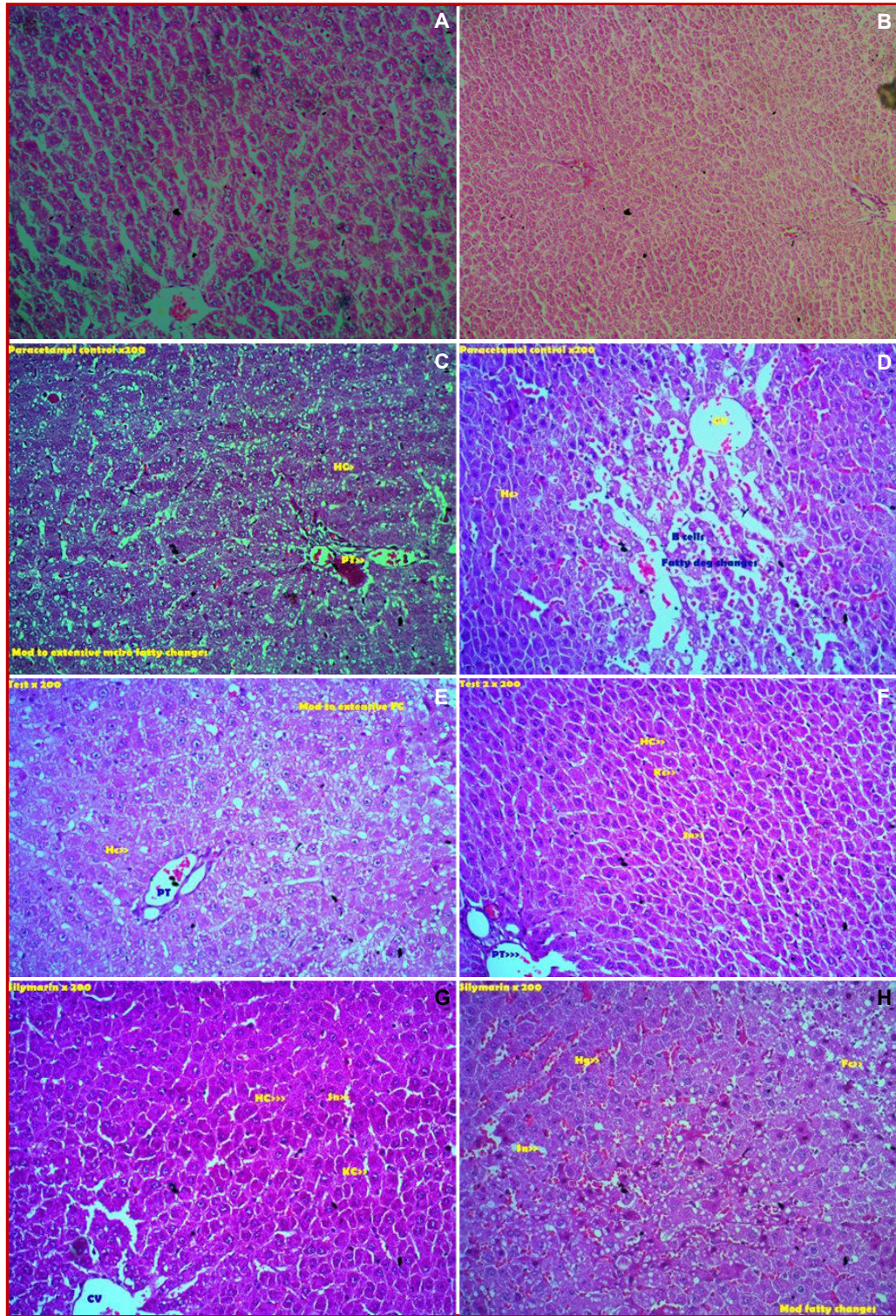


Figure 1: Photomicrographs of representative liver sections from normal control group treated with gum acacia shows normal cytoarchitecture of liver (A-B). Liver sections from silymarin and paracetamol injected rats (C-F). It shows protection and almost normal cytoarchitecture in sections from rats with mild degenerative changes in the form of necrosis and macro fatty changes were observed in sections. Liver sections from paracetamol control group shows hepatocyte necrosis, appearance of balloon cells, leukocyte infiltration, micro and macro fatty changes in the hepatocytes, sinusoidal dilatation and appearance of areas of regenerations. Photomicrographs of representative liver sections from Test drug and paracetamol injected rats shows mild fatty changes and mild cell infiltration (G and H); HC- Hepatic cell; KC- Kupffer cell; Sn- Sinusoid; PT- Portal triad; CI- Cell infiltration; Fc- Fatty changes; CV- Central vein

SGPT ( $p < 0.01$ ) and alkaline phosphatase activity ( $p < 0.05$ ) in comparison to paracetamol control group (Table I).

Microscopic examination of liver sections from paracetamol treated group showed extensive disturbance in the liver cytoarchitecture in comparison to the sections from normal control liver sections (Figure 1A-D). The changes observed were hepatocyte necrosis, appearance of balloon cells, leukocyte infiltration, micro and macro fatty changes in the hepatocytes, sinusoidal dilatation and appearance of areas of regenerations.

Liver sections from paracetamol pretreated group followed by either extract or silymarin exhibited good protection and almost normal cytoarchitecture in sections from three rats (Figure 1E-H). Moderate degenerative changes in the form of necrosis and macro fatty changes were observed in sections from two rats. In the remaining sections diffused mild microfatty changes were observed.

Mild fatty changes were observed in *G. Pedunculata* extract treated group in three rats only. In two sections moderate fatty changes and mild cell infiltration was observed. In one section mild to moderate degenerative changes were observed.

---

## Discussion

In the present study, hepatoprotective activity of aqueous extract of fruits of *G. pedunculata* was evaluated against paracetamol overdose induced hepatotoxicity in Wistar albino rats.

Ingested paracetamol undergoes metabolism in liver by cytochrome  $P_{450}$ , producing most reactive metabolite N-acetyl-p-benzoquinoneimine. At usual doses N-acetyl-p-benzoquinoneimine is quickly detoxified by conjugation with glutathione (Grosser et al., 2006). While administered at overdose the detoxification pathway remains saturated and as a consequences N-acetyl-p-benzoquinoneimine accumulates causing hepatic damage.

SGOT is a mitochondrial enzyme released from heart, liver, skeletal muscle and kidney. SGOT level may rise in acute necrosis or ischemia of other organs such as the myocardium, besides the liver cell injury. SGPT is a cytosolic enzyme primarily present in the liver tissue. Thus the serum estimation of SGPT is fairly specific for liver tissue is of great value in liver cell injury (Dixon et al., 1971; Schmidt et al., 1975). It is well established that level of serum enzymes such as SGOT and SGPT gets elevated in paracetamol induced hepatotoxicity. In the present study extremely significant elevation was observed in paracetamol treated group. This transaminase activity elevation was found to be significantly reduced by extract and reference standard drug silyma-

rin. This can be considered as the first line of evidence for the presence of significant hepatoprotection in the test drug.

Serum alkaline phosphatase is produced by many tissues, especially bone, liver, intestine and in pregnancy. Elevation in activity of the enzyme can thus be found in disease of bone, liver and in pregnancy. In the absence of bone disease and pregnancy, an elevated serum alkaline phosphatase levels generally reflect hepatobiliary diseases. Alkaline phosphatase is normally excreted in the bile. If it is affected due to liver injury its level gets elevated. This may be one of the reasons for the observed elevation since it is reported that greater elevation occurs in biliary tract obstruction (Rajesh et al., 2001).

In the present study statistically significant increase in the alkaline phosphatase activity was observed after paracetamol injection. This elevation was reversed in significant manner by extract and reference standard drug. Reversal of alkaline phosphatase elevation can be considered as another indicator of hepatoprotection.

Histopathological observation has shown that in three rats only mild fatty changes were observed in extract administered group. In two sections moderate fatty changes and mild cell infiltration was observed. In one section mild to moderate degenerative changes were observed. This indicates extract might have possessed membrane stabilizing action and it may contribute for protection of structural integrity of hepatocytes.

The preliminary phytochemical analysis revealed the presence of flavonoids, saponins, glycosides, steroids, alkaloids and phenols. It is also reported that the fruit of *G. pedunculata* has good anti-oxidant property and reported in the earlier studies. Thus these phytochemical may be responsible for the hepatoprotective activity of *G. pedunculata* perhaps through their anti-oxidant activity.

---

## Acknowledgements

Authors are highly grateful to our revered President, Dr. D. Veerendra Heggade for the constant support, and Dr. B. Yashoverma, Secretary SDM Educational Society for the guidance.

---

## References

- Bancroft JD, Gamble M. Theory and practice of histological techniques. 5<sup>th</sup> ed. Churchill Livingstone, 2002.
- Bradly DW, Maynard JE, Emery G, Webster H. Transaminase activities in serum of long-term hemodialysis patients. Clin Chem. 1972; 18: 1442.
- Dixon MF, Nimmo J, Prescott LF. Experimental paracetamol-induced hepatic necrosis: A histopathological study. J

- Pathol. 1971; 103; 225-27.
- Grosser T, Smyth E, Fitzgerald GA. Anti-inflammatory antipyretic and analgesic agents: Pharmacotherapy of gout. In: Goodman and Gilman's The Pharmacological basis of therapeutics. 11<sup>th</sup> ed. New York, The McGraw Companies, 2006, p 983.
- Jayaprakasha GK, Negi PS, Jena BS. Anti-oxidative and anti-mutagenic activities of the extracts from the rinds of *Garcinia pedunculata*. *Innov Food Sci Emerg Technol*. 2006; 7: 246-50.
- Kagyung R, Gajurel PR, Rethy P, Singh B. Ethnomedicinal plants used for gastrointestinal diseases by *Adi* tribes of Dehang-Debang Biosphere Reserve in Arunachal Pradesh. *Indian J Tradit Know*. 2010; 9: 496-501.
- Graham GG, Davies MJ, Day RO, Mohamudally A, Scott KF. The modern pharmacology of paracetamol: Therapeutic actions, mechanism of action, metabolism, toxicity and recent pharmacological findings. *Inflammopharmacology* 2013; 21: 201-32.
- Larson AM, Polson J, Fontana RJ. Acetaminophen-induced acute liver failure: Results of a United States multicenter, prospective study. *Hepatology* 2005; 42: 1364-72.
- Mundugaru R, Joy F, Shrinidhi R, Das L, Sudhakara, Ravishankar B. Anti-inflammatory activity of aqueous extract of fruits of *Garcinia pedunculata* in experimental animals. *Am J Pharma Tech Res*. 2014; 4; 3.
- Patiri B, Borah A. Wild edible plants of Assam. 1st ed. Assam, Director Forest Communication, Forest Department, 2007.
- Rumack B, Matthew H. Acetaminophen poisoning and toxicity. *Pediatrics* 1975; 55: 871-76.
- Rajesh MJ, Latha MS. Hepatoprotection by *Elephantopus scaber* Linn. in CCL<sub>4</sub>-induced liver injury. *Indian J Physiol Pharmacol*. 2001; 45; 481-86.
- Sahu A, Das B, Chatterjee A. Polyisoprenylated benzophenones from *Garcinia pedunculata*. *Phytochemistry* 1989; 28: 1233-35.
- Schmidt E, Schemidt FW, Mohr J, Otto P, Vido I, Wrongeman K, Herfarth C (eds.). In: Pathogenesis and mechanism of liver cell necrosis. 4<sup>th</sup> ed. Lancaster, Medical and Technical Publications, 1975, p 147.
- Wilkinson J H, Boutwell J H, Winsten S. Evaluation of a new system for kinetic measurement of serum alkaline phosphatase. *Clin Chem*. 1969; 15: 487-95.
- Yoshigurki M, Thoshihara H, Shoji A. High molecular weight protein aggregates formed in the liver of paracetamol treated rats. *J Pharm Pharmacol*. 1992; 44: 932.
- 

**Author Info**

Ravi Mundugaru (Principal contact)  
e-mail: ravisdm13@gmail.com