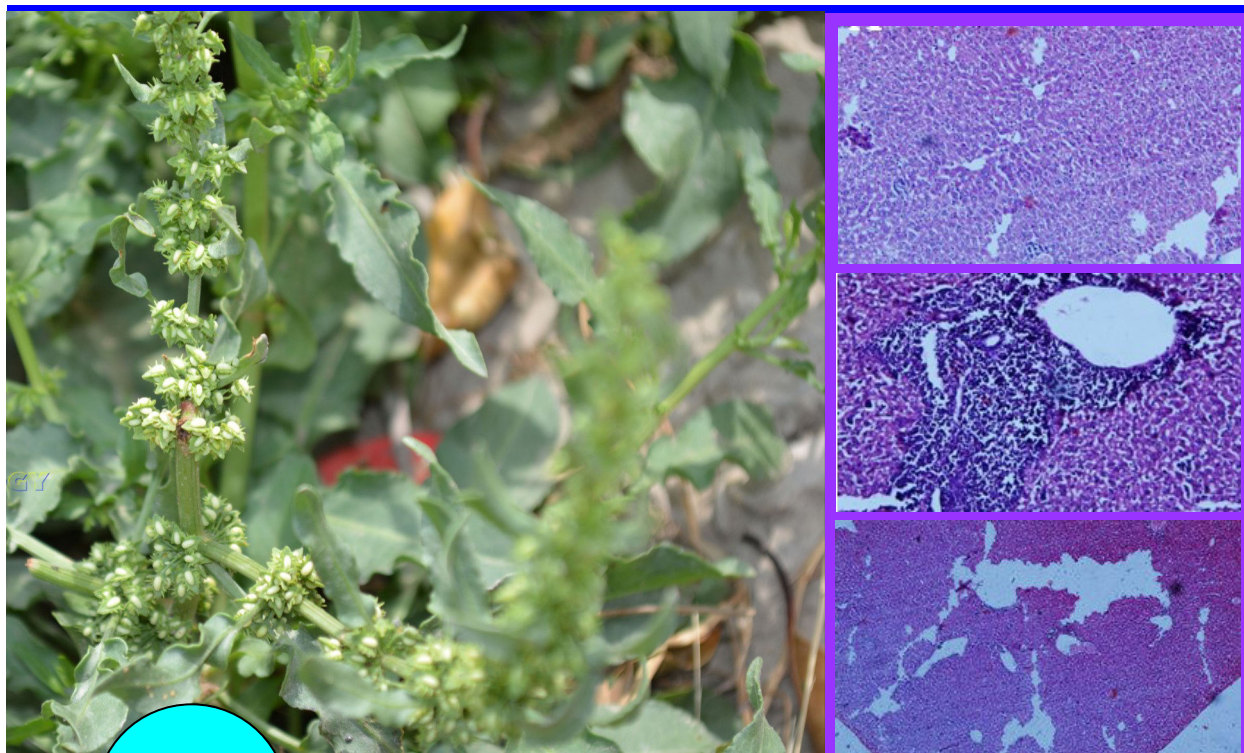

BJP

Bangladesh Journal of Pharmacology

Research Article

Hepatoprotective effect of aqueous methanolic extract of *Rumex dentatus* in paracetamol-induced hepatotoxicity in mice

Hepatoprotective effect of aqueous methanolic extract of *Rumex dentatus* in paracetamol-induced hepatotoxicity in mice

Mohammad Saleem¹, Bilal Ahmed¹, Mahrukh Karim¹, Shahzad Ahmed²,
Mobasher Ahmad³, M. Imran Qadir⁴, and Nawazish-i-Husain Syed³

¹College of Pharmacy, GC University, Faisalabad, Pakistan; ²Draxel University College of Medicines, Philadelphia, USA; ³University College of Pharmacy, University of The Punjab, Lahore, Pakistan; ⁴Institute of Molecular Biology & Biotechnology, Bahauddin Zakariya University, Multan Pakistan.

Article Info

Received: 12 May 2014
Accepted: 16 June 2014
Available Online: 13 July 2014
DOI: 10.3329/bjp.v9i3.18874

Cite this article:

Saleem M, Ahmed B, Karim M, Ahmed S, Ahmad M, Qadir MI, Syed NH. Hepatoprotective effect of aqueous methanolic extract of *Rumex dentatus* in paracetamol-induced hepatotoxicity in mice. Bangladesh J Pharmacol. 2014; 9: 284-89.

Abstract

Rumex dentatus is well known plant of Polygonaceae family which is widely used in traditional medicine to treat gastrointestinal tract. *R. dentatus* at doses 250 and 500 mg/kg significance decreased ($p < 0.001$) the elevated level of ALT, AST, ALP and bilirubin induced by paracetamol and results are comparable ($p < 0.001$) with silymarin. The results were supported by histopathological investigations, phytochemical screening and detection of hepatoprotective active constituents e.g quercetin, kaempferol, myricetin by HPLC. So, it is concluded that *R. dentatus* has hepatoprotective effect against paracetamol liver damage in mice.

Introduction

Liver is the one of the major and important organ of body. It has vital role in metabolism and elimination of various agents. All chemical agents first pass through liver prior to enter in blood circulation. So liver is at high risk of damage then other body organ (Samuel et al., 2012). The toxic agents which may damage the liver are drugs such as paracetamol, xenobiotics, viral infections, alcoholism and chemical agents (Ramchandara et al., 2007). That's why the liver injury is one of the major problems in World Wide Health. Synthetic preparations are available in the market to treat liver diseases but these synthetic are limited in number and also have side effects. So there is an urgent need to investigate the natural plants and isolate their constituents which can be beneficial to control liver diseases (Ravikumar et al., 2012). It has been seen that many herbal plants are found to be hepatoprotective such as *Cichorium intybus* (Heibatollah et al., 2008), *Luminet racemosa* (Gnanadesigan et al., 2011), *Solanum*

nigrum (Raju et al., 2003), *Hibiscus vitifolius* (Samuel et al., 2012), *Chenopodium murale* (Saleem et al., 2014), *Trichodesma sedgwickianum* (Saboo et al., 2013), *Offpomoea staphylyna* (Bag and Mumtaz, 2013), *Convolvulus arvensis* (Ali et al., 2013), *Suaeda fruticosa* (Rehman et al., 2013) and *Khamira Gaozaban Ambri Jadwar Ood Saleeb Wala* (Akhtar et al., 2013).

Rumex dentatus is plant of Polygonaceae family. It has antifungal, antibacterial, insecticidal and allelopathic activities (Hussain et al., 2010; Umer et al., 2010). It also showed anti-inflammatory activity (Suleyman et al., 1999), antidermatitis (Litvinenko and MuzychKina, 2003), anti-proliferative (Zhang et al., 2012), anthelmintic properties (Bate-Smith, 1962). The paste of plant root is used to relieve headache externally (Manandhar, 2002). The leaves of plant are used traditionally as diuretic, refrigerant and cooling agent (Fatima et al., 2009; Hameed and Dastagir, 2009). Roots of plant used as purgative (Mananhar, 2002), eczema, acariasis and dysentery (Song et al., 1999). The objective



of our study was to evaluate the hepatoprotective effect of *R. dentatus*.

Materials and Methods

Collection of plants: Fresh plants were collected from district Sialkot, Punjab Pakistan. Plant was identified by Dr. Mansoor Hameed, Department of Botany, University of Agriculture, Faisalabad. Vouchers No 270-13 can be used for future reference.

Preparation of plant extracts: Plant was washed, dried under shade and finally grounded to powder. The powdered plant was soaked in aqueous methanolic (30:70) solvent for 7 days with occasional shaking at regular intervals. The extract was filtered and evaporated by using rotary evaporator at 60°C. The residue was stored in amber coloured glass bottle at 4°C.

Experimental animals: Adult Swiss albino mice weighing about 22-34 g were used. All the animals were placed in the animal house of College of Pharmacy, GC University Faisalabad. The animals were allowed to acclimate under standard laboratory conditions prior to perform experiment.

Experimental protocol: All animals were divided into 5 groups containing 5 animals each. Group 1 served as a control group receiving distilled water only Group II served as paracetamol control group received paracetamol 250 mg/kg (p.o) 7 days (Sabir and Rocha, 2008). Group III was treated with silymarin 50 mg/kg (p.o) and followed by paracetamol administration 3 hours after silymarin for 7 days (Girish et al., 2009). Group IV was treated with aqueous methanolic extract of *R. dentatus* at dose of 250 mg/kg (p.o) followed by paracetamol administration 250 mg/kg (p.o) 3 hours after the extract dose for 7 days. Group V was treated with aqueous methanolic extract of *R. dentatus* at dose of 500 mg/kg (p.o) followed by paracetamol administration 250 mg/kg (p.o) 3 hours after the extract dose for 7 days (Sabir and Rocha, 2008).

Biochemical and histopathological investigations: On 8th day, animals were sacrificed and blood was collected for serum separation. The change in aspartate amino transferase (AST), alanine amino transferase (ALT), alkaline phosphatase (ALP) and total bilirubin (TB) levels were measured for biochemical investigations. Histopathological studies were also conducted to examine microscopic changes in liver architecture (Ali et al., 2013).

Histopathological examination: Histopathological study was carried out to see the microscopic changes in the hepatocytes. For this purpose the slides of the liver sections were prepared and were examined by microscope to see the changes in liver hepatocytes.

Preliminary phytochemical analysis

The phytochemical screening of the plant extracts were

performed by standard procedures as given below:

Test for alkaloids: 0.2 g of the extract was added in 2N HCl (5 mL) then heated on the boiling water bath. The mixture was filtered after cooling and the filtrate was divided in the two equal halves. Few drops of Mayer's reagent were added in one portion and the Dragendoeff's reagent was added in other portion. Turbidity of the formed precipitate in the both reagents indicates the presence of alkaloids (Mojab et al., 2003; Sharma et al., 2010).

Test for tannins: 0.2 g extracts was dissolved in 10 mL of distilled water and warm on water bath. The mixture was filtered and 5% solution of ferric chloride was added to filtrate. The formation of dark green solution indicates the presence of tannins (Mojab et al., 2003).

Test for saponins: 0.2 g of extract was mixed in test tube with 5 mL of distilled water and warm on water bath until it begins to boil. Formation of foam that persists for 10 min indicates the presence of saponins (Mojab et al., 2003; Sofowora, 1993).

Test for terpenoids: 0.2 g of extract was shaken separately with 2 mL of chloroform (CHCl₃), and then 3 mL of concentrated H₂SO₄ was added carefully to form a layer. The formation of reddish brown color at inert face of the solution indicates the presence of terpenoids (Sofowora, 1993; Sharma et al., 2010).

Test for flavonoids: 0.2 g of extract was taken separately and dissolved in 5 mL diluted NaOH then 1M of 5 mL HCl was added. A yellow color solution that changes into colourless solution indicates the presence of flavonoids (Sofowora, 1993).

Test for steroids: Two milliliters of acetic anhydride was added to 0.5 g ethanolic extract of each sample with 2 mL H₂SO₄. The colour changed from violet to blue or green in some samples indicating the presence of steroids.

Test for anthraquinones: 0.5 g of extract was boiled with 10% of HCl in water bath for few min and then filtered. The filtrate was cooled and then equal amount of CHCl₃ was added in the filtrate. Few drops of 10%NH₃ was added in the mixture and heated. The formation of rose-pink coloration indicates the presence of anthraquinones (Mojab et al., 2003; Sharma et al., 2010).

Test for glycosides: 1.2 g of extract was hydrolyzed with 10 mL of 1% HCl and then neutralized by 10% of NaOH solution. Few drops of Fehling's solution A and B were poured in it. Formation of red color precipitates shows the presence of glycosides (Mojab et al., 2003; Sharma et al., 2010).

Identification of active constituents by HPLC: Qualitative determination of active constituents having hepatoprotective activity was done by using HPLC. Sample was prepared by adding small amount of extract in 5 mL distilled water, 12 mL methanol and kept for 5 min. Then 6 mL distilled water was again

added and kept for 5 min. 10 mL of 15M HCl was added and placed in oven for 2 hours. Final solution was filtered with syringe filter. Phenolics were separated using a shim-pack CLC-ODS (C-18) column, 25 cm × 4.6 mm, 5 μm. Mobile phase used was isocratic: ACN: Dichloro-methane: methanol- 60:20:20 at a flow rate of 1 mL/min. Samples were analysed using UV- Visible detector at 280 nm at room temperature while Kaempferol was separated at 248 nm (Sultana et al., 2008).

Statistical analysis: Statistical analysis was done with one-way ANOVA (analysis of variance). Results were showed by mean ± SE.

Results

Hepatoprotective effect of aqueous methanolic extract at 250 mg/kg and 500 mg/kg was determined by estimating ALT, AST, ALP and total bilirubin (Table I). The average value of ALT of normal animals was 50.2 ± 3.0 U/L. Treatment with paracetamol raised this value to 172.4 ± 6.2 U/L. Administration of aqueous methanolic extract of *R. dentatus* at dose of 250 mg/kg and 500 mg/kg brought the level of this enzyme to 101.0 ± 16.4 and 86.6 ± 11.6 U/L respectively which is comparable to (p<0.01, p<0.001) standard hepatoprotective drug, silymarin 61.0 ± 6.1. U/L The average value of AST of normal animals was 57.8 ± 3.4 U/L. Treatment with paracetamol raised this value to 167.4 ± 6.5 U/L. Administration of aqueous methanolic extract of *R. dentatus* at dose of 250 mg/kg and 500 mg/kg brought the level of this enzyme to 103.2 ± 14.0 and 95.6 ± 12.4 U/L respectively which is comparable to (p<0.01, p<0.001) standard hepatoprotective drug, silymarin 68.8 ± 2.81 U/L. The average value of ALP of normal animals was 173.6 ± 16.2 U/L. Treatment with paracetamol raised this value to 407.6 ± 36.4 U/L. Administration of aqueous methanolic extract of *R. dentatus* at dose of 250 mg/kg and 500 mg/kg brought the level of this enzyme to 219.4 ± 39.0 and 243.6 ± 19.0 U/L respectively which is comparable to (p<0.01, p<0.001) standard hepatoprotective drug, silymarin 190.4 ± 12.4 U/L. Similarly the average value of total bilirubin of normal animals was 0.7 ± 0.0 mg/dL. Treatment with paracetamol raised this value to 2.0 ± 0.2 mg/dL.

	ALT (U/L)	AST (U/L)	ALP (U/L)	Total bilirubin (mg/dL)
Normal	50.2 ± 3.0	57.8 ± 3.4	173.6 ± 16.2	0.7 ± 0.0
Paracetamol (250 mg/kg)	172.4 ± 6.2	167.4 ± 6.5	407.6 ± 36.4	2.0 ± 0.2
Silymarin (50 mg/kg) + Paracetamol (250 mg/kg)	61.0 ± 6.1 ^c	68.8 ± 2.8 ^c	190.4 ± 12.4 ^c	0.8 ± 0.0 ^c
Extract (250 mg/kg) + Paracetamol (250 mg/kg)	101.0 ± 16.4 ^b	103.2 ± 14.0 ^b	219.4 ± 39.0 ^b	1.0 ± 0.1 ^a
Extract (500 mg/kg) + Paracetamol (250 mg/kg)	86.6 ± 11.2 ^c	95.6 ± 12.4 ^c	243.6 ± 19.0 ^b	0.7 ± 0.0 ^b

Mean ± SE. is used to show the results; The results are compared by one-way ANOVA (analysis of Variance); Significant ^ap<0.05, ^bp<0.01, ^cp<0.001

Constituents	Aqueous methanolic
Tannins	+
Saponin	+
Flavonoids	+
Steroids	-
Terpenoids	+
Cardiac glycosides	+
Alkaloids	+
Anthraquinones	+

Compound	Retention time	Area(%)	Quantity (ppm)
Detection at 280 nm			
Chlorogenic acid	2.3	1.1	69.3
Quercetin	2.7	24.7	112.4
Myricetin	14.9	1.9	60.2
Vitamin C	23.2	5.5	16.6
Detection at 248 nm			
Kaempferol	2.6	3.6	1100.8

Administration of aqueous methanolic extract of *R. dentatus* at dose of 250 and 500 mg/kg brought the level of this enzyme to 1.0 ± 0.1 and 0.7 ± 0.0 mg/dL respectively which is comparable to (p<0.05, p<0.001) standard hepatoprotective drug, silymarin 0.8 ± 0.0 mg/dL.

The phytochemical screening shows the presence of tannins, saponin, flavonoids (Table II).

Histopathology studies showed that the liver architecture was normal in the control group. Sections reveal unremarkable lines, parenchyma comprised of portal triads, central vein and hepatocytes are arranged in cord separated by sinusoidal spaces. While the paracetamol-treated group showed the sever periportal inflammation and sever tissue necrosis. There was also sever blooming and dilation in sinusoidal spaces. Silymarin treated group showed only mild inflammation

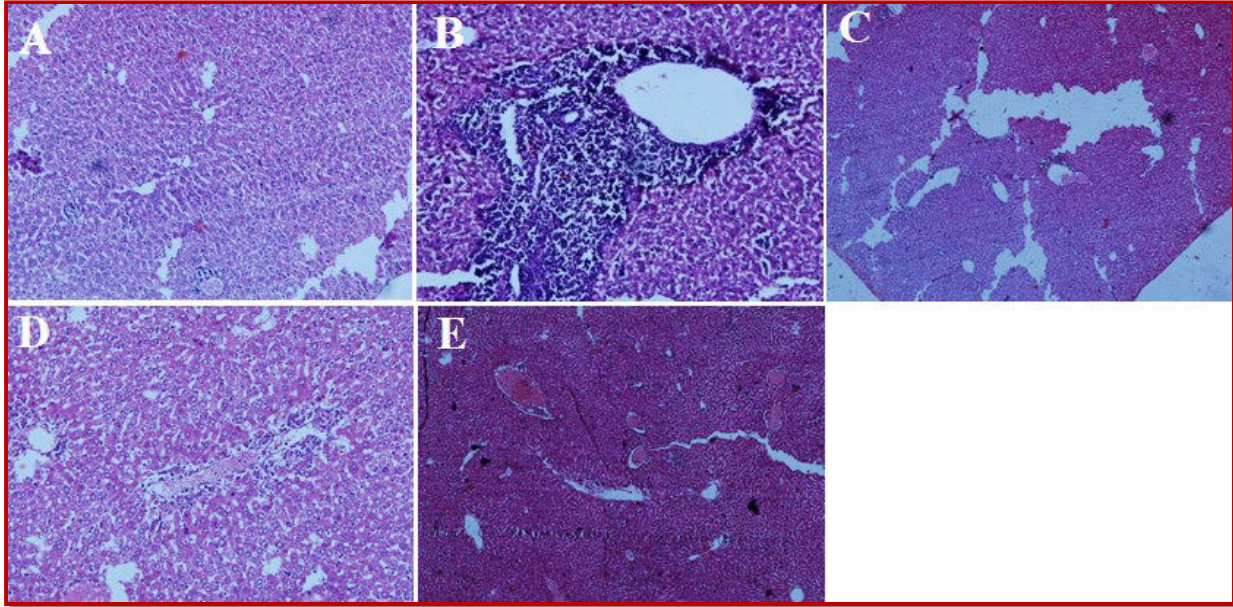


Figure 1: Histological picture of normal group (A), paracetamol-treated (B), silymarin-treated (C), *R. dentatus* extract 250 mg/kg (D), *R. dentatus* extract 500 mg/kg (E)

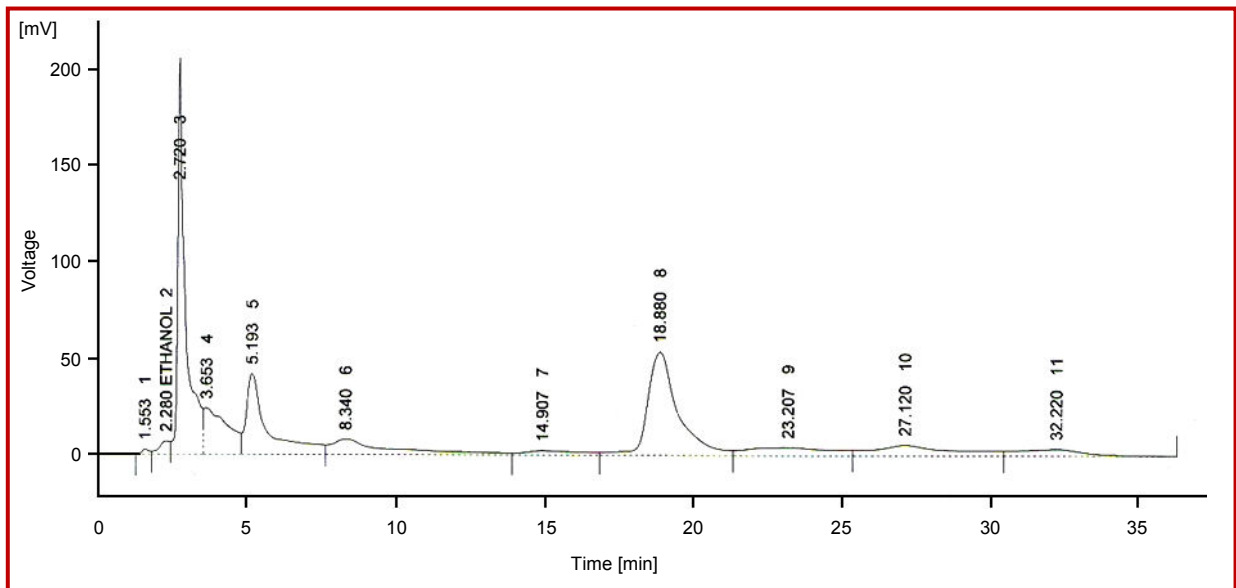


Figure 2: HPLC chromatogram detected at 280 nm

with no ballooning. Animals treated with aqueous methanolic extract of *R. dentatus* at 250 mg/kg showed mild inflammation with no ballooning while the animals treated at dose 500 mg/kg showed almost normal hepatocytes. Histopathological changes in liver architecture can be seen in Figure 1.

The HPLC chromatogram of *R. dentatus* showed the presence of chlorogenic acid, quercetin, myricitin, vitamin C and kaempferol (Figure 2 and 3; Table III).

Discussion

R. dentatus contains syringic acid, vanillin, benzoic acid, ferulic acid, cinnamic acid (Elzaaweil and Tawata,

2012). Preliminary phytochemical studies showed the presence of tannins, saponins, flavonoids, terpenoids, cardiac glycosides and alkaloids. Hepatoprotective action is found in cinnamic acid (Simonyan, 1993), ferulic acid (Srinivasan et al., 2007), saponins, (Kumar et al., 2011; Gujrati et al., 2007), syringic acid (Itoh et al., 2009) alkaloids (Gujrati et al., 2007; Vijayan et al., 2003), vinillin (Makni et al., 2011), tannins (Sathaya et al., 2011), anthraquinones (Arosio et al., 2008) and flavonoids (Vijay and Padmaa, 2011; Sahreen et al., 2011).

The current HPLC of *R. dentatus* showed the presence of chlorogenic acid, quercetin, myricitin, vitamin C and kaempferol. Among these isolated constituents myricitin (Rashid et al., 2013; Matic et al., 2013),

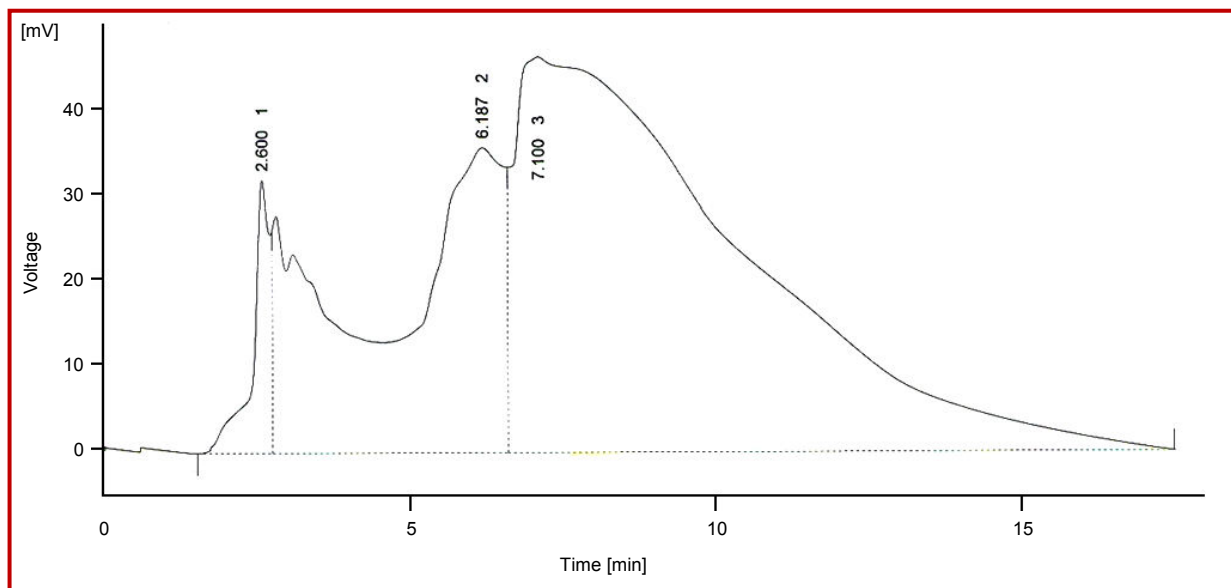


Figure 3: HPLC chromatogram detected at 248 nm

quercetin (Janbaz et al., 2004), kaempferol (Song et al., 2003), have been reported to have hepatoprotective activity. In present study the *R. dentatus* significantly control the elevation of liver enzymes and were comparable to standard hepatoprotective drug, silymarin. So, this hepatoprotective action may be due to presence of above constituents. However, *R. dentatus* looks more potent at 500 mg/kg. It is concluded that *R. dentatus* have significant hepatoprotective activity in aqueous methanolic extract.

References

- Ali M, Qadir MI, Saleem M, Janbaz KH, Gul H, Hussain L, Ahmad B. Hepatoprotective potential of *Convolvulus arvensis* against paracetamol-induced hepatotoxicity. *Bangladesh J Pharmacol.* 2013; 8: 300-04.
- Akhtar MS, Asjad HMM, Bashir S, Malik A, Khalid R, Gulzar F, Irshad N. Evaluation of anti-oxidant and hepatoprotective effects of Khamira Gaozaban Ambri Jadwar Ood Saleeb Wala (KGA). *Bangladesh J Pharmacol.* 2013; 8: 44-48.
- Arosio B, Gagliano N, Fusaro LMP, Parmeggiani L, Tagliabue J, Galetti P, Annoni G. Aloe-emodin quinone pretreatment reduces acute liver injury induced by carbon tetrachloride. *Pharmacol Toxicol.* 2008; 87: 229-33.
- Bag AK, Mumtaz SMF. Hepatoprotective and nephroprotective activity of hydroalcoholic extract *Oflpomoea staphylinia* leaves. *Bangladesh J Pharmacol.* 2013; 8: 263-68.
- Bate-Smith E. The phenolic constituents of plants and their taxonomic significance. I. Dicotyledons. *J Linn Soc Bot.* 1962; 58: 95-173.
- Elzaawely AA, Tawata S. Anti-oxidant capacity and phenolic content of *Rumex dentatus* L. Grown in Egypt. *J Crop Sci Biotech.* 2012; 15: 59-64.
- Fatima N, Zia M, Rehman R, Rizvi ZF, Ahmad S, Mirza B, Chaudhary MF. Biological activities of *Rumex dentatus* L: Evaluation of methanol and hexane extracts. *Afr J Biotechnol.* 2009; 8: 6945-51.
- Gnanadesigan M, Ravikumar S, Inbaneson SJ. Hepatoprotective and anti-oxidant properties of marine halophyte *Luminetzera racemosa* bark extract in CCL4-induced hepatotoxicity. *Asian Pac J Trop Med.* 2011; 4: 462-65
- Girish C, Koner BC, Jayanthi S, Ramachandra RK, Rajesh B, Pradhan SC. Hepatoprotective activity of picroliv, curcumin and ellagic acid compared to silymarin on paracetamol induced liver toxicity in mice. *Fundam Clin Pharmacol.* 2009; 23: 735-45.
- Gujrati V, Patel N, Rao VN, Nandakumar K, Gouda T. Hepatoprotective activity of alcoholic and aqueous extracts of leaves of *Tylophora indica* (Linn.) in rats. *Indian J Pharmacol.* 2007; 39: 43.
- Hameed I, Dastagir G. Nutritional analyses of *Rumex hastatus* D. Don, *Rumex dentatus* Linn and *Rumex nepalensis* Spreng. *Afr J Biotechnol.* 2009; 8: 4131-33.
- Heibatollah S, Mohammad Reza N, Izadpanah G and Sohailla S. Hepatoprotective effect of *Cichorium intybus* on CCL4-induced liver damage in rats. *Afr J Biochem Res.* 2008; 2: 141-44
- Hussain F, Ahmad B, Hameed I, Dastagir G, Sanaullah P, Azam S. Antibacterial, antifungal and insecticidal activities of some selected medicinal plants of polygonaceae. *Afr J Biotechnol.* 2010; 9: 5032-36.
- Itoh A, Isoda K, Kondoh M, Kawase M, Kobayashi M, Tamesada M, Yagi K. Hepatoprotective effect of syringic acid and vanillic acid on concanavalin A-induced liver injury. *Biol Pharm Bull.* 2009; 32: 1215-19.
- Janbaz K, Saeed S, Gilani A. Studies on the protective effects of caffeic acid and quercetin on chemical-induced hepatotoxicity in rodents. *Phytomedicine.* 2004; 11: 424-30.
- Kumar B, Lakshman K, Swamy V, Kumar P, Shekar D, Manoj B, Vishwantha G. Hepatoprotective and anti-oxidant activities of *Amaranthus viridis* Linn. *Macedonian J Med Sci.* 2011; 4: 125-30.
- Litvinenko YA, Muzychikina R. Phytochemical investigation of

- biologically active substances in certain Kazakhstan *Rumex* species. Chem Nat Compd. 2003; 39: 446-49.
- Makni M, Chtourou Y, Fetoui H, Garoui EM, Boudawara T, Zeghal N. Evaluation of the anti-oxidant, anti-inflammatory and hepatoprotective properties of vanillin in carbon tetrachloride-treated rats. Eur J Pharmacol. 2011; 668: 133-39.
- Matić S, Stanić S, Bogojević D, Vidaković M, Grdović N, Dinić S, Mihailović M. Methanol extract from the stem of *Cotinus coggygria* Scop., and its major bioactive phytochemical constituent myricetin modulate pyrogallol-induced DNA damage and liver injury. Mutat Res-Gen Tox En. 2013; 755: 81-89.
- Manandhar N. Plants and people of Nepal timber press. Oregon 2002; 192: 527-26.
- Mojab F, Kamalinejad M, Ghaderi N, Vahidipour HR. Phytochemical screening of some species of Iranian plants. IJPR. 2003; 4: 77-82.
- Raju K, Anbuganapathi G, Gokulakrishnan V, Rajkapoor B, Jayakar B, and Manian M. Effect of dried fruits of *Solanum nigrum* Linn against CCl₄-induced hepatic damage in rats. Biol Pharm Bull. 2003; 26: 1618-19.
- Setty SR, Quereshi AA, Swamy AHMV, Patil T, Prakash T, Prabhu K, Gouda AV. Hepatoprotective activity of *Calotropis procera* flowers against paracetamol-induced hepatic injury in rats. Fitoterapia 2007; 78: 451-54.
- Rashed KN, Chang CW, Wu LY, Peng WH. Hepatoprotective activity of *Diospyros lotus* fruits on acute liver injury induced by carbon tetrachloride and phytochemical analysis. Topcls J Herb Med. 2013; 2: 75-83.
- Ravikumar S, Gnanadesigan M. Hepatoprotective and Anti-oxidant Properties of *Rhizophora mucronata* plant in CCl₄ Intoxicated Rats. J Exp Clin Med. 2012; 4: 66-72.
- Rehman JU, Saqib NU, Akhtar N, Jamshaid M, Asif HM, Sultana S, Rehman RU. Hepatoprotective activity of aqueous-methanolic extract of *Suaeda fruticosa* in paracetamol-induced hepatotoxicity in rabbits. Bangladesh J Pharmacol. 2013; 8: 378-81.
- Sabir S, Rocha J. Water-extractable phytochemicals from *Phyllanthus niruri* exhibit distinct *in vitro* anti-oxidant and *in vivo* hepatoprotective activity against paracetamol-induced liver damage in mice. Food Chem. 2008; 111: 845-51.
- Saboo SS, Tapadiya G, Farooqui IA, Khadabadi SS. Free radical scavenging, *in vivo* anti-oxidant and hepatoprotective activity of folk medicine *Trichodesma sedgwickianum*. Bangladesh J Pharmacol. 2013; 8: 58-64.
- Sahreem S, Khan MR, Khan RA. Hepatoprotective effects of methanol extract of *Carissa opaca* leaves on CCl₄-induced damage in rat. BMC Complem Altern Med. 2011; 11: 48.
- Saleem M, Ahmed B, Qadir MI, Karim M, Rafiq M, Ahmad M, Ahmad B. Hepatoprotective effect of *Chenopodium murale* in mice. Bangladesh J Pharmacol. 2014; 9: 124-28.
- Sathaye S, Bagul Y, Gupta S, Kaur H, Redkar R. Hepatoprotective effects of aqueous leaf extract and crude isolates of *Murraya koenigii* against *in vitro* ethanol-induced hepatotoxicity model. Exp Toxicol Pathol. 2011; 63: 587-91.
- Samuel AJSJ, Mohan S, Chellappan DK, Kalusalingam A, Ariamuthu S. *Hibiscus vitifolius* (Linn.) root extracts shows potent protective action against anti-tubercular drug induced hepatotoxicity. J Ethnopharmacol. 2012; 141: 396-402.
- Sharma PP, Roy RK, Anurag GD. Pentacyclic triterpenoids from *Betula utilis* and *Hyptis suaveolens*. IJPTR. 2010; 1558-32.
- Simonyan A. Activity of cinnamic acid derivatives and new methods for their synthesis. Pharm Chem J. 1993; 27: 92-100.
- Sofowora. Medicinal plants and traditional medicine in Africa. New York, John Wiley and Sons Ltd, 1993.
- Song LR, Hu L. *Rumex dentatus*. Traditional Chinese herb. 1st ed. Shanghai, Science and Technology Publisher, 1999, p 727.
- Song EK, Kim JH, Kim JS, Cho H, Nan JX, Sohn DH, Ko GI, Oh H, Kim YC. Hepatoprotective phenolic constituents of *Rhodiola sachali-nensis* on tacrine-induced cytotoxicity in Hep G2 cells. Phytother Res. 2003; 17: 563-65.
- Srinivasan M, Sudheer AR, Menon VP. Ferulic acid: Therapeutic potential through its anti-oxidant property. J Clin Biochem Nutr. 2007; 40: 92.
- Sultana B, Anwar F, Rafique AM, Chatha SAH. Anti-oxidant potential of extracts from different agro wastes: Stabilization of corn oil. Grasasy Aceites, 2008; 59: 205-17.
- Süleyman H, Demirezer L Ö, Kuruüzüm A, Banoğlu Z, Göçer F, Özbakir G, Gepdiremen A. Antiinflammatory effect of the aqueous extract from *Rumex patientia* L roots. J Ethnopharmacol. 1999; 65: 141-48.
- Umer A, Yousaf Z, Khan F, Hussain U, Anjum A, Nayyab Q, Younas A. Evaluation of allelopathic potential of some selected medicinal species. Afr J Biotechnol. 2010; 9: 6194-206.
- Vijay N, Padmaa M. Hepatoprotective activity of *Chenopodium album* Linn. against paracetamol induced liver damage. Pharmacologyonline 2011; 3: 312-28.
- Vijayan P, Prashanth H, Vijayaraj P, Dhanaraj S, Badami S, Suresh, B. Hepatoprotective effect of the total alkaloid fraction of *Solanum pseudocapsicum* leaves. Pharma Biol. 2003; 41: 443-48.
- Zhang H, Guo Z, Wu N, Xu W, Han L, Li N, Han Y. Two novel naphthalene glucosides and an anthraquinone isolated from *Rumex dentatus* and yheir anti-proliferation activities in four cell lines. Molecules 2012; 17: 843-50.

Author Info

Mohammad Saleem (Principal contact)
e-mail: saleem2978@hotmail.com