

Turkish Journal of Cerebrovascular Diseases 2019; 25 (1): 31-36
doi: 10.5505/tbdhd.2019.05668

Türk Beyin Damar Hastalıkları Dergisi 2019; 25 (1): 31-36

ORIGINAL ARTICLE

ARAŞTIRMA YAZISI

DECOMPRESSIVE HEMICRANIECTOMY IN ACUTE ISCHEMIC STROKE

İrem İLGEZDİ*, Levent ÖCEK**, Lütfiye Asena BİNYAY***, Metin Murat ÖZÇELİK***, Burak KINALI****, Ufuk SENER***, Figen TOKUCOĞLU***, Yasar ZORLU***

* Giresun University Prof. Dr. A. İlhan Özdemir Training and Research Hospital, Neurology Clinic, Giresun, TURKEY

** Uşak University Training and Research Hospital, Neurology Clinic, Uşak, TURKEY

*** İzmir Tepecik Training and Research Hospital, Neurology Clinic, İzmir, TURKEY

**** İzmir Tepecik Training and Research Hospital, Neurosurgery Clinic, İzmir, TURKEY

ABSTRACT

INTRODUCTION: Cerebral edema is the leading cause of mortality and morbidity in ischemic stroke patients. Decompressive hemicraniectomy may be beneficial to patients that fail to respond to medical treatment. In this study, clinical features and prognostic factors of patients that underwent decompressive hemicraniectomy due to acute ischemic stroke were evaluated.

METHODS: We examined 21 ischemic stroke patients who underwent decompressive hemicraniectomy. Demographic features and neuroimaging findings were recorded. Functional status of patients were evaluated with modified Rankin Scale. Clinical features and neuroimaging findings of the patients who died were compared with the survivors during hospitalization.

RESULTS: Twenty-one patients were included in this study. Twelve of the patients were male, 9 were female. The mean age of these patients was 58.7±8.2 (46 - 78). The main initial NIHSS score was 12.5±4.5. Territory of infarctions were supplied by middle cerebral artery in 17 patients, internal carotid artery in 4 patients. The mean time of decompressive hemicraniectomy was 2.9±2.5 days, hospitalization duration was 42.6±39.2 days. Five (% 23.8) patients died in-hospital. There were no relation between clinical features, neuroimaging findings and mortality.

DISCUSSION and CONCLUSION: Decompressive hemicraniectomy is a significant treatment option for ischemic stroke patients who deteriorate despite receiving medical treatment.

Keywords: Stroke, decompressive hemicraniectomy, ischemia, morbidity, mortality, modified Rankin scale.

AKUT İSKEMİK İNMEDE DEKOMPRESİF HEMİKRANİYEKTOMİ

ÖZET

GİRİŞ ve AMAÇ: İskemik inme hastalarında gelişen serebral ödem mortalite ve morbiditenin en önemli nedenidir. Medikal tedaviye cevap alınamayan hastalarda dekompresif hemikraniyektomi yararlı olabilir. Bu yazıda, kliniğimizde akut iskemik inme nedeniyle dekompresif hemikraniyektomi uygulanan hastaların klinik özellikleri ve prognoz ile ilişkili faktörler değerlendirilmiştir.

YÖNTEM ve GEREÇLER: Bu çalışmaya iskemik inme nedeni ile dekompresif hemikraniyektomi uygulanan 21 hasta alındı. Hastaların demografik özellikleri ile görüntüleme bulguları kaydedildi. Hastaların fonksiyonel durumu modifiye Rankin Skalası ile değerlendirildi. Hastanedeki izlem süresinde eksitus olan ve yaşayan hastaların klinik özellikleri ve görüntüleme bulguları karşılaştırıldı.

BULGULAR: Çalışmaya 12'si erkek, 9'u kadın, yaş ortalaması 58.7±8.2 (46 - 78) olan 21 hasta alındı. Hastaların başvuru NIHSS skoru ortalaması 12.5±4.5 idi. İnfarkt 17 hastada orta serebral arter, 4 hastada internal karotis arter alanındaydı. Dekompresif hemikraniyektomi uygulama zamanı ortalama 2.9±2.5 gün ve hastanede ortalama kalış süresi 42.6±39.2 gün idi. Hastanedeki izlem süresinde beş (% 23.8) hasta eksitus oldu. Dekompresif hemikraniyektomi uygulanan hastalarda klinik özellikler ve görüntüleme bulguları mortalite ile ilişkili bulunmadı.

TARTIŞMA ve SONUÇ: İskemik inmede dekompresif hemikraniyektomi medikal tedavi uygulanmasına rağmen kötüleşen hastalarda önemli bir tedavi seçeneğidir.

Anahtar Sözcükler: İnme, dekompresif hemikraniyektomi, iskemi, morbidite, mortalite, modifiye Rankin skalası.

Corresponding author: İrem İlgezdi. Giresun University Prof. Dr. A. İlhan Özdemir Training and Research Hospital, Neurology Clinic, Giresun, TURKEY.

Telephone: +90454 310 20 00

E-mail: iremilgezdi@yahoo.com

Received: 22.01.2019

Accepted: 01.04.2019

This article should be cited as following: İlgezdi İ, Öcek L, Binyay L.A, Özçelik M.M, Kınalı B, Sener U, Tokuçoğlu F, Zorlu Y. Decompressive hemicraniectomy in acute ischemic stroke. Turkish Journal of Cerebrovascular Diseases 2019; 25 (1): 31-36. doi: 10.5505/tbdhd.2019.05668

INTRODUCTION

Large supratentorial hemispheric infarcts (malignant infarcts) constitute 1-10% of all supratentorial infarcts. In these infarcts, the brain edema develops in a few days and 80% of the patients have a fatal course despite medical treatment (1). Decompressive hemicraniectomy (DH) may be a life-saving treatment for these patients. The age of the patient, time of surgery and the lateralization of the infarct are controversial issues in DH procedure. In this paper, clinical features of the patients who were treated with DH due to acute ischemic stroke and the factors relating to the prognosis were evaluated.

MATERIAL AND METHODS

In this study, data of 21 patients who were followed-up with the diagnosis of ischemic stroke between January 2012 and January 2018 and who were treated with DH due to the development of brain edema despite medical treatment were evaluated retrospectively. The patients who were treated with DH due to infarct in the middle cerebral artery or internal carotid artery area were included in the study. The patients were followed up in the Neurology Intensive Care Unit in the postoperative period.

Patients' demographic characteristics, ischemic stroke risk factors, infarct localization and lateralization, the prognosis during time after stroke until DH is performed and during the follow-up period in the hospital were recorded. Hypertension, diabetes mellitus, hyperlipidemia, atrial fibrillation, coronary artery disease and past ischemic stroke were recorded as the risk factors of ischemic stroke. The neurological status of the patients at the first application was evaluated with the National Institute of Health Stroke Scale (NIHSS) score. The presence of a midline shift of the septum pellucidum on CT was evaluated and recorded in mm. In case of presence of midline shift and/or clinical progression, neurosurgery department was consulted and decompressive hemicraniectomy was so decided. The functional status of the patients while discharge was evaluated using modified Rankin Scale (mRS). mRS >3 was considered as poor prognosis. Clinical features and imaging findings of exitus and surviving patients were compared.

Statistical Package for Social Science (SPSS v.20; IBM Corp. Armonk, NY;USA. Released 2011)

software was used for statistical analysis. Descriptive statistical method was used for standard deviation, mean, minimum and maximum values and frequency values. The qualitative analysis was evaluated by T-test in independent samples. $P < 0.05$ was considered as significance level.

RESULTS

The clinical features and imaging findings of the patients were given in Table I. Twelve (57.1%) of the patients were males and 9 (42.9%) were female. The mean age was 58.7 ± 8.2 (46 - 78). Ten of the patients (47.6%) were younger than 60 years.

The infarction was in the middle cerebral artery in 17 (80.9%) patients and in the internal carotid artery in 4 patients. Eleven patients (52.4%) had infarct in the left hemisphere, while 10 (47.6%) patients had in the right hemisphere. Two patients were treated with thrombolytic therapy.

Nine patients (42.8%) had hypertension, 6 patients (28.6%) had coronary artery disease, 6 patients (28.6%) had past ischemic stroke, 5 patients (23.8%) had diabetes mellitus, 3 patients (14.3%) had atrial fibrillation and 8 patients (38%) had hyperlipidemia as stroke risk factors.

The NIHSS score of the patients at the time of application was between 4 and 24 (12.5 ± 4.5). All patients were treated with an extensive hemicraniectomy and duraplasty (Figure). The time of DH application was averagely 2.9 ± 2.5 (1-11) days. DH was performed for 7 patients (33.3%) on 1st day, for 6 patients (28.6%) on 2nd day, for 3 patients (14.3%) on 3rd day, and for 3 patients (14.3%) on 4th day. DH was performed on the 7th of initial ischemic stroke for one patient, and on 11th day for one patient. The reason for the application of DH in these patients was type 2 hemorrhagic transformation and the development of brain edema.

Six patients (28.6%) had no midline shift in CT. The shift was between 2 and 15 mm (8.06 ± 3.5) in the patients with midline shift.

None of the patients developed intracranial and / or wound infections. Three (14.3%) patients had post-DH hemorrhagic transformation.

The average hospitalization period of the patients was 42.6 ± 39.2 (6-154) days. Five (23.8%) patients died during the follow-up in the hospital.

The mRS was ≤ 3 for 6 (28.5%) patients during discharge. Gender ($p=0.338$), age ($p=0.182$), lateralization of the infarction ($p=0.149$), NIHSS score at the application ($p=0.165$), presence of a midline shift ($p=0.598$), having intravenous thrombolytic therapy applied ($p=1.000$), time passed until DH is performed ($p=0.142$), duration of hospitalization ($p=0.433$), having post-DH hemorrhagic transformation ($p=0.549$) were not found associated with the

mortality (Table II). The mRS ≤ 3 during discharge, gender ($p=0.523$), age ($p=0.691$), lateralization of the infarction ($p=0.635$), NIHSS score at the application ($p=0.906$), time passed until DH is performed ($p=0.281$), having post-DH hemorrhagic transformation ($p=0.526$), presence of a midline shift ($p=0.623$), having intravenous thrombolytic therapy applied ($p=0.500$) and duration of hospitalization ($p=0.433$) were not found associated (Table II).

Table I. The clinical features and imaging findings of the patients.

	Gender	Age	Infarct		rTPA	Shift (mm)	Hemorrhagic Transformation	DH day	Hospitalization day	NIHSS First	mRS
			Artery	Side							
1	E	59	ICA	Left	-	15	-	2	116	17	4
2	M	60	MCA	Right	-	10	+	1	104	24	4
3	K	47	MCA	Right	-	5	-	2	84	18	4
4	M	60	MCA	Left	-	0	-	4	40	4	4
5	M	63	ICA	Right	-	0	-	1	45	16	6
6	F	52	ICA	Right	-	6	-	1	16	11	3
7	M	57	MCA	Left	-	3	-	4	30	16	3
8	F	47	MCA	Left	-	2	-	2	17	12	3
9	M	65	MCA	Left	-	7.5	-	3	15	14	3
10	F	68	ICA	Right	-	12	-	1	32	13	6
11	F	60	MCA	Left	-	7	-	1	15	13	3
12	M	55	MCA	Left	+	0	+	2	33	9	4
13	F	49	MCA	Left	-	11	+	7	14	12	4
14	M	69	MCA	Left	-	7	-	2	14	11	6
15	F	78	MCA	Right	-	12	-	3	154	13	5
16	F	61	MCA	Right	-	0	-	4	19	15	5
17	M	51	MCA	Right	-	0	-	3	6	8	6
18	F	46	MCA	Left	-	9	-	1	17	12	4
19	M	64	MCA	Right	+	0	-	1	37	10	3
20	M	57	MCA	Left	-	7	-	2	32	12	5
21	M	64	MCA	Right	-	7.5	-	11	18	8	6

*M: Male, F: Female, ICA: internal carotid artery, MCA: middle cerebral artery, DH: decompressive hemicraniectomy, mRS: modified Rankin score

Table II. The relation of clinical and imaging features with the mortality and prognosis.

	Exitus n=5	Survival n=16	P	mRS ≤ 3 n=6	mRS > 3 n=15	P
Gender (male/female)	4/1	8/8	0.338	3/3	9/6	0.523
Age, year	63 \pm 7.1	57 \pm 8.2	0.182	57.5 \pm 7.0	59.1 \pm 8.8	0.691
Infarct lateralization (right/left)	4/1	6/10	0.149	2/4	8/7	0.635
Midline shift (+/-)	3/2	12/4	0.598	5/1	10/5	0.623
NIHSS score at application	10.0 \pm 4.4	13.2 \pm 4.3	0.165	12.6 \pm 2.1	12.4 \pm 5.2	0.906
Thrombolytic therapy	0/5	2/14	1.000	1/5	1/14	0.500
Time passed until DH is performed (day)	4.40 \pm 4.21	2.50 \pm 1.63	0.142	2.0 \pm 1.26	3.33 \pm 2.79	0.281
Hospitalization period (day)	30.2 \pm 18.3	46.4 \pm 43.4	0.433	21.6 \pm 9.4	50.9 \pm 43.5	0.125
Having hemorrhagic transformation	0/5	3/13	0.549	0/6	3/12	0.526

*NIHSS: National Institutes of Health Stroke Scale, DH: decompressive hemicraniectomy, mRS: modified Rankin score

DISCUSSION

The DH efficacy was evaluated in three randomized controlled studies (DESTINY I, DECIMAL, HAMLET). In DESTINY I study, the mortality rate within first 30 days was reported as 12% in the patients who were treated with DH due

to malignant middle cerebral infarction, as 53% in the patients who were treated with medical treatment (MT); and the ratio of patients with mRS ≤ 3 after 6 and 12 months was reported as 47% with DH and as 27% with MT (2). In DECIMAL

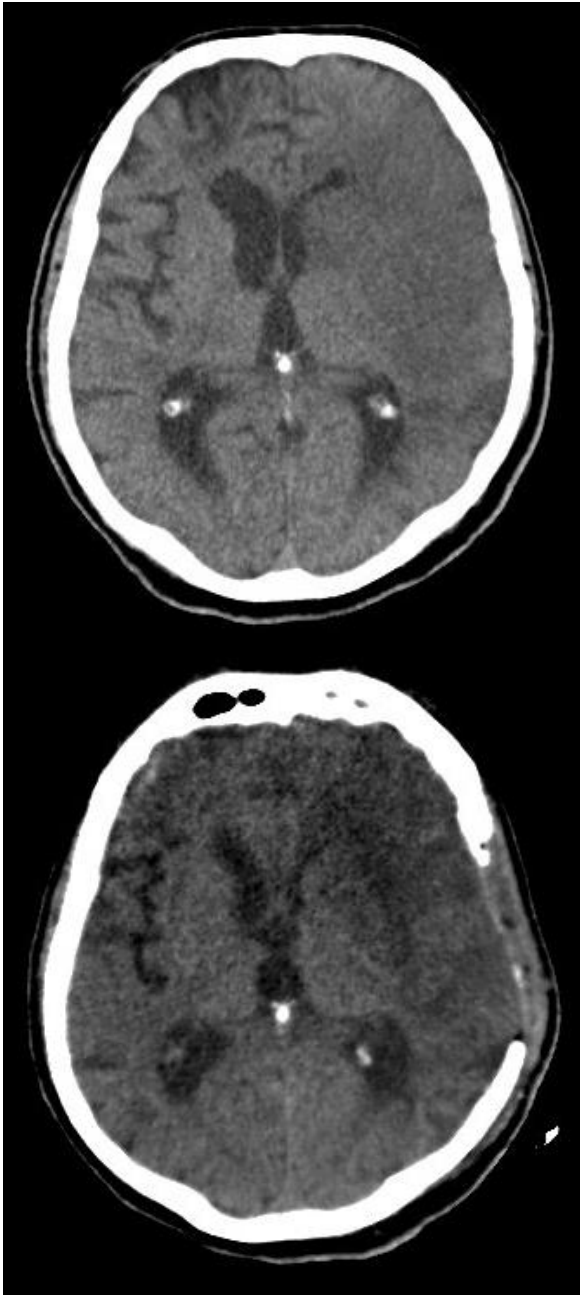


Figure. Pre and post-surgery CT images of patient received decompressive hemicraniectomy due to left middle cerebral artery infarction.

study, it was stated that 52.8% reduction was ensured in the mortality ratio with DH application and the ratio of the patients with mRS ≤ 3 at the end of first year was 50% with DH and 22.2% with MT (3). In HAMLET study, the mortality ratio at the end of first year was found as 22% in the patients treated with DH and as 59% in those treated with MT, and the ratio of the patients with

mRS > 4 was 41% with DH and 59% with MT (4). It was reported in the meta-analysis in which the data of these three studies were evaluated that the mortality decreased with DH and the number of patients with good prognosis increased (5). The benefit of DH was also supported in the meta-analyses published in the further years (6-8). In HeADDFIRST study published in 2014, the mortality rate in 21 days was found lesser (21% with DH, 40% with MT) in the patients treated with DH. 23.8% of our patients died during hospital follow-up period. Huang et al. reported a similar mortality ratio (28.2%) in their study.

The age of the patient, time of surgery and the lateralization of the infarct are controversial points in DH procedure.

Elderly patients were not included in the first randomized controlled studies (For DECIMAL study >55 years, for DESTINY I and HAMLET studies >60 years) (2-4). In some studies conducted later, it was reported that DH decreased mortality in elderly patients (11,12), but major disability was more frequent in surviving patients (8,13,14). This opinion was not supported in many studies. In DESTINY II study, the mortality ratio for the patients older than 61 years and treated with DH was found lesser (33% with DH and 70% with MT), while the ratio of surviving patients without serious disability was higher (38% with DH and 18% with MT) (15). Zhao et al. reported that DH treated within 48 hours is not only a life-saving treatment in elderly patients, but also increases the survival chance without serious disability (11). 10 patients treated with DH (47.6%) was younger than 60 years. The mortality ratio was 10.4% (1/10) in these patients while it was 36.4% (4/11) in our patients aged 60 years and over. However, no statistically significant relationship was found between age and mortality ($p=0.182$).

The most appropriate time for performing DH in ischemic strokes is controversial. It is reported that, in case it is performed late, the benefit will reduce as the brain damage progressed, and in case it is performed early, there is a possibility of unnecessary surgery. Patients treated with DH within first 43 hours were included in DECIMAL study (3), followed by patients within 36 hours in DESTINY I study (2) and patients within 96 hours in HAMLET study (4). It was reported in the meta-analysis in which the data of these three studies were evaluated that the mortality decreased with DH treated within first 48 hours and the ratio of patients with mRS 0-3 was higher after 12

months (5). There is no consensus on the benefit of DH applied much later. In some studies, it was reported that the duration between stroke and DH is not related to the prognosis (16,17). In some studies, it was stated that DH applied after 48 hours does not have any benefit (4,7). Dasenbrock et al. reported that a DH applied earlier is associated with a better prognosis, however it does not affect the mortality during follow-up in the hospital (18). DH was performed within first 48 hours for 61.9% of our patients, and the mortality ratio for these patients was 23.1% (3/13). 2 out of 8 patients (25%) who were treated with DH in a later time period died. No statistically significant relation was found between the mortality ratio during the follow-up in the hospital and the time passed until performing DH ($p=0.142$).

Although some studies reported that the right hemisphere infarcts have a better prognosis (19), this opinion was not supported in other studies (1). Doau et al. reported in their study that the poor prognosis ratio in 90 days is higher in dominant hemisphere infarcts, however the cerebral dominance was not associated with the prognosis in the latest follow-up (20). In our study, 4 out of 10 patients having right hemisphere infarct and 1 out of 11 patients having left hemisphere infarcts died, and no relation was found between the lateralization of infarct and the mortality ($p=0.149$).

No relation was found between presence of stroke risk factors and the prognosis (1,21) in many studies, while past stroke (20), diabetes mellitus (16,20), hypertension (16) were found related to the poor prognosis in some studies. Another finding reported to be associated with poor prognosis is the shift of the septum pellucidum more than 10 mm from the midline (16,20,22). Six (28.6%) of our patient had no midline shift and 2 of these patients (33.3%) died, while 3 out of 15 patients (20%) having midline shift died and the presence of midline shift was not found associated with the mortality ($p=0.598$).

Two patients received intravenous thrombolytic therapy before DH and thrombolytic therapy was not associated with mortality ($p=1,000$). In some studies, it has been reported that intravenous thrombolytic therapy does not affect prognosis in patients who were treated with DH (23). It was reported that hemorrhagic transformation developed in 52-59 % of the

patients who were treated with DH, however the hemorrhagic transformation did not affect prognosis (23,24). Three patients had post-DH hemorrhagic transformation and the hemorrhagic transformation was not found associated with mortality ($p=0.549$).

The mRS ≤ 3 during discharge, gender ($p=0.523$), age ($p=0.691$), lateralization of the infarction ($p=0.635$), NIHSS score at the application ($p=0.906$), time passed until DH is performed ($p=0.281$), having post-DH hemorrhagic transformation ($p=0.526$), presence of a midline shift ($p=0.623$), having intravenous thrombolytic therapy applied ($p=0.500$) and duration of hospitalization ($p=0.125$) were not found associated.

Complications of DH are hemorrhage, infection, cerebrospinal fluid escape, hydrocephalus, cardiac and pulmonary complications (25). The most common complication developed in our patients was infection.

In conclusion, DH may be beneficial for the adult patients from all ages having ischemic stroke who worsen despite medical treatments.

REFERENCES

1. Bansal H, Chaudhary A, Singh A ve ark. Decompressive craniectomy in malignant middle cerebral artery infarct: An institutional experience. *Asian J Neurosurg* 2015;10:203-06.
2. Jüttler E, Schwab S, Schmiedek P ve ark. ; DESTINY study group. Decompressive surgery for the treatment of malignant infarction of the middle cerebral artery (DESTINY): A randomized, controlled trial. *Stroke* 2007;38:2518-25.
3. Vahedi K, Vicaut E, Mateo J ve ark., on behalf of the DECIMAL investigators. Sequential-design, multicenter, randomized, controlled trial early decompressive craniectomy in malignant middle cerebral artery infarction (DECIMAL trial). *Stroke* 2007a;38:2506-17.
4. Hofmeijer J, Kappelle LJ, Algra A ve ark., for the HAMLET investigators. Surgical decompression for space-occupying cerebral infarction (the hemicraniectomy after middle cerebral artery infarction with life-threatening edema trial [HAMLET]): A multicentre, open, randomised trial. *Lancet Neurol* 2009;8:326-33.
5. Vahedi K, Hofmeijer J, Juettler E ve ark.; DECIMAL, DESTINY, and HAMLET investigators. Early decompressive surgery in malignant infarction of the middle cerebral artery: a pooled analysis of three randomised controlled trials. *Lancet Neurol* 2007b;6:215-22.
6. Alexander P, Heels-Ansdell D, Siemieniuk R ve ark. Hemicraniectomy versus medical treatment with large MCA infarct: a review and meta-analysis. *BMJ Open* 2016;6:e014390.
7. Lu X, Huang B, Zheng J ve ark. Decompressive craniectomy for the treatment of malignant infarction of the middle cerebral artery. *Sci Rep* 2014;4:7070.

8. Mohan Rajwani K, Crocker M, Moynihan B. Decompressive craniectomy for the treatment of malignant middle cerebral artery infarction. *Br J Neurosurg* 2017;31:401-09.
9. Frank JI, Schumm LP, Wroblewski K ve ark.; HeADDFIRST trialists. Hemicraniectomy and durotomy upon deterioration from infarction-related swelling trial: A randomized pilot clinical trial. *Stroke* 2014;45:781-87.
10. Huang P, Lin FC, Su YF ve ark. Predictors of in-hospital mortality and prognosis in patients with large hemispheric stroke receiving decompressive craniectomy. *Br J Neurosurg* 2012;26:504-09.
11. Zhao J, Su YY, Zhang Y ve ark. Decompressive hemicraniectomy in malignant middle cerebral artery infarct: a randomized controlled trial enrolling patients up to 80 years old. *Neurocrit Care* 2012;17:161-71.
12. Dasenbrock HH, Robertson FC, Aziz-Sultan MA ve ark. Patient age and the outcomes after decompressive hemicraniectomy for stroke: A nationwide inpatient sample analysis. *Neurocrit Care* 2016;25:371-83.
13. Ragoschke-Schumm A, Junk C, Lesmeister M ve ark. Retrospective consent to hemicraniectomy after malignant stroke among the elderly, despite impaired functional outcome. *Cerebrovasc Dis* 2015;40:286-92.
14. Park J, Son W, Lee J. Critical age affecting functional outcome after decompressive hemicraniectomy for malignant hemispheric infarction. *World Neurosurg* 2016;93:104-10.
15. Jüttler E, Unterberg A, Woitzik J ve ark., for the DESTINY II investigators. Hemicraniectomy in older patients with extensive middle cerebral artery stroke. *N Engl J Med* 2014;370:1091-100.
16. Kamran S, Akhtar N, Salam A ve ark. Decompressive hemicraniectomy for malignant middle cerebral artery stroke: South Asian experience. *J Stroke Cerebrovasc Dis* 2017b;26:2306-12.
17. Kamran S, Akhtar N, Salam A ve ark. Revisiting hemicraniectomy: late decompressive hemicraniectomy for malignant middle cerebral artery stroke and the role of infarct growth rate. *Stroke Res Treat* 2017c;2507834.
18. Dasenbrock HH, Robertson FC, Vaitkevicius H ve ark. Timing of decompressive hemicraniectomy for stroke. A nationwide inpatient sample analysis. *Stroke* 2017;48:704-11.
19. Paliwal P, Kazmi F, Teoh HL ve ark. Early decompressive hemicraniectomy for malignant middle cerebral artery infarction in Asian patients: A single-center study. *World Neurosurg* 2018;111:e722-e728.
20. Daou B, Kent AP, Montano M ve ark. Decompressive hemicraniectomy: predictors of functional outcome in patients with ischemic stroke. *J Neurosurg* 2016;124:1773-79.
21. Hao Z, Chang X, Zhou H ve ark. A cohort study of decompressive craniectomy for malignant middle cerebral artery infarction. *Medicine* 2015;94:e1039.
22. Kamran S, Salam A, Akhtar N ve ark. Predictors of in-hospital mortality after decompressive hemicraniectomy for malignant ischemic stroke. *J Stroke Cerebrovasc Dis* 2017a;26:1941-47.
23. Yoo BR, Yoo CJ, Kim MJ ve ark. Analysis of the outcome and prognostic factors of decompressive craniectomy between young and elderly patients for acute middle cerebral artery infarction. *J Cerebrovasc Endovasc Neurosurg* 2016;18:175-84.
24. Al-Jehani H, Petrecca K, Martel P ve ark. Decompressive craniectomy for ischemic stroke: effect of hemorrhagic transformation on outcome. *J Stroke Cerebrovasc Dis* 2016;25:2177-83.
25. Zweckberger K, Juettler E, Bösel J ve ark. Surgical aspects of decompression craniectomy in malignant stroke: review. *Cerebrovasc Dis* 2014;38:313-23.