

DOI: <https://doi.org/10.5114/pjr.2019.84829>

Received: 17.11.2018
Accepted: 18.02.2019
Published: 15.04.2019

<http://www.polradiol.com>

Original paper

Endovascular treatment of small (< 5 mm) unruptured middle cerebral artery aneurysms

Damian Kocur^{1A,B,C,D,E,F}, Nikodem Przybyłko^{1B,D}, Jan Baron^{2B,D,E}, Adam Rudnik^{1B,D,E}

¹Department of Neurosurgery, School of Medicine in Katowice, Medical University of Silesia, Katowice, Poland

²Department of Radiology and Nuclear Medicine, School of Medicine in Katowice, Medical University of Silesia, Katowice, Poland

Abstract

Purpose: We report our experience with endovascular treatment of these lesions, with special consideration of angiographic and clinical outcomes and periprocedural complications.

Material and methods: The analysis included treatment results of 19 patients with 20 aneurysms. The aneurysm size ranged from 1.9 to 4.7 mm (mean 3.8, SD 0.7). Clinical examinations with the use of modified Rankin Score and angiographic outcomes were evaluated initially postembolisation and at a minimum follow-up of six months.

Results: Initial post-treatment complete and near-complete aneurysm occlusion was achieved in 19 (95%) cases and incomplete occlusion in one (5%) case. Imaging follow-up, performed in 17 (89.4%) patients, showed no change in the degree of occlusion in 16 (94.1%) patients and coil compaction in one (5.9%). There were no retreatment procedures. The procedure-related mortality rate was 5% (1/20) and was associated with intraprocedural aneurysm rupture. There was a case of a clinically silent coil prolapse into the parent artery. The clinical follow-up evaluation achieved in 17 (89.4%) patients showed no change in clinical status in all followed patients.

Conclusions: Endovascular treatment of small unruptured middle cerebral artery aneurysms is feasible and effective. The procedure-related complications are not negligible, especially in terms of the benign natural course of these lesions.

Key words: embolisation, middle cerebral artery, unruptured cerebral aneurysms.

Introduction

Middle cerebral artery (MCA) aneurysms account for 18-22% of all intracranial aneurysms and are the third most common location for aneurysmal subarachnoid haemorrhage [1,2]. In the case of small unruptured MCA aneurysms, the indication for treatment should be made carefully because the risk of rupture of these lesions is very low [3]. There are, however, some clinical situations, e.g. an enlarging aneurysm on repeat imaging, when early treatment is recommended [4]. Before an interventional management is considered, the natural history of small unruptured aneurysms must be compared with potential procedure-related complications. Traditionally, in regard to MCA aneurysms,

microsurgical clipping has often been the first-line treatment method [5-7]. Although the endovascular coiling of MCA aneurysms is controversial, there is increasing interest in treating these lesions via this approach [6-14].

In the literature there are a limited number of studies concerning endovascular coiling of small unruptured aneurysms [15-17]. In fact, there seems to be no published study entirely dedicated to endovascular embolisation of small unruptured MCA aneurysms. The purpose of the current study is to report our experience with the endovascular coiling of small (< 5 mm) unruptured MCA aneurysms, with special regard to immediate and long-term radiographic and clinical outcomes and procedure-related complications.

Correspondence address:

Dr. Damian Kocur, Department of Neurosurgery, School of Medicine in Katowice, Medical University of Silesia, Katowice, Poland, e-mail: dankocur@gmail.com

Authors' contribution:

A Study design · B Data collection · C Statistical analysis · D Data interpretation · E Manuscript preparation · F Literature search · G Funds collection

Material and methods

Patient population

Between February 2008 and March 2015, 19 patients harbouring 20 small (< 5 mm), unruptured MCA aneurysms were treated at our centre via endovascular approach. There were 15 (78.9%) females and four (21%) males. The patients' ages ranged from 47 to 73 years (mean 57.6, SD 6.6). Seven patients underwent standard coil embolisation, and 12 patients underwent stent-assisted coiling. All the patients included in the present study were treated for the first time via endovascular approach. There were no retreatment procedures. For this retrospective study Ethics Committee approval and informed patient consent were waived.

Aneurysm characteristics

The aneurysm size, defined as the maximal height of the dome, ranged from 1.9 mm to 4.7 mm (mean 3.8, SD 0.7). Patient selection for treatment with stents was based only on the angioarchitectural characteristics of each aneurysm. Thus, only the wide-neck aneurysms, defined as those with aneurysm neck diameter \geq 4 mm and/or those with dome-to-neck ratio < 1.5, were considered for this treatment.

Endovascular techniques

Because all the aneurysms were depicted by computed tomography angiography at admission, both conventional and rotational digital subtraction angiographies (DSA) were performed in every case to evaluate accurately the aneurysmal configuration, neck size, and the width and height of the aneurysm. All the procedures were performed by experienced interventional radiologists, and always after neurosurgical consultation. The patients were treated under general anaesthesia. Anti-platelet premedication, consisting of a 75 mg loading dose of acetylsalicylic acid and an additional 75 mg clopidogrel in the case of planned stent-assisted coiling, was performed every day for five days before coiling.

Following selective catheterisation of the aneurysm lumen, another microcatheter was placed distally in the M2 segment for stent deployment. A neuroform stent (Stryker) was advanced over the microguidewire and deployed when the precisely targeted location was confirmed. Then, the aneurysm was coiled using Stryker Detachable Coils in the same session with the help of the previously deployed microcatheter. The procedures were usually performed in a bi-plane angiography suite. Once it was technically feasible, an attempt was made to achieve complete occlusion in the first treatment session. During the procedures heparinised saline was continuously infused into the arterial line. After embolisation,

the patient was transferred to the intensive care unit for clinical observation and monitoring of medical parameters. At that time, systemic heparin 15,000 IU for the next 24 hours was administered intravenously to raise the activated partial thromboplastin time 2-3 times above normal values. Patients after uncomplicated treatment were typically discharged from hospital on postoperative day 3. Antiplatelet therapy consisting of 75 mg acetylsalicylic acid was applied postoperatively every day with the intention of administering for the rest of the patient's life. In the case of stent-assisted coiling an additional 75 mg of clopidogrel was applied postoperatively every day for six weeks.

Angiographic and clinical analysis

A control angiography was obtained immediately after the embolisation and at a minimum follow-up of six months. Anatomical results were evaluated using three-class classification according to Raymond *et al.* (i.e. complete obliteration, residual neck, and residual aneurysm) [18]. A lack of contrast filling within the entire aneurysm and the residual filling in the aneurysm neck were categorised as complete and near-complete occlusion, respectively, whereas incomplete occlusion was defined as any opacification of the aneurysm sac. In cases of complete aneurysm obliteration at control angiogram performed a minimum of six months after coiling, the patient was not followed-up any longer, except for selected cases (e.g. endovascular treatment of accompanying cerebral aneurysms). Recanalisation was defined as any increase in aneurysmal filling at follow-up. Once there was enough space for placement of an additional coil, retreatment was considered.

Regarding clinical evaluation, modified Rankin Scale (mRS) scores were recorded at discharge from hospital and during the last angiographic follow-up period. Patients who did not undergo control angiography were interviewed by telephone if it was possible.

Detailed patient characteristics as well as outcomes are presented in Table 1.

Results

Angiographic results and retreatment

Instant post-embolisation angiogram revealed a complete aneurysm occlusion in 18 (90%) cases. A near-complete aneurysm occlusion was performed in one case (5%), and incomplete occlusion in another one (5%). Primary inadequate occlusion of aneurysms resulted from intraprocedural aneurysm rupture in one case. In another case, of near-complete occlusion, it was impossible to occlude the aneurysm with the shortest available coil.

Angiographic follow-up was achieved in 17 (89.4%) cases and ranged from six to 78 months, with a mean of

Table 1. Patient and aneurysm characteristics, occlusion rates, and outcome for patients with small unruptured middle cerebral artery aneurysms treated by coiling

No.	Age/sex	Initial symptoms	Aneurysm size (mm)	Instant aneurysm occlusion	Technical complications	Stent-assisted coiling	Occlusion at last follow-up	Angiographic follow-up period (months)	mRS at discharge	mRS at last follow-up	Clinical follow-up period (months)
1	73/F	Incidental	3.7	Complete	None	Yes	N/A		0	N/A	
2	55/F	Incidental	4.4	Complete	Coil prolapse	No	Near-complete	20	0	0	20
3	53/F	Headache	3.3	Complete	None	No	Complete	6	0	0	48
4	57/M	Headache	4.6	Complete	None	Yes	Complete	14	0	0	60
5	61/F	Incidental	3.4	Complete	None	Yes	Complete	6	0	0	6
6	56/F	Incidental	3.6	Complete	None	Yes	Complete	8	0	0	8
7	60/F	Headache	4.5	Complete	None	Yes	Complete	13	0	0	13
8	47/F	Headache	4.5	Complete	None	Yes	Complete	7	0	0	7
9	50/M	Headache	4.6	Complete	None	No	Complete	6	0	0	6
10	67/F	Incidental	4.4	Complete	None	Yes	Complete	6	0	0	6
11	56/F	Headache	3.8	Complete	None	Yes	N/A		0	N/A	
12	58/F	Headache	3.5	Near-complete	None	No	Near-complete	6	0	0	6
13	64/F	Incidental	3.6	Complete	None	Yes	Complete	6	0	0	6
14	53/F	Incidental	1.9	Complete	None	Yes	Complete	78	0	0	78
15	53/F	Incidental	3.5	Complete	None	Yes	Complete	78	0	0	78
16	65/M	Incidental	4.6	Complete	None	No	Complete	48	0	0	48
17	60/M	Incidental	4.5	Incomplete	IAR	No	N/A		6	N/A	
18	55/F	Incidental	3.8	Complete	None	Yes	Complete	8	0	0	8
19	47/F	Headache	4.7	Complete	None	No	Complete	7	0	0	7
20	57/F	Incidental	2.6	Complete	None	No	Complete	7	0	0	7

mRS – modified Ranking Score, IAR- intraoperative aneurysm rupture, N/A – not available

19 months. In 16 (94.1%) cases no change in the degree of occlusion at initial angiographic follow-up was observed. An illustrative example is presented in Figure 1. The recanalisation rate was 5.9% (1/17). There were no retreatment procedures.

Clinical results and complications

The procedure-related mortality rate of 5% (1/20 procedures) was associated exclusively with an event of intraprocedural bleeding of the aneurysm. Perforation of the aneurysm occurred during insertion of the first coil. The embolisation was not continued. Urgently performed CT scan revealed massive subarachnoid haemorrhage with intraventricular haemorrhage. The patient expired as a consequence of delayed cerebral ischaemia associated with SAH. There was a case of a coil prolapse into the parent artery without any adverse neurological consequences.

Clinical follow-up was achieved in 17 (89.4%) cases and performed at 6-78 months (mean 24.1 months) after

coiling. Analysis showed no change in clinical status in all followed patients.

Discussion

The traditional treatment for MCA aneurysms has been microsurgical clipping, because these aneurysms can be easily approached surgically and manipulated after splitting the Sylvian fissure [19]. Surgical clip ligation in the case of MCA aneurysms results in effective and durable aneurysm repair with the rates of complete occlusion above 90% and good neurological outcomes, and this form of treatment has been commonly preferred to endovascular coiling [19,20]. In the literature, however, there is no randomised, controlled trial that has compared the efficacy and safety of MCA aneurysm treatment between the two above-mentioned modalities [7,19-21]. Even on the basis of a multicentre, randomised ISAT trial involving ruptured intracranial aneurysms, it is impractical to establish the optimal method of management of MCA aneurysms because these lesions were underrepresented in

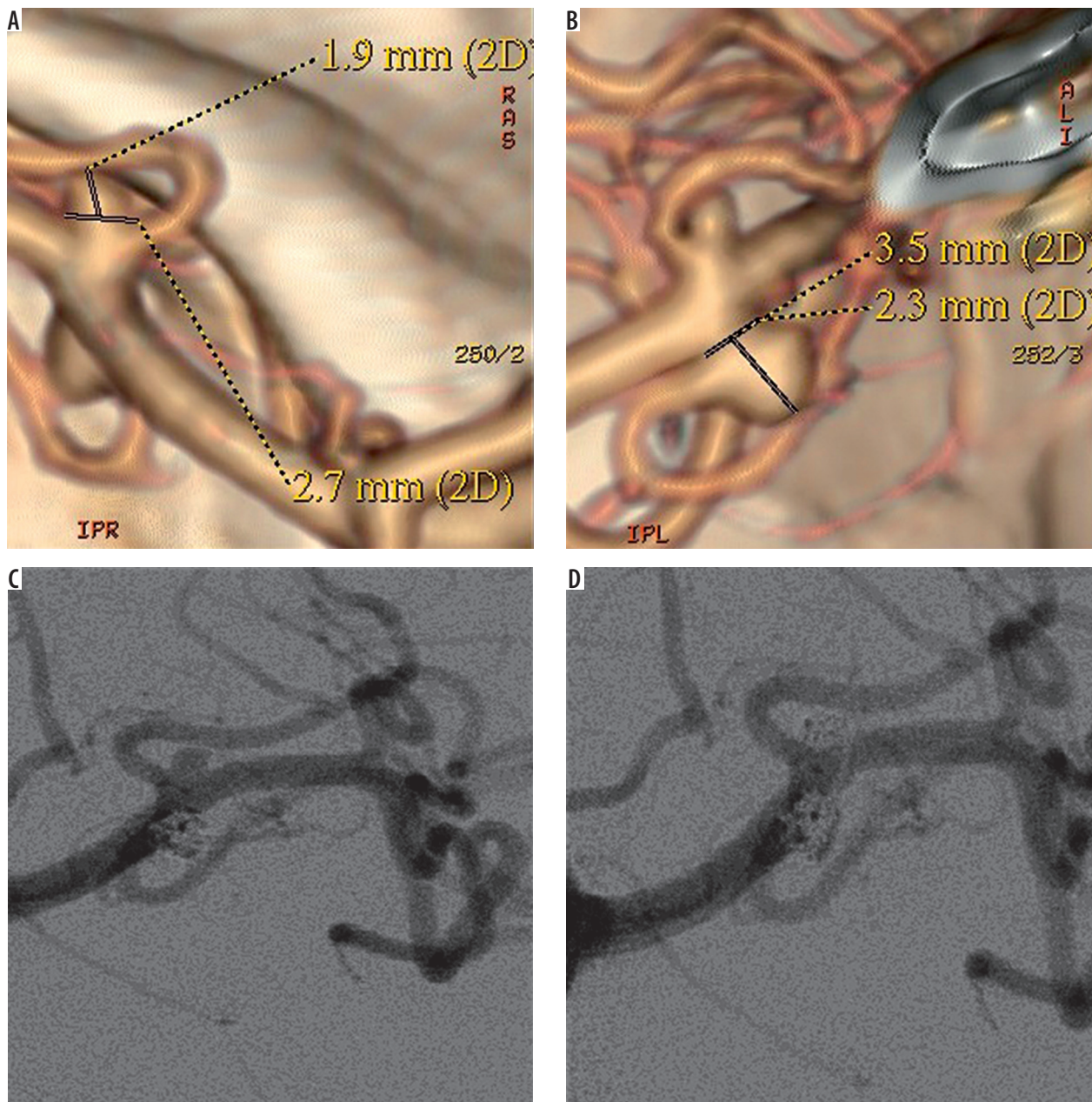


Figure 1. 53-year-old female patient presented with two small unruptured middle cerebral artery (MCA) aneurysms. **A, B)** Computed tomography angiograms showed two small (< 5 mm) MCA aneurysms. **C, D)** Control digital subtraction angiography following endovascular coiling, showed the complete occlusion of the two aneurysms. Follow-up angiogram (not shown) performed after 78 months confirmed the complete obliteration of the lesions

this study [19,21,22]. The two reported meta-analyses on unruptured MCA aneurysms performed by Smith *et al.* and Blackburn *et al.* showed that the surgical clipping is associated with higher occlusion rates compared to coil embolisation [20,23]. According to the study by Smith *et al.*, the microsurgical procedures yielded slightly lower unfavourable clinical outcomes, but in the report of Blackburn *et al.* the functional outcomes did not differ significantly between the two groups [20].

Although the coil embolisation of MCA aneurysms is controversial, there is increasing interest in treating these lesions via endovascular approach [6-11]. Advances in endovascular techniques such as rotational angiography

with three-dimensional reconstruction allows improved visualisation of MCA aneurysms and arterial branches before endovascular treatment [7,20,24]. Development of remodelling techniques such as balloons and stents, as well as improvement of preventive protocols of anticoagulation, have resulted in increased application of endovascular therapy of MCA aneurysms [7,20,24]. It is reported that in properly selected patients, endovascular coiling of MCA aneurysms should be considered, and satisfactory aneurysm occlusion is achieved in 62.5% to 96.8% of patients, with a complication rate from 3.8% to 20% [7,8,25,26].

One of the fundamental limitations of endovascular coiling of MCA aneurysms is the frequently complex

anatomy of these lesions [7,19]. These aneurysms often have wide necks, frequently incorporate one or both M2 branch vessels, and may have branches originating from the base or side wall of the aneurysm [7,19]. Coil embolisation of MCA aneurysms with unfavourable morphology may be associated with increased risk of branch occlusion [7,19,20,24].

In the case of small unruptured aneurysms the indication for intervention therapy is still under debate. The natural history of these lesions has not yet been conclusively investigated, and there is still uncertainty if coil embolisation of small unruptured aneurysms significantly reduces the incidence of haemorrhage [15-17]. According to the prospective ISUIA study published in 2003 the five-year cumulative rupture rate of MCA aneurysms < 7 mm is 0% [3]. Other studies on the natural history of unruptured aneurysms revealed a somewhat higher rupture risk in comparison to the 2003 ISUIA trial in the case of MCA aneurysms, but the risk is still very low [27,28]. The definite cut-off size above which the cerebral aneurysms should be unequivocally recommended for treatment has not yet been determined [15]. Nonetheless, selected patients with asymptomatic small aneurysms should be considered for treatment. These include patients with aneurysm growth, younger age, previous subarachnoid haemorrhage from another aneurysm, family history of aneurysm in first-degree relatives, certain morphological characteristics of aneurysm, or psychological factors [4,29]. When deciding how to treat patients with small unruptured aneurysms, surgical clipping as well as embolisation procedures may be taken into consideration. In the literature there are no studies directly comparing microsurgical clip ligation and endovascular embolisation of small asymptomatic unruptured aneurysms [16]. In view of occlusion durability, surgical clipping is considered to be applied in younger patients with a long life expectancy [29]. In older patients coil embolisation might be preferable; however, it is doubtful if the risk of treatment in such patients outweighs the rupture risk for small unruptured aneurysms [29]. Nonetheless, coil embolisation of small unruptured aneurysms may be performed with an acceptable occlusion rate and low degree of recurrence [29]. According to previous reports the initial complete or near-complete occlusion rate of small unruptured aneurysms treated via endovascular approach is 94.7-98.6% [15-17]. In comparison to others, small MCA aneurysms are associated with lower feasibility of endovascular coiling [16]. Oishi *et al.* reported that the risk of technical failure during endovascular coiling of small (< 10 mm), unruptured cerebral aneurysms was highest in MCA aneurysms, with a failure rate of 11.1% [16]. The results of our study with the 95% rate of the initial complete or near-complete aneurysm occlusion showed that small aneurysms on MCA may be coiled with satisfactory angiographic outcome.

The previously reported recanalisation rate during endovascular embolisation of small unruptured aneu-

rysms ranges between 2.9% and 9% [17,30,31]. Our results, with a recanalisation rate of 5.9%, are comparable with these studies. It should be noted that two cases of complete aneurysm obliteration from our database with angiographic follow-up of 48 and 78 months are proof that coiling of small unruptured MCA aneurysms may have long-term durability. To our knowledge, the present two cases of coiled small unruptured MCA aneurysms harbour the longest angiographic follow-up compared with the literature to date.

It is obvious that in the case of small unruptured aneurysms the risk of treatment-associated complications should be lower than the rupture risk of the aneurysms [29]. Im *et al.* presented a 10.1% risk of complications during treatment of small unruptured aneurysms, with 0.27% morbidity and 0% mortality rate [15]. In their report of 500 small unruptured intracranial aneurysms, Oishi *et al.* experienced 38 incidents of complications (7.6%) with morbidity and mortality rates of 0.8% and 0.2%, respectively [16]. The 5% risk of procedure-related mortality presented in the current study seems to be quite high, especially considering the low rupture rate of small MCA aneurysms. This relatively high complication rate should be taken into consideration when choosing this form of treatment for small unruptured MCA aneurysms. Although it is not uniformly established, the coiling of small aneurysms in comparison to larger lesions may be associated with higher risk of intraprocedural aneurysm rupture [17,32,33]. It may result from the more restricted space available for movement of a microcatheter within the small aneurysm, which results in lesser stabilisation of a microcatheter position [17,32,33]. This complication may have benign clinical course but also may be associated with fatal clinical consequences, as was presented in the case of aneurysm perforation from the current study [17]. In our case the perforation was performed with the first coil deployed into the aneurysm lumen, and it was impossible to stop the bleeding with prompt complete embolisation. This resulted in massive intracranial bleeding with subsequent death of the patient. There is a theory that a higher rupture rate during coiling of small aneurysms may be associated with a higher stiffness of the initial segment of a coil, i.e. the segment between the tip of the microcatheter and that of the coil that contacts the aneurysm wall [32]. The so-called bending stiffness of a coil is inversely proportional to the length of the coil segment, and the stiffness of the initial coil segment is supposed to be higher in smaller aneurysms in comparison to larger ones. Therefore, the risk of aneurysm perforation with a coil may be higher in smaller aneurysms [32].

Another adverse event that may take place during aneurysm coiling is coil protrusion into the parent artery. Coil prolapse may be associated with thromboembolic events, and the risk is high, but a stent deployment into the parent artery or coil retrieval is generally recommended for cases of severe protrusions [34]. In the literature,

thromboembolism has been the most frequent complication accompanying MCA aneurysm embolisation, and it may have serious clinical sequelae because the MCA branches often supply eloquent branches [6,7]. In the case of a clinically silent coil prolapse presented in the case of our database no interventional treatment was initiated. Because the blood flow in the parent artery was maintained we decided to treat the patient conservatively with aggressive antiplatelet therapy, as was presented in previous reports [35,36]. The clinical and radiographic course of our patient with 20-month follow-up proceeded uneventfully, suggesting that the expectant management is likely to be a safe treatment option for non-massive coil protrusions in small MCA aneurysms.

A limitation of the current study is its retrospective and observational character. There was also a patient-selection

bias, because all the cases reported in this series were from a single institution.

Conclusions

Endovascular treatment of small unruptured MCA aneurysms is feasible with satisfactory angiographic outcome and low recurrence rate. However, procedure-related complications resulting in severe clinical consequences are not negligible and should be taken into consideration, especially in terms of benign natural course of these lesions.

Conflict of interest

The authors declare no conflict of interest.

References

- Doerfler A, Wanke I, Goericke SL, et al. Endovascular treatment of middle cerebral artery aneurysms with electrolytically detachable coils. *AJNR Am J Neuroradiol* 2006; 27: 513-520.
- Estevão IA, Camporeze B, Araujo Jr AS de, et al. Middle cerebral artery aneurysms: aneurysm angiographic morphology and its relation to pre-operative and intra-operative rupture. *Arq Neuropsiquiatr* 2017; 75: 523-532.
- Wiebers DO, Whisnant JP, Huston J, et al. Unruptured intracranial aneurysms: natural history, clinical outcome, and risks of surgical and endovascular treatment. *Lancet Lond Engl* 2003; 362: 103-110.
- Brown RD. Controversy: clipping of asymptomatic intracranial aneurysm that is < 7 mm: yes or no? *Stroke* 2013; 44: S96-S96.
- Quadros RS, Gallas S, Noudel R, et al. Endovascular treatment of middle cerebral artery aneurysms as first option: a single center experience of 92 aneurysms. *Am J Neuroradiol* 2007; 28: 1567-1572.
- Bracard S, Abdel-Kerim A, Thuillier L, et al. Endovascular coil occlusion of 152 middle cerebral artery aneurysms: initial and mid-term angiographic and clinical results: clinical article. *J Neurosurg* 2010; 112: 703-708.
- Eboli P, Ryan RW, Alexander JE, et al. Evolving role of endovascular treatment for MCA bifurcation aneurysms: case series of 184 aneurysms and review of the literature. *Neurol Res* 2014; 36: 332-338.
- Iijima A, Piotin M, Mounayer C, et al. Endovascular treatment with coils of 149 middle cerebral artery berry aneurysms. *Radiology* 2005; 237: 611-619.
- Suzuki S, Kurata A, Ohmomo T, et al. Endovascular surgery for very small ruptured intracranial aneurysms: Technical note. *J Neurosurg* 2006; 105: 777-780.
- Brinjikji W, Cloft H, Kallmes DF. Difficult aneurysms for endovascular treatment: overdue or undertall? *Am J Neuroradiol* 2009; 30: 1513-1517.
- Johnson AK, Heiferman DM, Lopes DK. Stent-assisted embolization of 100 middle cerebral artery aneurysms: clinical article. *J Neurosurg* 2013; 118: 950-955.
- Zhang X, Zhou Y, Duan G, et al. Endovascular treatment of ruptured middle cerebral artery aneurysms: a single armed meta-analysis and systematic review. *World Neurosurg* 2019 [Epub ahead of print]. DOI: 10.1016/j.wneu.2019.01.066.
- Alreshidi M, Cote DJ, Dasenbrock HH, et al. Coiling versus microsurgical clipping in the treatment of unruptured middle cerebral artery aneurysms: a meta-analysis. *Neurosurgery* 2018; 83: 879-889.
- Schwartz C, Aster HC, Al-Schameri R, et al. Microsurgical clipping and endovascular treatment of middle cerebral artery aneurysms in an interdisciplinary treatment concept: comparison of long-term results. *Interv Neuroradiol* 2018; 24: 608-614.
- Im SH, Han MH, Kwon OK, et al. Endovascular coil embolization of 435 small asymptomatic unruptured intracranial aneurysms: procedural morbidity and patient outcome. *Am J Neuroradiol* 2008; 30: 79-84.
- Oishi H, Yamamoto M, Shimizu T, et al. Endovascular therapy of 500 small asymptomatic unruptured intracranial aneurysms. *Am J Neuroradiol* 2012; 33: 958-964.
- Feng X, Wang L, Guo E, et al. Progressive occlusion and recanalization after endovascular treatment for 287 unruptured small aneurysms (<5mm): a single-center 6-year experience. *World Neurosurg* 2017; 103: 576-583.
- Raymond J, Guilbert F, Weill A, et al. Long-term angiographic recurrences after selective endovascular treatment of aneurysms with detachable coils. *Stroke* 2003; 34: 1398-1403.
- Rodríguez-Hernández A, Sughrue ME, Akhavan S, et al. Current management of middle cerebral artery aneurysms: surgical results with a 'clip first' policy. *Neurosurgery* 2013; 72: 415-427.
- Smith TR, Cote DJ, Dasenbrock HH, et al. Comparison of the efficacy and safety of endovascular coiling versus microsurgical clipping for unruptured middle cerebral artery aneurysms: a systematic review and meta-analysis. *World Neurosurg* 2015; 84: 942-953.
- Yang W, Huang J. Treatment of middle cerebral artery (MCA) aneurysms: a review of the literature. *Chin Neurosurg J* 2015 [Epub ahead of print]. DOI: 10.1186/s41016-015-0001-8.
- Molyneux AJ, Kerr RS, Yu LM, et al. International subarachnoid aneurysm trial (ISAT) of neurosurgical clipping versus endovascular coiling in 2143 patients with ruptured intracranial aneurysms:

- a randomised comparison of effects on survival, dependency, seizures, rebleeding, subgroups, and aneurysm occlusion. *Lancet* 2005; 366: 809-817.
23. Blackburn SL, Abdelazim AM, Cutler AB, et al. Endovascular and surgical treatment of unruptured mca aneurysms: meta-analysis and review of the literature. *Stroke Res Treat* 2014; 2014: 1-11.
 24. Kadkhodayan Y, Delgado Almandoz JE, Fease JL, et al. Endovascular treatment of 346 middle cerebral artery aneurysms: results of a 16-year single-center experience. *Neurosurgery* 2015; 76: 54-61.
 25. Yang P, Liu J, Huang Q, et al. Endovascular treatment of wide-neck middle cerebral artery aneurysms with stents: a review of 16 cases. *Am J Neuroradiol* 2010; 31: 940-946.
 26. Vendrell J-F, Costalat V, Brunel H, et al. Stent-assisted coiling of complex middle cerebral artery aneurysms: initial and midterm results. *Am J Neuroradiol* 2011; 32: 259-263.
 27. Juvela S, Porras M, Poussa K. Natural history of unruptured intracranial aneurysms: probability of and risk factors for aneurysm rupture. *J Neurosurg* 2000; 93: 379-387.
 28. The UCAS Japan Investigators; Morita A, Kirino T, Hashi K, et al. The natural course of unruptured cerebral aneurysms in a Japanese cohort. *N Engl J Med* 2012; 366: 2474-2482.
 29. Burkhardt JK, Benet A, Lawton MT. Management of small incidental intracranial aneurysms. *Neurosurg Clin N Am* 2017; 28: 389-396.
 30. Stetler WR, Wilson TJ, Al-Holou WN, et al. Conventional endovascular treatment of small intracranial aneurysms is not associated with additional risks compared with treatment of larger aneurysms. *J Neurointerv Surg* 2015; 7: 262-265.
 31. Hwang JH, Roh HG, Chun YI, et al. Endovascular coil embolization of very small intracranial aneurysms. *Neuroradiology* 2011; 53: 349-357.
 32. Mitchell PJ, Muthusamy S, Dowling R, et al. Does small aneurysm size predict intraoperative rupture during coiling in ruptured and unruptured aneurysms? *J Stroke Cerebrovasc Dis* 2013; 22: 1298-1303.
 33. Schuette AJ, Hui FK, Spiotta AM, et al. Endovascular therapy of very small aneurysms of the anterior communicating artery: five-fold increased incidence of rupture. *Neurosurgery* 2011; 68: 731-737.
 34. Ishihara H, Ishihara S, Niimi J, et al. Risk factors for coil protrusion into the parent artery and associated thrombo-embolic events following unruptured cerebral aneurysm embolization. *Interv Neuroradiol* 2015; 21: 178-183.
 35. Kocur D, Zbroszczyk M, Przybyłko N, et al. Stent-assisted embolization of wide-neck anterior communicating artery aneurysms: review of consecutive 34 cases. *Neurol Neurochir Pol* 2016; 50: 425-431.
 36. Abdihalim M, Kim SH, Maud A, et al. Short- and intermediate-term angiographic and clinical outcomes of patients with various grades of coil protrusions following embolization of intracranial aneurysms. *Am J Neuroradiol* 2011; 32: 1392-1398.