

The hepatoprotective effect of *Arnebia euchroma* hydro-alcoholic extract against liver toxicity induced by CCl₄ in mice

Mohammad Shokrzadeh¹, Mohammad Azadbakht^{2*}, Hamidreza Shakibamanesh³

¹Department of Pharmacology and Toxicology, Pharmaceutical Sciences Research Center, Faculty of Pharmacy, Mazandaran University of Medical Sciences, Sari, Iran

²Department of Pharmacognosy, Pharmaceutical Sciences Research Center, Faculty of Pharmacy, Mazandaran University of Medical Sciences, Sari, Iran

³Student Research Committee Pharmacy, Faculty of Pharmacy, Mazandaran University of Medical Sciences, Sari, Iran

ARTICLE INFO

*Corresponding author:

azadbakht110@gmail.com

Article history:

Received: Oct 3, 2017

Accepted: Dec 25, 2017

Keywords:

Hepatoprotective,
Arnebia euchroma,
CCl₄,
mice

ABSTRACT

Arnebia euchroma is from Boraginaceae family. Various therapeutic effects have been reported for different species of this plant. The aim of this study was to investigate antioxidant activity of hydroalcoholic extract of the root of *A. euchroma* and its protective effect on hepatotoxicity induced by CCl₄ in mice. In this experimental study, *A. euchroma* was extracted with ethanol solvent by maceration method. Antioxidant activity of the plant has been evaluated by the DPPH free radical scavenging method. Then, the hepatoprotective effect of *A. euchroma* was evaluated through determination the content of glutathione in liver tissue, ALP, AST, ALT serum levels and histopathology of liver in different groups. The total phenolic content determined as 0.56% per 100 g of plant was equivalent to gallic acid. The total flavonoid content was 0.079% per 100 g of plant that was equivalent to quercetin. The IC₅₀ of the extract for free radical scavenging was obtained 139.2 µg/ml. The extract increased liver glutathione and serums ALP, AST, ALT that were decreased by CCl₄ administration in animal. All protective effects were dose-dependent and the results of liver histopathology showed a significant improvement of inflammation and necrosis that were caused by CCl₄ in mice. The results of this study revealed that the hydroalcoholic extract of *A. euchroma* root has an antioxidant effect and excellent hepatoprotection in mice.

Citation: Pharm Biomed Res 2017;3(4):23-29. DOI: [10.18502/pbr.v3i4.87](https://doi.org/10.18502/pbr.v3i4.87)

Introduction

The liver is the largest organ in the body forming 3-5% of the body mass. The most important actions of the liver are various material metabolisms, detoxification of environmental pollutants and chemical drugs (1). Liver disease is one of the serious problems threatening the health of the human community. Today, it has been demonstrated that osteotomy and fibrosis are the underlying causes of fatal cirrhosis in humans. Although the pathogenesis of liver fibrosis has not been completely determined, it is clear that reactive oxygen species (ROS) samples play a determining role in the pathology changes in the liver (2). Biological membranes are the most sensitive parts of the cell to the effects of ROS. The peroxidation of unsaturated fatty acids in biological membranes, in addition to reducing fluidity, can destroy them (3). Although intracellular protective mechanisms greatly reduce the risk of ROS, there are other protective ways especially food antioxidants for human health due to the high frequency of these free radicals. The presence of natural compounds especially plant specimens having antioxidant properties, has such characteristics (4). There are many plants in traditional medicine of Iran prescribed for liver disorders such as chicory and purslane (*Portulaca Oleracea*) (5). *Arnebia euchroma* is

from Boraginaceae family and its other names include Shankar, Shanjar, Hannah al-Ghul, Khums al-Hammar, Regal al-Hamamah, and the Shajarat - al- dam (6, 7). The roots of borage family such as *Arnebia euchroma* is containing shikonin, alkanin and other naphthoquinone derivatives (8). These substances have antioxidant properties with a wide range of biological capabilities, such as wound healing, antifungal activity, antiviral activity like the flu virus and AIDS (9-12). In addition, other studies have shown that *A. euchroma* has antimicrobial (6) and anti-inflammatory effects (13). In this study, the hepatoprotective effect of the hydroalcoholic extract of this plant was evaluated in liver toxicity induced by carbon tetrachloride in mice.

Materials and Method

Plant specimen

The substratum (root) of the *A. euchroma* plant was collected from the plant in the late summer and early autumn and after confirmation by a botanist and preparing a herbarium specimen, number of E₁-36-281 specified for the sample. After drying of this plant in the shade at 37 °C, the extraction was carried out using a multiple maceration method at the temperature of 15-20 °C with ethanol (80%). After 72 h, the extract was collected (three times). After filtration, the major of

solvent was removed using distillation apparatus in a vacuum. Then the extract was dried and powdered using a freeze drier. The extract was standardized based on the total phenol content will be carried out using the Folin-Ciocalteu Reagent and flavonoids content using aluminum chloride by spectrophotometry and standard curve drawing (2).

Free radical scavenging

4 mL of extract at concentrations 1-20 mg/ml was mixed with 1 mL of 2,2-diphenyl-1-picrylhydrazyl (DPPH) (Merck company, Germany) solution at 10 μ M (final concentration of 0.2 mM DPPH). After mixing, the samples were incubated in darkness for 30 min and then absorbance was measured at 517 nm in front of blank. The scavenger ability of the extract was calculated ($n = 3$). The IC_{50} (concentration of each extract required to remove up to 50% of radicals) was obtained from the control curve versus the extract concentration. Vitamin C was used as a positive control for comparison (2).

Determining the total phenol and flavonoid contents

Total phenolic content was carried out through Folin-Ciocalteu method (14). 0.5 mL of the extract at concentration 0.5 mg/ml was mixed with 2.5 mL reagent and 0.2% Folin-Ciocalteu. Sodium carbonate solution (2 mL, 7.5%) was added to this mixture. The absorbance of the sample was measured at room temperature by ultraviolet spectrophotometer (PerkinElmer, USA) at 760 nm after 2 h. The results were expressed as equivalent values with gallic acid. The mean absorption was put in the linear equation obtained from the drawing of gallic acid standard curve. The result was reported as total phenol content of the extract in mg equivalent to gallic acid per gram of extract. Experiments were repeated 3 times for each extract and standard. The total flavonoid content of the extract was evaluated through colorimetric methods (14). 0.5 mL of the sample at a concentration of 0.5 mg/ml was mixed with 1.5 mL of ethanol, and then 0.1 mL of 10% aluminum chloride was added. Then, 0.1 mL of potassium acetate (1 M) solution and 8.2 mL of distilled water were added and the collection was kept at room temperature for 30 min. The absorbance of the final solution was measured at 415 nm. Quercetin was used as the standard for plotting the calibration curve. Flavonoid content was reported in mg equivalent of quercetin per gram of the extract. The experiments were repeated 3 times and their mean was reported.

Animal study

Firstly, extract was prepared at doses of 200 and 400 mg/kg by dissolving of extract in normal saline. In all cases, 0.5 ml of extract was injected in mouse. Male mice (8-10 weeks, 25-30 g) were kept in Experimental Animals Center of Mazandaran University of Medical Sciences. This study was approved by Ethical

Committee of University (ID: 2186). Mice (in each group 6 mice in separate cages) were kept under controlled temperature (between 20-25 °C) and light (12-12 h light and darkness). Food powder and water was available for them. For intraperitoneal injection and animal surgery, olive oil was used as a solvent for carbon tetrachloride (Merck Company, Germany). Carbon tetrachloride (CCl_4) was injected by Intraperitoneal injection (IP) method for 7 days (15).

Animals were divided into 5 groups and their injections were carried out as follows.

Group: 1 negative control group that was received only olive oil (carbon tetrachloride solvent) (1 ml/kg IP), daily for 7 days. Group 2: Mice were received only carbon tetrachloride with its solvent, daily for 7 days. Group 3: Mice were received of the extract (200 mg/kg/ day IP) of *A. euchroma* for 7 days. Group 4: Mice were received of the extract (400 mg/kg/ day IP) of *A. euchroma* for 7 days. Group 5: Mice were received of the vitamin C as an antioxidant compound (10 mg/kg/ day IP) for 7 days.

Biochemical analysis

Animals were anesthetized at 24 h after last injection with a mixture of ketamine and xylazine and then killed. Immediately after fracturing the abdomen and chest, about 2 mL of blood was removed from the heart with an insulin syringe and centrifuged to measure the enzymes from the animals' serum. The serum was transferred to sterile tubes for each animal and stored in a freezer to measure the appropriate serum levels of alanine aminotransferase (ALT), Aspartate aminotransferase (AST), and alkaline phosphatase (ALP) in a working day. Immediately after blood collection, the animal liver was washed by physiologic serum to measure glutathione by Alman method and pathological examination, and then it was placed in formalin 10% for tissue fixation and histopathological studies (15). 0.1 g of liver tissue was transferred to the homogenizer tube. 1 ml of EDTA was added and the homogenization was carried out several times with a piston to obtain a uniform mixture. Then the contents of the homogenizer tube were transferred to the refrigerated centrifuge tube. In the next step, 1.5 mL of 10% trichloroacetic acid (TCA) (Merck Company, Germany) was added to centrifuge tube for protein deposition. The tubes were centrifuged for 15 min at 3500 rpm and 1 mL of the solution was transferred to the test tube and 2.5 mL of 0.4 M Tris buffer (pH = 9.9) and 0.5 mL of 5,5'-dithio-bis-(2-nitrobenzoic acid (DTNB) (Merck Company, Germany) added. The tube was then shaken well until a uniform yellow color was obtained in the tube. Finally, the absorbance of the resulting solution was read at 412 nm and the glutathione concentration was measured using the standard curve (15, 16). To measure serum ALP, AST, ALT, 1.5 to 2 ml of blood was transferred to a centrifuge

tube and placed in a laboratory for 30 min to be incubated, then centrifuged at 1500 rpm for 15 min. Then, about 0.5 mL of serum was obtained. A kit was used to measure all three enzymes, ALP, ALT, and AST. The results of these three enzymes were reported as U/L (16, 17).

Histopathology assessment

For histopathology, the incision was taken from the central part of the liver in 10% formalin, the longitudinal and transverse sections and placed in special Tissue Processor apparatus. Tissues and the sample code was placed there. The basalt was placed in 10% formalin for 24 h so that formalin penetrates into the inner parts of the tissue. Then, the baskets were put into the Tissue Processor with 10% formalin, 70% alcohol, 80% alcohol, 90% alcohol, 100% alcohol (absolute), xylene and paraffin (paraffin temperature is approximately 64 °C), respectively. After the removal of baskets from Tissue Processor apparatus, the tissues were removed from the basket and covered with paraffin. Finally, after preparing the appropriate incisions the tissue was prepared for coloring step. The coloring was carried out using Giemsa method.

Statistical analysis

The results of this study were analyzed using Graph pad prism 6 software (USA) in the form of one-way ANOVA variance analysis test. The data were reported as mean \pm SD. Also Tukey posttest was used to compare the groups. Comparing the mean of the groups, $P < 0.05$, was considered significant.

Results

Phytochemical and antioxidant analysis

After extraction, the percent of extraction yield was obtained 6.34 by measuring the extracts weight. In total phenol measurements in Folin-Ciocateu extract, the content of total phenol in the plant was 0.56% gallic acid per 100 gram of the plant. By measuring total flavonoid in the plant using aluminum chloride, total flavonoid content was determined 0.079% of quercetin per 100-gram plant.

In scavenging DPPH free radical, the value of IC_{50} was obtained 139.2 μ g/ml for the extract and IC_{50} for vitamin C was 8.4 μ g/ml.

Animal tests

The results of measurement of glutathione (GSH) of mice liver (μ mol/g) in the studied groups after chronic exposure to the hydroalcoholic extract of *A. euchroma* root have been illustrated in figure 1.

The results of glutathione measurement of GSH in the mice liver showed that the maximum amount of glutathione in the normal saline (control) group was 108 μ mol/g, and the lowest amount of glutathione in the CCl_4 group was 75.2 μ mol/g of extract. The extract

significantly and dose-dependently increased the glutathione levels in liver of mice treated with CCl_4 .

Comparison of AST enzyme level in the mice in the studied groups and the group receiving carbon tetrachloride and normal saline has been presented in figure 2.

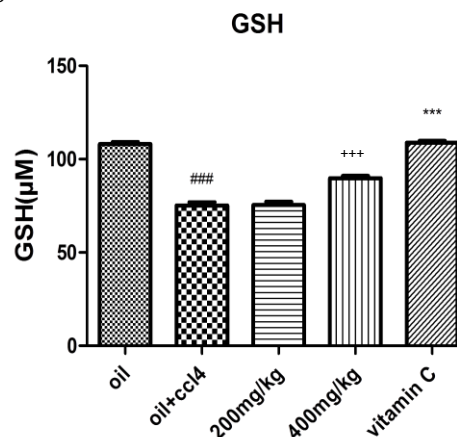


Figure 1 Comparison of glutathione GSH level in mice liver (μ mol/g) in the study groups and the group receiving carbon tetrachloride (CCl_4 , control) and normal saline (control, vitamin C has been used as positive control). ###: significance with $P < 0.001$ compared to normal saline; +++: significant with $P < 0.001$ compared to carbon tetrachloride.

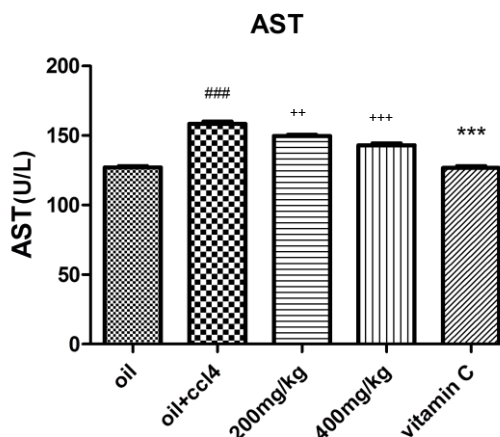


Figure 2 Comparing serum AST enzyme levels in the studied groups and the groups receiving CCl_4 and normal saline. Vitamin C has been used as a positive control. ###: significance with $P < 0.001$ compared to normal saline; **: significance with $P < 0.001$ compared to carbon tetrachloride; +++: Significance with $P < 0.001$ compared to CCl_4 ; ***: Significance with $P < 0.001$ compared to carbon tetrachloride.

The highest amount of serum AST is in the group receiving CCl_4 with 158 U/L and the lowest amount of

AST in the serum is in the group receiving normal saline 127 and vitamin C 127 U/L.

Comparison of serum ALT level of mice in the studied groups and the group receiving carbon tetrachloride and normal saline has been presented in figure 3.

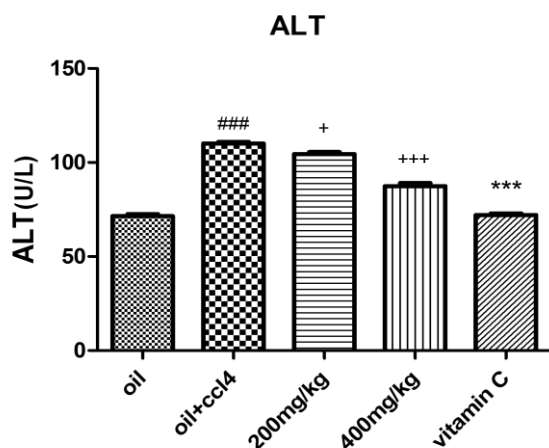


Figure 3 Comparison of serum ALT levels of mice in the studied groups and the group receiving CCl_4 and normal saline. Vitamin C is used as a positive control. ###: significance with $P < 0.001$ compared to normal saline; +: significance with $P < 0.05$ compared to carbon tetrachloride; +++: Significance with $P < 0.001$ compared to carbon tetrachloride; ***: significance with $P < 0.001$ compared to CCl_4 .

The highest amount of serum ALT is in the CCl_4 group with 110 U/L, the lowest amount of ALT in the serum is in the group receiving normal saline with 71.4 U/L and vitamin C with 72 U/L. Extract significantly and dose-dependently decreased ALT level in the serum of CCl_4 -treated mice compared to the group receiving CCl_4 .

Comparison of serum ALP levels of mice in the studied groups and the group receiving CCl_4 and normal saline has been presented in figure 4.

The highest serum ALP level is in the carbon tetrachloride group with 216 U/L, the lowest amount of ALP in the serum is in the group receiving normal saline with 164 U/L, and vitamin C with 160 U/L. The extract significantly and dose-dependently decreased the amount of ALP in the serum of CCl_4 -treated mice compared to the group receiving CCl_4 .

The results of histopathologic studies of the liver are as follows (figure 5).

Group 1: In the normal saline group, the liver was normal and without inflammation in the portal area and necrosis of the hepatocytes. Cells had no bleeding, and central vessels were normal.

Group 2: In the group receiving CCl_4 , severe inflammation and extensive necrosis of hepatocytes have seen. Necrosis and extensive bleeding were observed around the central vessels. Local

inflammation and extensive parenchymal necrosis were also observed in the liver cells.

Group 3: The group receiving 200 mg/kg of *A. euchroma* root extract did not showed any significant change in terms of bleeding, necrosis and inflammation in different parts of the liver in relation to CCl_4 .

Group 4: The group receiving 400 mg/kg root extract of *A. euchroma*, bleeding decreased slightly in the central veins, inflammation is not seen in most parts of the liver in relation to carbon tetrachloride. Parenchymal necrosis has been reduced in all parts, but portal inflammation is still visible (Fig. 5).

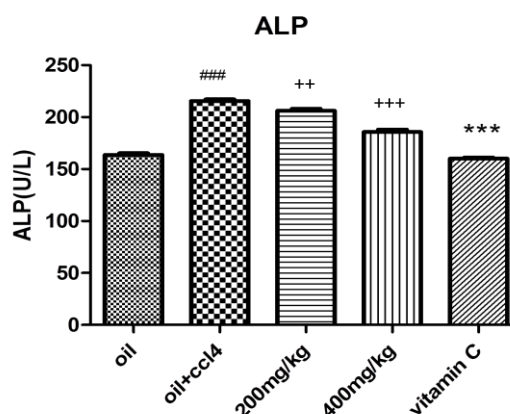


Figure 4 Comparison of serum ALP levels of mice in the studied groups and the group receiving CCl_4 and normal saline. Vitamin C is used as a positive control. ###: significance with $P < 0.001$ compared to normal saline; ++: significance with $P < 0.01$ compared to carbon tetrachloride; +++: significance with $P < 0.001$ compared to carbon tetrachloride; ***: Significance with $P < 0.001$ compared to CCl_4 .

Discussion

In this study, the protective effect of hydroalcoholic extract of *A. euchroma* root on hepatotoxicity resulting from carbon tetrachloride in mice was investigated. Serum levels of ALT, AST, ALP for the measurement of liver activity by carbon tetrachloride and oxidative stress factors including glutathione levels were investigated. Carbon tetrachloride reduced glutathione content and increased levels of liver enzymes such as ALT, AST, ALP. Carbon tetrachloride is one of the hepatotoxic drug used to study liver diseases. The destruction of liver cells is due to the breakdown of carbon tetrachloride tie by carbon tetrachloride, followed by the formation of tri-chloromethyl free radical. This radical is highly unstable and immediately reacts with cell membrane compounds or separates a hydrogen atom from unsaturated fatty acids of the cell membrane, which eventually results in the production of a radical lipid and chloroform. The radical lipids

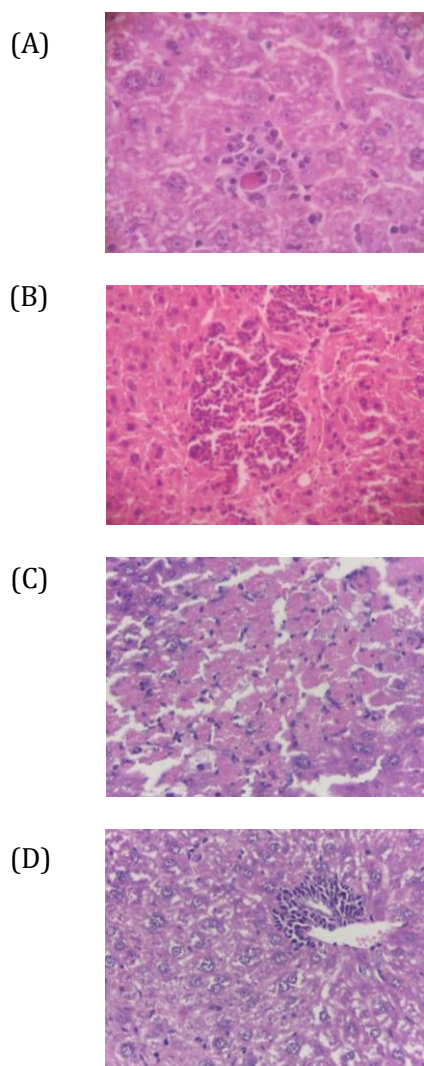


Figure 5 A: Normal hepatic tissue of tested animal by magnifying 40, B: Evaluation of histopathologic effects of liver tissue tested animal in the group faced with carbon tetrachloride in olive oil by magnifying 40, C: Evaluation of histopathologic effects of liver tissue of tested animal in the group receiving 200 mg/kg doses of root extract by magnifying 40, D: Evaluation of histopathologic effects of liver tissue of tested animal in the group receiving 400 mg/kg doses of root extract by magnifying 40.

cause the destruction of endoplasmic reticuloids after being combined with oxygen and ultimately release enzymes of death and necrosis of the cells (18). Free radicals containing oxygen, called ROS, are the most important biological free radicals. Because free radicals have one or more unequal electrons, they are extremely unstable. Such radicals in the body seek to get or lose electrons. Consequently, they damage cells, proteins, and DNA (19). It is produced in the body of animals under the influence of different reactions or

environmental factors of different free oxy radicals with unpaired external orbitals. This empty molecular orbital exists in oxygen or in nitrogen, which is called ROS, RNA, respectively. Free radicals are increased under oxidative stress and cause damage to the cell membrane (20).

Today, liver diseases are one of the most important problems of human societies, and finding an effective drug in the treatment of these disorders is of interest to researchers (2). Production of active oxygen particles and induction of oxidative stress are the main mechanisms for liver damage by many liver toxins (15). The liver is one of the largest organs in the body, accounting for 3 to 5 percent of the body mass. Because of the fact that one of the most important activities of the liver is detoxification of substances, in most cases, enzymes are used causing damage to various tissues including the liver itself by producing P cytochrome 450 of toxic metabolites (1). Due to the fact that liver diseases and tissue damages are a life-threatening problem, attempts to discover and use compounds that have a protective effect on liver are increasing; in addition, paying attention to complementary medicines and treatment with natural plant-derived compounds has been increased (21). Thioacetamide, ethanol, acetaminophen and carbon tetrachloride are substances metabolized by this enzyme system after entering the body (1). Carbon tetrachloride is an organic solvent that is widely used as a liver toxicity model due to the production of such particles and the induction of oxidative stress (22). In the development of liver toxicity by CCl_4 , the bond between carbon and chlorine is broken down and trichloromethyl free radical is formed (23). Measuring the levels of some serum enzymes is used as a biomarker in liver damages. These enzymes are released into the blood from the cytosol and organelles. AST is mostly found in the tissues of the liver, heart and musculoskeletal system, and to a lesser extent in the brain, pancreas, lung, and leukocyte varitrosis. If these tissues are affected, the serum is increased in AST and this causes an increase in ALT in liver necrosis, that's why measuring this enzyme is a selective test for liver necrosis (15, 24). ALT serum level is more sensitive and specific than AST for liver injury (24). In previous studies, liver damage induced by intraperitoneal injection of 1 mg/kg carbon tetrachloride has been well documented and its effect has been proven (25, 26). In this study, prescription of 1 mg / kg of carbon tetrachloride in the form of intraperitoneal injection significantly increased the level of AST, ALP and ALT enzymes in comparison with the control group. Daily administration of the extract for one week significantly reduced the serum ALT, AST, ALP enzymes levels and reduced the levels of these enzymes to normal levels. There are abundant herbs used in the treatment of poisoning and liver disease in traditional medicine.

Plants such as *Silybum marianum*, dandelion, *Fumaria officinalis*, turmer (*Curcuma longa*), artichoke (*Cynara scolymus*) and several other plants have been effective in the treatment of liver disease (27). Certain Labiatae plants such as *Rosmarinus officinalis* and some salvia plants from this family have liver protection effects (28). The hepato-protective effect of *Polygonum* has also been reported (15). Intraperitoneal injection of carbon tetrachloride significantly increased the level of AST and ALT enzymes in the plasma and the level of lipid peroxidation in the liver tissue. Administration of ethanol extract of *Polygonum* at doses of 500, 750 and 1000 mg/kg, markedly decreased the level of liver enzymes and lipid peroxidation. Several medicinal plants have been used in the treatment of poisoning and liver diseases in traditional medicine, which mainly contain polyphenols and flavonoids that are the most important antioxidants (28). A number of other medicinal plants have been identified as liver protective organisms, such as artichoke, *Feniculum vulgare*, *Cynara scolymus*, *Solanum nigrum*, *Terminalia chebula* and *Carum copticum*. The liver protection effect of these plants is attributed to the presence of glycosides, flavonoids, triterpenes and phenols (29, 30). Barberry extract at concentrations of 10, 100 and 200 mg/kg were administered orally in mice. Carbon tetrachloride significantly increased serum levels of alanine aminotransferase, aspartate aminotransferase and alkaline phosphatase in rats, while ethanolic extract of barberry reduced the levels of these enzymes significantly to approximately normal levels (31). It has been reported that intra-tract injection of carbon tetrachloride in mice increased the activity of AST, ALT, and ALP by 46.68, and 85.17%, and 134.94%, respectively, compared to the control group (2). The use of extract of *Dorema auchri* (200, 400 and 500 mg/kg), as gavage, made these factors be significantly closer to the normal level. The results of this study indicate that the extract of *Dorema auchri* has a protective effect against the liver damage induced by carbon tetrachloride (2). In another study, carbon tetrachloride (1.25 mg/kg) caused liver damage and increased transaminase levels in the blood considerably. Administration of pistachio gum extract with doses of 0.5 and 1 g/kg before carbon tetrachloride significantly prevented the increase of ALT, but had no effect on AST concentration (32). Glutathione is the most abundant non-enzymatic antioxidant in the body. This compound is naturally regenerated and in equilibrium with its oxidized form it is the pathway of vitamin E and vitamin C (33). Substances like vitamin are reversed to produce primary glutathione again (34). In our study, administration of the extract significantly and dose-dependently increased glutathione levels in mice. The hepatic protective effect of the extract is well confirmed with histopathological evidence. On the other hand, the

antioxidant activity of plants can be attributed mainly to the presence of phenolic compounds (35). Polyphenols have different biological activities, including antifungal, antibacterial, antiviral, anti-inflammatory and anti-allergic activities as well as vasodilation (35). Total phenol content in the extract was determined in total extracts and its value was equal to 0.56% gallic acid per 100 g of the plant.

Flavonoids are widely distributed in plants and are responsible for doing many functions. Flavonoids are the most important plant pigment for flower coloration. In addition, some flavonoids have inhibitory activity against organisms that cause plant diseases. Flavonoids account for about half of the 8,000 identified phenols (34). As stated, Flavonoids are responsible for creating color in leaves and fruits and are considered in the pharmaceutical and food industries due to antioxidant activity (35). The action of flavonoids is free radical scavenging or chelating the ions. Total flavonoid content in extract was determined of 0.079% per 100 g of plant. In this test, vitamin C was used as a positive control, IC₅₀ value for scavaging DPPH free radical for extract was obtained 139.2 mg/ml. Recovery capacity is used as an indicator in determining the antioxidant capacity of medicinal plants (36).

Conclusion

The effects of *Arnebia euchroma* extract on CCL₄-induced hepatotoxicity in mice were evaluated by recording changes in hepatic enzymes and other biomarker levels as well as histopathological changes. The extract of *Arnebia euchroma* showed noticeable antioxidant activity, through its ability to scavenge free radicals and efficiency against lipid peroxidation. Therefore, results of our study suggest that *Arnebia euchroma* is a potent hepatoprotective agent that could protect liver against the acute injury and this ability might be attributed to its antioxidant potential.

Acknowledgments

This research was carried out with the financial support of the deputy of research and technology affiliated to Mazandaran University of Medical Sciences. Hereby I'd like to thank him.

Conflict of interests

The authors declare no conflicts of interest.

References

1. Ahmad A, Pillai KK, Najmi AK, Ahmad SJ, Pal SN, Balani DK. Evaluation of hepatoprotective potential of jigrine post-treatment against thioacetamide induced hepatic damage. *J Ethnopharmacol* 2002 Feb 1;79:35-41.
2. Sadeghi H, Ghaitasi I, Mazrooghi N, Sabzali S. The hepatoprotective effects of *Dorema auchri* on carbon tetrachloride induced liver damage in rats. *J Shahrekord Univ Med Sci* 2007;9:38-43.

3. Valentao P, Fernandes E, Carvalho F, Andrade PB, Seabra RM, Bastos ML. Antioxidant activity of *Centaureum erythraea* infusion evidenced by its superoxide radical scavenging and xanthine oxidase inhibitory activity. *J Agric Food Chem* 2001 Jul 16;49:3476-9.
4. Bosek P, Nakano M. Hepatoprotective effect of rooibos tea (*Aspalathus linearis*) on CCl₄-induced liver damage in rats. *Physiological Res* 2003;52:461-6.
5. Wollenweber E, Dörr M, Rustiyan A. *Dorema aucheri*, the first umbelliferous plant found to produce exudate flavonoids. *Phytochem* 1995;38:1417.
6. Papageorgiou VP, Assimopoulou AN, Couladouros EA, Hepworth D, Nicolaou KC. The chemistry and biology of alkannin, shikonin, and related naphthazarin natural products. *Angewandte Chemie International Edition* 1999 Feb 1;38:270-301.
7. Pirbalouti AG, Yousefi M, Nazari H, Karimi I, Koohpayeh A. Evaluation of burn healing properties of *Arnebia euchroma* and *Malva sylvestris*. *Electronic J Bio* 2009, 5: 62-6.
8. Sharma RA, Singh B, Singh D. Ethnomedicinal, pharmacological properties and chemistry of some medicinal plants of Boraginaceae in India. *J Medicin Plants Res* 2009 31;3:1153-75.
9. Shen CC, Syu WJ, Li SY, Lin CH, Lee GH, Sun CM. Antimicrobial activities of naphthazarins from *arnebia e uchroma*. *J Nat Prod* 2002;65:1857-62.
10. Sasaki K, Abe H, Yoshizaki F. In vitro antifungal activity of naphthoquinone derivatives. *Biol Pharm Bulletin* 2002;25:669-70.
11. Chen X, Yang L, Zhang N, Turpin JA, Buckheit RW, Osterling C, et al. Shikonin, a component of Chinese herbal medicine, inhibits chemokine receptor function and suppresses human immunodeficiency virus type 1. *Antimicrob agents chemothera* 2003 1;47:2810-6.
12. Yamasaki K, Otake T, Mori H, Morimoto M, Ueba N, Kurokawa Y, Shiota K, et al. Screening test of crude drug extract on anti-HIV activity. *Yakugaku Zasshi: J Pharm Soci Japan* 1993;113:818-24.
13. Kaith BS, Kaith NS, Chauhan NS. Anti-inflammatory effect of *Arnebia euchroma* root extracts in rats. *J ethnopharmacol* 1996;55:77-80.
14. Ebrahimzadeh MA, Nabavi SM, Nabavi SF, Dehpour AA. Antioxidant activity of hydroalcoholic extract of *Ferula gummosa* Boiss roots. *Europ rev med pharmacol sci* 2011;15:658-64.
15. Moradi-Afrapoli F, Shaki F, Heidari M, Seyedmirzaee M, Mandegary A. Hepatoprotective effect of *Polygonum hyrcanicum* methanolic extract on the carbon tetrachloride induced hepatotoxicity in mice. *Iran JPP* 2015;1:43-8.
16. Shokrzadeh M, Ebrahimnejad H, Zear A, Chabra A, Naghshvar F, Ahmadi A. In vivo protective effect of myricetin on liver biochemical damage induced by endosulfan. *J Mazandaran Uni Med Sci* 2016 15;26:28-36.
17. Moradi Afrapoli F. Hepatoprotective effect of methanolic extract from *polygonum hyrcanicum* against CC14-induced toxicity in mice (Doctoral dissertation, School of Pharmacy, Kerman University of Medical Sciences, Kerman, Iran).
18. Ha KT, Yoon SJ, Choi DY, Kim DW, Kim JK, Kim CH. Protective effect of *Lycium chinense* fruit on carbon tetrachloride-induced hepatotoxicity. *J ethnopharmacol* 2005;96:529-35.
19. Ranjbar A, Khorami S, Safarabadi M, Shahmoradi A, Malekirad AA, Vakilian K, et al. Antioxidant activity of Iranian *Echium amoenum* Fisch & CA Mey flower decoction in humans: a cross-sectional before/after clinical trial. *Evid Based Complement Alternat Med*;3:469-73.
20. Misra S, Choudhury RC. Vitamin C modulation of cisplatin-induced cytogenotoxicity in bone marrow, spermatogonia and its transmission in the male germline of Swiss mice. *J chemotherapy* 2006;18:182-7.
21. Brewer MS. Natural antioxidants: sources, compounds, mechanisms of action, and potential applications. *Compr Rev Food Sci Food Saf* 2011;10:221-47.
22. Abdel-Salam OM, Sleem AA, Shaffie NM. Effect of *Viscum album* on acute hepatic damage caused by carbon tetrachloride in rats. *Turkish J Med Sci* 2010;40:421-6.
23. Panovska T, Kulevanova S, Gjorgoski I, Bogdanova M, Petrushevska G. Hepatoprotective effect of the ethyl acetate extract of *Teucrium polium* L. against carbontetrachloride-induced hepatic injury in rats. *Acta pharm* 2007;57:241-8.
24. Lin CC, Chang CH, Yang JJ, Namba T, Hattori M. Hepatoprotective effects of emodin from *Ventilago leiocarpa*. *J ethnopharmacol* 1996;52:107-11.
25. Williams RJ, Spencer JP, Rice-Evans C. Flavonoids: antioxidants or signalling molecules?. *Free Radic Biol Med*;36:838-49.
26. Soni B, Visavadiya NP, Madamwar D. Ameliorative action of cyanobacterial phycoerythrin on CCl₄-induced toxicity in rats. *Toxicol* 2008;248:59-65.
27. Ahsan MR, Islam KM, Bulbul IJ, Musaddik MA, Haque E. Hepatoprotective activity of methanol extract of some medicinal plants against carbon tetrachloride-induced hepatotoxicity in rats. *Eur J Sci Res* 2009;37:302-10.
28. Kinghorn AD. Pharmacognosy in the 21st century. *J Pharm Pharmacol* 2001;53:135-48.
29. Jannu V, Baddam PG, Boorgula AK, Jambula SR. A review on hepatoprotective plants. *Int J Drug Dev Res* 2012;4:1-8.
30. Heidarian E, Jafari-Dehkordi E, Seidkhani-Nahal A. Effect of garlic on liver phosphatidate phosphohydrolase and plasma lipid levels in hyperlipidemic rats. *Food chem toxicol* 2011 1;49:1110-4.
31. Eidi A, Ghalam Z, ShA R, Adeli R. Hepatoprotective effect of *Berberis vulgaris* L. extract on CCl₄-induced toxicity in rats. *Trauma Monthly* 2011:169-73.
32. Parvardeh S, Niapoor M, Hosseinzadeh H. Hepatoprotective activity of *Pistacia vera* L. gum extract in rats. *J Plants* 2002;4:27-34.
33. Nordberg J, Arner ES. Reactive oxygen species, antioxidants, and the mammalian thioredoxin system1. *Free radic biol med* ;31:1287-312.
34. Lauterburg BH, Velez ME. Glutathione deficiency in alcoholics: risk factor for paracetamol hepatotoxicity. *Gut* 1988 1;29:1153-7.
35. Djeridane A, Yousfi M, Nadjemi B, Boutassouna D, Stocker P, Vidal N. Antioxidant activity of some Algerian medicinal plants extracts containing phenolic compounds. *Food chemis* 2006;97:654-60.
36. Mensor LL, Menezes FS, Leitão GG, Reis AS, Santos TC, Coube CS, Leitão SG. Screening of Brazilian plant extracts for antioxidant activity by the use of DPPH free radical method. *Phytotherap res* 2001;15:127-30.