

# Emergency management: acute endophthalmitis



**Nuwan**

**Niyadurupola**

Consultant Ophthalmic Surgeon & Honorary Senior Lecturer: Ophthalmology Department, The Norfolk and Norwich University Hospital NHS Trust, Norwich, UK.

Endophthalmitis can have devastating consequences for a patient's eye and vision. Prompt recognition and urgent treatment are vital.

## How to recognise endophthalmitis

1. Suspect endophthalmitis if **any** of the following symptoms or clinical signs are present, particularly if there is a previous history of surgery, intravitreal injection or penetrating trauma:

- Blurred vision
- Pain
- Red eye
- Hypopyon
- Vitreous opacities
- Swollen eyelids
- Poor red reflex

2. Perform B-scan ultrasonography (if available) to check for vitritis or retinal detachment.

3. Do not try to treat with a course of corticosteroids first – this will delay treatment and may result in losing the eye.

## Protocol: How to respond to the condition

**Do not delay! Treat as a medical emergency**

### Within 1 hour

- Perform an intravitreal tap or vitrectomy through the pars plana (see panel). Collect samples of vitreous for Gram stain and culture. A vitrectomy may be indicated if the patient has perception of light only. *However, if a delay is likely before a vitrectomy can be performed, it is advisable to perform a vitreous tap and inject intravitreal antibiotics for more rapid treatment*

## Technique: How to do an intravitreal tap

- Use aseptic technique with drape
- Instil topical antibiotics and povidone iodine 5%
- Administer subconjunctival or sub-Tenon's anaesthetic
- Insert a 23-gauge or 25-gauge needle 4 mm (phakic eyes) or 3.5 mm (pseudoaphakic/aphakic eyes) behind the limbus into the middle of the vitreous cavity, pointing at the optic disc (approx 7–8 mm deep) and aim to aspirate 0.3–0.5 ml of vitreous fluid.

## Antibiotics

1st choice:

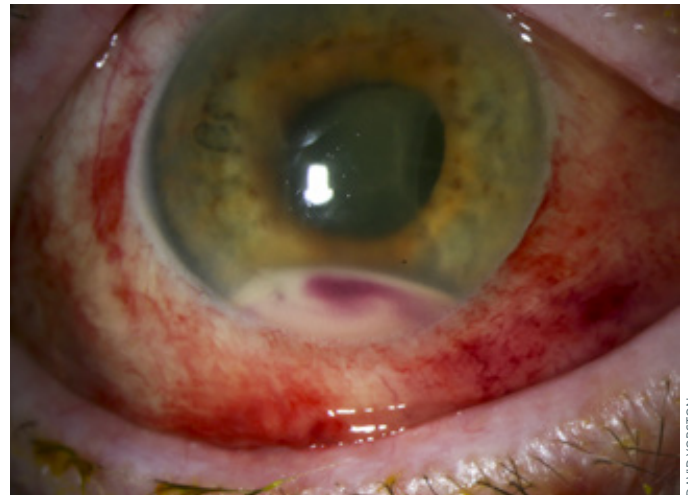- Vancomycin 1 mg in 0.1 ml and
- Ceftazidime 2 mg in 0.1 ml

OR

2nd choice:

- Amikacin 400 µg in 0.1 ml and
- Ceftazidime 2 mg in 0.1 ml

**Note: Use a new syringe and a new 30-gauge needle for each drug. Do not mix drugs together in the same syringe.**



**Endophthalmitis. The eyelids are swollen, the eye is red and a hypopyon is clearly visible.**

- Immediately following the intravitreal tap, inject antibiotics into the vitreous (see panel)
- After injecting intravitreal antibiotics, use a different syringe and a 30-gauge needle to inject preservative-free dexamethasone (400 µg in 0.1 ml) into the vitreous.

### Then

- Consider adjunctive systemic therapy, with the same antibiotics as those used intravitreally, for 48 hours. This will maintain higher levels within the posterior segment of the eye. If systemic antibiotics are not available, topical antibiotics are better than nothing
- Monitor the patient carefully
- Use the response to treatment and the results of Gram stain and culture to determine whether further intravitreal antibiotic therapy is required.

## Preparing for the emergency

An endophthalmitis kit should be accessible in every practice where postoperative patients are seen. This is essential for the prompt diagnosis and treatment of endophthalmitis. Include instructions for preparing the antibiotics (see p. 69).

### Equipment for preparation of patient

- Tetracaine (anaesthetic) drops
- Povidone iodine
- Drape
- Speculum

### Equipment for sub-Tenon's anaesthetic injection

- 10 ml 2% lidocaine
- 10 ml syringe
- Sub-Tenon's cannula
- Westcott scissors

### Equipment for vitreous biopsy/tap

- 23-gauge or 25-gauge needle
- 5 ml syringe
- Calipers

### Equipment for preparation of antibiotic injections

- 1 vial of 500 mg vancomycin or 1 vial of 500 mg (250 mg/ml) amikacin

- 1 vial of 500 mg ceftazidime
- 3 x 10 ml sodium chloride 0.9% injection (saline)
- 4 x 10 ml syringe
- 2 x 5 ml syringe
- 2 x 1 ml syringe
- 1 x sterile galley pot (for amikacin)
- 6 x 21-gauge needles for preparation of antibiotics
- 2 x 30-gauge needles for intravitreal injection

## Instructions for preparation of antibiotic injections

### Vancomycin 1mg/0.1ml

- Reconstitute 500 mg vial with 10 ml saline
- Withdraw all 10 ml into 10 ml syringe
- Inject 2 ml of this solution back into vial
- Add 8 ml saline into vial to make up to 10 ml (10 mg/ml)
- Use 1 ml syringe to draw 0.1 ml of this solution (1 mg/0.1 ml)

### Amikacin 400 µg/0.1 ml

- Use 10 ml syringe to withdraw 1.6 ml of amikacin (250 mg/ml)
- Make up to 10 ml in the syringe with saline
- Discard 9 ml from syringe and make the remaining 1 ml up to 10 ml (in the syringe) by adding saline
- Transfer the solution into a sterile galley pot and use 1 ml syringe to draw 0.1 ml of this solution (400 µg/0.1 ml)

### Ceftazidime 2 mg/0.1 ml

- Reconstitute 500 mg vial with 10 ml saline
- Withdraw all 10 ml into a 10 ml syringe
- Inject 2 ml of this solution back into vial
- Add 3 ml saline into vial to make up to 5 ml (20 mg/ml)
- Use 1 ml syringe to draw 0.1 ml of this solution (2 mg/0.1 ml)

### Further reading

ESCRS Endophthalmitis Study Group. Prophylaxis of postoperative endophthalmitis following cataract surgery: results of the ESCRS multicenter study and identification of risk factors. *J Cataract Refract Surg* 2007;33:978–988.

Endophthalmitis Vitrectomy Study Group. Results of the Endophthalmitis Vitrectomy Study. A randomized trial of immediate vitrectomy and of intravenous antibiotics for the treatment of postoperative bacterial endophthalmitis. *Arch Ophthalmol* 1995;113:1479–1496.

# Emergency management: exposure keratopathy



**Wanjiku Mathenge**  
Consultant Ophthalmologist and Director of Training and Research: Rwanda National Institute of Ophthalmology and Dr Agarwal's Eye Hospital, Kigali, Rwanda.

Exposure keratopathy can result in destruction of the cornea and blindness if not treated urgently.

Exposure keratopathy (also known as exposure keratitis) is damage to the cornea due to dryness caused by incomplete or inadequate eyelid closure, resulting in loss or insufficiency of the tear film. It is usually a mild condition that is simple to treat. However, it can become an eye emergency in the following situations:

- In unconscious patients in intensive care units, when there is inadequate lid closure
- In patients with a facial nerve palsy, which causes paralysis of the eyelids
- In patients who experience a sudden bleed behind the eye (e.g., after a peribulbar or retrobulbar block)
- In patients who have a condition, such as a tumour, that pushes the eye forward and makes it impossible for the eyelids to close (lagophthalmos)
- Following severe damage to the eyelids (particularly the upper lid), such as trauma, burns or scarring from *Herpes zoster* infection
- If corneal sensation is reduced (e.g., following *Herpes zoster* infection). This makes the eye particularly vulnerable to exposure.

If the keratopathy becomes severe, there is a very high risk of irreversible blindness within a matter of hours or days, so treatment must begin immediately.

## Signs and symptoms

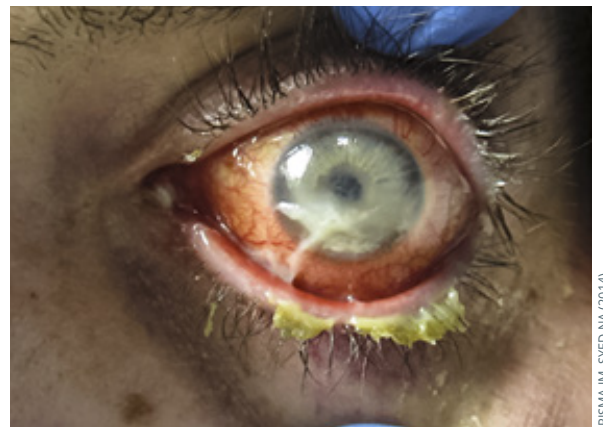
In severe cases, the cornea will look dry and may ulcerate, leading to perforation. Patients will experience pain or irritation, foreign body sensation, burning, blurring of vision, watering, redness and sensitivity to light.

## Examination

Assess lid closure and corneal sensitivity. Perform fluorescein staining of the cornea to assess for infection, thinning, scarring or perforation of the cornea.

## Management

Aim to cover, protect and lubricate the cornea.



Severe keratopathy with ulceration and keratinisation of the cornea.

In the case of a sudden bleed, perform a canthotomy (p. 62) to relieve pressure and allow the eyelids to close.

In case of proptosis from other causes, take care to protect the cornea from exposure where lid closure is compromised. Prescribe frequent lubricating drops (preservative free if possible to avoid toxicity) during the day and lubricating ointment at night.

In patients who cannot close their eyes, either because they are unconscious, or because of a facial nerve palsy, apply lubricating gel and close the eyelid. This can be as simple as a patch, or lid closure using tape. The lids can also be closed using temporary sutures such as a Frost suture, or partially closed by creating a temporary or permanent tarsorrhaphy.<sup>1</sup>

If the eyelids cannot be closed due to loss of the eyelid or severe proptosis, the cornea can be protected using a moisture chamber. A low-cost moisture chamber can be made using plastic wrap.

## When to refer

Patients with sight-threatening complications such as persistent corneal ulceration, microbial keratitis, perforation and corneal scar should be seen by a specialist. Patients with exposure and reduced corneal sensation should also be referred.

## Protecting unconscious patients

Reach out to intensive care unit personnel to explain the dangers of exposure and encourage early detection and referral. Prescribe lubricating drops or ointments to all at risk.

### Further reading

Rajak S, Rajak J, Selva D. Performing a tarsorrhaphy. *Comm Eye Health* 2015;28(89): 10-11.