



---

Volume 2 | Issue 4

Article 12

---

2016

## Acute Limb Ischemia due to a Fractured Superficial Femoral Artery Stent

Alaa Gabi, Ahmed Amro, Haytham Aljoudi, Faisal Hayat, and Rameez Sayyed

Follow this and additional works at: <https://mds.marshall.edu/mjm>

 Part of the [Cardiology Commons](#)



This work is licensed under a [Creative Commons Attribution 4.0 License](#).

---

### Recommended Citation

Gabi, Alaa; Amro, Ahmed; Aljoudi, Haytham; Hayat, Faisal; and Sayyed, Rameez (2016) "Acute Limb Ischemia due to a Fractured Superficial Femoral Artery Stent," *Marshall Journal of Medicine*: Vol. 2: Iss. 4, Article 12.

DOI: <http://dx.doi.org/10.18590/mjm.2016.vol2.iss4.12>

Available at: <https://mds.marshall.edu/mjm/vol2/iss4/12>

DOI: <http://dx.doi.org/10.18590/mjm.2016.vol2.iss4.12>

Open Access |

## References with DOI

1. Iida O, Nanto S, Uematsu M, Morozumi T, Kotani J, Awata M, et al. Effect of exercise on frequency of stent fracture in the superficial femoral artery. *Am J Cardiol.* 2006;98:272–274. <https://doi.org/10.1016/j.amjcard.2006.01.091>
2. Adlakha S, Sheikh M, Wu J, Burket MW, Pandya U, Colyer W, et al. Stent fracture in the coronary and peripheral arteries. *J Interv Cardiol.* 2010;23:411–419. <https://doi.org/10.1111/j.1540-8183.2010.00567.x>
3. B.H. Gray, T.M. Sullivan, M.B. Childs, et al. High incidence of restenosis/reocclusion of stent in the percutaneous treatment of long-segment superficial femoral artery disease after suboptimal angioplasty. *J Vasc Surg.* 1997;25(1):74-83. [https://doi.org/10.1016/s0741-5214\(97\)70323-9](https://doi.org/10.1016/s0741-5214(97)70323-9)
4. Scheinert D, Scheinert S, Sax J, Piorkowski C, Braunlich S, Ulrich M, et al. Prevalence and clinical impact of stent fractures after femoropopliteal stenting. *J Am Coll Cardiol.* 2005;45:312–315. <https://doi.org/10.1016/j.jacc.2004.11.026>
5. Park JY, Jeon YS, Cho SG, et al. Stent fractures after superficial femoral artery stenting. *Journal of the Korean Surgical Society.* 2012;83(3):183-186. <https://doi.org/10.4174/jkss.2012.83.3.183>
6. Dippel EJ, Makam P, Kovach R, et al. Randomized Controlled Study of Excimer Laser Atherectomy for Treatment of Femoropopliteal In-Stent Restenosis: Initial Results From the EXCITE ISR Trial (EXCimer Laser Randomized Controlled Study for Treatment of Femoropopliteal In-Stent Restenosis). *J Am Coll Cardiol Interv.* 2015;8(1\_PA):92-101. <https://doi.org/10.1016/j.jcin.2014.09.009>
7. Palena LM, Cester G, Manzi M. Endovascular treatment of in-stent occlusion: new technique for recanalization of long superficial femoral artery occlusion (direct stent puncture technique) *Cardiovasc Intervent Radiol.* 2012;35:418–421. <https://doi.org/10.1007/s00270-011-0260-5>

## **Acute limb ischemia due to a fractured superficial femoral artery stent**

Alaa Gabi, MD<sup>1</sup>, Ahmed Amro, MD<sup>1</sup>, Haytham Aljouadi, MD<sup>1</sup>, Faisal Hayat, MD<sup>1</sup>, Rameez Sayyed, MD<sup>1</sup>

### **Author Affiliation:**

1. Joan C. Edwards School of Medicine, Marshall University, Huntington, West Virginia

The authors have no financial disclosures to declare and no conflicts of interest to report.

### **Corresponding Author**

Alaa Gabi, MD  
Marshall University  
Huntington, West Virginia  
Email: [gabi@marshall.edu](mailto:gabi@marshall.edu)

## **Abstract**

Peripheral Vascular Disease (PVD) is a rapidly growing and recognized disease of the peripheral circulation. Its presentation can vary between asymptomatic state, exercise limiting limb pain, limb loss and even death. Advances have been achieved in the treatment of PVD especially in the field of interventional cardiovascular medicine. Different devices and techniques are used in the treatment of peripheral atherosclerotic disease, which have lowered the need for bypass surgery. Although invasive peripheral intervention has a low rate of complications, there are still well recognized acute and chronic complications that an operator should be aware of. We present an interesting case of acute limb ischemia due to Superficial Femoral Artery (SFA) stent fracture.

## **Keywords**

fractured stent, acute limb ischemia, pvd

## **Introduction**

Stent fracture is an important reported complication after percutaneous transluminal angioplasty (PTA). The incidence of SFA stent fracture varies between 2 and 65% in several studies.<sup>1</sup>

## **Case Report**

A 71-year-old Caucasian male with significant peripheral arterial disease underwent stenting of the right SFA for critical limb ischemia at another facility. Patient was evaluated for surgical intervention but he was declined due to high operative risk. Five days later while still in the hospital he started having excruciating pain in the right leg. Duplex ultrasound at that facility was suggestive of complete occlusion of the SFA.

The Patient was transferred emergently to our facility for further evaluation and intervention. He was taken emergently to the cardiac catheterization lab. The left femoral artery was accessed using a 4 French arterial sheath that was placed carefully over a guidewire. IMA catheter was then advanced to the contralateral right side and arteriogram was performed. The right SFA was found to be occluded at the ostium (Figure1). The SFA had been stented throughout it's entirety, but, there were at least 2 areas of stent fractures (Figure2). There was no flow through the SFA stent and popliteal area. The right lower extremity had only 1 vessel run-off distally in the posterior tibial artery.

Figure 1: Angiogram of the proximal right lower extremity showing no flow of right femoral artery and right SFA. Also it shows stents of the right femoral artery and right SFA.

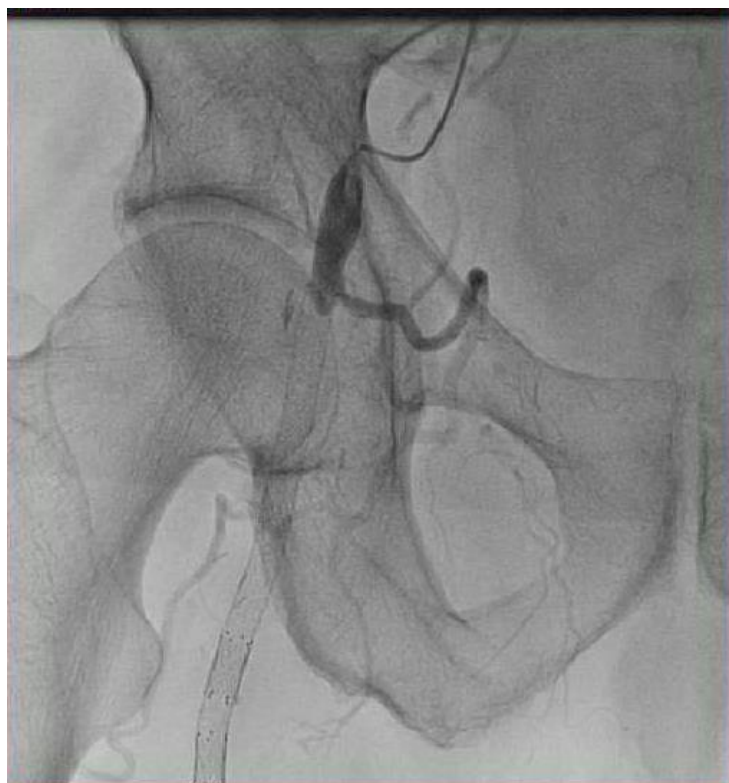
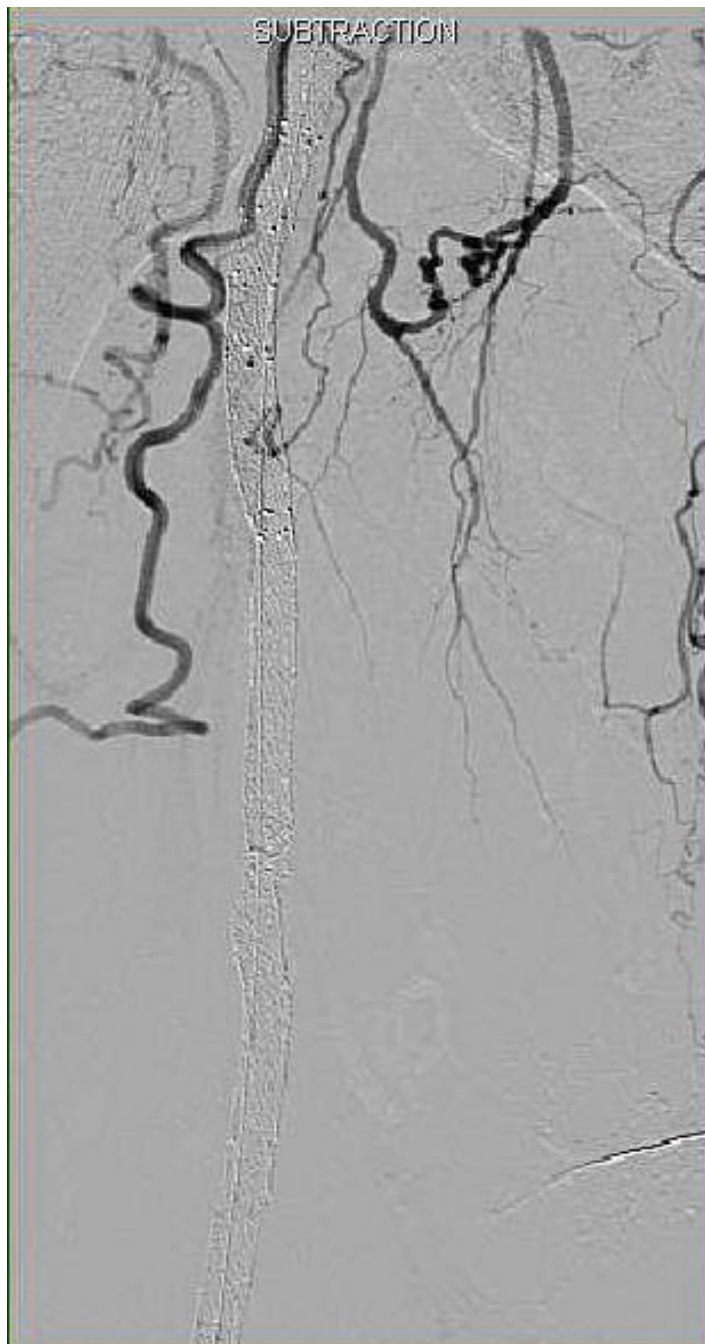


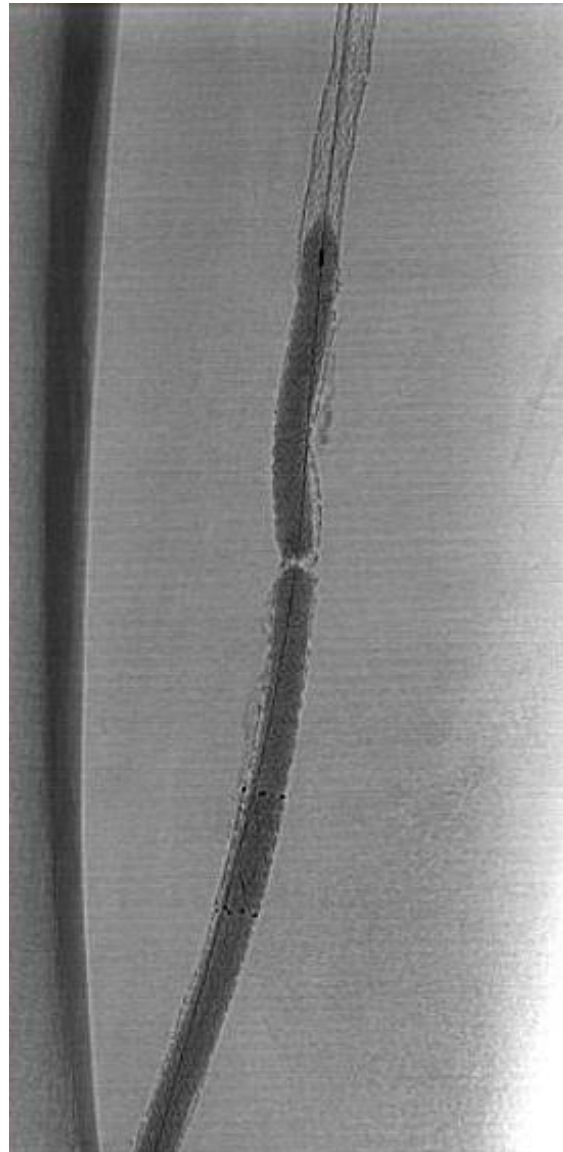
Figure 2: Angiogram of the right lower extremity showing right SFA stent with two areas of fractured stent.



Decision was made to proceed with further intervention. The sheath was then exchanged for a 6 French long sheath over a guidewire. Multiple wires were attempted until we could cross the SFA. After placement of the wire in the infrapopliteal area, the SFA was dilated with a balloon

deployed at 20 atmospheres (Figure 3). The balloon was then taken out. There was significant clot burden in the SFA with no flow. A laser atherectomy was utilized to perform treatment of the right SFA for a total of 1 pass. This area was again dilated with a 6/150mm balloon inflated at 6 atmospheres. Angiogram was performed after removal of the balloon which, again, did not show any flow in the SFA.

Figure 3: Fluoroscopic image showing balloon angioplasty of the right SFA.



The patient had received multiple doses of therapeutic Heparin. Significant clot burden was still noted in the SFA and decision was made to proceed with thrombectomy. Aspiration thrombectomy (Angiojet) was performed for a total of 2 times. The thrombectomy device was taken out and a second pass of laser atherectomy was performed. After all this angiogram still showed no flow in the SFA. At that time manual thrombectomy was performed using a Pronto

extraction catheter. Repeat Angiogram at the end of thrombectomy again showed no flow in the SFA. Finally, the decision was made to place a tPA catheter. The tPA catheter was advanced over a guidewire. The distal tip of the tPA catheter was within the Tibial-Peroneal trunk. The catheter was secured by suturing it down to the skin.

The patient was transferred to the ICU with a tPA drip running at a rate of 2mg/hr for the following 12 hours. The next morning he was taken back to the cath lab for a re-look angiogram. Angiogram through the perfusion catheter revealed better results (Figure 4); flow was seen going down the posterior tibial artery where the perfusion catheter was left. Angiogram of the entire SFA still revealed persistent large volume thrombosis. AngioJet thrombectomy was performed, but, this time with good outcome throughout the SFA as seen on angiogram. Of note, the prior placed stent was found to have 2 areas of stent collapse. Both areas were treated with balloon angioplasty with a 6/100 balloon at high pressure. There was still significant recoil and collapse of the stent at a point with difficulty in passing tools. Stent was deployed to the distal collapsing part of the old stent. The more proximal collapse was treated with a 5.5/120 a stent. Good results were noted at this area with <20% residual disease (Figure 5). Infrapopliteal angiogram was obtained following these interventions, which revealed better results than before.

Figure 4: Angiogram of the right SFA after balloon angioplasty showing restoration of distal blood flow.

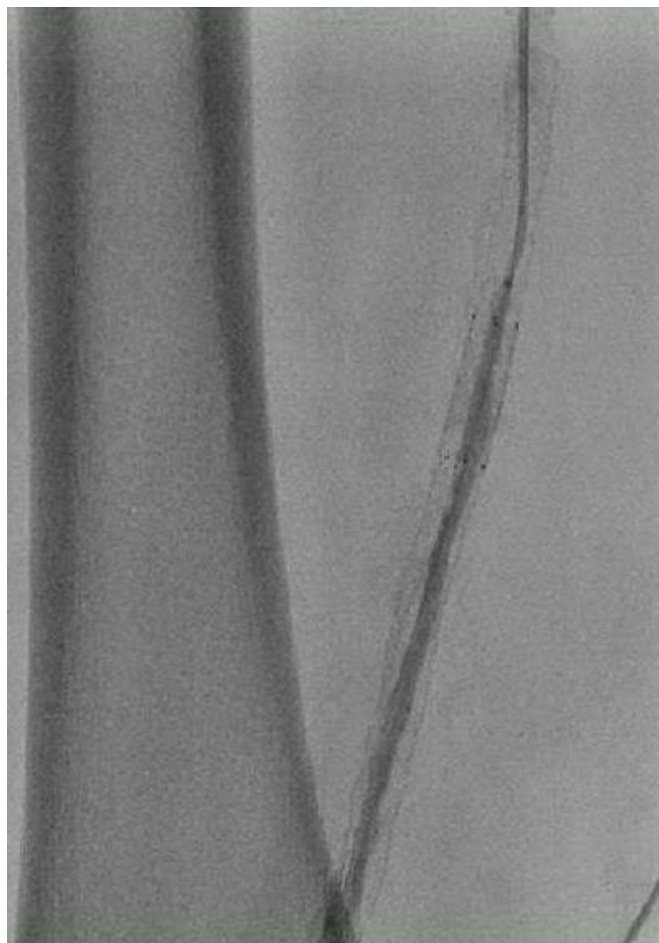
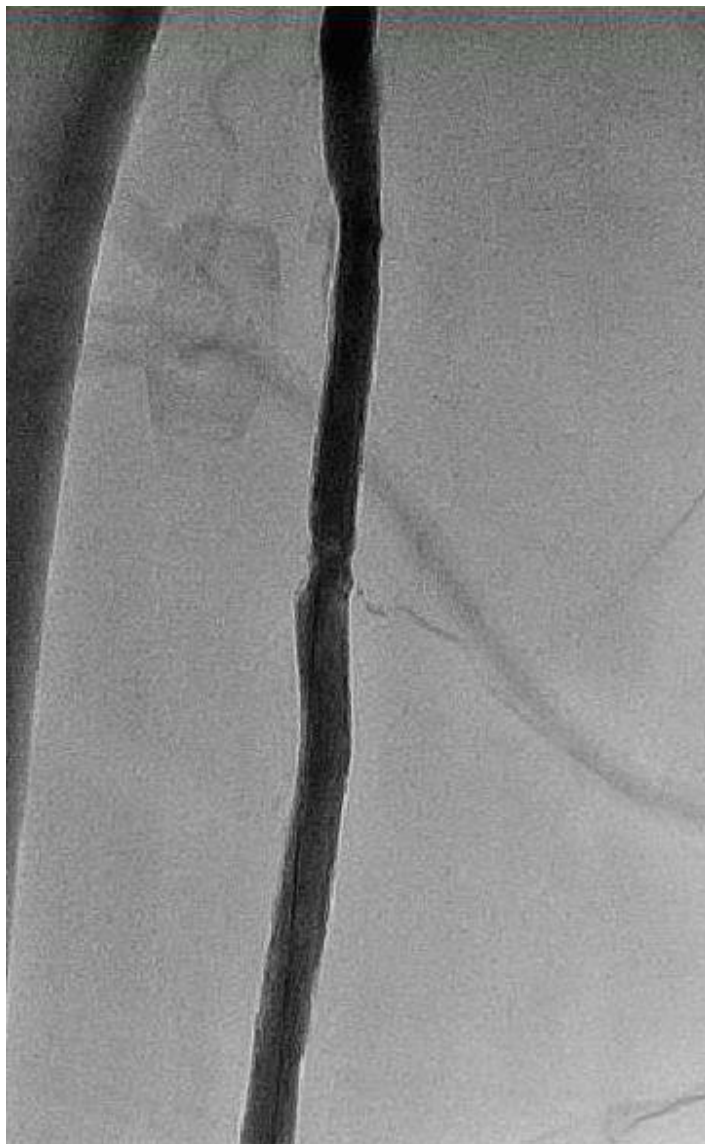



Figure 5: Final Angiogram of the right SFA showing widely patent stent with minimal residual disease.



## Discussion

Stents have emerged as an important therapeutic option in the treatment of infrainguinal PVD. Stent patency rate is a major challenge that faces interventionists. Stent fracture is not an uncommon complication of SFA stenting. The incidence varies between 2 and 65% in several studies.<sup>1</sup> Etiology of stent fracture is related to the manufacturing characteristics of the stent, anatomical location and intrinsic and extrinsic mechanical stress after deployment.<sup>2</sup> Self-expanding nitinol stents showed better outcome compared to first-generation self-expanding

stents. This is attributable to the flexibility of the nitinol alloy used in the manufacture of this type of stents.<sup>3</sup> In our case the fractured stent was a third generation self-expanding stent.

Stent fractures are more common when long-segment stents (> 8 cm) are used as compared to short segment. They are also more common when stent overlapping occurs.<sup>4</sup> The SFA has a superficial course that makes it vulnerable to extrinsic compression from the surrounding thigh muscles with activity, which, in turn, can subsequently lead to stent fracture. There are 5 types of stents fractures; type I is single strut fracture, type 2 is multiple strut fracture, type 3 is complete transverse fracture without displacement, type 4 is complete transverse fracture with displacement and type 5 is transaxial spiral fracture.<sup>5</sup> Stent fracture can be associated with stent thrombosis, perforation and distal embolization.<sup>2</sup>

Management of stent fracture can be either conservative or by intervention which is chosen by different angioplasty techniques or surgical bypass. Angioplasty can be done with or without stenting of the affected area. High thrombus burden if present will warrant using different thrombectomy devices and even thrombolytics, as was done in our case. Laser atherectomy was well studied as an adjunctive mode of treatment for In-stent restenosis and showed superior outcomes in EXCITE-ISR trial compared to conventional percutaneous transluminal angioplasty alone.<sup>6</sup> Even though this trial didn't study the use or safety of laser atherectomy in stent fractures, in our patient we found it to be beneficial. If recanalization remains impossible, another way to manage this is to create a new lumen by passing a wire in the subintimal region at the occlusion site and pass it back to the native lumen distal to it, and deploy a stent to create a track that bypasses the occlusion.<sup>7</sup>

## Conclusion

Stent fracture is a major complication after peripheral vascular angioplasty that creates a challenge to maintain patency on the long run after procedure. This complication requires operators' attention on how to manage it.

## References

1. Iida O, Nanto S, Uematsu M, Morozumi T, Kotani J, Awata M, et al. Effect of exercise on frequency of stent fracture in the superficial femoral artery. *Am J Cardiol.* 2006;98:272–274.
2. Adlakha S, Sheikh M, Wu J, Burket MW, Pandya U, Colyer W, et al. Stent fracture in the coronary and peripheral arteries. *J Interv Cardiol.* 2010;23:411–419.
3. B.H. Gray, T.M. Sullivan, M.B. Childs, *et al.* High incidence of restenosis/reocclusion of stent in the percutaneous treatment of long-segment superficial femoral artery disease after suboptimal angioplasty. *J Vasc Surg.* 1997;25(1):74-83.
4. Scheinert D, Scheinert S, Sax J, Piorowski C, Braunlich S, Ulrich M, et al. Prevalence and clinical impact of stent fractures after femoropopliteal stenting. *J Am Coll Cardiol.* 2005;45:312–315.
5. Park JY, Jeon YS, Cho SG, et al. Stent fractures after superficial femoral artery stenting. *Journal of the Korean Surgical Society.* 2012;83(3):183-186. doi:10.4174/jkss.2012.83.3.183.
6. Dippel EJ, Makam P, Kovach R, et al. Randomized Controlled Study of Excimer Laser Atherectomy for Treatment of Femoropopliteal In-Stent Restenosis: Initial Results From the EXCITE ISR Trial (EXCimer Laser Randomized Controlled Study for Treatment of Femoropopliteal In-Stent Restenosis). *J Am Coll Cardiol Interv.* 2015;8(1\_PA):92-101. doi:10.1016/j.jcin.2014.09.009.
7. Palena LM, Cester G, Manzi M. Endovascular treatment of in-stent occlusion: new technique for recanalization of long superficial femoral artery occlusion (direct stent puncture technique) *Cardiovasc Intervent Radiol.* 2012;35:418–421.