

Science & Research

SPECIFIC TRAUMATIC INJURIES ESTABLISHED ON THE BODY OF A MOTORCYCLIST ASSOCIATED WITH A TRAFFIC ACCIDENT

Mileva B., Apostolov A., Odzhakov F., Ankova M, Gergov G.

Department of Forensic medicine and deontology, Medical faculty - Medical University – Sofia

Corresponding author:

Biliana Mileva, MD

Department of Forensic Medicine and Deontology – Medical University, Sofia

Zdrave 2 Str., Sofia 1431, Bulgaria

Tel.: +359 878 456 219

e-mail: bibs_15@abv.bg

ABSTRACT

Introduction: Traffic accidents are a common cause of traumatic injuries today and are the cause of a great number of deaths. The information, gathered from the site of the accident, the forensic autopsy and the toxicological analysis of blood and urine samples taken from the deceased, reveals the sequence of events leading to the incident, the type of vehicle involved in the crash, the place of the occupants of the vehicle, the cause of the death and the mechanism of occurring of the injuries.

Materials and methods: forensic autopsy of the body; chemical analyses of blood and urine. **Case**

presentation: We present a case of a 30-year-old male motorcyclist who died in a traffic accident, as he was hit and run over by a cargo truck. The body of the deceased was examined in the Department of Forensic medicine and deontology, Sofia. Multiple traumatic injuries were identified, with specific findings on the chest and the abdomen – excoriations with specific shape corresponding to a specific detail (an identification number) of the tire of the motor vehicle. **Discussion:** Traumatic injuries on the chest and abdomen were due to contact with a motor vehicle tire element, expressed as a positive-negative imprint. This statement is firmly proven based on the specific injury located on the thorax and abdomen with visualization of the serial number of the tire. **Conclusion:** Every detail, traumatic injuries and their comparison are essential for the correct interpretation of a traffic accident to recreate the events that led to the incident and its outcomes, i.e. building a situational image of a traffic accident.

INTRODUCTION:

Road-transport incidents are a common cause of traumatism in our time and are associated with a high number of deaths. Road problems and overcrowding in major cities are common, and in this context, motorcycles are becoming an alternative as they are fast, efficient mean of transport. / 3,6,7 /

In-depth study and knowledge of traumatic injuries resulting from road accidents give extremely important information about the type of the vehicle and the way in which injuries are obtained. (8) In the case of incidents in which, after the impact, the perpetrator flees from the scene, based on established traumatic injuries, a relatively accurate estimate of the type of the vehicle involved in the accident as well as its approximate speed can be given. (5) In the case of pedestrian bumps, injuries in the legs or thighs are characteristic, with the height of the injury giving information about the type of the vehicle / passenger car or freight car /. In other cases, based on established traumatic injuries, precise information can be obtained about who the driver was - when a seat belt was fitted, typical line abrasions were produced to help identify the passenger seat in the vehicle. Based on the above, the specific injuries - those that reflect the shape of a particular part of the vehicle, and sometimes the dimensions of a particular detail - a grapple footprint, radiator grille, headlights, steering wheel, etc. - the type and brand of the vehicle, sometimes the specific vehicle, if it has individual peculiarities and defects. / 1 /

The forensic autopsy in the case of traffic accidents victims should provide accurate

information on the sequence of events leading to the incident, the cause of the death of the victim and the mechanism of the traumatic injuries - a process for which a thorough analysis is needed - traumas of death, toxicological analysis of blood and urine samples, thorough examination of motor vehicle defects, and a comprehensive view of the site. / 2,4,9 /

MATERIALS AND METHODS:

- Forensic medical autopsy performed according to the standard section technique;
- Chemical analysis of blood samples for searching for ethyl alcohol - work with the gas chromatography technique;
- Chemical testing of blood and urine samples to search for narcotic substances - works with thin-layer chromatography and UV-spectrophotometry. Urine samples are tested with immunological samples.
- Comprehensive medical and technical expertise.

CASE PRESENTATION: In the Clinic of Forensic Medicine and Deontology, Sofia, the corpse of a 30-year-old man who died in a road accident as a motorcycle hit by a freight vehicle.

During the forensic autopsy, the external examination of the deceased man revealed the following characteristic traumatic injuries: fractures of the bones of the two forearms, with multiple abrasions in the same areas, a disturbed wound in the area of the left palm, depressions in the area of the two hips, knees and feet. An interesting finding in the external examination is an abrasion in the area of the chest and abdomen - starting from the lower third and continuing to the right chest, where with a slight arcuate curve continues down the entire length of the chest and abdomen and reaches the cross-hip area. In its middle part, about one centimeter of it has another tapered pale scarf, parallel to which there is a abrasion with the appearance of the letter "X" and a not readily digitized code of 5-6 elements / Fig. 1, Fig. 2, Fig. 3).

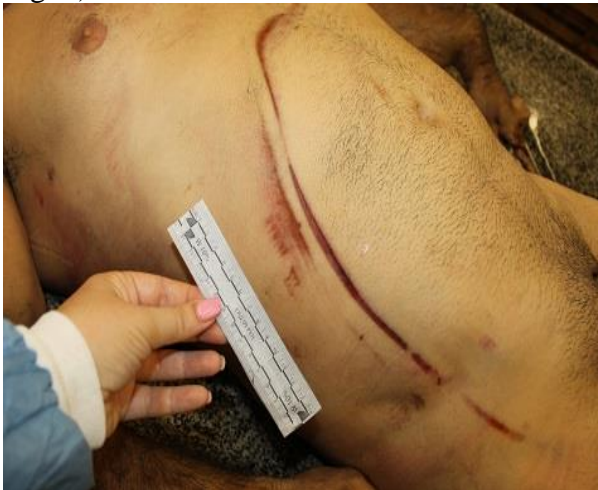

FIGURE 1

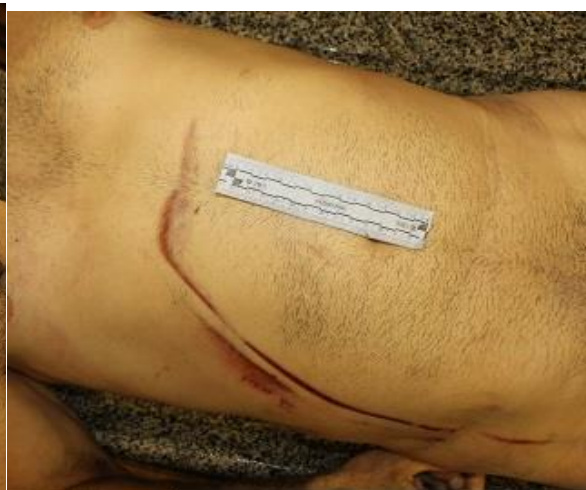

FIGURE 2

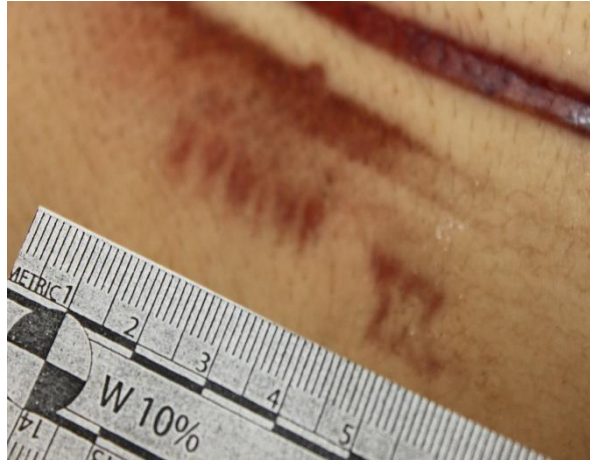


FIGURE 3

In the internal examination of the dead man's body, severe thoracic and abdominal traumas have been identified, consisting of bilateral fracture of the ribs, breakage of the sternum, rupture of the surrounding heart and the right ventricle, with blood in the chest cavity and contusion of the lungs, spleen, liver and gall bladder, with blood in the abdominal cavity, and an injury in the area of renal hylex.

During the autopsy, blood and urine samples were taken to test for the presence of ethyl alcohol, drugs and narcotics - with negative results being reported.

The reason for the death of the motorist is the severe incompatible with life thoracic and abdominal trauma, with the injuries of vital organs and the spilling of blood in the chest and abdominal cavity.

In the case of further material provided at a later stage, photographs from the scene of the accident and the damage to the motor vehicle and the motorcycle, it was found that chest and abdominal injuries represent a specific impression of a tire element of a lorry, as well as part of the rim of the same (fig.4, fig. 5).



FIGURE 4

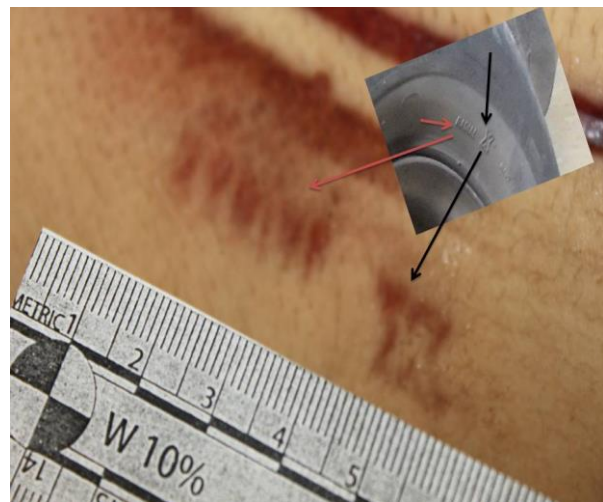


FIGURE 5

DISCUSSION:

Road accidents are one of the leading causes of violent death worldwide. The detailed analysis of the collected materials in each case - site inspection, vehicle defects involved in the incident, forensic autopsy, and chemical analysis of the blood allows to assemble the

overall picture of the incident - what is the cause of the incident - the use of alcohol, illness, structural damage to the road, bad weather, speeding; What type is the vehicle involved in the accident - a car, a lorry etc.; The place of the occupants of the vehicle - who was the driver; What causes the death of the perpetrators and whether it is a cause and effect relationship with the resulting traumatic injuries; What is the mechanism and the way of getting traumatic injuries.

In the case presented, the established traumatic injuries in the external examination of the body - chest and abdomen abrasion, similar to the letter "X" and a numerical code composed of 5-6 elements, were obtained by the mechanism of a positive negative footprint of contact with an element of the tire of a motor vehicle. This statement is strongly demonstrated by the specific damage to the thorax and abdomen with visualization of the serial number of the tire. This finding gives us valuable evidence of the incident, namely that after the motorcycle falls, the motorist hits the tire of the truck, which is the deadly stroke that caused the severe and incompatible with the life of the thoracic-abdominal trauma, severely damaging the internal organs.

CONCLUSION:

On the basis of the above, it can be concluded that comparative analysis between each structural detail and traumatic injury is crucial for the correct interpretation of a traffic accident to recreate the sequence of events leading to the incident and its results.

REFERENCES:

1. Стойчо Раданов et al, Учебник по Съдебна медицина и деонтология, 2006, pages 88-103.
2. Elisabeth E. Turk, Cardiac injuries in car occupants in fatal motor vehicle collisions – An autopsy-based study, Jurnal of Forensic and legal medicine, august 2010, Volume 17, Issue 6, Pages 339-343.
3. F P Rivara, Injuries and death of children in rollover motor vehicle crashe in the United States, Injury Prevention 2003;9:76-80.
4. Jan Mario Breen; Paal Aksel Naess; Christine Gaarder; Arne Stray-Pedersen. Case characteristics and injury mechanisms in motor vehicle accidents in South East Norway from 2000 to 2014: An autopsy study, Journal of Local and Global Health Science 2015;12 <http://dx.doi.org/10.5339/jlghs.2015.itma.12>.
5. Jonathan R Lucas, MD: Forensic Investigation - Motor Vehicle Accidents and Motor Vehicle-Pedestrian Accidents, jan 25, 2015.
6. José Gustavo Parreira et al: Comparative analysis of injuries observed in motorcycle riders involved in traffic accidents and victims of other blunt trauma mechanisms, Revista da Associação Médica Brasileira (English Edition), Volume 58, Issue 1, January–February 2012, Pages 76-81.
7. Josep Ferrando et al, Motor-Vehicle Injury Patterns in Emergency-Department Patients in a South-European Urban Setting, Annu Proc Assoc Adv Automot Med. 2000; 44: 445–458.
8. Kazuhiko Kibayashi, Ryo Shimada, Ken-inchiro Nakao: Fatal traffic accidents and forensic medicine IATSS Research, Volume 38, Issue 1, July 2014, Pages 71–76.
9. Stephen Luchter, Fatal Injuries in Light Vehicle Crashes - Time to Death and Cause of Death, Annu Proc Assoc Adv Automot Med. 1998; 42: 277.