

CASE REPORT
IN EMERGENCY MEDICINE

Spontaneous splenic rupture in a teenager as first manifestation of acute myeloid leukemia: Case report and literature review

Antonio Villa¹, Simona Rossi², Isabella Riva¹, Cecilia Tedesco³,
Francesca Maria Zanchettin¹, Rinaldo Chiumento⁴

Affiliations:

¹ M.D., Department of Emergency, ASST Monza, PO Desio, Monza, Italy

² M.D., Department of Pediatrics, ASST Monza, PO Desio, Monza, Italy

³ M.D., Department of Anesthesiology and Critical Care, ASST Monza, PO Desio, Monza, Italy

⁴ M.D., Department of Radiology, ASST Monza, PO Desio, Monza, Italy

Corresponding author:

Dr. Antonio Villa, ASST Monza, PO Desio, Via Fiuggi, 56 20159 Milan, Italy.

E-mail: antonio_villa@fastwebnet.it

Abstract

Spontaneous splenic rupture is a well-known, but rare life-threatening complication of hematological malignancies. We describe the case of a 12-year-old boy with a 5-day history of fever and successively left upper quadrant abdominal pain and sudden clinical deterioration necessitating emergency splenectomy. On arrival, a blood dyscrasia was postoperatively confirmed as acute myeloid leukemia. Cases of atraumatic rupture in diseased spleens are widely reported and pathological rupture of the spleen is a rare, but well recognized complication in hematological malignancies. This case report represents a rare and fatal initial presentation of acute myeloid leukemia in an adolescent. Because of the rarity of atraumatic splenic rupture, a high index of clinical suspicion must be maintained in patients with left upper quadrant pain and abnormal differential count on peripheral blood smear.

KEY WORDS: Acute myeloid leukemia; spontaneous splenic rupture; ultrasonography.

Riassunto

La rottura di milza spontanea è una complicanza di neoplasie maligne ematologiche ben conosciuta, ma rara e potenzialmente mortale. Descriviamo il caso di un ragazzo di 12 anni con una storia di febbre da cinque giorni e successiva comparsa di dolore al quadrante addominale superiore sinistro ed improvviso deterioramento delle condizioni cliniche che ha richiesto la splenectomia in urgenza. All'arrivo, un'alterazione dei valori ematici è stata confermata, dopo l'intervento chirurgico, quale una leucemia mieloide acuta. Casi di rottura spontanea in milze patologiche sono ampiamente riportati e la rottura patologica di milza è una complicanza rara, ma ben conosciuta, di patologie maligne del sistema ematopoietico. Questo caso clinico rappresenta una rara e fatale presentazione iniziale di leucemia mieloide acuta in un adolescente. A causa della rarità della rottura patologica di milza, un elevato livello di sospetto clinico deve essere mantenuto in pazienti con dolore al quadrante addominale superiore sinistro ed alterazioni dello striscio di sangue periferico.

TAKE-HOME MESSAGE

Spontaneous splenic rupture should be considered in case of blood dyscrasia associated with abdominal pain and a clinical picture of hemodynamic instability, in previously healthy patients without a traumatic background.

Competing interests - none declared.

Copyright © 2018 Antonio Villa et al. Edizioni FS Publishers

This is an open access article distributed under the Creative Commons Attribution (CC BY 4.0) License, which permits unrestricted use, distribution, and reproduction in any medium, provided the original work is properly cited. See <http://www.creativecommons.org/licenses/by/4.0/>.

Cite this article as: Villa A, Rossi S, Riva I, Tedesco C, Zanchettin FM, Chiumento R. Spontaneous splenic rupture in a teenager as first manifestation of acute myeloid leukemia: Case report and literature review. J Health Soc Sci. 2018;3(3):297-302

DOI 10.19204/2018//spnt3

Received: 07/08/2018

Accepted: 14/09/2018

Published online: 05/10/2018

INTRODUCTION

Spontaneous splenic rupture is a well known, but rare life-threatening complication of hematological malignancies. Rokitansky first described spontaneous splenic rupture in leukemia in 1861 [1]. Since that time, no more than 40 cases of splenic rupture associated with leukemias have been reported in literature. In the last 30 years only 19 cases have been associated with acute myeloid leukemia (AML) [2–20] and only 6 cases of them as a first manifestation of AML [5, 10, 12–14, 20]. We describe the case of a 12-year-old boy with a 5-day history of fever and successively left upper quadrant pain and sudden clinical deterioration necessitating emergency splenectomy. Preoperatively, the patient was diagnosed with spontaneous splenic rupture and blood dyscrasia, and postoperatively, this was confirmed as AML.

CASE REPORT

A 12-year-old boy presented to the Emergency Department (ED) with a history of mesogastric and left-sided abdominal pain. There was no history of trauma. He and his mother subsequently recalled a 5-day history of fever and shortness of breath. On initial presentation, his vital signs were as follows: blood pressure: 100/80 mm/Hg; temperature: 38°C; pulse: 140 beats per minute; saturation: 87%; and respiration rate: 28 per minute. The physical examination revealed generalized pallor and dry skin; upon palpation of the abdomen, it was soft, although diffusely painful, accentuated in the left upper quadrant; spleen was not evaluable and hepatomegaly was appreciable.

An Extended Focused Assessment with Sonography for Trauma (US-FAST) examination, conducted to detect the etiology of hypotension, revealed diffuse free fluid and hepatosplenomegaly with splenic laceration, from upper to lower pole; an intraparenchymal hematoma in lower pole (6 x 10 x 2.5 centimeters) was also present. Abdominal computed tomography scan confirmed ultrasound data (Figure 1). Since the patient was thought to be in hemorrhagic shock, fluid re-

placement was administered, and transfusion blood products was commenced. The patient was admitted to perform an urgent laparotomy and splenectomy.

Pathological examination showed a spleen of 200 x 150 x 90 mm in size with a weight of 870 g and a parenchymal rupture with partially active bleeding. The microscopic evaluation of the spleen revealed a widespread infiltration of monocytic cells with focally blasts positive for CD117 and rarely for CD34. Overall finding was consistent with localization of acute myeloproliferative process with monocytic differentiation.

His complete blood count revealed the following: total white blood cell count 38.3 x 10³/μL with 31% of monocyte; hemoglobin 9.9 g/dL; platelet count 59 x 10³/μL.

The patient's peripheral blood smear showed 80% on monocytic blasts. The bone marrow examination revealed a marked proliferation of monocytic blasts (90%) positive for CD11a, CD11b, CD11c, CD13, CD14, CD15, CD33, CD64, CD65 and negative for CD34, CD56 and CD117.

After surgery, the patient remained hypotensive and needed amine support with no response to aggressive resuscitative measures. The next day, he developed septic shock with multiorgan failure and after 2 days from presentation he died.

DISCUSSION

Rupture of the spleen is relatively common following significant blunt abdominal injury and this phenomenon is well documented in the scientific literature [21]. Cases of atraumatic rupture in diseased spleens are also widely reported [22] and pathological rupture of the spleen is a rare but well recognized complication in hematological malignancies, but in our case the hematological diagnosis was not defined when the patient arrived in the ED.

A 2012 systematic review of cases of splenic rupture in which there was not an immediately obvious cause on presentation such as significant trauma (either recent or remote) or previously diagnosed disease known

to affect the spleen has been reported [21]. Among the 613 studied cases, the most common associated disease were infectious ($n = 143$), hematologic ($n = 84$) and non-hematologic neoplasms ($n = 48$). Moreover, among hematologic cases only 6 were associated to AML [21]. We conducted a further review of papers indexed in PubMed and two new cases have been published since 2012 [14, 20], as first manifestation of AML. Because the splenic rupture is a rare clinical entity, its incidence in pediatric population has not yet been established and most reported cases are associated with infections [23]. Athale and colleagues [24] investigated the frequency of splenic rupture in pediatric patients with hematologic malignancies. From 1962 to 1997 they reported splenic rupture in 7 children; primary diagnosis included AML in 4 patients, acute lymphocytic leukemia in 2 patients, and Hodgkin lymphoma in one case. Spontaneous splenic rupture is a rare event encountered in the ED, and when the diagnosis is delayed, it is potentially at risk of life. Generally, the most common symptom is abdominal pain in the left upper quadrant. The pain can be generalized with distension and rigidity in later stages. Abdominal symptoms may be accompanied by nausea, vomiting, dizziness, paleness, tachycardia, hypotension and alterations of hemodynamic parameters [20, 23, 25]. Clinical assessment and laboratory evalua-

tion should be accompanied by emergent ultrasound evaluation due to its ready availability and high specificity (from 91 to 100%) for detecting splenic rupture and intra-abdominal free fluid [15]. US-FAST has been also considered as an effective diagnostic tool in hemodynamically unstable patient [26]. The etiology of splenic rupture in hematologic malignancies remains to be firmly established. The possible mechanisms suggested thus far include mechanical effect of distension secondary to leukemic infiltration of the spleen, especially the capsule; splenic infarction with capsular hemorrhage and subsequent rupture; and leukemia-associated coagulopathy [12, 13]. Splenectomy is the treatment of choice in patients hemodynamically instable with intractable splenic rupture [13]. Without surgical intervention, the mortality rate reported in this population approaches 100% [13]. In children, the splenic preservation is always preferred to minimize the risk of infection. In this young population, the risk of developing post-splenectomy septicemia is 4% with a mortality rate of 1.8% [23]. According to the splenic damage severity scale based on the size and location of lacerations and splenic hematomas, high-grade lesions (American Association for the Surgery of Trauma [AAST] grade III and higher) require surgical therapy [27]. However, there is evidence that the clinical situation should be the most im-

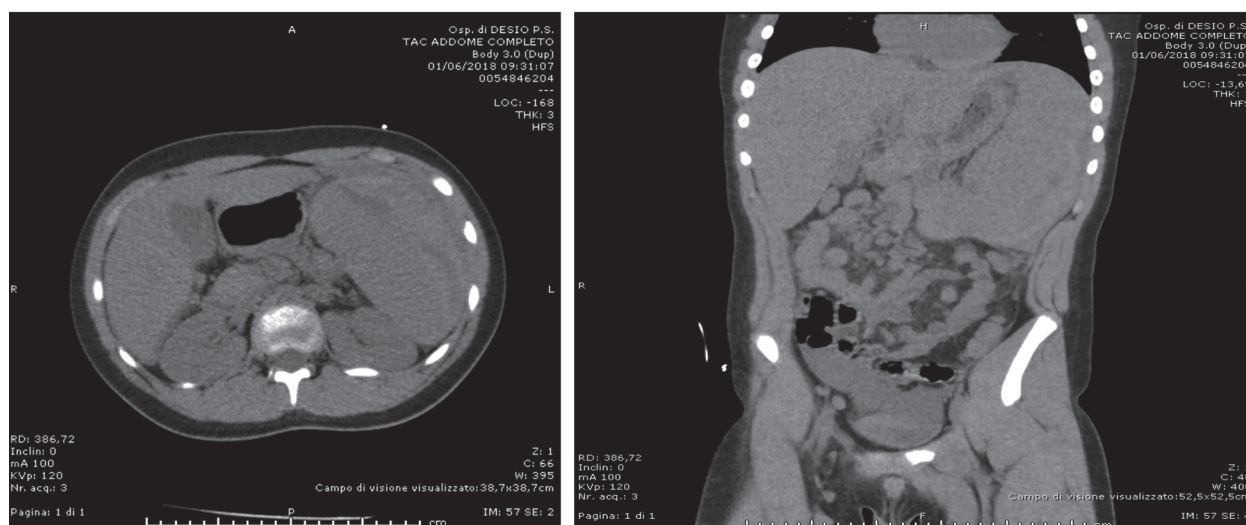


Figure 1. Computed tomographic scan of the abdomen showing splenomegaly, splenic linear laceration, intraparenchymal hematoma in lower pole, and perihaptic, perisplenic and pelvic free fluid.

portant factor in decision-making guidance. Recently, a system of scales based on multi-detector computed tomography has been proposed to improve the accuracy of predicting the need of intervention, compared with the traditional AAST scale [28–30].

CONCLUSION

This case represents a rare and fatal initial presentation of AML in an adolescent. Because of the rarity of atraumatic splenic rup-

ture, a high index of clinical suspicion must be maintained in patients with left upper quadrant abdominal pain and abnormal differential count on peripheral blood smear.

In emergency, spontaneous splenic rupture should be considered in case of blood dyscrasia associated with abdominal pain and a clinical picture of hemodynamic instability, in previously healthy patients without a traumatic background as well.

References

1. Rokitansky KF. Two recent cases of spontaneous rupture of the spleen. *Wochenblatt der Zeitschrift der k k Gesellschafht der Aerzte in Wien*. 1861;17:42–44.
2. Canady MR, Welling RE, Strobel SL. Splenic rupture in leukemia. *J Surg Oncol*. 1989;41(3):194–197.
3. Borgeat A, Tran-Thang C, Bachmann F. Acute monoblastic leukemia complicated by fatal splenic rupture following initiation of chemotherapy. *Schweiz Med Wochenschr*. 1989;119(7):227–229.
4. Lazzarino M, Morra E, Castagnola C, Inverardi D, Dore R, Catona A, Bernasconi C. Spontaneous splenic rupture during induction chemotherapy for acute promyelocytic leukemia successfully treated with splenectomy. *Haemathologica*. 1990;75(1):84–86.
5. Serur D, Terjanian T. Spontaneous rupture of the spleen as the initial manifestation of acute myeloid leukemia. *N Y State J Med*. 1992;92(4):160–161.
6. Zimmer BM, Berdel WE, Ludwig WD, Notter M, Reufi B, Thiel E. Fatal spleen rupture during induction chemotherapy with rh GM-CSF priming for acute monocytic leukemia. Clinical case report and in vitro studies. *Leuk Res*. 1993;17(3):277–283.
7. Guth AA, Pachter HL, Jacobowitz GR. Rupture of the pathologic spleen: is there a role for nonoperative therapy? *J Trauma*. 1996;41(2):214–218.
8. Kasper C, Jones L, Fujita Y, Morgenstern GR, Scarffe JH, Chang J. Splenic rupture in a patient with acute myeloid leukemia undergoing peripheral blood stem cell transplantation. *Ann Hematol*. 1999;78(2):91–92.
9. Hernandez R, del Cañizo MC, Lopez C, Gonzalez MI, Vazquez ML, Caballero MD, et al. Pathologic rupture of the spleen during induction with ATRA in a patient with acute promyelocytic leukemia. *Med Oncol*. 2000;17(4):337–339.
10. Rajagopal A, Ramasamy R, Martin J, Kumar P. Acute myeloid leukemia presenting as splenic rupture. *J Assoc Physicians India*. 2002;50:1435–1437.
11. Görg C, Cölle J, Görg K, Prinz H, Zugmaier G. Spontaneous rupture of the spleen: ultrasound patterns, diagnosis and follow-up. *Br J Radiol*. 2003;76(910):704–711.
12. Tan A, Ziari M, Salman H, Ortega W, Cortese C. Spontaneous rupture of the spleen in the presentation of acute myeloid leukemia. *J Clin Oncol*. 2007;25(34):5519–5520.
13. Han JS, Oh SY, Kim SH, Kwon HC, Hong SH, Han JY, et al. A case of pathologic splenic rupture as the initial manifestation of acute myeloid leukemia M2. *Yonsei Med J*. 2010;51(1):138–140.
14. Singhal V, Kuiper J, Chavda K, Kashmer D. Spontaneous splenic rupture as first manifestation of acute myeloid leukemia: case report and review of literature. *J Clin Oncol*. 2011;29(19):e576–578.
15. Maqbool MS, Brush RG, Northrup M. Atraumatic splenic rupture. *Ultrasound Q*. 2014;30(3):208–210.
16. Zeidan A, Mitchell M, Khatri R, Itani D, Boikos S, Bose S, et al. Spontaneous splenic rupture during induction chemotherapy for acute myeloid leukemia. *Leuk Lymphoma*. 2014;55(1):209–212.
17. De Santis GC, Oliveira LC, Ramos AF, da Silva ND, Falcão RP. Pathologic rupture of the spleen in a pa-

- tient with acute myelogenous leukemia and leukostasis. *Rev Bras Hematol Hemoter.* 2014;36(4):290–292.
18. Kuba A, Szotkowski T, Rohon P, Faber E, Turcsanyi P, Hubacek J, et al. Spontaneous splenic rupture in a patient with acute promyelocytic leukaemia during induction chemotherapy. *Biomed Pap Med Fac Univ Palacky Olomouc Czech Repub.* 2015;159(2):294–298.
 19. Modi D, Mamdani H, Deol A. Malignant cause of abdominal pain in leukemia: spontaneous splenic rupture. *Am J Med Sci.* 2015;349(2):189–190.
 20. Aydin AA, Şenocak R, Bilge S, Kaymak S, Kilbaş Z. Nontraumatic splenic rupture as the initial manifestation of acute myeloid leukemia in emergency department. *Am J Emerg Med.* 2016;34(8):1731.e1-3
 21. Aubrey-Bassler FK, Sowers N. 613 cases of splenic rupture without risk factors or previously diagnosed disease: a systematic review. *BMC Emerg Med.* 2012;12:11–25.
 22. Renzulli P, Hostettler A, Schoepfer AM, Gloor B, Candinas D. Systematic review of atraumatic splenic rupture. *Br J Surg.* 2009;96(10):1114–1121.
 23. Gomez-Ramos JJ, Marin-Medina A, Lisijuan-Bracamontes J, Garcia-Ramirez D, Gust-Parra H, Ascencio-Rodriguez MG. Adolescent with spontaneous splenic rupture as a cause of hemoperitoneum in the Emergency Department: case report and literature review. *Pediatr Emerg Care.* 2018 May 23. doi: 10.1097/PEC.0000000000001520. [Epub ahead of print].
 24. Athale UH, Kaste SC, Bodner SM, Ribeiro RC. Splenic rupture in children with hematologic malignancies. *Cancer.* 2000;88(2):480–490.
 25. Rhee SJ, Sheena Y, Imber C. Spontaneous rupture of the spleen: a rare but important differential of an acute abdomen. *Am J Emerg Med.* 2008;26(6):733.e5-6.
 26. Rose JS, Bair AE, Mandavia D, Kinser DJ. The UHP ultrasound protocol: a novel ultrasound approach to the empiric evaluation of the undifferentiated hypotensive patient. *Am J Emerg Med.* 2001;19(4):299–302.
 27. Moore EE, Cogbill TH, Jurkovich GJ, Shackford SR, Malangoni MA, Champion HR. Organ injury scaling: spleen and liver (1994 revision). *J Trauma.* 1995;38(3):323–324.
 28. Weaver H, Kumar V, Spencer K, Maatouk M, Malik Ş. Spontaneous splenic rupture: a rare life-threatening condition; diagnosed early and managed successfully. *Am J Case Rep.* 2013;14:13–15.
 29. Tonolini M, Bianco R. Nontraumatic splenic emergencies: cross-sectional imaging findings and triage. *Emerg Radiol.* 2013;20(4):323–332.
 30. Soto JA, Anderson SW. Multidetector CT of blunt abdominal trauma. *Radiology.* 2012;265(3):678–693.