



Poultry Science Journal

ISSN: 2345-6604 (Print), 2345-6566 (Online) <http://psj.gau.ac.ir>
DOI: 10.22069/psj.2019.15801.1374



Subcutaneous and Deep Lipomas in Exotic and Nigerian Indigenous Chickens: A Case Report

Musa IW¹, Sani NA², Gaba EE³ & Lawal MI¹

¹Department of Veterinary Medicine, Ahmadu Bello University Zaria, Nigeria

²Department of Veterinary Pathology, University of Abuja, Nigeria

³Veterinary Teaching Hospital, Ahmadu Bello University Zaria, Nigeria

Poultry Science Journal 2019, 7(1): 1-6

Keywords

Surgical
Chicken
Deep-lipoma
Management
Subcutaneous

Corresponding author

Waziri Ibrahim Musa
ibwazkalt@yahoo.co.uk

Article history

Received: December 4, 2018

Revised: April 2, 2019

Accepted: April 21, 2019

Abstract

Three case reports describing the clinicopathological diagnosis and surgical management of subcutaneous lipomas in adult exotic and Nigerian indigenous chicken, as well as deep lipoma in exotic chickens are here presented. One dead and two live chickens were presented to the Poultry Clinic, Veterinary Teaching Hospital, Ahmadu Bello University, Zaria, Nigeria, on the 15th October, 2016 and 13th August, 2017, respectively. The live indigenous hen was presented with a slow growing 8 month-old large mass on the right, ventro-lateral aspect of the neck. The mass was clinically observed to be pendulous, circumscribed, soft, lobulated, painless, subcutaneous seated and about 8 cm in diameter. The two dead exotic birds were earlier presented with the first having a similar lesion of different dimensions located in the ventro-lateral aspect of the left thigh and the second with lesions in the liver. Cytological evaluation of fine needle aspirates of the masses revealed well differentiated adipocytes interspersed with nucleated red blood cells. Consequently, the masses were tentatively diagnosed as subcutaneous and deep lipomas, and the management decision taken in the live chicken was surgical following standard procedures. Sections of the excised masses were fixed in 10% neutral buffered formalin and processed for histopathological examination. Histopathology revealed well differentiated adipocytes of uniform sizes interspersed with few blood vessels and connective tissue. Final diagnoses of lipomas were made. Depending on location and possible complications, subcutaneous lipomas may not be life threatening but they can be a source of discomfort to the patient and may cause emotional distress to their owners if not removed surgically. Deep lipomas may compromise organ functions leading to death.

Introduction

Over sixty percent of chicken population in Nigeria is indigenous breeds. One form of classification has it as those with normal feathers, frizzled feathers, and the naked neck (Fayeye and Oketoyin, 2006; Adeleke *et al.*, 2011). Chickens play significant socio-cultural roles in Nigeria and many rural communities in developing nations (Sonaiya and Olori, 1989; Kperegbeyi *et al.*, 2009; Padhi, 2016). The naked neck breed is not so common and is phenotypically characterized by the absence of or if present, few feathers on the neck. A feature that assists very much in its thermoregulatory ability, and therefore makes it

well suited to withstand the hot climatic conditions of the tropics (Merat, 1990). The naked neck is also known to be tolerant to many chicken infectious diseases (Hernandes *et al.*, 2002) and believed to have better productive traits (Merat, 1990; Yalcin *et al.*, 1997) thus attracting special care. Despite these good qualities of the naked neck chicken, it is faced with the danger of being extinct in the near future as it has been documented to be only 6% of the Nigerian indigenous chicken (Sonaiya and Olori, 1989). This may be why owners of the naked neck chickens often attach high importance to the wellbeing of their

chickens and will therefore report sick birds to the nearest Veterinary Clinics and where the need arises referred to Veterinary Teaching Hospitals.

Neoplasm is an abnormal, uncontrolled, progressive proliferation of cells in any tissue or organ (Latimer, 1994). Lipomas are benign mesenchymal neoplasms of adipose and subcutaneous tissues that normally occur in areas of abundant adipose tissue. They are mainly derived from mesenchymal preadipocytes and not mature adipocytes but are composed of various proportions of fat and hematopoietic cells that closely resemble those of normal adipose tissues (Latimer and Rakich, 1995; Arora and Madaan, 2016). They are the commonest soft tissue tumors with about 20 % located in the proximal extremities involving mainly the head and neck region. Many can be found in the upper back, the neck, the shoulder and sometimes the abdomen (Kransdorf, 1995; Medina *et al.*, 2007; Hammedi *et al.*, 2013; Arora and Madaan, 2016). Predisposing factors to the development of lipoma include obesity, age, genetics and high energy diets (Latimer, 1994). Subcutaneous lipomas are usually painless, soft, circumscribed, round, lobulated and pale yellow (Turrel *et al.*, 1987; Medina *et al.*, 2007; Hammedi *et al.*, 2013). Cytological examination of fine needle aspirate from a lipoma provides a presumptive diagnosis, and is characterized by adipocytes appearing as large balloon-like cells arranged in aggregates held together by fine

fibrovascular stroma (Boes, 2013). A definitive diagnosis requires histopathologic examination of surgical biopsies of the neoplasm (Latimer, 1994; Hammedi *et al.*, 2013). Complete surgical excision, if permitted by owners, can be curative (Boes, 2013).

Even though lipomas have been reported in birds, this is probably the first report of lipoma management in the naked neck type of Nigerian indigenous chicken. This brief communication further reports lipomas originating from the subcutaneous tissues and liver in two exotic birds.

Case History

An adult Nigerian indigenous hen weighing about 1.2 kg from a flock of 10 chickens was presented to the Poultry Clinic, Veterinary Teaching Hospital, Ahmadu Bello University, Zaria, on 13th June 2017, with a complaint of a large growth on the neck, which was first noticed about 8 months ago. The flock of chickens was on free range with irregular grain supplementation. The mass continued to increase in size despite several local attempts at treatment.

Clinical Examination

Physical examination revealed a subcutaneously located large dome-shaped, pendulous, soft mass on the right ventro-lateral aspect of the neck just below the wattles (Figure 1.A). Upon palpation, the mass was soft, painless, multilobulated and freely movable under the skin.

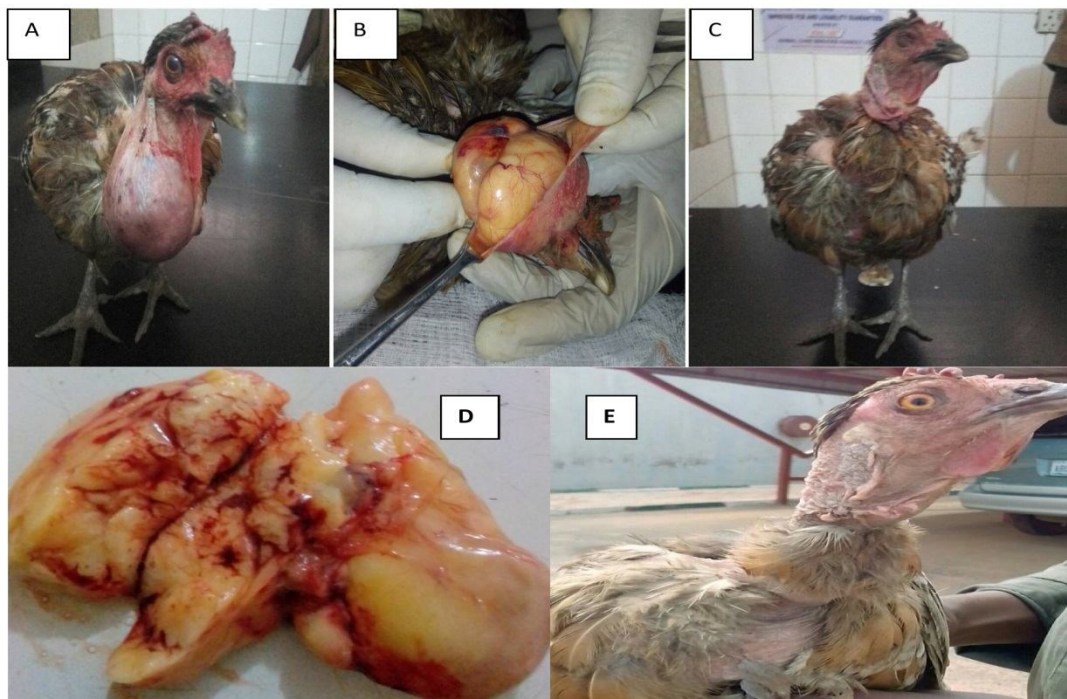


Figure 1. A subcutaneous lipoma in a Nigerian indigenous chicken. A. Note the large subcutaneous mass on the right ventral aspect of the neck. B. Note the yellow, lobulated mass exteriorized at surgery. C. Note the chicken after surgical resection of the mass. D. Note the vascularized cut surface of the yellow lobulated mass. E. Note the chicken 14 days post-surgery.

Cytological Examination

A fine needle aspirate of the mass was air dried on a clean grease-free slide and stained with Giemsa stain. Microscopic examination of the slide revealed

aggregates of round to irregularly shaped vacuoles of varying sizes interspersed with nucleated red blood cells (Figure 2. A). Therefore, the mass was provisionally diagnosed as a subcutaneous lipoma.

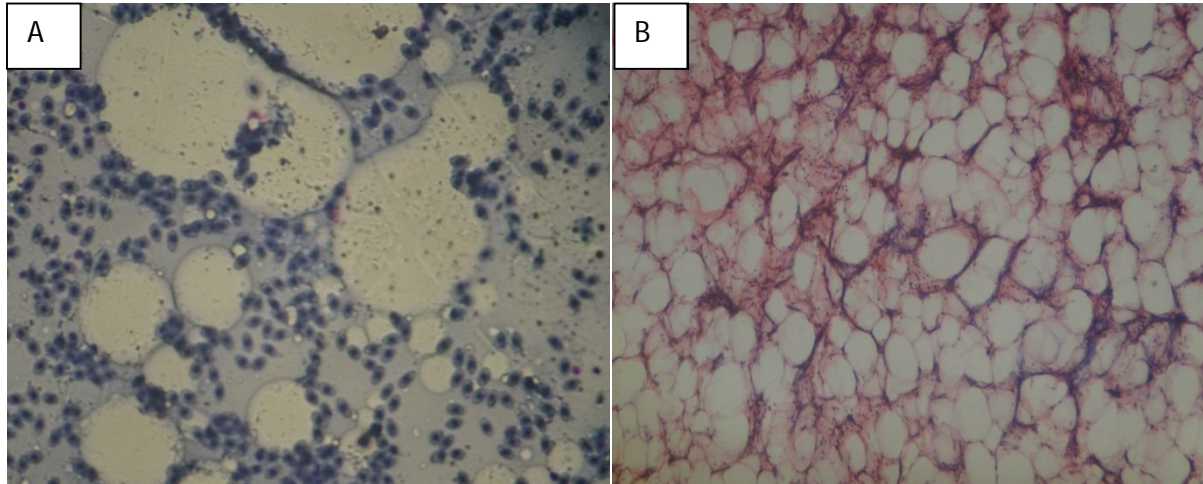


Figure 2. Photomicrographs of the mass from the Nigerian indigenous chicken. A. Note the cytological features of the mass which is characterized by balloon like colorless vacuoles interspersed with nucleated red blood cells. B. Note the histopathologic features of the mass which is characterized by aggregates of colorless, polyhedral vacuoles mainly of uniform sizes connected by fibrovascular stroma.

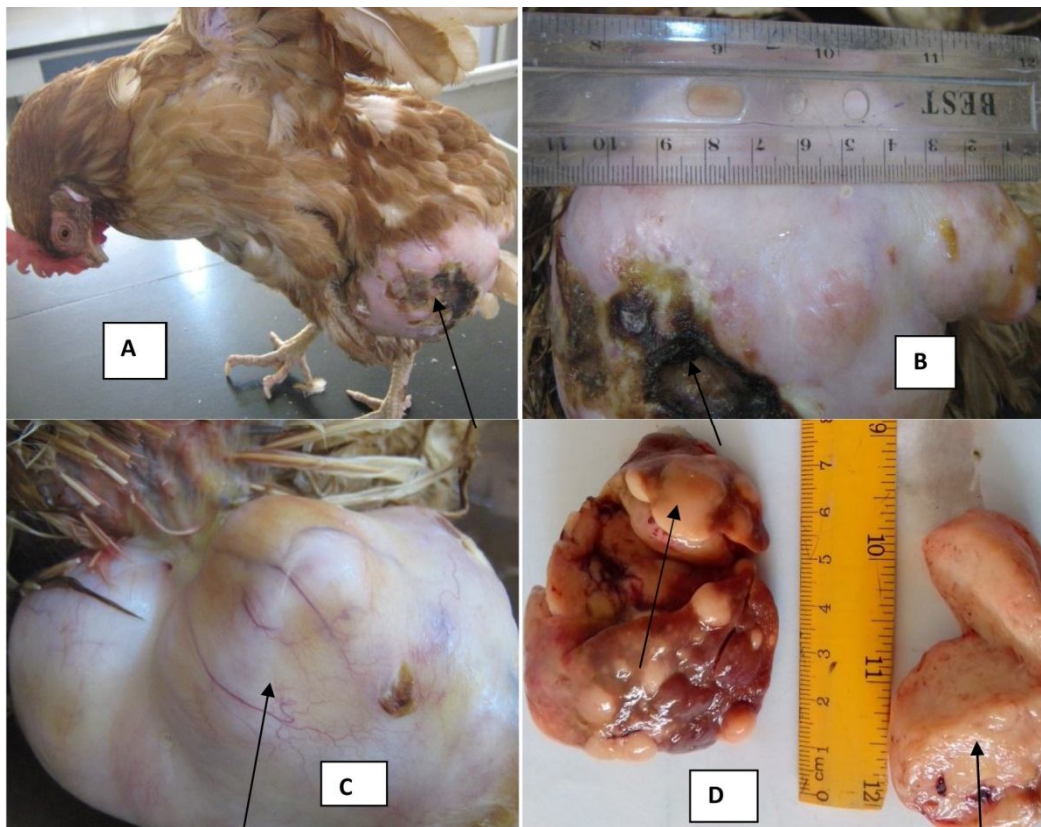


Figure 3. A, B, C-Exotic chicken with traumatized, lobulated large mass (11 cm) on the ventro-lateral surface of the left thigh. D-Deep lipoma and cut surface of deep the lipoma in the liver of a local bird.

Surgical Management

The hen was properly restrained on left lateral recumbency. The skin around the mass was thoroughly cleaned and disinfected with 5% diluted chlorhexidine. Ring block local anesthesia was achieved using 2 ml lidocaine (2%), injected subcutaneously around the neck of the mass. A 2 cm skin incision was made on the body of the mass and the mass was subsequently separated from the overlying skin by blunt dissection until the stalk of the mass was assessed. The stalk was ligated twice at 0.5 cm intervals using chromic catgut (2.0). The mass was completely excised and the surgical wound was closed using silk (2.0) by simple interrupted suture pattern. Post surgery, oxytetracycline and gentian violet spray was liberally applied on the sutured site. Oxytetracycline long acting (Tetranor LA-Jubaily®) at 20mg/Kg and diclofenac sodium at 4mg/kg were administered intramuscularly.

Gross and Histopathological Evaluation

Grossly, the excised mass was multilobulated and measured 8 cm in diameter. On cut surface, it was yellow-coloured, appeared fatty and admixed with focal haemorrhages and dilated blood vessels (Figure 1. B and D). A section of the mass was immediately fixed in 10% neutral buffered formalin and taken to histopathology laboratory. Histopathologic examination of the mass revealed aggregates of lipocytes with nucleus located at the margin of each lipocyte. The aggregates of lipocytes were interspersed with connective tissues and blood vessels (Figure 2. B). A final diagnosis of subcutaneous lipoma was therefore made. The deep lipoma was observed during postmortem examination of a local bird from a flock of 50 that was presented dead to Clinic for evaluation and possible advice. At necropsy, the liver was enlarged and had multiple lobulated tumors that grossly enlarged the liver to as much as 8 cm in diameter. The tumors were yellow in appearance and the cut surfaces appeared yellow and fatty (Figure 3. D).

Discussion

Lipomas are often seen in adult and more frequently in older animals. Lipomas could originate from the subcutaneous tissues, deeper organs like liver and/or spleen. However, hepatic lipomas may be presented singly or in multiples while lipomas of the splenic are generally solitary and appear white-brown (Latimer and Rakich, 1995). The subcutaneous mass in the local chicken was considered benign as it was soft solitary and movable in the patient and had been in that same location for over 8 months. Histologically, the tumor was composed of mature adipose cells, few blood vessels, and uniform lipocytes. Superficial lipomas are benign neoplasms commonly affecting the subcutis of domestic and wild animals (Aslani *et*

al., 1999; Jakhar *et al.*, 2006; Nowak *et al.*, 2010; Azizi *et al.*, 2011; Baqir *et al.*, 2014; Joseph *et al.*, 2015; Hupples *et al.*, 2016). On the other hand, malignant lipomas like liposarcomas are hypervascular in nature, well circumscribed by fibrous tissues and characterized by cells of different sizes and shapes (Hammedi *et al.*, 2013). Subcutaneous Lipoma has also been observed to be the most frequently occurring neoplasm in companion birds (Turrel *et al.*, 1987). The deep-seated lipomas are very rare in occurrence and when they occur, they can be found in many sites of the body at a much later stage of development, and in some situations tend to be larger than superficial lipomas (Figure 3. D). However, subcutaneous lipoma of the exotic bird observed in this study was largest which could be due to nutritional influence as exotic chickens are intensively fed commercial feeds. These seem to be the first report on the cases of subcutaneous and deep lipomas in Nigerian indigenous and exotic chickens in Zaria, Nigeria.

Although the aetiology of lipoma is still not clearly understood, predisposing factors such as obesity, old age, species involved, trauma and feeding of high energy diets have been advanced (Latimer, 1994). Unlike lipomas, common neoplasms affecting the blood, immune and lymphatic systems of poultry like erythroid leukosis, myeloid leukosis, malignant lymphoma, lymphoid leukosis and Marek's disease are caused by viruses (Latimer and Rakich, 1995). Each of these forms of hemolymphatic neoplasia is believed to be associated with the proliferation of a single cell line. In contrast, lipomas are the result of the proliferation of lipocytes and mixed hematopoietic cell lines, making viral origin unlikely to be responsible for these cases. The local chicken, in this case, was not obese because it was managed on the free-range system and was only occasionally fed whole grains as a supplement. Old age may also not be a factor as the growth was reported to be first observed about 8 months prior to presentation to the clinic which puts the age at onset to be approximately 4 months. More so, there were documented evidence of lipoma in very young animals as well as multiple lipomatosis in humans (Ozmen, 2005; Medina *et al.*, 2007; Azizi *et al.*, 2011). Lipomas were also observed to be associated with trauma but it was not ascertained as to whether trauma was responsible for the tumor or the tumor got traumatized from the environment as observed in figures 3. A, B and C.

The tentative diagnosis of lipoma was made in this case presented because the provisional diagnosis of subcutaneous lipoma can be achieved by cytological evaluation of fine needle aspirate of the mass (Boes, 2013; Hammedi *et al.*, 2013). However, conventional lipoma and its variants (spindle cell lipoma, pleomorphic lipoma, chondrioid, lipoma and

benign lipoblastoma) have similar cytological features, exhibiting adipose tissue that is mature in appearance, except in benign lipoblastoma where the adipocytes are immature. However, their histopathologic characteristics are strikingly dissimilar. Those located within or infiltrate muscles and on internal organs may require other diagnostic techniques such as radiography (Aslani *et al.*, 1999), ultrasonography, CT scan or magnetic resonance imaging (Salvatore *et al.*, 2003; Hammedi *et al.*, 2013).

Liposuction, steroid injection and surgical excision have been the three common methods of handling lipoma cases. Liposuction leaves behind little or no scar and therefore cosmetically friendly, but it is associated with the possibility of reoccurrence if residual tumor remains after the procedure. Steroid injection is given severally and only suitable for smaller cutaneous lipomas. Surgical resection of the mass is the treatment of choice in

cases of subcutaneous lipoma (Medina *et al.*, 2007; Boes, 2013; Hammedi *et al.*, 2013). Unfortunately, the cost of surgical management of lipoma may outweigh the market value of the animal affected, especially when the animal is kept mainly for financial benefits. In this case of local chicken with subcutaneous lipoma, the chicken was highly valuable to the owner because of his belief that the chicken had spiritual and magical powers. In managing such a case, therefore, the welfare of the chicken as well as the economic status of the owner was considered by the clinicians.

Conclusion

Though infiltrating lipomas have not been successfully managed surgically, and in some situations, euthanasia is recommended. In our case, however, tumor regrowth was not observed following surgical resection. Benign tumors can be diagnosed and effectively managed surgically in birds.

References

- Adeleke MA, Peters SO, Ozoje MO, Ikeobi CON, Bamgbose AM & Adebambo OA. 2011. Growth performance of Nigerian local chickens in crosses involving an exotic broiler breeder. *Tropical Animal Health and Production*, 43: 643–650. DOI: 10.1007/s11250-010-9747-3
- Arora KM & Madaan E. 2016. Lipoma of the ring finger in a young female: case report and review of literature, *Progress in Orthopedic Science*, 4: 37-39. DOI: 10.5455/pos.20161026022814
- Aslani MR, Davazdah-Emami MR & Movassaghi AR. 1999. Subcutaneous lipoma in a neonatal calf. *Journal of Applied Animal Research*, 15: 197-199. DOI: 10.1080/09712119.1999.9706254
- Azizi S, Kheirandish R & Namjoo AR. 2011. Occurrence of infiltrative lipoma with remarkable abomasal ulcers in a lamb - a case report. *Veterinary Archive*, 81: 683-690.
- Baqir S, Azri HA, Rasbi KA, Mastromonaco G & Gartley C. 2014. Skin Lipoma in an Arabian Leopard (*Panthera pardus nimr*). *Acta Scientiae Veterinariae*, 42: 1-6.
- Boes KM. 2013. Top 5 Masses Diagnosed with In-House Cytology. *Clinician's brief*, 15-27.
- Fayeye R & Oketoyin AB. 2006. Characterization of Fulani ecotype chicken for thermoregulatory feather gene. *Livestock Research for Rural Development* 18: Article 45.
- Hammedi F, Fouli S, Hadhri R, Nem L, Chagweche MA, Hamoudi H, Moussa A & Zakhama A. 2013. Angiomyxolipoma: Report of a new case in subcutaneous tissue and review of the literature. *Journal of Case Report in Practice*, 1: 17-19.
- Hernandes R, Ferro JA, Gonzales E., Macari M, Bernal FEM & Ferro MIT. 2002. Resistance to Ascites syndrome, homoeothermic competence and levels of Hsp70 in the heart and lungs of broilers. *Revista-Brasileira-de-Zoontecnia*, 31: 1442-1450. DOI: 10.1590/S1516-35982002000600016
- Huppess RR, Pietro ND, Wittmaack MC, Sembenelli G, Bueno CM, Pazzini JM, Jark PC, De Nardi AB & Costa-Castro JL. 2016. Intermuscular Lipoma in Dogs. *Acta Scientiae Veterinariae*, 44: 1-7.
- Jakhar KK, Singh P & Dev K. 2006. Occurrence of tumors in domestic animals. *Haryana Veterinary*, 45: 79-81.
- Joseph C, George RS, Sridevi P, Rangasamy S & Jemimah RE. 2015. Uterine horn lipoma with concurrent pyometra in an intact Dachshund bitch. *Indian Journal of Animal Reproduction*, 36: 67-68.
- Kperegbeji JI, Meye JA & Ogboi E. 2009. Local chicken production: strategy of household poultry development in coastal regions of Niger Delta, Nigeria. *African Journal of Agriculture*, 5: 17-20. DOI: 10.5897/JAERD2013.0527
- Latimer K.S. 1994. *Oncology. In: Avian Medicine: Principles and Application.* Ritchie BW, Harrison GJ and Harrison LR. (Eds). Wingers Publishing, Inc. Lake Worth, Florida. 1384 Pages.
- Latimer KS, & P. M. Rakich MP. 1995. Subcutaneous and Hepatic Myelolipomas in four exotic birds. *Communications and Case Reports, Veterinary Pathology*, 32: 84-87. DOI: 10.1177/030098589503200117
- Kransdorf MJ. 1995. Benign soft-tissue tumors in a large referral population: distribution of specific diagnoses by age, sex, and location. *American Journal Roentgenology*, 164: 395–402. DOI: 10.2214/ajr.164.2.7839977
- Medina CR, Schneider S, Mitra A & Spears A. 2007. Giant submental lipoma: Case report and review of the literature. *Canadian Journal of Plastic Surgery*, 4: 219- 222. DOI: 10.1177/229255030701500405

- Merat P. 1990. Pleiotropic and associated effects of major genes, in: Crawford RD, (ed), Poultry breeding and genetics, Elsevier, Amsterdam. Pg. 442-448
- Nowak M, Madej JA, Ciaputa R & Poradowski D. 2010. Manifestation of tumours in domestic animals in Lower Silesia in 2005-2008. *Bulletin of Veterinary Institute Pulawy*, 54: 229-236.
- Ozmen O. 2005. Clinical case: Congenital lipomatosis in a Brown Swiss calf. *Revue de Medecine Veterinaire*, 156: 191-193.
- Padhi MK. 2016. Importance of indigenous breeds of chicken for rural economy and their improvements for higher production performance. *Scientifica*, 1-9. DOI: 10.1155/2016/2604685
- Salvatore C, Antonio B, Del Vecchio W, Lanza A, Tartaro G & Giuseppe C 2003. Giant infiltrating lipoma of the face: CT and MR Imaging Findings. *American Journal of Neuroradiology*, 24: 283-286.
- Sonaiya EB & Olori, VE. 1989. Village chicken production in South Western Nigeria. In: *Proceedings of the International workshop on rural poultry development in Africa* (Sonaiya, E.B., Ed.), 13 – 16 November 1989, Ile-Ife, Nigeria, pp. 243 – 247.
- Turrel JM, McMillan MC & Paul-Murphy J. 1987. Diagnosis and treatment of tumors of companion birds I. *Association of Avian Veterinarians*, 1: 109-116. DOI: 10.2307/27670279
- Yalcin S, Testik A, Ozkan S, Settar P, Celen F & Cahaner A. 1997. Performance of naked neck and normal broilers in hot, warm, and temperate climates. *Poultry Science*, 76: 930-937. DOI: 10.1093/ps/76.7.930