

Malakhov S. S. General characteristics of morphometric parameters nerve structures of the tentorium cerebelli. *Journal of Education, Health and Sport*. 2018;8(10):273-284. eISSN 2391-8306. DOI <http://dx.doi.org/10.5281/zenodo.1478845>
<http://ojs.ukw.edu.pl/index.php/johs/article/view/6281>

The journal has had 7 points in Ministry of Science and Higher Education parametric evaluation. Part b item 1223 (26/01/2017).
1223 Journal of Education, Health and Sport eISSN 2391-8306 7

© The Author(s) 2018.

This article is published with open access at Licensee Open Journal Systems of Kazimierz Wielki University in Bydgoszcz, Poland

Open Access. This article is distributed under the terms of the Creative Commons Attribution Noncommercial License which permits any noncommercial use, distribution, and reproduction in any medium, provided the original author (s) and source are credited. This is an open access article licensed under the terms of the Creative Commons Attribution Non commercial license (<http://creativecommons.org/licenses/by-nc/4.0/>) which permits unrestricted, non commercial use, distribution and reproduction in any medium, provided the work is properly cited.

This is an open access article licensed under the terms of the Creative Commons Attribution Non commercial License (<http://creativecommons.org/licenses/by-nc/4.0/>) which permits unrestricted, non commercial use, distribution and reproduction in any medium, provided the work is properly cited.

The authors declare that there is no conflict of interests regarding the publication of this paper.

Received: 02.10.2018. Revised: 19.10.2018. Accepted: 31.10.2018.

GENERAL CHARACTERISTICS OF MORPHOMETRIC PARAMETERS NERVE STRUCTURES OF THE TENTORIUM CEREBELLI

S. S. Malakhov

State Establishment "Lugansk State Medical University"

Department of general surgery, topographic anatomy and operative surgery

93012 m. Rubezhnoe Street. Builders 32

Abstract

Objective. Establish morphometric features of the position, shape and size of tentorium cerebelli nerves in middle-aged people. **Methods** - macro and microscopic examination of tentorium cerebelli and its nerve structures, morphometry of all departments of tentorium cerebelli, microscopic study of the structure and innervation of tentorium cerebelli leaves stained with hematoxylin-eosin, and also by the Schubich-Hodos method using Schiff's reagent, individual preparations impregnated by the method of Rasskazova-Kupriyanov. The obtained data were systematized from the position of the doctrine V.M. Shevkunenko about individual anatomical variability and were substantiated by means of a variational-statistical analysis. **Results.** The study found that the main source of innervation of tentorium cerebelli is tentorial nerve. There are two main forms of the branching of tentorial nerve in the tissue tentorium cerebelli: one-sided and double-sided. The diameter of the nerve trunks of tentorial nerve reaches values from 2.70 to 3.16 mm in men and 2.46 to 2.98 mm in women; the diameter of the lateral and medial branches does not exceed 1.55-2.30 mm (men) and 1.47-2.12 mm (women); the diameter of the intermediate twigs is 500-900 microns in the first and 350-920 microns in the others; the diameter of the

fins is 40-170 and 10-160 microns. The highest rates of brachicephals are slightly reduced in mesocephals, and reach the smallest values in the dolichocephals. The length of the trunks tentorial nerve is in the range from 1.50 to 2.28 cm; the length of the main branches does not exceed 2,05-3,10 cm; the length of the zone of innervation of the terminal branches of the tentorial nerve is from 1.40 to 1.95 cm. This parameter has the highest rates in people with a dolichocephalic form of the head, the smallest - in people with brachycephalic form.

Keywords: tentorium cerebelli , tentorial nerve, innervation, morphometry.

ЗАГАЛЬНА ХАРАКТЕРИСТИКА МОРФОМЕТРИЧНИХ ПАРАМЕТРІВ НЕРВОВИХ УТВОРЕНЬ НАМЕТУ МОЗОЧКА

С. С. Малахов

ДЗ «Луганський державний медичний університет»

Кафедра загальної хірургії, топографічної анатомії з оперативною хірургією

93012 м. Рубіжне, вул. Будівельників 32

Реферат

Мета - встановити морфометричні особливості положення, форми та розмірів нервових утворень НМ у людей зрілого віку. Методи - макро- та мікроскопічне дослідження НМ та його нервових структур, морфометрія всіх відділів НМ, мікроскопічне дослідження будови та іннервації листків НМ, які забарвлювалися гематоксилін-еозинном, а також за методом Шубіча-Ходоса з використанням реактиву Шиффа, окремі препарати імпрегновані за способом Расказової-Купріянова. Отримані дані систематизувались з позиції вчення В.М. Шевкуненко про індивідуальну анатомічну мінливість та обґрунтовувались за допомогою варіаційно-статистичного аналізу.

В ході дослідження встановлено, що основним джерелом іннервації НМ є ТН. Виділяються дві основні форми розгалуження ТН в тканині НМ: одностовбутова та двостовбутова. Діаметр нервових основних стовбурів ТН досягає значень від 2,70 до 3,16 мм у чоловіків та від 2,46 до 2,98 мм у жінок; діаметр латеральної та медіальної гілок не переважає 1,55-2,30 мм (чол.) та 1,47-2,12 мм (жін.); діаметр проміжних гілочок становить 500-900 мкм у перших та 350-920 мкм у других; діаметр кінцевих гілочок дорівнює 40-170 та 10-160 мкм. Найбільші показники притаманні

брахіцефалам, трохи зменшуються у мезоцефалів, та досягають найменших значень у доліхоцефалів. Довжина стовбурів ТН знаходиться в діапазоні від 1,50 до 2,28 см; довжина основних гілок не переважає 2,05-3,10 см; довжина зони іннервації кінцевих гілок ТН становить від 1,40 до 1,95 см. Даний параметр має найбільші показники у людей доліхоцефалічною формою голови, найменші - у людей з брахіцефалічною формою.

Ключові слова: намет мозочка, тенторіальний нерв, іннервація, морфометрія.

ОБЩАЯ ХАРАКТЕРИСТИКА МОРФОМЕТРИЧЕСКИХ ПАРАМЕТРОВ НЕРВНЫХ ОБРАЗОВАНИЙ НАМЕТА МОЗЖЕЧКА

С. С.Малахов

ГУ «Луганский государственный медицинский университет»

Кафедра общей хирургии, топографической анатомии с оперативной хирургией
93012 м. Рубежное, ул. Строителей 32

Реферат

Цель - установить морфометрические особенности положения, формы и размеров нервных образований НМ у людей зрелого возраста. Методы - макро- и микроскопическое исследование НМ и его нервных структур, морфометрия всех отделов НМ, микроскопическое исследование строения и иннервации листков НМ, которые окрашивались гематоксилин-эозином, а также по методу Шубича-Ходоса с использованием реактива Шиффа, отдельные препараты импрегнированной по способу Рассказовой -Куприянова. Полученные данные систематизировались с позиции учения В.Н. Шевкуненко об индивидуальной анатомической изменчивости и обосновывались с помощью вариационно-статистического анализа.

В ходе исследования установлено, что основным источником иннервации НМ является ТН. Выделяются две основные формы ветвления ТН в ткани НМ: одностволовая и двухстволовая. Диаметр основных нервных стволов ТН достигает значений от 2,70 до 3,16 мм у мужчин и от 2,46 до 2,98 мм у женщин; диаметр латеральной и медиальной ветвей не превышает 1,55-2,30 мм (муж.) и 1,47-2,12 мм (жен.); диаметр промежуточных веточек составляет 500-900 мкм в первых и 350-920

мкм в вторых; диаметр конечных веточек равен 40-170 и 10-160 мкм. Наибольшие показатели присущи брахицефалам, немного уменьшаются у мезоцефалов, и достигают наименьших значений в долихоцефалов. Длина стволов ТН находится в диапазоне от 1,50 до 2,28 см; длина основных ветвей не превышает 2,05-3,10 см; длина зоны иннервации конечных ветвей ТН составляет от 1,40 до 1,95 см. Данный параметр имеет наибольшие показатели у людей с долихоцефалической формой головы, наименьшие - у людей с брахицефалической формой.

Ключевые слова: намет мозжечка, тенториальный нерв, иннервация, морфометрия.

Work performed under the thematic plan of research "Lugansk State Medical University" within the topics of general surgery, topographic anatomy and operative surgery "Variability of morphological features, relations structures of the head, skull, brain and their practical value" number state registration- 0109U002006.

Introduction. Tentorium cerebelli (TC) is the second offshoot dura mater of the brain area, occupying an important position in topography cranial cavity. This process is located in a horizontal plane with a dome-shaped uplift and is located between the oily lobes of the brain and the cerebellum and is a kind of "roof" of the posterior cranial fossa. TC is the strongest form of dura mater of the brain because it helps protect the cortex and cerebellum worm along with the brain stem and its vital centers [1, 3].

Each half of the tent is the cerebellum neurovascular bundle, which consists of tentorial arteries and the same nerve that runs from front to back and forks in the walls of the left and right transverse sinus, some reaching the posterior third straight sinus and side walls confluence of sinuses [4, 5].

The basis tent innervation cerebellum performs reverse nerve Arnold - n. Tentorius (TN) with the first (ophthalmic) branch of the trigeminal nerve, giving branches to parietal area of convectional area of dura mater of the brain, sickle posterior third of the falx cerebri, all the walls of the upper sagittal and transverse sinuses [6, 7].

It is known that the headaches associated with irritation of nerves of dura mater of the brain a specific and localized irradiation of the entire area mater [2].

The aim of the study: morphometric features set position, shape and size nerve structures of the TC in middle-aged people.

Materials and methods. The study was conducted on 105 TC preparations taken from corpses of people of different age, gender and size of the head. Performed macro- and

microscopic examination TC and the nervous structures. Using special devices goniometer, protractor and ruler held combined sliding morphometry required all departments TC. For the microscopic study of the structure and innervation leaves TC was made 95 histological preparations, which are then stained with hematoxylin-eosin and method Shubich-Hodos using Schiff's reagent, some preparations impregnated by the method Rasskazovo-Kupriyanov. The data were systematized teaching position with VM Shevkunenko of individual anatomical variability and justified using variation statistical analysis.

Results and discussion

According to our data, the backbone of Arnold, or the tentorial nerve, which is paired form and branched off from the I branch of the trigeminal nerve (n. ophthalmicus), carries out the innervation of the TC.

There is variability in the origin and course TN: most often it comes from the ophthalmic branch of the trigeminal nerve, branching off its dorsal medial or dorsal site at a distance of 0.5-1.0 cm from the corner, which limited the free edge and the top edge TC rocky part of the temporal bone. This branch runs along the side wall of the cavernous sinus, then the upper-medial surface of the trigeminal knot, getting in front corner TC. Course TN left and right are often identical, it is located at 0.5-0.8 cm from the free tentorial edge.

We describe the various options and the branching passage within TN and TC: local - with a limited number of branches, which stretch to the transverse sinuses, which break up a large number of small twigs and form a grid nervous; loose version - nerve divided into 3-4 large trunk in the pool which implied nerve plexus.

An important feature of the course of the initial nerve trunk of the tentorial nerve is the difference is in the depth of its position relative to the thickness of bone. TN surfactants can pass along the upper leaf TC. Rarely, in the middle of a process of tissue on the border between the upper to the lower leaves. And often he goes deep in the bottom of the leaf, the main collagen skeleton and is much thicker (Fig. 1).

Our data TN often leaves one barrel of ophthalmic branch of the trigeminal nerve, which we called one-sided form, characterized by the separation of the medial and lateral branches within the department pointed front nm. One can clearly see that the original trunk of the nerve is always a small extension (up to 1.5-2.0 cm) and short breaks in the medial and lateral long branches. Moreover, the first of which covers the area along the straight sinus innervation as the left and right, reaching its walls, and the second branch occupies a much larger area, situated along the rocky top on transverse sinus and ends in the side walls of the drain sinuses (Fig. 2 .).

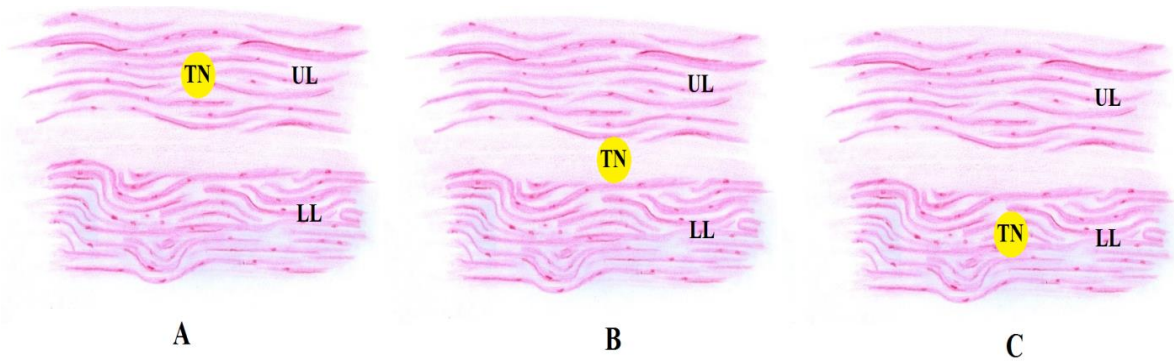


Fig. 1. Various passing the initial depth tentorial nerve trunk: UL - upper leaf TC; LL - lower leaf nm; TN - tentorial nerve; A - surface (upper leaf); B - average (between sheets); C - deep (lower leaf).

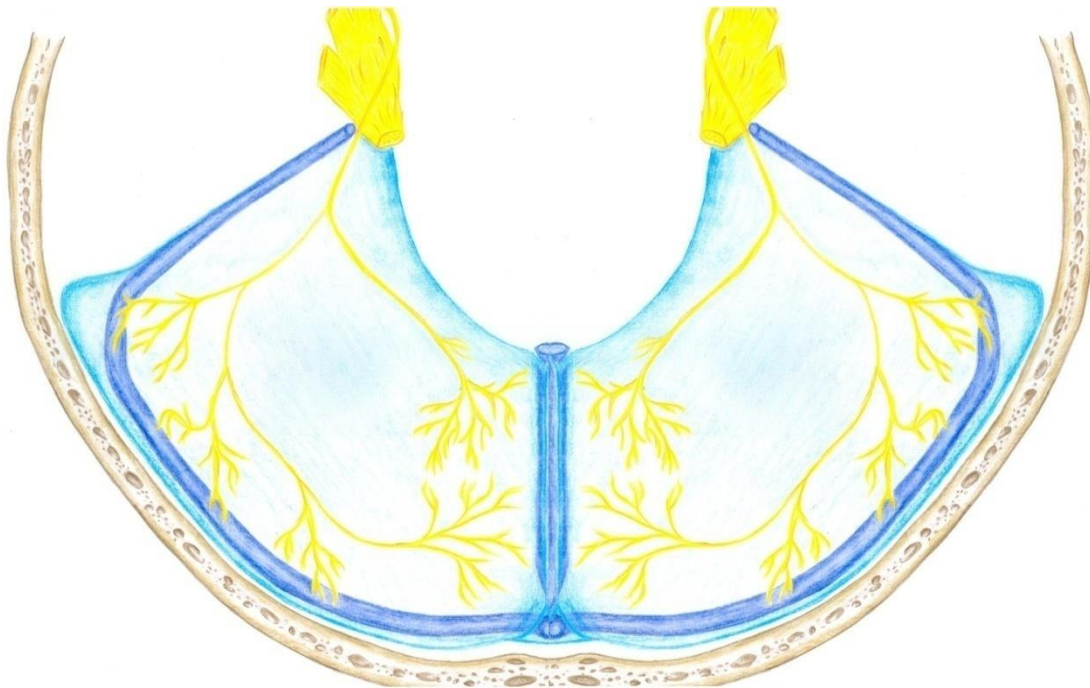


Fig. 2. A characteristic position of one-sided tentorial nerve in relation to the grooves of dura mater of brain formed by leaves of TC.

Less common double-sided form TN that traced throughout TC with uniform discharge parasinuses branches in areas all around the venous reservoir (Fig. 3).

With this structure TN marked increase in the number of branches, which depart from the main stem, from the anterior neural directly to the rocky walls of the upper sinus, followed by two trunks - to the transverse sinuses, capturing the side walls of the confluence of sinuses. The feature of this structure is the final TN branch against the side walls of the straight sinus. They end up in this reservoir, which is not one-side was noted in the form of nerve.

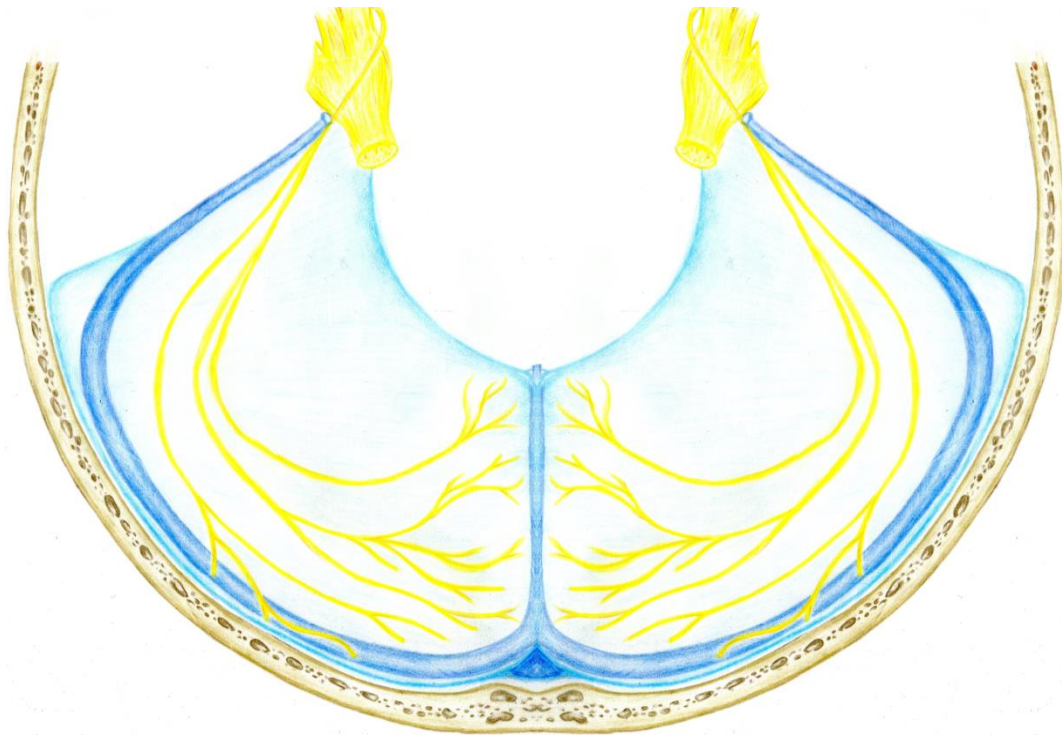


Fig. 3. Characteristic position of double-sided tentorial nerve in relation to the grooves of of dura mater of brain formed by leaves of TC.

At the same time found that progress TN has a similar trend in most studied drugs. Checked expressed arched with convexity to the lateral parts of NM, that is closer to the transverse sinus. And it remains both in single and in double-sided forms tentorial nerves. The central section of a process normally devoid of stem above the nerves are located mainly finer their branches.

For one-side TN characteristic forms division in the appendix to the anterior medial and lateral branches, when there is a kind of ring-shaped course with a typical shift and arched them in the medial and lateral sections nm. It also means free central area devoid of the aforementioned nerve structures.

According to our data, the diameter of the stem TN adulthood in humans characterized by a certain uniformity in the range of 2.46 to 3.16 mm. Men tentorial caliber barrels ranging from 2.70 to 3.16 mm in women - from 2.46 to 2.98 mm. Accordingly, a typical separation TN on the medial and lateral branches allowed to determine their diameter. In men mature this option medial branches ranges from 1.56 to 1.95 mm in women - from 1.48 to 1.91 mm; lateral branches - from 1.60 to 2.30 mm in women - from 1.56 to 2.10 mm (tab. 1).

Table 1

Variability of diameter of TN and its trunks in middle-aged people (in mm)

№	Head shape and Resear. features		Brachicephals		Mesocephals		Dolichocephals	
			Men	Women	Men	Women	Men	Women
1	The diameter of the trunk TN	left	2.90-3.16	2.82-2.98	2.77-2.86	2.62-2.70	2.70-2.82	2.46-2.55
		right	2.91-3.14	2.81-2.97	2.74-2.84	2.60-2.72	2.71-2.84	2.47-2.56
2	The diameter of the medial branch	left	1.86-1.95	1.83-1.91	1.74-1.81	1.66-1.70	1.56-1.66	1.48-1.57
		right	1.85-1,94	1.82-1.90	1.72-1.83	1.64-1.72	1.55-1.67	1.47-1.58
3	The diameter of the lateral branches	left	2.16-2.30	1.94-2.10	1.82-1.90	1.78-1.86	1.60-1.70	1.56-1.64
		right	2.17-2.28	1.93-2.12	1.80-1.92	1.77-1.86	1.60-1.72	1.54-1.64

Found that men of mature age TN diameter ranging from 2.70 to 3.16 mm, but with the structural features of the head and TC observed some features. Brachicephals diameter TN has a characteristic tendency to increase and is 2.90-3.16 mm (left) and 2.91-3.14 mm (right). Therefore, women with this extreme form of head observed variability diameter core barrel TN from 2.82 to 2.98 mm (left) of 2.81-2.97 mm (right). People with mesocephals head shape marked a slight decrease in diameter TN as left and right. The representatives of the males from 2.74 to 2.86 mm; in females from 2.60 to 2.72 mm, respectively, in dolichocephals seen a slight decrease in the diameter of the CN, which is left to men, from 2.70 to 2.82 mm, right - of 2.71-2.84; women typical range from 2.46 to 2.55 (left) and from 2.47 to 2.556 (right).

In addition, the set range of variability of the diameter of the main branches of TN in middle-aged people. TN diameter medial branch on the left half of the men TC varies from 1.56 to 1.95 mm, with a characteristic dependence on the shape of the head, in brachicephals from 1.86 to 1.95 mm; in mesocephals from 1.74 to 1.81 mm; in dolichocephals from 1.56 to 1.66 mm. Accordingly, women from 1.48 to 1.91 mm, with a range of individual differences: in brachicephals from 1.83 to 1.91 mm; in mesocephals from 1.66 to 1.70 mm; in dolichocephals from 1.48 to 1.57 mm. Similarly, on the right side of the medial branch of TC TN is within certain limits depending on the sex and shape of the head. Men distinctive range of variability of the nerve diameter of 1.55 to 1.94 mm. In brachicephals diameter ranging from 1,85-1,94 mm; mesocephals - from 1.83 to 1.72 mm; dolichocephals - from 1.55 to 1.67 mm. Accordingly, the right medial branch TN women ranges from 1.48 to 1.90 mm

(brachicephals - from 1.82 to 1.90 mm; mesocephals - from 1.64 to 1.72 mm; dolichocephals - from 1, 47 to 1.58 mm).

TN lateral branch has a slightly larger settings and also depends on the structure of individual variability TC.

According to our data, the diameter of the lateral branches in men ranges from 1.60 to 2.30 mm, depending on the shape of the head, in brachicephals from 2.16 to 2.30 mm; mesocephals - from 1.82 to 1.90 mm; dolichocephals - of 1,60-1,70 mm (left). Right this option overrides 1,60-2,28 mm, brachicephals from 2.17 to 2.28 mm; in mesocephals - from 1.80 to 1.92 mm; in dolichocephals - from 1.60 to 1.72 mm.

Accordingly, women mature abovementioned items in the left half of TC ranges from 1.56 to 2.10 mm. It is brachicephals: 1.94-2.10 mm; mesocephals of 1.78-1.86 mm; dolichocephals of 1.56-1.64 mm. In the right half of women with TC brachicephals shape of the head is between 1.93-2.12 mm; mesocephals of forms - from 1.77 to 1.86 mm; with dolichocephals - from 1.54 to 1.64 mm.

This indicates that people with average parameters marked intermediate head and the average value of the diameter of the thread. People with dolichocephal structure head diameter lateral branches TN has the lowest value.

It is established that each of the aforementioned main branches TN dichotomically divided into smaller branches (II-IV order) ending within the walls of the sinus of the dura mater of the brain that formed leaves TC. They morphometric characteristics presented in table. 2.

Table 2.

The variability of the diameter of the middle and final tentorial branches in middle-aged people (in microns).

№	Resear. features	Head shapeand	Brachicephals		Mesocephals		Dolichocephals	
			Men	Women	Men	Men	Women	Men
1	The diameter of twigs intermediate (II-IV order)	left	800-980	750-900	650-790	600-730	550-630	500-600
		right	790-960	720-920	630-750	590-670	500-620	350-580
2	Diameter end branches	left	85-170	80-160	60-135	50-125	45-100	10-90
		right	80-160	75-150	65-125	55-120	40-95	35-85

Present table indicates that during his medial and lateral branches TN give a large number of intermediate branches, distributed between the upper and lower leaves TC. The diameter of twigs II-IV procedure within: men from 550 to 980 microns, women - from 350 to 960 microns. It should be noted that the caliber of these branches and twigs changing second order reaches 800-980 microns (men) and 750-900 microns (women), the third order branches ranging 650-750 microns (men) and 550-700 microns (women), IV order of 500 to 650 microns (men) and from 550 to 650 microns (woman). Found that in men with brachicephal form of the head diameter intermediate branches ranges from 800 to 980 microns and 750 microns to 900 women; in mesocephal from 650 to 790 microns (men) and 600 to 730 microns (women) in dolichocephal from 550 to 630 microns (men) and from 350 to 600 microns (women). This clearly defined trend of decreasing caliber TN branches throughout the plane TC in people with meso and dolichocephal form of head.

Accordingly, the features of morphometric values of the diameter of the end branches TN. For brachicephals typical range of variability of parameters from 80 to 160 microns (men) And 75 to 160 microns (women), mesocephals for mens from 60 to 135 microns and 50 to 125 microns - women; dolichocephals for 40 to 100 microns and 35 to 90 microns, depending on gender.

Next we determined for this length throughout TN and found that this option is dependent on the extreme forms of the structure of the head and has sex characteristics (Table. 3).

Table 3

The variability of the length of TN throughout TC in middle-aged people (cm)

№	Head shape and Resear. features		Brachicephals		Mesocephals		Dolichocephals	
			Men	Women	Men	Women	Men	Women
1	The length of the trunk TN	left	1.50-1.75	1.50-1.72	1.70-1.85	1.68-1.88	1.98-2.55	1.90-2.10
		right	1.55-1.80	1.52-1.70	1.72-1.87	1.65-1.85	2.35-2.55	1.92-2.28
2	The length of the main branches TN	left	2.15-2.35	2.10-2.40	2.40-2.80	2.40-2.72	3.30-3.35	2.80-3.05
		right	2.20-2.40	2.05-2.35	2.25-2.82	2.35-2.65	3.15-3.20	2.85-3.10
3	The length of the end zone innervation branches TN	left	1.40-1.70	1.30-1.65	1.70-1.82	1.60-1.78	1.90-2.00	1.80-1.95
		right	1.40-1.65	1.35-1.60	1.68-1.80	1.58-1.70	1.92-2.10	1.83-1.90

Brachicephals length anterior TN or initial part ranges from 1.50 to 1.75 cm in men and from 1.50 to 1.70 cm in women. In this period TN mesocephals slightly increased from 1.70 to 1.85 cm (men) And from 1.68 to 1.80 cm (women). Dolichocephals there is a further increase in this parameter from 1.98 to 2.55 cm in men and from 1.90 to 2.28 cm in women. This is a characteristic increase in longitudinal parameters in people with meso and dolichocephals form of the head. In accordance with what marked increase TC in length, regardless of gender.

The length of the main branches TN men with brachicephal form of the head up the left side of 2.15 to 2.35 cm, right from 2.20 to 2.40 cm. In women, this setting overrides 2.10-2.40 cm (left) and 2.05-2.35 cm (right). Accordingly, dolichocephals this department has the most nerve length and reaches 1.98-2.55 cm left and right 2,35-2,55 cm (men). In women, this option is: 2.80-3.05 cm (left) and 2.85-3.10 (right).

For the length of the end zone innervation branches TN characterized by the following individual features, brachicephals men it ranges from 1.40 to 1.70 cm (left) and from 1.40 to 1.65 cm (right). For mesocephals characteristic increase in this parameter: 1,70-1,82 cm (left) and 1,68-1,80 cm (right) with the tendency of a small increase in their length dolichocephals left from 1.90 to 2.00 cm and right from 1.92 to 2.10 cm.

Accordingly, women are marked differences in the length of the zone of innervation branches end in TN brachicephals from 1.30 to 1.65 cm; mesocephals parameter varies from 1.60 to 1.78 cm; dolichocephals women set a range of 1.80 to 1.95 cm.

Conclusions

1. The main source of neural innervation is TN. There are the two main forms of branching TN tissue TC: one-sided and double-sided.

2. The diameter of the main nerve trunks TN reaches values of 2.70 to 3.16 mm in men and from 2.46 to 2.98 mm in women; the diameter of the lateral and medial branches overrides 1,55-2,30 mm (men.) and 1,47-2,12 mm (women) diameter intermediate branches is 500-900 mm in the first and in the second 350-920 microns; diameter end branches is 40-170 and 10-160 microns. The most typical indicators brachicephals slightly reduced in mesocephals and reach the smallest values in dolichocephals.

3. The length of the trunks TN is in the range of 1.50 to 2.28 cm; the length of the main branches are not dominated 2,05-3,10 cm the length of the end zone innervation branches TN ranges from 1.40 to 1.95 cm. This option has the highest rates in people wsth dolichocephal shape of the head, the smallest - in people with brachicephals form.

Prospects for further research.

In the future conduct a comprehensive study of the features of innervation of all departments and processes the dura mater of the brain taking into account individual anatomical variability head.

References:

1. Davidson JR, Mack J, Gutnikova A, Varatharaj A, Darby S, Squier W. Developmental changes in human dural innervation. *Childs Nerv Syst.* 2012 May;28(5):665-71.
2. Feindel W, Penfield W, McNaughton F. The tentorial nerves and localization of intracranial pain in man. *Neurology.* 1960 Jun;10:555-63.
3. Keller JT, Saunders MC, Beduk A, Jollis JG (1985) Innervation of the posterior fossa dura of the cat. *Brain Res Bull* 14:97–102
4. Kemp WJ 3rd, Tubbs RS, Cohen-Gadol AA. The innervation of the cranial dura mater: neurosurgical case correlates and a review of the literature. *World Neurosurg.* 2012 Nov;78(5):505-10.
5. Lee SH, Shin KJ, Koh KS, Song WC. Visualization of the tentorial innervation of human dura mater. *J Anat.* 2017 Nov;231(5):683-689.
6. Lv X, Wu Z, Li Y. Innervation of the cerebral dura mater. *Neuroradiol J.* 2014 Jun;27(3):293-8.
7. Rai R, Iwanaga J, Shokouhi G, Oskouian RJ, Tubbs RS. The Tentorium Cerebelli: A Comprehensive Review Including Its Anatomy, Embryology, and Surgical Techniques. *Cureus.* 2018 Jul 31;10(7):e3079. doi: 10.7759/cureus.3079.