

RVC OPEN ACCESS REPOSITORY – COPYRIGHT NOTICE

This article is posted on this site with the permission of the American Veterinary Medical Association, which holds the copyright for the article. For permission to distribute the article, in print or electronically, please contact the AVMA (dfagen@avma.org).

The version of record is available via on the AVMA site via:

<https://doi.org/10.2460/javma.254.11.1309>.

The full details of the published version of the article are as follows:

TITLE: Surgical management of an adrenal gland tumor that had extended into the thoracic portion of the caudal vena cava in a dog

AUTHORS: Victoria J. Lipscomb MA, VetMB

JOURNAL TITLE: Journal of the American Veterinary Medical Association

PUBLISHER: American Veterinary Medical Association

PUBLICATION DATE: 1 June 2019

DOI: 10.2460/javma.254.11.1309

Surgical management of an adrenal gland tumor that had extended into the thoracic portion of the caudal vena cava in a dog

Victoria J. Lipscomb MA, VetMB

From the Queen Mother Hospital for Animals, Royal Veterinary College, University of London, Hatfield, AL9 7TA, England.

Address correspondence to Dr Lipscomb (vlipscomb@rvc.ac.uk).

CASE DESCRIPTION

A 14-year-old neutered female Border Collie with a 3-week history of collapse during exercise was evaluated because of recumbency, tachycardia, and hypotension.

CLINICAL FINDINGS

Results of biochemical testing indicated the presence of a pheochromocytoma, and CT revealed an enlarged right adrenal gland mass that extended down the right phrenicoabdominal vein into the posthepatic thoracic portion of the caudal vena cava.

TREATMENT AND OUTCOME

A midline celiotomy and median sternotomy were performed to allow en bloc removal of the right adrenal gland tumor and its tumor thrombus extension within the caudal vena cava. Temporary occlusion of the thoracic and abdominal portions of the caudal vena cava and both renal veins and the dual inflow to the liver (Pringle maneuver) were required. The venotomy and tumor and thrombus extractions required a 25-minute period of vascular occlusion. The dog had no major postsurgical complications. Histologic findings indicated that direct adrenal tumor invasion into the caudal vena cava wall had occurred along the established route of tumor extension down the phrenicoabdominal vein.

CLINICAL RELEVANCE

For the dog of this report, an adrenal tumor thrombus that extended into the thoracic portion of the caudal vena cava was surgically managed with a combined median sternotomy and midline celiotomy approach and temporary occlusion of the hepatic artery, portal vein, and abdominal and thoracic portions of the caudal vena cava. This facilitated successful manual manipulation of the tumor and enabled venotomy of sufficient size for tumor thrombus extraction. (*J Am Vet Med Assoc* 2019;254:1309–1315)

A 14-year-old 18.6-kg (40.9-lb) neutered female Border Collie with a 3-week history of 3 episodes of collapsing during exercise with no loss of consciousness was evaluated. The dog was recumbent at the time of the evaluation. Physical examination revealed that the dog had appropriate mentation; rectal temperature was 38.8°C (101.8°F), and heart rate was 212 beats/min with a regular rhythm and weak femoral pulses. A grade 1/6 left apical early systolic heart murmur was detected. Respiratory rate was fast because the dog was panting, and lung auscultation revealed no abnormalities. Mucous membranes were very pale but moist, and capillary refill time was approximately 4 seconds. Peripheral systolic arterial blood pressure determined by use of Doppler ultrasonography was 60 mm Hg. Findings of abdominal palpation were considered normal, and the dog's body condition score was 5/9.

Results of a CBC were unremarkable. Serum biochemical analyses revealed mildly high activities of alanine aminotransferase (208 mmol/L; reference in-

terval, 13 to 88 mmol/L), alkaline phosphatase (472 mmol/L; reference interval, 19 to 285 mmol/L), and amylase (1,270 mmol/L; reference interval, 176 to 1,245 mmol/L); all other variables including electrolyte concentrations were within reference limits. The dog was treated with a bolus of CSLS^a (15 mL/kg [6.8 mL/lb], IV) after which Doppler-determined systolic arterial blood pressure increased to 120 mm Hg and remained stable thereafter. Intravenous fluid therapy with CSLS was continued at a rate of 2 mL/kg/h (0.9 mL/lb/h) for a further 48 hours. Echocardiography revealed mild thickening of mitral valve leaflets associated with mild mitral valve regurgitation but no evidence of left atrial or ventricular dilation or other structural abnormalities. A nonhomogeneous hyperechoic structure was observed filling the lumen of the thoracic portion of the caudal vena cava on echocardiographic images.

A CT scan of the dog's thorax and abdomen revealed an enlarged, rounded (18-mm-diameter) right adrenal gland mass that extended down the phrenicoabdominal vein, filling 80% to 90% of the lumen of the caudal vena cava and extending beyond the diaphragm within the thoracic cavity from the level

ABBREVIATIONS

CSLS Compound sodium lactate (Hartmann) solution

of L1 to T8 (**Figure 1**). After administration of contrast medium to the dog, the adrenal gland mass and its intraluminal extension had marked, heterogeneous contrast enhancement and multiple collateral vessels around the adrenal gland were evident. The tumor-bearing region of the caudal vena cava was enlarged (35 mm at its widest midhepatic point); the width and height of the prerenal portion of the vessel caudal to the tumor were 11 mm and 13 mm, respectively. The left adrenal gland and both kidneys appeared normal.

The dog underwent an ACTH stimulation test, the result of which was considered normal. Serum thyroxine and thyroid-stimulating hormone concentrations were within reference intervals. High plasma concentrations of metanephrine (> 10 nmol/L; reference interval, 0.28 to 3.88 nmol/L) and normetanephrine (> 25 nmol/L; reference interval, 0.95 to 5.38 nmol/L) were consistent with presence of a pheochromocytoma. Surgical treatment, including the high risks of perioperative complications and death associated with the large intravascular tumor thrombus extending into the thoracic cavity, was discussed in detail with the owners, and the option of euthanasia was offered. The owners elected surgical treatment. The dog was administered phenoxybenzamine hydrochloride^b (1 mg/kg [0.45 mg/lb], PO, q 12 h) for 7 days prior to surgery. During the 7-day preoperative period, the dog was hospitalized because of the risk of hypotension- or hypertension-induced collapse, and Doppler-determined systolic arterial blood pressure varied between 120 mm Hg and 180 mm Hg. Immediately prior to surgery, the dog's PCV was 29%; blood typing was performed in anticipation of the potential requirement for a perioperative blood transfusion.

A midline celiotomy and median sternotomy were performed with the manubrium left intact. The right adrenal gland mass was covered in multiple enlarged vessels that communicated with the caudal vena cava, assumed to be distension of collateral circulation secondary to chronic obstruction of the vessel's lumen by the tumor thrombus (**Figure 2**). Massive, firm distension of the prehepatic por-

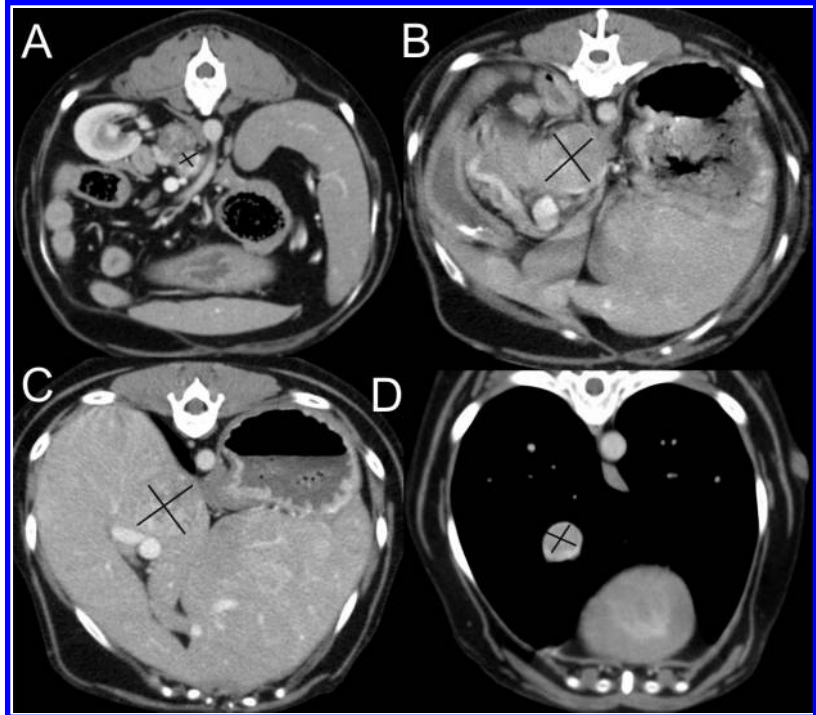


Figure 1—Transverse CT images of a right adrenal gland mass and intracaval extension of a tumor thrombus at the level of the insertion of the phrenicoabdominal vein on the postrenal portion of the caudal vena cava (A), the porta hepatis (B), the midhepatic portion of the caudal vena cava (C), and the mid-thoracic portion of the caudal vena cava in a 14-year-old dog that had a 3-week history of collapse during exercise and was evaluated because of recumbency, tachycardia, and hypotension. The cross marks the cross section of the caudal vena cava containing tumor thrombus at each level.

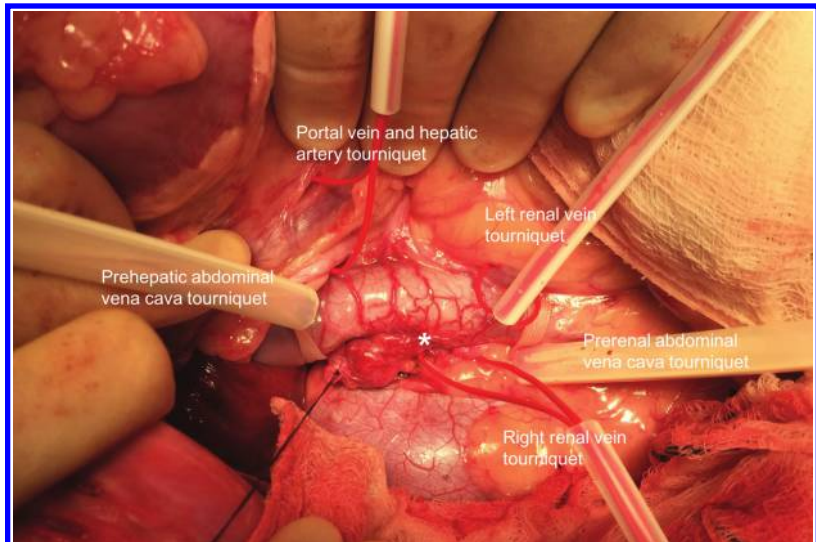


Figure 2—Intraoperative photograph of the abdomen of the dog in Figure 1. The right adrenal gland mass has been isolated by blunt dissection up to its attachment on the caudal vena cava via the right phrenicoabdominal vein. Multiple enlarged collateral vessels (asterisk) are communicating between the adrenal gland capsule and caudal vena cava. Massive, firm distension of the caudal vena cava by the tumor thrombus is evident immediately cranial to the insertion of the phrenicoabdominal vein. Rumel tourniquets have been placed around the left and right renal veins, the pre- and postrenal abdominal portions of the caudal vena cava, and the hepatic artery and portal vein together (Pringle maneuver).

tion of the caudal vena cava by the tumor thrombus was palpated. The right adrenal gland was isolated with blunt dissection and a combination of diathermy and application of titanium ligation clips^c and ligatures until it only remained attached to the caudal vena cava via the right phrenicoabdominal vein containing the tumor thrombus. Rumel tourniquets^d were placed around both renal veins, the pre- and postrenal portions of the caudal vena cava, the thoracic portion of the caudal vena cava, and the hepatic artery and portal vein together at the epiploic foramen to allow hepatic inflow occlusion (Pringle maneuver) and thereby reduce backflow of blood from the liver into the venotomy during occlusion of the thoracic portion of the caudal vena cava (**Figures 2 and 3**). Heparin sodium solution^e (50 U/kg [22.7 U/lb], IV) was administered prophylactically 5 minutes before starting the venotomy. During surgery, the

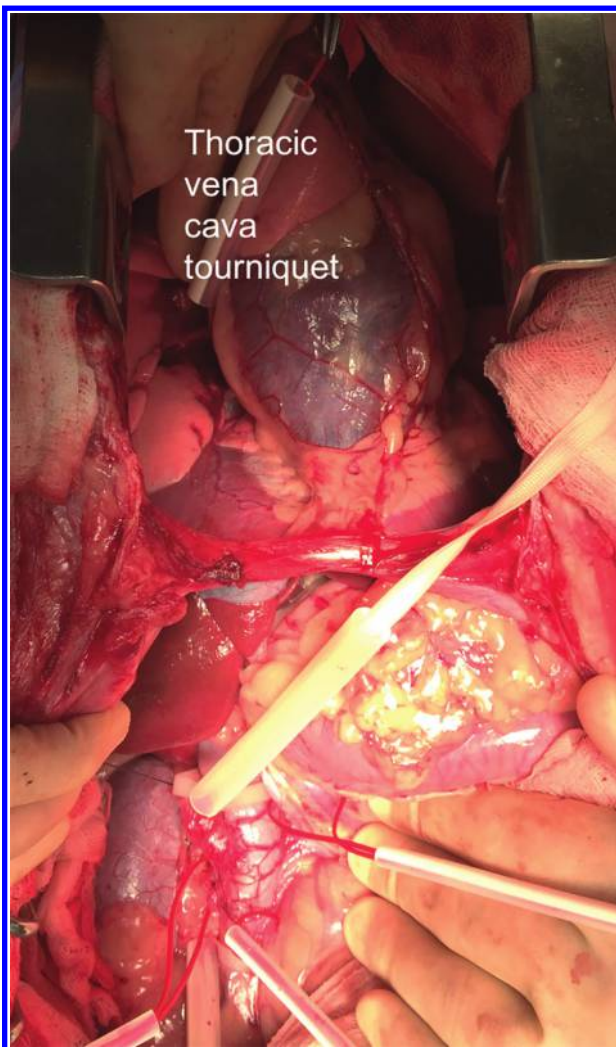


Figure 3—Intraoperative photograph of the thoracic and abdominal cavities exposed by median sternotomy and midline celiotomy. In addition to the abdominal Rumel tourniquets, a tourniquet has been placed around the thoracic portion of the caudal vena cava.

dog was not actively warmed initially, and its esophageal temperature decreased to 29.9°C (85.8°F) by the time temporary venous occlusion was initiated. At the end of the venotomy, the esophageal temperature had further decreased to 26.1°C (79.0°F), and active warming of the dog with a circulating warm air device was commenced. At 20 minutes after the venotomy, the esophageal temperature had increased to 33°C (91.4°F).

During surgery, direct arterial blood pressure measurements were recorded from a right dorsal pedal metatarsal arterial catheter. Immediately prior to the venotomy, mean arterial blood pressure was 80 mm Hg, systolic arterial blood pressure was 130 mm Hg, and diastolic arterial blood pressure was 66 mm Hg. The Rumel tourniquets around both renal veins and the prerenal portion of the caudal vena cava were occluded, and a stopwatch timer was started. An elliptical venotomy was performed around the insertion of the right phrenicoabdominal vein on the caudal vena cava. The tumor extending down the phrenicoabdominal vein was attached to the main portion of the tumor thrombus in the caudal vena cava by a short, narrow stalk. The caval venotomy was extended cranially incrementally for a distance of 7 cm to its exposure limit at the porta hepatis in an attempt to facilitate removal of the tumor thrombus; however, the wide diameter of the tumor in the hepatic portion of the caudal vena cava precluded its removal. The tumor thrombus in the thoracic portion of the caudal vena cava was palpated and manually pushed caudally up to the level of the diaphragm with simultaneous caudal traction applied with forceps and manual retraction of the exposed tumor thrombus in the abdominal caval venotomy. Despite these efforts, the tumor thrombus in the hepatic portion of the vena cava could not be dislodged. The surgeon inserted an index finger into the abdominal caval venotomy underneath the tumor thrombus and curled it around the cranial end of the tumor to pull the thrombus out caudally through the abdominal venotomy. Following removal of the tumor, the Rumel tourniquet around the postrenal (prehepatic) portion of the caudal vena cava immediately caudal to the liver was occluded. The tourniquets around the prerenal abdominal portion of the caudal vena cava and both renal veins were released, and the caudal end of the venotomy was digitally occluded. However, mean arterial blood pressure remained low at 30 mm Hg (systolic arterial blood pressure, 40 mm Hg; diastolic arterial blood pressure, 24 mm Hg), and it was assumed that complete ligation of the abdominal portion of the caudal vena cava at this level would not be tolerated by the dog. Repair of the venotomy was elected. The tourniquets around the prerenal abdominal portion of the caudal vena cava and both renal veins were reoccluded, and the caval venotomy was closed with 5-0 polypropylene suture material^f placed in 2 overlapping continuous suture patterns (**Figure 4**). Air was allowed to escape from the caval

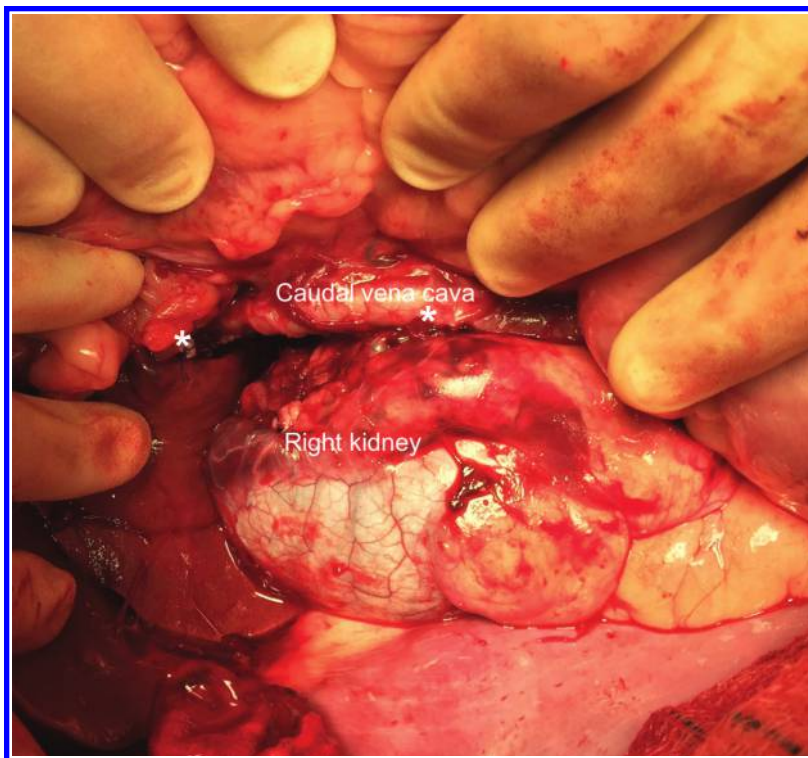


Figure 4—Intraoperative photograph of the 7-cm caudal vena cava venotomy, extending from the porta hepatis (left asterisk) to the level of insertion on the right renal vein (right asterisk).

lumen by temporarily releasing the occlusion before final closure of the suture line. Two additional simple interrupted sutures of 6-0 polypropylene suture material^f were placed at the caudal end of the continuous suture lines at the level of the right renal vein insertion on the caudal vena cava. There was an estimated 50% narrowing along the 7-cm caval venotomy once the venotomy closure had been completed. During suturing of the venotomy near the porta hepatis, the postrenal (prehepatic) abdominal portion of the caudal vena cava tourniquet had to be released twice for access while the tourniquets around the thoracic portion of the caudal vena cava, hepatic artery, and portal vein were each occluded for 5 minutes. The total occlusion time was 25 minutes, after which all tourniquets were released and refilling of the caudal vena cava with blood commenced.

During the occlusion period, mean arterial blood pressure ranged from 25 to 30 mm Hg, systolic arterial blood pressure ranged from 29 to 40 mm Hg, and diastolic arterial blood pressure ranged from 20 to 26 mm Hg. Strategies used to address intraoperative hypotension included IV administration of CSLS at a rate of 10 mL/kg/h (4.5 mL/lb/h) throughout surgery; IV administration of an additional bolus (10 mL/kg) of CSLS, 2 boluses (each 4 mL/kg [1.8 mL/lb]) of 6% hydroxyethyl starch solution,^g and 1 dose (20 µg/kg [9.1 µg/lb]) of phentolamine mesylate^h; and adjustment of isofluraneⁱ delivery to the lowest pos-

sible vaporizer settings (range, 0.6% to 2.4%) in combination with a remifentanyl hydrochloride^j infusion (0.3 to 0.4 µg/kg/min [0.14 to 0.18 µg/lb/min], IV) throughout the surgery. A packed RBC transfusion was started just prior to venous occlusion, and a total of 1.5 U of packed RBCs was administered. The abdomen and thorax were closed routinely with placement of a right-sided thoracic drain, which was removed the following day. On recovery from anesthesia, the dog's mean arterial blood pressure was 73 mm Hg, systolic arterial blood pressure was 115 mm Hg, and diastolic arterial blood pressure was 63 mm Hg; cardiac rhythm was apparently normal. Blood lactate concentration was within the reference interval immediately after surgery (1.3 mmol/L; reference interval, 0.6 to 2.5 mmol/L) and at 24 hours after surgery (1.1 mmol/L). The dog's PCV was 21% immediately after surgery and 35% at 24 hours after surgery. The day after surgery, serum biochemical analyses revealed mild azotemia (urea concentration, 13.7 mmol/L [reference interval, 3.0 to 9.1 mmol/L]; creatinine concentration, 287 µmol/L [reference interval, 59 to 138 µmol/L]); resolution of this abnormality was evident at 6 weeks after surgery.

Gross examination of the adrenal gland mass and tumor thrombus confirmed the presence of an adrenal gland mass attached by a short, narrow stalk (tumor in the phrenicoabdominal vein) to a long, wide extension of the tumor (tumor within the prehepatic, hepatic, and thoracic portions of the caudal vena cava [Figure 5]). Collateral vessels and the adrenal gland tumor had directly invaded the intraluminal surface of the portion of the caudal vena cava wall existed along with the adrenal gland mass and intraluminal tumor thrombus (Figure 6). Histologic examination findings confirmed that the tumor was a pheochromocytoma, which had expanded and replaced the medulla of the adrenal gland, infiltrated the adrenal gland cortex, extended through the adrenal capsule into the adjacent adipose tissue, and multifocally directly infiltrated the wall of the caudal vena cava. The neoplastic cells invading the vena cava formed discrete clusters between the myocytes of the tunica media, and there was associated secondary proliferation of the vasa vasorum (consistent with the distended collateral circulation observed at surgery). In addition, multifocally, blood vessels contained tumor cells within the lumen (neoplastic emboli) indicative of vascular invasion.

The dog was discharged from the hospital 5 days after surgery, and the owners were instructed

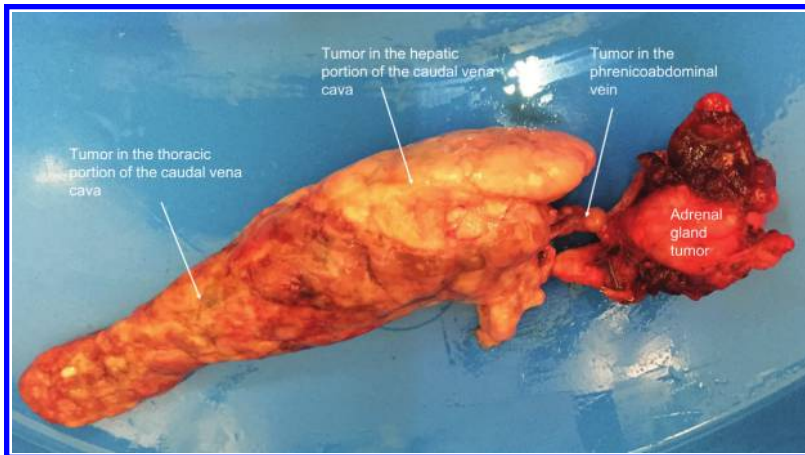


Figure 5—Photograph of the right adrenal gland mass attached by a short, narrow stalk (tumor in the phrenicoabdominal vein) to a long, wide extension of the tumor (tumor that previously had been located in the prehepatic, hepatic, and thoracic portions of the caudal vena cava) in the dog in Figure 1.

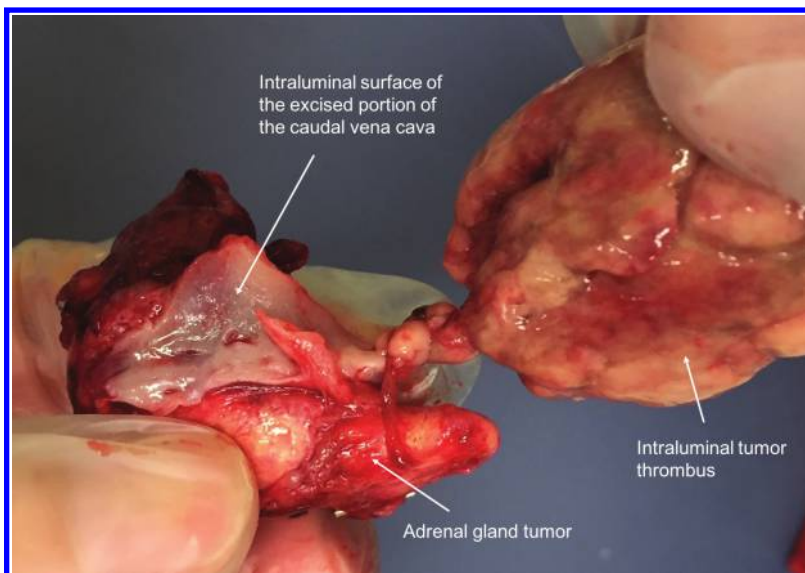


Figure 6—Photograph of the intraluminal surface view of the portion of the caudal vena cava wall that was excised along with the adrenal gland mass and intraluminal tumor thrombus, illustrating the direct communication between the adrenal gland tumor and the wall of the caudal vena cava.

to provide strict rest for 6 weeks. Mild regurgitation occurred approximately once daily; treatment with omeprazole^k (1 mg/kg, PO, q 24 h) was started, and after 3 weeks, regurgitation had resolved. At a reexamination 6 weeks after surgery, the dog was reported to be doing well at home, and results of a physical examination and clinicopathologic analyses were considered normal. One week later, after resuming normal exercise, the dog was reevaluated because of 1 episode of collapse while exercising. Physical examination findings were unremarkable, and Doppler-determined systolic arterial blood pressure was 130 mm Hg. Abdominal ultrasonography revealed an organized blood clot within the caudal vena cava lumen at the site of the venotomy. Hema-

tologic analyses revealed mildly regenerative anemia with a PCV of 23%, and thromboelastography revealed mild hypercoagulability. Treatment with clopidogrel bisulfate^l (2 mg/kg, PO, q 12 h) was initiated to reduce the risk of progressive blood clot formation. At a reexamination 9 weeks after surgery, the dog was bright and reported to be doing well at home; hence, repeated imaging was declined by the owners. Findings of a physical examination and repeated hematologic analyses were apparently normal, and clopidogrel administration was discontinued. The dog was reexamined 11 months after surgery, and physical examination findings were within reference intervals. The owners perceived the dog to be enjoying twice-daily normal-level exercise. At reexamination 20 months after surgery, physical examination findings were unremarkable and the owners reported that the dog continued to exercise normally with no clinical signs.

Discussion

To the author's knowledge, sparse information regarding surgical techniques for removal of adrenal tumor thrombi that extend within the vena cava distal to the diaphragm in dogs has been published. Several reports¹⁻⁴ mention extensive adrenal tumor thrombi that were deemed nonresectable. One study² included 7 dogs with tumor thrombi extending beyond the hepatic hilus, but there was no precise information regarding the limits of extension or a detailed description of the surgical technique used to remove the thrombus for each case. One report⁵ of 6 dogs included 2 that underwent caudal sternotomy to access the thoracic portion of the vena cava; in those 2 cases, the extracaval mass was removed separately first, followed by removal of the intracaval tumor thrombus, but additional surgical details were not provided. For the dog of the present report, the surgical plan was to attempt en bloc removal of the right adrenal gland tumor and the tumor thrombus that extended into the caudal vena cava, in keeping with oncological principles. In a study¹ of 40 dogs with adrenal gland tumors, while the caudal tourniquet was fully occluded, the tourniquet around the prehepatic abdominal portion of the vena cava remained loosened in 2 dogs that had a tumor thrombus extending into the hepatic portion of the vena cava until the tumor thrombus had been removed; this was followed by venotomy closure inside

a tangential clamp that partially occluded the vena cava, thereby allowing removal of the tourniquets during closure of the venotomy.

In the dog of the present report, concurrent median sternotomy to allow access to the thoracic portion of the vena cava was planned from the outset because of the width of the tumor thrombus in the hepatic portion of the caudal vena cava and its extension beyond the diaphragm into the thoracic portion of the caudal vena cava. However, the plan was accompanied by serious preoperative concerns that the required length of the venotomy would not allow tourniquet-assisted occlusion of the prehepatic portion of the caudal vena cava following tumor thrombus removal, that the venotomy would be too long to allow closure within a tangential clamp, or that the venotomy would be too close to the porta hepatis to allow easy placement of a tangential clamp. It was also thought that the risk of fragmentation of the tumor thrombus during removal and potential release of a portion of the tumor thrombus within the thoracic portion of the caudal vena cava was high, which would also necessitate median sternotomy access to occlude the thoracic portion of the caudal vena cava and any fragments of thrombus within it so that they could be retrieved via the venotomy. A transdiaphragmatic approach was considered, but for the aforementioned reasons, access provided by a median sternotomy appeared preferable. The possible need for complete rather than partial caval occlusion during venotomy closure, the likelihood of a longer than usual total vascular occlusion time, and a possible requirement for tourniquet occlusion of the thoracic portion of the caudal vena cava, hepatic artery, and portal vein in addition to the usual temporary occlusion of the abdominal portion of the caudal vena cava and renal veins were discussed with the anesthesia team prior to surgery. The CT scan was important for measurement of the size and assessment of the extension of the intracaval portion of the adrenal tumor thrombus, thereby facilitating careful preoperative planning.

In a study⁶ of the hemodynamic and metabolic effects of occlusion of the thoracic portion of the caudal vena cava for an 8-minute period via a fifth intercostal thoracotomy in 6 healthy experimental dogs, spontaneous hemodynamic normalization occurred within 5 minutes after release of the occlusion. The total occlusion time for the dog of the present report was unavoidably extended beyond 8 minutes to a total of 25 minutes; however, this prolonged period of occlusion appeared to be tolerated by the dog, albeit with mild, self-resolving azotemia during the postoperative period. Trial occlusion of the prehepatic portion of the caudal vena cava in the dog during surgery was associated with severe hypotension; therefore, ligation of the vena cava was rejected as an option despite reports^{7,8} of successful suprarenal ligation and venectomy in 2 other dogs in which vascular invasion could not be corrected surgically. In the dog of

the present report, intraoperative hypothermia was intentionally induced by not initiating active warming during anesthesia until after the venotomy procedure, with the aim of potentially reducing the risk of neurologic injury associated with the anticipated temporary ischemic insult caused by prolonged vascular occlusion. Intraoperative hypothermia during adrenalectomy with caval invasion by tumor thrombi in dogs has been advocated by other authors,^{1,4} although whether it was of benefit in this case was unknown.

In the case described in the present report, histopathologic findings confirmed that direct adrenal gland tumor invasion into the caudal vena cava wall had occurred along the established common route of tumor extension down the phrenicoabdominal vein. A previous study¹ included 2 dogs with broad-based involvement of the caval wall, one of which had a local caval tumor thrombus that required partial resection of the caval wall; the other dog had an extensive caval tumor thrombus that was judged to be nonresectable. Histologic examination findings for tissue sections from the region of broad-based attachment did not mention whether direct tumor invasion of the caval wall was detected. In the report of that study,¹ it was noted that unless an attempt is made to dissect the neoplastic adrenal gland tissue from the caval wall, a surgeon can be easily misled into thinking that there is direct extension of the tumor through the caval wall, leaving doubt as to whether those 2 dogs in the previous study¹ truly had direct tumor extension.

Potential complications of venotomy procedures include hemorrhage, venous air embolism, vein narrowing or stricture, and thromboembolism. In the dog of the present report, although marked hemorrhage was encountered during removal of the tumor and necessitated administration of a blood product, the venotomy closure itself did not leak or require further augmentation. Air was allowed to escape from the caval lumen by temporarily releasing the occlusion before final closure of the suture line. An ellipse of the caudal vena cava wall was excised, and a long venotomy was performed, resulting in an estimated 50% narrowing along the 7-cm caval venotomy. Although the degree of caval narrowing in the dog of the present report did not appear to interfere with restoration of normal blood arterial pressure and other cardiovascular variables after surgery, it was a very likely risk factor for the postoperative thromboembolic complications that the dog developed. Pheochromocytoma, venotomy, and blood transfusion were also all factors that increased the risk of disseminated intravascular coagulation in a series of dogs undergoing adrenalectomy.² The base of evidence for anticoagulation protocols in small animal patients is sparse, and protocols are typically highly variable among institutions and individuals. To the author's knowledge, there are no reported studies of the incidence of thromboembolism associated with

different anticoagulation treatments in dogs or cats undergoing adrenalectomy.⁹ The risk of administering a systemic anticoagulant to any animal undergoing a venotomy must be weighed carefully against the potential benefits. In dogs undergoing venotomy, use of local anticoagulation strategies, such as topical application of an ice-cold solution of 2% lidocaine, heparin, and saline (0.9% NaCl) solution to thoroughly flush the isolated vein prior to closure,¹⁰ could be considered. Furthermore, instead of the single IV dose of heparin solution administered prophylactically 5 minutes before starting the venotomy in the case described in the present report, one could consider more extended systemic anticoagulation protocols, such as that applied to dogs undergoing adrenalectomy wherein heparin was administered in plasma during surgery with additional heparin doses tapered over several days.¹ Prophylactic clopidogrel administration in dogs undergoing vascular surgery has not been reported, to the author's knowledge, but it has been used with relative safety in a prospective study¹¹ of dogs with immune-mediated hemolytic anemia. Given that, prophylactic clopidogrel administration to dogs with adrenal gland tumors and caval invasion of tumor thrombi that undergo adrenalectomy seems attractive and also warrants careful consideration.

In 1 study,² dogs with caval tumor thrombi that extended beyond the hepatic hilus were > 4 times as likely to die during the short-term period as were dogs with caval tumor thrombi that did not extend past the hilus. Therefore, the owners of the dog of the present report were forewarned of their dog's higher risk of death and offered the option of euthanasia as an alternative to surgery. A carefully planned team approach, including consideration of the anticipated anesthesia and postoperative critical care conditions, and ready availability of blood products are as important as the technical aspects of the surgery itself. Dogs that survive the perioperative period following surgery to treat adrenal gland tumors with or without caval invasion have consistently long survival times of many years.^{1,2,4,12} The case described in the present report has highlighted the fact that a good long-term outcome is possible even for dogs that have advanced or severe disease.

Acknowledgments

The author declares that there were no conflicts of interest.

Footnotes

- a. Aquapharm 11 (Hartmann) solution for infusion, Animal Care Ltd, York, England.

- b. Mercury Pharmaceuticals Ltd, London, England.
- c. Premium Surgiclip II, Auto Suture, Medtronic, Watford, England.
- d. Medtronic, Watford, England.
- e. Wockhardt, Wrexham, England.
- f. Prolene, Ethicon, Johnson & Johnson Medical Ltd, Livingston, Scotland.
- g. Voluvyte 6%, Poly(O-2-hydroxyethyl)starch (Ph Eur), Fresenius Kabi Ltd, Runcorn, England.
- h. Alliance Pharma plc, Chippenham, England.
- i. Isocare 100% w/v Inhalation vapour, liquid (isoflurane), Animalcare Ltd, York, England.
- j. Remifentanyl, 2 mg powder for concentrate for solution for Injection or Infusion, Teva UK Ltd, Castleford, England.
- k. Zentiva, Guildford, England.
- l. Plavix, Doncaster Pharmaceuticals Group Ltd, Doncaster, England.

References

1. Kyles AE, Feldman EC, De Cock HEV, et al. Surgical management of adrenal gland tumors with and without associated tumor thrombi in dogs: 40 cases (1994–2001). *J Am Vet Med Assoc* 2003;223:654–662.
2. Barrera JS, Bernard F, Ehrhart EJ, et al. Evaluation of risk factors for outcome associated with adrenal gland tumors with or without invasion of the caudal vena cava and treated via adrenalectomy in dogs: 86 cases (1993–2009). *J Am Vet Med Assoc* 2013;242:1715–1721.
3. Pradelli D, Quintavalla C, Domenech O, et al. Tumour thrombus: direct endoluminal “caudal caval vein - right atrium” extension in a dog affected by adrenal neoplasia. *Vet Res Commun* 2003;27(suppl 1):787–789.
4. Schwartz P, Kovak JR, Koprowski A, et al. Evaluation of prognostic factors in the surgical treatment of adrenal gland tumors in dogs: 41 cases (1999–2005). *J Am Vet Med Assoc* 2008;232:77–84.
5. Gilson SD, Withrow SJ, Orton EC. Surgical treatment of pheochromocytoma: technique, complications, and results in six dogs. *Vet Surg* 1994;23:195–200.
6. Hunt GB, Malik R, Bellenger CR, et al. A new technique for surgery of the caudal vena cava in dogs using partial venous inflow occlusion. *Res Vet Sci* 1992;52:378–381.
7. Guillaumot PJ, Heripret D, Bouvy BM, et al. 49-month survival following caval venectomy without nephrectomy in a dog with a pheochromocytoma. *J Am Anim Hosp Assoc* 2012;48:352–358.
8. Louvet A, Lazard P, Denis B. Pheochromocytoma treated by en bloc resection including the suprarenal caudal vena cava in a dog. *J Small Anim Pract* 2005;46:591–596.
9. Adin CA, Nelson RW. Adrenal glands. In: Tobias KM, Johnston SA, eds. *Veterinary surgery: small animal*. 2nd ed. St Louis: Elsevier Saunders, 2018;2033–2042.
10. Phillips H, Aronson L. Vascular surgery. In: Tobias KM, Johnston SA, eds. *Veterinary surgery: small animal*. 2nd ed. St Louis: Elsevier Saunders, 2018;1854–1869.
11. Mellett AM, Nakamura RK, Bianco B. A prospective study of clopidogrel therapy in dogs with primary immune-mediated hemolytic anemia. *J Vet Intern Med* 2011;25:71–75.
12. Lang JM, Schertel E, Kennedy S, et al. Elective and emergency surgical management of adrenal gland tumors: 60 cases (1999–2006). *J Am Anim Hosp Assoc* 2011;47:428–435.