

Branch ligatures and blood aspiration for post-traumatic superficial temporal artery pseudoaneurysm: surgical technique

Zoran Rancic · Felice Pecoraro · Gianluigi Nigro ·
Roger Simon · Thomas Frauenfelder ·
Dieter Mayer · Mario Lachat

Received: 19 December 2012 / Accepted: 5 February 2013 / Published online: 13 February 2013
© The Japanese Association for Thoracic Surgery 2013

Abstract The aim of this study is to report a new minimally invasive technique of superficial temporal artery (STA) pseudoaneurysm treatment. Several surgical options have been employed to treat STA pseudoaneurysms. To address this rare condition, the employed techniques are ligation and excision of the aneurysm, endovascular coil embolization or percutaneous ultrasound-guided thrombin injection. Between techniques no significant differences are reported in terms of outcomes. The decision to adopt a technique depends on STA pseudoaneurysm morphology and surgeon preference. In the present report, STA pseudoaneurysm afferent and efferent branches were identified by ultrasound in a 92-year-old female. Under local anaesthesia, these branches were ligated through small skin incisions. STA pseudoaneurysm decompression was obtained by an ‘over the needle aspiration’. A compressive dressing was left in space for 48 h.

Keywords Temporal · Artery · Pseudoaneurysm · Post-traumatic

Introduction

Several options to treat superficial temporal artery (STA) pseudoaneurysm have been reported. Although pseudoaneurysm ligation and excision was the first employed technique [1], more recently endovascular coil embolization [2] and percutaneous ultrasound-guided thrombin injection [3] have been reported. STA pseudoaneurysm morphology and surgeon preference lead to technique selection. In the present case, a new minimally invasive technique to treat a STA pseudoaneurysm in a nonagenarian lady is reported.

Case report

A 92-year-old lady was admitted with a headache and pulsating mass in the left fronto-temporal region. At anamnesis a traumatic head injury, after a fall down stairs, was reported 4 weeks earlier. At medical history hypertension, mitral insufficiency, chronic atrial fibrillation and left atrial appendage thrombus, insulin-dependent diabetes mellitus and advanced chronic renal failure were present. The patient was under oral anticoagulation because of cardiac disease (INR: 2.0). At admission patient presented headache and left periorbital mass. A spiral computed tomography (CT), performed due to skull fracture suspicion, showed no skull lesions; a partially thrombosed pseudoaneurysm originating from frontal terminal branch of STA (35 × 22 mm in diameter) and a nasal bone fracture were detected (Fig. 1).

Z. Rancic · F. Pecoraro · G. Nigro · D. Mayer · M. Lachat
Clinic for Cardiovascular Surgery, University Hospital Zurich,
Zurich, Switzerland

F. Pecoraro (✉)
Vascular Surgery Unit, University Hospital ‘P. Giaccone’,
Via L.Giuffrè, 5, 90100 Palermo, Italy
e-mail: felicepecoraro@libero.it

G. Nigro
Vascular Surgery Unit, Ospedale Regionale di Torrette,
Ancona, Italy

R. Simon
Clinic for Angiology, University Hospital Zurich, Zurich,
Switzerland

T. Frauenfelder
Department of Radiology, University Hospital Zurich, Zurich,
Switzerland

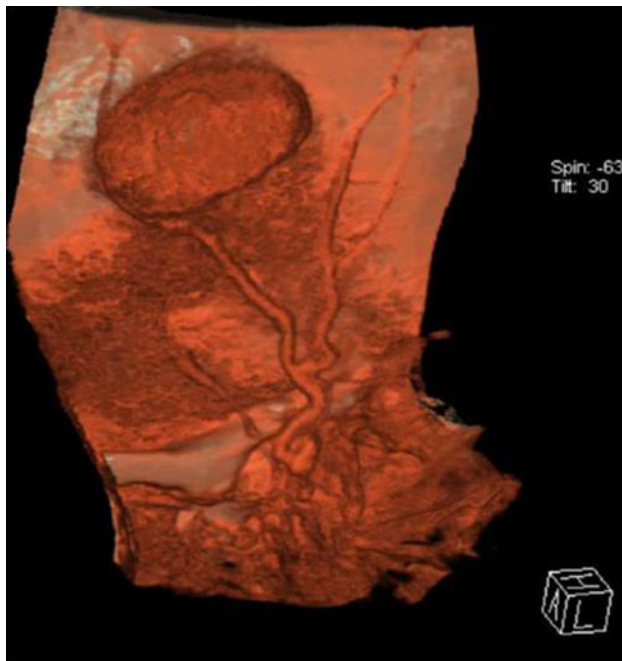


Fig. 1 Preoperative findings. Computed tomography angiography. Superficial temporal artery pseudoaneurysm

Technique

After an unsuccessful 20-min compression on both STA pseudoaneurysm and afferent branch, an operative management was scheduled. Both afferent and efferent branches were identified and marked with ultrasound (US)

(Fig. 2a). No other branches were identified both by CT and US preoperatively. Through 1 cm skin incisions both branches were identified, dissected and ligated (Fig. 2b). After ligation, no pulsation was more recognizable. STA pseudoaneurysm decompression was achieved: over a 14 G needle was aspirated 15 ml of blood thus reducing considerably pseudoaneurysm size (Fig. 2c). A compressive dressing was left in place for 48 h (Fig. 2d). Recovery was uneventful. The patient was discharged at first postoperative day. During the STA management and at discharge anticoagulant therapy was not modified. Follow-up at 2 weeks and 2 months later showed no signs of recurrence (Fig. 3).

Discussion

In 1861, both a surgical and a conservative approach to “cure aneurysms of the temporal artery” were reported. The first consisted of “opening the tumour, turning out its contents, and tying the artery on each side of it”. However, a conservative management by “pressure of the proximal end of the vessel with the finger” was considered as the most indicated approach [1]. STA pseudoaneurysm is rare, with about 200 cases reported mostly as isolated case [4]. STA pseudoaneurysm is suspected in the presence of a preauricular pulsatile mass associated to a history of trauma or surgery into the temporal region. The time from injury to STA pseudoaneurysm development is usually

Fig. 2 Intraoperative findings. **a** Afferent and efferent branches ultrasound identification. **b** Afferent branch exposition and dissection through small skin incision. **c** Final result at skin closure and superficial temporal artery pseudoaneurysm percutaneous decompression. **d** Compressive dressing application

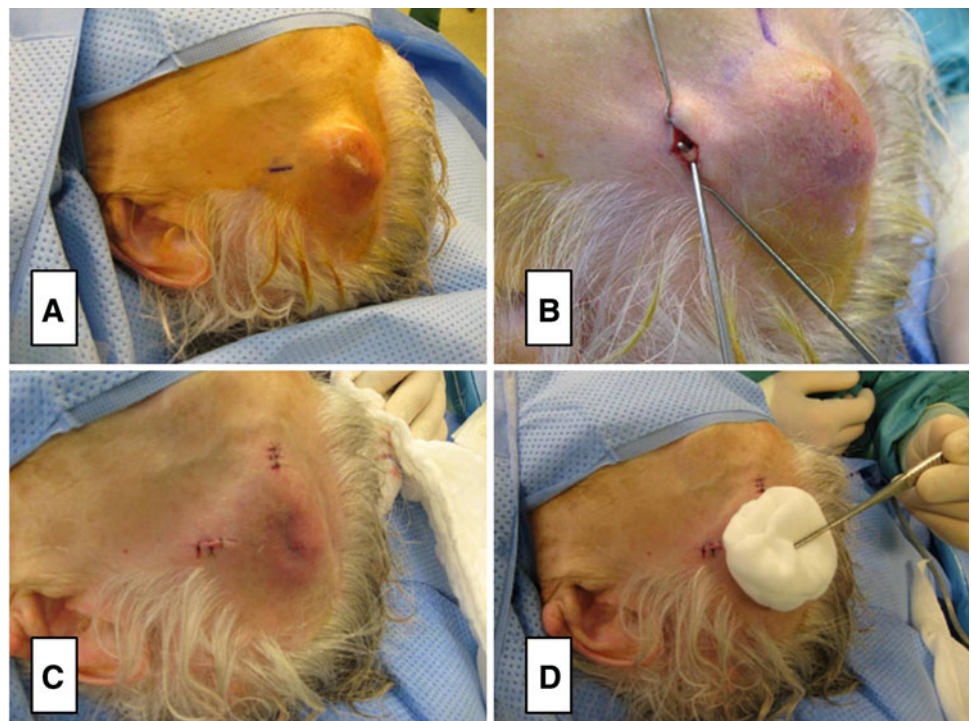
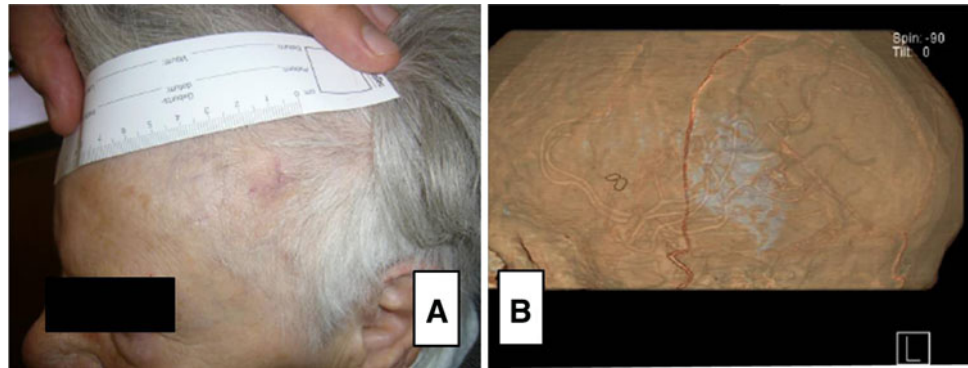


Fig. 3 Two months postoperative findings. **a** Clinical evidence. No aesthetic defect. **b** Computed tomography angiography. No residual pseudoaneurysm, complete occlusion of frontal superficial temporal artery branch and parietal branch patency



2–6 weeks, less than 20 % present between 6 months and 3 years after injury. The clinical diagnosis is supported either by US, CT and angiography. Although STA pseudoaneurysm rupture has been reported, no definitive data upon its natural history are available [5]. A surgical repair is usually indicated when pain, cosmetic deformity, and the potential for rupture is present [6]. The most employed operative technique remains branches ligation and pseudoaneurysm excision under local anaesthesia [6]. A conservative approach can be utilized in critically ill patients [7]. Other operative options, such as transarterial pseudoaneurysm coiling [2, 8] and ultrasound percutaneous embolization [2, 9, 10] can be effective. The reported allergic reaction, systemic thrombosis, distal ischemia, and related-cost represent a limitation to a widespread use of these approaches [2, 11]. In the present case, the attempt to treat the pseudoaneurysm with 20-min compression of afferent branch was not successful. An endovascular approach was excluded due to severe atherosclerosis of aortic arch and external carotid artery, and the chronic renal failure. After branches ligation, the STA pseudoaneurysm surgical excision was replaced by percutaneous sac puncture and blood aspiration, thus achieving a significant mass reduction. It could be argued about the concept to leave the pseudoaneurysm sac in place. In our experience, STA pseudoaneurysm evolution into fibrotic tissue did not generate any scar or skin retraction. The limited time of follow-up, however, is not enough to validate this technique.

Conclusion

This surgical approach was safe and effective in STA pseudoaneurysm treatment. Its minimally invasive feature allowed limited exposition with unnecessary anticoagulation therapy modification and good aesthetic result. This

technique could be included in armamentarium of STA pseudoaneurysm treatment.

Conflict of interest Zoran Rancic and other co-authors have no conflict of interest.

References

1. Anonymous (1861) St. George's Hospital. Aneurysm of temporal artery, cure by compression. *Lancet* 2:135.
2. Hong JT, Lee SW, Ihn YK, et al. Traumatic pseudoaneurysm of the superficial temporal artery treated by endovascular coil embolization. *Surg Neurol*. 2006;66(1):86–8.
3. Mann GS, Heran MK. Percutaneous thrombin embolization of a post-traumatic superficial temporal artery pseudoaneurysm. *Pediatr Radiol*. 2007;37(6):578–80.
4. Walker MT, Liu BP, Salehi SA, Badve S, Batjer HH. Superficial temporal artery pseudoaneurysm: diagnosis and preoperative planning with CT angiography. *AJNR Am J Neuroradiol*. 2003; 24(1):147–50.
5. Peick AL, Nichols WK, Curtis JJ, Silver D. Aneurysms and pseudoaneurysms of the superficial temporal artery caused by trauma. *J Vasc Surg*. 1988;8:606–10.
6. Lee KS, Gower DJ, McWhorter JM. Aneurysm of the superficial temporal artery. *Neurosurgery*. 1988;23:499–500.
7. Grasso RF, Quattrocchi CC, Crucitti P, Carboni G, Coppola R, Zobel BB. Superficial temporal artery pseudoaneurysm: a conservative approach in a critically ill patient. *Cardiovasc Intervent Radiol*. 2007;30(2):286–8.
8. Sanchez F, Delgado F, Ramos M. Pseudoaneurysm of the superficial temporal artery treated by embolization: report of a case. *J Oral Maxillofac Surg*. 2000;58(7):819–21.
9. Partap VA, Cassoff J, Glikstein R. US-guided percutaneous thrombin injection: a new method of repair of superficial temporal artery pseudoaneurysm. *J Vasc Interv Radiol*. 2000;11(4):461–3.
10. Bobinski L, Boström S, Hillman J, Theodorsson A, et al. Post-operative pseudoaneurysm of the superficial temporal artery (S.T.A.) treated with Thrombostat (thrombin glue) injection. *Acta Neurochir (Wien)*. 2004;146(9):1039–41.
11. Komorowska-Timek E, Teruva TH, Abou-Zamzam AM Jr, Papa D, Ballard JL. Treatment of radial and ulnar artery pseudoaneurysms using percutaneous thrombin injection. *J Hand Surg Am*. 2004;29(5):936–42.