

Eur Spine J (2014) 23:985–990
DOI 10.1007/s00586-013-3071-3

ORIGINAL ARTICLE

Increased intraoperative epidural pressure in lumbar spinal stenosis patients with a positive nerve root sedimentation sign

Thomas Barz · Markus Melloh · Lukas P. Staub · Sarah J. Lord · Jörn Lange · Harry R. Merk

Received: 8 October 2012 / Revised: 17 June 2013 / Accepted: 10 October 2013 / Published online: 29 October 2013
© Springer-Verlag Berlin Heidelberg 2013

Abstract

Purpose The sedimentation sign (SedSign) has been shown to discriminate well between selected patients with and without lumbar spinal stenosis (LSS). The purpose of this study was to compare the pressure values associated with LSS versus non-LSS and discuss whether a positive SedSign may be related to increased epidural pressure at the level of the stenosis.

Methods We measured the intraoperative epidural pressure in five patients without LSS and a negative SedSign,

and in five patients with LSS and a positive SedSign using a Codman™ catheter in prone position under radioscopy.

Results Patients with a negative SedSign had a median epidural pressure of 9 mmHg independent of the measurement location. Breath and pulse-synchronous waves accounted for 1–3 mmHg. In patients with monosegmental LSS and a positive SedSign, the epidural pressure above and below the stenosis was similar (median 8–9 mmHg). At the level of the stenosis the median epidural pressure was 22 mmHg. A breath and pulse-synchronous wave was present cranial to the stenosis, but absent below. These findings were independent of the cross-sectional area of the spinal canal at the level of the stenosis.

Conclusions Patients with LSS have an increased epidural pressure at the level of the stenosis and altered pressure wave characteristics below. We argue that the absence of sedimentation of lumbar nerve roots to the dorsal part of the dural sac in supine position may be due to tethering of affected nerve roots at the level of the stenosis.

Thomas Barz and Markus Melloh have contributed equally to this study.

T. Barz

Department of Orthopaedic Surgery, Asklepios Klinikum Uckermark, Schwedt, Germany

M. Melloh

Centre for Medical Research, University of Western Australia, Nedlands, Australia

L. P. Staub (✉)

MEM Research Center, Institute for Evaluative Research in Orthopaedic Surgery, University of Bern, Bern, Switzerland
e-mail: lukas.staub@memcenter.unibe.ch

L. P. Staub · S. J. Lord

NHMRC Clinical Trials Centre, University of Sydney, Sydney, Australia

J. Lange

Department of Trauma and Reconstructive Surgery, Medical Faculty, University of Greifswald, Greifswald, Germany

H. R. Merk

Department of Orthopaedic Surgery, Medical Faculty, University of Greifswald, Greifswald, Germany

Keywords Lumbar spinal stenosis · Nerve root sedimentation · Epidural pressure · Spinal surgery · Intraoperative

Introduction

Since lumbar spinal stenosis (LSS) was first described by Verbiest in 1954 [1]; no consensus has been established on how to define symptomatic LSS using clinical, radiological or pathological criteria [2–7]. In recent years, a number of studies have been published focusing on the correlation between symptomatic LSS and clinical and radiological tests such as walking distance and cross-sectional area

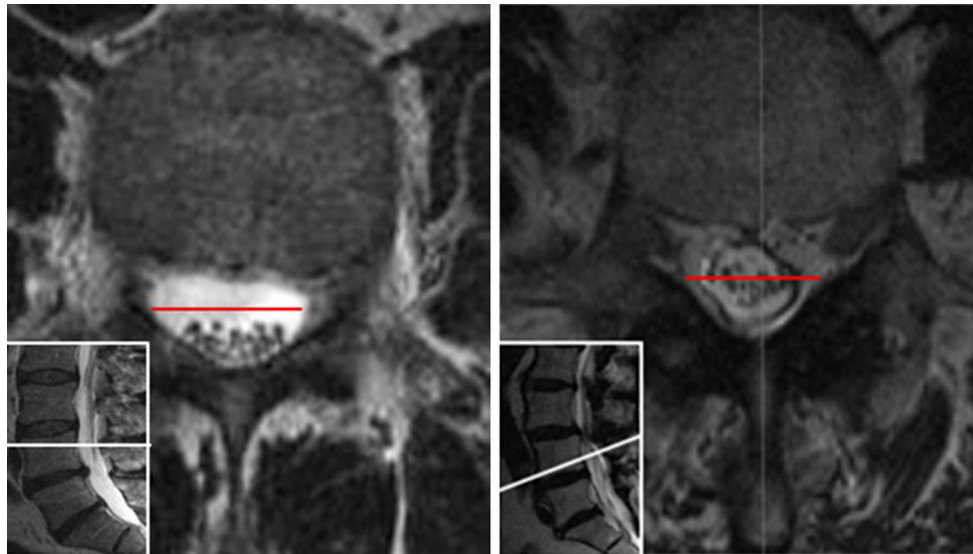


Fig. 1 Nerve root sedimentation sign, *left* negative sign, *right* positive sign

(CSA) of the dural sac, to determine diagnostic criteria where surgery is indicated [3, 8, 9].

With the recently introduced nerve root sedimentation sign (SedSign), it has been attempted to base the surgical indication for patients with LSS on an additional imaging characteristic [10]. The SedSign is measured in supine position in lumbar transverse magnetic resonance imaging (MRI) scans. A positive SedSign is defined as nerve roots being located in the ventral or central part of the dural sac as seen in patients with severe LSS. A negative SedSign is defined as all nerve roots being located in the dorsal part of the dural sac (Fig. 1). The SedSign has been found to discriminate well between patients with symptomatic LSS and patients with non-specific low back pain [10].

Experimental animal studies have reported increased epidural pressures at the level of spinal stenosis [11–15]. Increased pressure could also be responsible for a positive SedSign in patients with LSS, inhibiting the sedimentation of nerve roots to the dorsal part of the dural sac. Increased epidural pressure at the level of the stenosis would provide an explanation for the appearance of nerve roots as ‘tethered’ in the spinal canal at this level as if held by a mechanical clamp. To our knowledge, no published data on values of epidural pressure in the spinal canal of LSS patients are available. Most of the existing studies focus on cerebral pressure [16–23]. The aims of this study were to establish a method of measuring epidural pressure, and to present pressure values associated with a positive SedSign in patients undergoing spinal surgery for LSS and for patients without LSS and a negative SedSign undergoing other types of spine surgery.

Materials and methods

This is an analytical proof-of-concept study of epidural pressure measurement in patients undergoing spinal surgery. The study adhered to the recommendations of the Declaration of Helsinki (2008) and was approved by the Ethics Committee of the Brandenburg Medical Association, Germany (AS 107 (Bb)/2011). Patients gave their written consent for the intraoperative measurement of the epidural pressure that required an extension of operating time by approximately 20 min.

Between August and December 2011, we measured the intraoperative epidural pressure in five patients with monosegmental LSS and a positive SedSign, and in another five spine patients without LSS or any other pathology of the spinal canal and a negative SedSign. Patients without LSS or any other pathology of the spinal canal were either suffering from lumbar instability or foraminal stenosis and were treated with either fusion or foraminal decompression surgery. There is no standardized and commonly accepted procedure for the measurement of epidural pressure. Initial measurements in our study with an epidural catheter and a pressure transducer did not produce reliable data in the operating situation. Therefore, we decided to measure epidural pressure directly, using an intracranial pressure sensor (Codman™, Johnson & Johnson; Fig. 2).

Preoperatively, all patients underwent lumbar MRI examination with the CSA measured in transverse T2-weighted scans. Surgery was performed with patients in prone position, using a standard posterior midline approach. Prior to the actual surgical intervention, the Codman™ catheter was first calibrated following the manufacturer’s instructions, and then inserted by means of

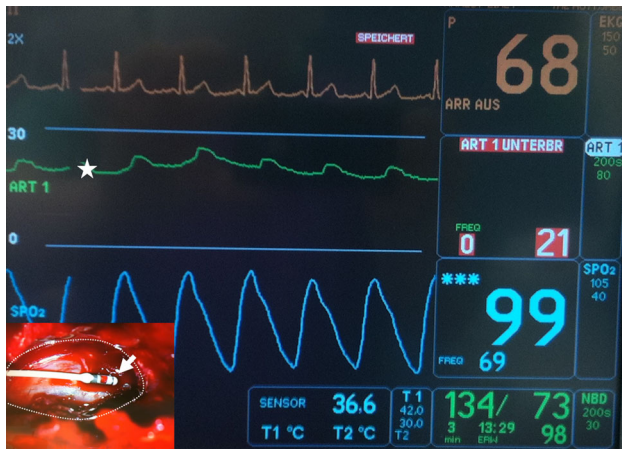

Fig. 2 Intraoperative view of patient with LSS and positive SedSign: introduction of Codman catheter tip with visible piezo element (arrow) into epidural space above dural sac at interlaminar window L5/S1 (lower left corner) and anesthetic monitor with epidural pressure and pressure curve (asterisk)

a tracking-catheter through an interlaminar window at L5/S1. A complete flavectomy had not been performed at this stage. The position of the Codman™ catheter was controlled by an image intensifier (Ziehm Solo™, Ziehm Imaging). From the beginning of surgery, epidural pressure, blood pressure and heart rate were measured continuously. Epidural pressure was measured at different locations in the lumbar spinal canal from L1/2 to L5/S1. Since pressure values during the positioning of the catheter fluctuate considerably due to the mechanical loading at the tip of the catheter, measurements were taken after a time lag of 10 s after positioning of the catheter. Pressure values were recorded at the level of the vertebral disc and at half height of the vertebral body. In addition, pressure curves

and their characteristics were documented. Each measurement was performed three times, and the measurement system automatically transformed waves into values and calculated the average of the three measurements. Measurement protocols were identical for patients in both study groups.

Results

Baseline characteristics, diagnoses and test results of all ten patients are provided in Table 1. Apart from the underlying spine disorder, the two patient groups were similar. Oswestry disability index (ODI) values were somewhat lower in patients with LSS compared to those without LSS.

Information about the surgical procedures and the measured pressure values is given in Table 2. In patients with monosegmental LSS and a positive SedSign, the median epidural pressure cranial to the stenosis was 9 mmHg (8–12). Similar pressures were measured caudal to the stenosis (median 8 mmHg, range 7–10). At the level of the stenosis, the median epidural pressure was 22 mmHg (21–26). These findings were independent of the CSA of the dural sac at the level of the stenosis. Cranial to the stenosis, the pressure curves recorded during continuous measurement displayed a breath and pulse-synchronous wave, i.e., the frequency of epidural pressure curve, artificial ventilation and heart rate were identical. However, this wave was absent below the stenosis.

Patients without LSS and a negative SedSign had a median epidural pressure of 9 mmHg (range 8–11) independent of the segmental level. The CSA of the dural sac and the level of the stenosis were not related to the epidural

Table 1 Baseline patient characteristics

Patient	Age	Sex	Diagnosis	ODI	VAS back	VAS legs	Loss of strength	Paresthesia	Treadmill test (m)	CSA (mm ²)	SedSign
Patients with monosegmental LSS											
1	64	M	Stenosis L3/4	34	8	8	4/5 Quadriceps	Dermatome L4	50	34	Positive
2	87	F	Stenosis L4/5	32	6	8	None	None	10	46	Positive
3	84	M	Stenosis L4/5	30	5	8	None	None	20	44	Positive
4	82	F	Stenosis L3/4	34	4	8	None	None	10	54	Positive
5	74	F	Stenosis L4/5	24	9	9	None	None	0	32	Positive
Patients without LSS											
6	73	M	Intraforaminal prolapse L5/S1	56	5	8	4/5 Ext.hall.	Dermatome L5	50	>120	Negative
7	67	F	Instability L5/S1	52	8	4	None	None	500	>120	Negative
8	78	F	Degenerative lumbar scoliosis	34	8	8	None	None	30	>120	Negative
9	80	M	Spondylolisthesis L5/S1	44	8	8	4/5 Ext.hall.	Dermatome L5	200	>120	Negative
10	76	F	Spondylolisthesis L4/L5	36	7	8	None	None	50	>120	Negative

LSS indicates lumbar spinal stenosis, ODI oswestry disability index, VAS visual analog scale, CSA cross-sectional area of dural sac, SedSign nerve root sedimentation sign

Table 2 Intraoperative epidural pressure measurements

Patient	Surgical procedure	Duration of surgery (min)	Epidural pressure (mmHg)			Systol BP (mmHg)	Diastol BP (mmHg)
			Cranial	Level of stenosis	Caudal		
Patients with monosegmental LSS and positive SedSign							
1	Dorsal fusion	210	8	21	7	125	77
2	Dorsal fusion	110	8	23	8	129	58
3	Selective decompression	55	9	26	9	127	76
4	Selective decompression	65	10	22	8	139	80
5	Dorsal fusion	300	12	21	10	130	76
Patients without LSS and negative SedSign							
6	Microsurgical revision of spinal disc	55	8	–	8	112	68
7	Dorsal fusion	105	9	–	9	128	72
8	Dorsal fusion	220	9	–	9	118	65
9	Dorsal fusion	160	8	–	8	125	75
10	Dorsal fusion	135	11	–	11	132	61

LSS indicates lumbar spinal stenosis, *systol BP* systolic blood pressure, *diastol BP* diastolic blood pressure, *SedSign* nerve root sedimentation sign

pressure. The pressure curves displayed a breath and pulse-synchronous wave throughout the measured area. The amplitude of the pressure curve was between 1 and 3 mmHg (Fig. 2).

Discussion

This proof-of-concept study presents a method to measure epidural pressure during spinal surgery. It showed that epidural pressure values at the level of a central stenosis are higher than above and below the stenosis. In addition, the epidural pressure above and below the stenosis in patients with severe LSS and a positive SedSign was found to be similar to the epidural pressure in patients without LSS and a negative SedSign. This study addresses an important knowledge gap in the current literature, as no published data on differential values of epidural pressure across the level of stenosis exist.

Since the publication of the first paper on the SedSign [10], the authors have been repeatedly asked one and the same question: which mechanism is responsible for the absence of lumbar nerve root sedimentation in patients with a central spinal canal stenosis? Previous papers have reported adherent or redundant nerve roots in patients with arachnoiditis [24–26], for example due to an operative dura lesion. However, we have repeatedly observed nerve root re-sedimentation after decompression of a central spinal canal stenosis, which refutes an arachnoiditis as potential cause of a positive SedSign (unpublished data). This observation suggests that a positive SedSign in patients with severe LSS might be caused by an increased epidural

pressure at the level of the stenosis, resulting in tethering of nerve roots in the spinal canal at that level, as if held by a mechanical clamp. Detection of localized increase in pressure would support this hypothesis.

The present study is the first to measure epidural pressure in spine patients directly by a CodmanTM catheter with a piezoelectric sensor that also allows continuous recording of the pressure curve. Using this technique, we also provide the first report in a clinical setting of changes in pressure wave characteristics below the stenosis. Our finding of a breath and pulse-synchronous wave cranial to the stenosis, but not distally provides evidence that in the normal spinal canal, the pressure curve of the cerebrospinal fluid originates in the cerebrum and propagates down the spine.

The absence of a breath and pulse-synchronous wave below the stenosis has important clinical implications. This phenomenon is commonly used by experienced spinal surgeons for intraoperative monitoring to estimate the surgical degree of selective decompression. Beyond the perceived correlation between surgical action and postoperative relief of the patient, even experienced surgeons have no objective criterion for a sufficient decompression. This may explain the varying degree of bony resection according to different surgical schools, leading to different rates of postoperative segmental instability.

The present study findings suggest that in patients with LSS, the epidural pressure at the level of the stenosis (i.e., at the level of the vertebral disc of the affected segment) increases substantially compared to the normal pressure in prone position. It can be speculated that in patients with a positive SedSign a further decrease of the CSA may not lead to a further increase in the epidural

pressure. According to histological studies [14], in the chronic state of an absolute stenosis, a further decrease in the diameter of nerve tissue is caused by demyelination and a decrease of soft tissue. These changes have been attributed to ischaemia of the nerve roots when being compressed by osseous, ligamentous or discal structures [27, 28], which is also proposed as a potential mechanism for the symptoms of LSS. Yet, it remains unclear how mechanical compression causes ischemia of the nerve roots.

This study has several limitations. Its sample size is small, but it sufficed to prove the feasibility of intraoperative epidural pressure measurement. A larger number of patients could not have been justified at this proof-of-concept stage. Other limitations are the measurement of epidural pressure in prone position and the anaesthesia-related balanced blood pressure. A prone position is not conforming to real life situations with changing positions and associated changes in hydrostatic and blood pressure. The CSA of the dural sac in prone position with positioning cushion is unknown; it may be considerably different from the CSA measure in the MRI in supine position. Finally, this study does not allow us to draw a final conclusion about the underlying mechanism responsible for the Sed-Sign, which will require comparator group of patients with LSS and a negative Sign.

Further research is warranted (1) to examine the correlation between an increased epidural pressure and the level of LSS, (2) to study the relationship between epi- and intradural pressures, (3) to investigate whether the clinical symptoms caused by mechanical compression are mediated through nerve root ischemia, (4) to explore if the measurement of epidural pressure or pressure curve may be useful tools in monitoring decompression intraoperatively, and (5) to compare the epidural pressure in LSS patients with a positive and a negative SedSign to confirm the proposed mechanism of the Sign.

To conclude, in LSS patients with a positive SedSign epidural pressure is increased at the level of stenosis, and there is no breath and pulse-synchronous wave below the stenosis. A positive SedSign could possibly be explained by increased pressure on lumbar nerve roots resulting in a tethering of the nerve roots that inhibits the sedimentation of the nerve roots in the cerebrospinal fluid.

Conflict of interest No conflicts of interest disclosed.

References

- Verbiest H (1954) A radicular syndrome from developmental narrowing of the lumbar vertebral canal. *J Bone Joint Surg Br* 36-B:230–237
- Amundsen T, Weber H, Lilleas F, Nordal HJ, Abdelnoor M, Magnaes B (1995) Lumbar spinal stenosis. Clinical and radiologic features. *Spine* 20:1178–1186
- Barz T, Melloh M, Staub L, Roeder C, Lange J, Smiszek FG, Theis JC, Merk HR (2008) The diagnostic value of a treadmill test in predicting lumbar spinal stenosis. *Eur Spine J* 17:686–690
- Chiodo A, Haig AJ, Yamakawa KS, Quint D, Tong H, Choksi VR (2008) Magnetic resonance imaging vs. electrodiagnostic root compromise in lumbar spinal stenosis: a masked controlled study. *Am J Phys Med Rehabil* 87:789–797
- Kanno H, Ozawa H, Koizumi Y, Morozumi N, Aizawa T, Kusakabe T, Ishii Y, Itoi E (2012) Dynamic change of dural sac cross-sectional area in axial loaded magnetic resonance imaging correlates with the severity of clinical symptoms in patients with lumbar spinal canal stenosis. *Spine* 37:207–213
- Konno S, Hayashino Y, Fukuhara S, Kikuchi S, Kaneda K, Seichi A, Chiba K, Satomi K, Nagata K, Kawai S (2007) Development of a clinical diagnosis support tool to identify patients with lumbar spinal stenosis. *Eur Spine J* 16:1951–1957
- Sirvanci M, Bhatia M, Ganiyusufoglu KA, Duran C, Tezer M, Ozturk C, Aydogan M, Hamzaoglu A (2008) Degenerative lumbar spinal stenosis: correlation with Oswestry disability index and MR imaging. *Eur Spine J* 17:679–685
- Sigmundsson FG, Kang XP, Jonsson B, Stromqvist B (2011) Correlation between disability and MRI findings in lumbar spinal stenosis: a prospective study of 109 patients operated on by decompression. *Acta Orthop* 82:204–210
- Schulte TL, Schubert T, Winter C, Brandes M, Hackenberg L, Wassmann H, Liem D, Rosenbaum D, Bullmann V (2010) Step activity monitoring in lumbar stenosis patients undergoing decompressive surgery. *Eur Spine J* 19:1855–1864
- Barz T, Melloh M, Staub LP, Lord SJ, Lange J, Roder CP, Theis JC, Merk HR (2010) Nerve root sedimentation sign: evaluation of a new radiological sign in lumbar spinal stenosis. *Spine* 35:892–897
- Rydevik BL, Myers RR, Powell HC (1989) Pressure increase in the dorsal root ganglion following mechanical compression. Closed compartment syndrome in nerve roots. *Spine* 14:574–576
- Yabuki S, Kikuchi S, Olmarker K, Myers RR (1998) Acute effects of nucleus pulposus on blood flow and endoneurial fluid pressure in rat dorsal root ganglia. *Spine* 23:2517–2523
- Olmarker K, Holm S, Rosenqvist AL, Rydevik B (1991) Experimental nerve root compression. A model of acute, graded compression of the porcine cauda equina and an analysis of neural and vascular anatomy. *Spine* 16:61–69
- Sekiguchi M, Kikuchi S, Myers RR (2004) Experimental spinal stenosis: relationship between degree of cauda equina compression, neuropathology, and pain. *Spine* 29:1105–1111
- Kobayashi S, Baba H, Takeno K, Shimada S, Kubota M, Yayama T, Miyazaki T, Uchida K, Suzuki Y (2009) Blood flow analysis of compressed nerve root after intravenous injection of lipoprostaglandin E1. *J Orthop Res* 27:1252–1257
- Alperin N, Hushek SG, Lee SH, Sivaramakrishnan A, Lichtor T (2005) MRI study of cerebral blood flow and CSF flow dynamics in an upright posture: the effect of posture on the intracranial compliance and pressure. *Act Neurochir Suppl* 95:177–181
- Chopp M, Portnoy HD (1980) Systems analysis of intracranial pressure. Comparison with volume–pressure test and CSF-pulse amplitude analysis. *J Neurosurg* 53:516–527
- Coffey RJ, Miesel K, Billstrom T (2010) Cerebrospinal fluid pressure measurement in the ovine intrathecal space: a preliminary study towards the diagnosis of intrathecal drug administration catheter dislodgement or occlusion. *Stereotact Funct Neurosurg* 88:337–344

19. Fujioka S, Kaku M, Hamada J, Yokota A, Ushio Y (1989) The usefulness of lumbar epidural pressure as an index of intracranial pressure. *Neurol Med Chir (Tokyo)* 29:484–489
20. Gaab MR (1984) Intracranial pressure recording. Principles, techniques, results and possibilities. *Fortschr Med* 102:957–962 MMW
21. Lee RR, Abraham RA, Quinn CB (2001) Dynamic physiologic changes in lumbar CSF volume quantitatively measured by three-dimensional fast spin-echo MRI. *Spine* 26:1172–1178
22. Packer RA, Simmons JP, Davis NM, Constable PD (2011) Evaluation of an acute focal epidural mass model to characterize the intracranial pressure-volume relationship in healthy Beagles. *Am J Vet Res* 72:103–108
23. Shah JL (1981) Influence of cerebrospinal fluid on epidural pressure. *Anaesthesia* 36:627–631
24. Min JH, Jang JS, Lee SH (2008) Clinical significance of redundant nerve roots of the cauda equina in lumbar spinal stenosis. *Clin Neurol Neurosurg* 110:14–18
25. Jackson A, Isherwood I (1994) Does degenerative disease of the lumbar spine cause arachnoiditis? A magnetic resonance study and review of the literature. *Br J Radiol* 67:840–847
26. Laitt R, Jackson A, Isherwood I (1996) Patterns of chronic adhesive arachnoiditis following Myodil myelography: the significance of spinal canal stenosis and previous surgery. *Br J Radiol* 69:693–698
27. Hida S, Naito M, Kubo M (2003) Intraoperative measurements of nerve root blood flow during discectomy for lumbar disc herniation. *Spine* 28:85–90
28. Kobayashi S, Uchida K, Takeno K, Baba H, Suzuki Y, Hayakawa K, Yoshizawa H (2006) Imaging of cauda equina edema in lumbar canal stenosis by using gadolinium-enhanced MR imaging: experimental constriction injury. *Am J Neuroradiol* 27:346–353