

**USING OF MODERN METHODS OF  
DIAGNOSTICS IN THE PRACTICE OF  
ORAL SURGERY**

**Text book**

Poltava – 2018

МІНІСТЕРСТВО ОХОРОНИ ЗДОРОВ'Я УКРАЇНИ  
УКРАЇНСЬКА МЕДИЧНА СТОМАТОЛОГІЧНА АКАДЕМІЯ

АВЕТІКОВ Д.С., СКИКЕВИЧ М.Г., ЛОКЕС К.П.,  
БОЙЧЕНКО О.М.

AVETIKOV D.S., SKIKEVICH M.G., LOKES K.P.,  
VOJCHENKO O.M.

**USING OF MODERN METHODS OF  
DIAGNOSTICS IN THE PRACTICE OF ORAL  
SURGERY**

**ЗАСТОСУВАННЯ СУЧАСНИХ МЕТОДІВ  
ДІАГНОСТИКИ У ПРАКТИЦІ ОРАЛЬНОЇ  
ХІРУРГІЇ**

Навчальний посібник

Text-book

Полтава – 2018

Poltava – 2018

UDK 616.314-089-07

BBC 56.6

A 19

It is recommended by the Academic Council of the Ukrainian Medical Stomatological Academy as a textbook for English-speaking students of higher education institutions of the Ministry of Health of Ukraine (Protocol № 2, 17.10.2018).

#### **Writing Committee**

**D.S. Avetikov** – doctor of medical science, professor, chief of department of surgical stomatology and maxillo-facial surgery with plastic and reconstructive surgery of head and neck of the Ukrainian Medical Stomatological Academy.

**M.G. Skikevich** – candidate of medical science, associate professor of department of surgical stomatology and maxillo-facial surgery with plastic and reconstructive surgery of head and neck of the Ukrainian Medical Stomatological Academy

**K.P. Lokes** - candidate of medical science, associate professor of department of surgical stomatology and maxillo-facial surgery with plastic and reconstructive surgery of head and neck of the Ukrainian Medical Stomatological Academy

**O.M. Bojchenko** - candidate of medical science, assistant professor of department of therapeutic stomatology of the Ukrainian Medical Stomatological Academy

This publication describes the achievements of modern medicine as the methods of diagnostics for diseases of the maxillofacial area.

The cytological and histological studies, X-ray examination, computer and magnetic resonance imaging, arthroscopy, ultrasound and dermatoscopy are describes in present text-book. The text-book is illustrated by pictures of methods for investigation.

The text-book is intended for students of dental faculties of Higher Medical Schools, and can also be used for interns, clinical interns, stomatologists, family doctors and doctors of other specialties.

УДК 616.314-089-07

ББК 56.6

А 19

Рекондовано Вченою радою Української медичної стоматологічної академії як навчальний посібник для англomовних студентів Закладів вищої освіти МОЗ України (Протокол №2, від 17.10.2018 р.)

#### **Автори:**

**Д.С. Аветіков** – доктор медичних наук, професор, завідувач кафедри хірургічної стоматології та щелепно-лицевої хірургії з пластичною та реконструктивною хірургією голови та шиї Української медичної стоматологічної академії.

**М.Г. Скікевич** – кандидат медичних наук, доцент, доцент кафедри хірургічної стоматології та щелепно-лицевої хірургії з пластичною та реконструктивною хірургією голови та шиї Української медичної стоматологічної академії.

**К.П. Локес** – кандидат медичних наук, доцент, доцент кафедри хірургічної стоматології та щелепно-лицевої хірургії з пластичною та реконструктивною хірургією голови та шиї Української медичної стоматологічної академії.

**О.М. Бойченко** - кандидат медичних наук, асистент кафедри терапевтичної стоматології Української медичної стоматологічної академії.

У даному виданні висвітлені досягнення сучасної медицини, а саме методів діагностики захворювань щелепно-лицевої ділянки.

У навчальному посібнику представлені такі методи діагностики, як цитологічне та гістологічне дослідження, рентгенологічне дослідження, комп'ютерна та магніто-резонансна томографія, артроскопія, ультразвукове дослідження та дерматоскопія. Навчальний посібник містить ілюстровані зображення наведених методів обстеження.

Навчальний посібник призначений для студентів стоматологічних факультетів Закладів вищої медичної освіти англomовної форми навчання, також може використовуватися для лікарів-інтернів, клінічних ординаторів, стоматологів, сімейних лікарів та лікарів інших спеціальностей.

# CONTENT

INTRODUCTION

CYTOLOGICAL INVESTIGATION

BIOPSY

ELECTROMYOGRAPHY OF MASTICATORY AND FACIAL  
MUSCLES

APPLICABILITY OF PHOTODIAGNOSTIC BY DEVICE «UFL-122»

X-RAY INVESTIGATION

CT-SCAN

MRI SCAN

ULTRASOUND IMAGING

ARTHROSCOPY

DERMATOSCOPY

LITERATURE:

## INTRODUCTION

Lesions of the oral cavity and perioral areas must be identified and characterized so that specific therapy can lead to elimination of the lesion. When a lesion is discovered, several important, orderly steps should be undertaken to identify and characterize it. These steps include the health history, history of the specific lesion, clinical examination, radiographic examination, laboratory investigation, and, if indicated, surgical procedures to obtain a specimen for pathologic examination.

When the patient or dentist discovers a lesion, the dentist must be careful how this information is discussed with the patient. The words **lesion, tumor, growth, and biopsy** carry terrifying connotations to many patients. The empathetic dentist can spare patients from anxiety and frustration by carefully wording the discussion of the lesion. It behooves the dentist to remember and make the patient aware that the vast majority of lesions discovered in the oral and maxillofacial area are benign.

The doctor should master the technique of examination of dental patients and, first of all, the oral cavity and teeth. A full-scale examination of the patient allows us to establish not only the localization and nature of the pathological process, that is, to justify the diagnosis, but also to provide for the further course of the disease, its probable outcome. Based on the results of the examination of the patient, the physician chooses the tactics of treatment, establishes indications and contraindications to various therapeutic measures. Methods of research in clinical dentistry include interviewing a patient, examining (both external and oral cavity), examination of the oral cavity and teeth, as well as peri-mandibular soft tissues. It is generally accepted that the

questioning of the patient and the methods of objective examination, not related to the use of various laboratory and instrumental methods, are the main ones. These include survey, sounding, percussion, palpation. Methods based on the use of radiography, electrodontometry, laboratory and others are additional, since sometimes a diagnosis can be made without their use. With diseases of the mucous membrane and periodontal, special methods of examination and periodontal indices are used.

## **PRINCIPLES OF INVESTIGATION AND DIAGNOSIS**

Evaluation of dental status

Card for assessment of dental status.

The evaluation card for dental status for adults includes the following sections:

- survey identification information;
- general information;
- extraoral states;
- the state of the teeth (crown, root);
- condition of periodontal tissues;
- loss of epithelial attachment;
- Enamel fluorosis;
- tooth erosion;
- trauma to the tooth;
- damage to the oral mucosa;
- Presence of prostheses (fixed or removable);
- the need for emergency care and referral to specialists;

## **Clinical examination**

The oral cavity is part of the maxillofacial area, so doctors must register any visible pathology of the face, nose, cheeks or chin. The pathological state and its localization clearly is recorded.

Pathological condition:

- absence of signs of defeat;
- ulceration, wounds;
- erosion;
- cracks;
- cancer of the oral cavity;
- enlarged lymph nodes;
- any other lesions.

## **Localization of the pathological condition:**

- face;
- neck;
- nose;
- cheeks;
- chin;
- corners of the mouth;
- red lip rim;
- jaws.

Mucous and soft tissues in the cavity and around the mouth should be examined



### **System and execute in the following sequence:**

1. the mucous membrane of the lips (upper and lower);
2. The labial part of the folds and the mucous membrane of the cheeks (right and left);
3. tongue (dorsal and ventral surfaces, margins);
4. The bottom of the oral cavity;
5. firm palate and soft palate;
6. alveolar processes / gums (on the upper and lower jaws)

### **Principles of investigation and diagnosis**

- A detailed history.
- Clinical examination.

Extraoral.

Intraoral.

- Special investigations (as appropriate).

Radiography or other imaging techniques.

Biosy for histopathology (including immunofluorescence, immunocytochemistry, electron microscopy, molecular biological tests).

Specimen for microbial culture.

Haematological or biochemical tests.

## CYTOLOGICAL INVESTIGATION

**Cytological research** (Greek κύτος «cell» η λόγος — «study») is a study based on the investigation of the structure of cells, the cellular composition of organs, tissues, and body fluids in normal and pathological processes using a microscope. The diagnostic cytological study is similar to the histological examination of the biopsy material for the purpose (lifelong recognition of the pathological process), the methodological basis (morphological analysis), and the object of the study (components of pathological areas of the investigated organ and tissue), the methods of coloring the nucleus, cytoplasm and other cell components.

Cytology is the investigation of small samples of dispersed or dissociated cells and other tissue components devoid of natural tissue architecture. Cytological investigation provides a preliminary diagnostic impression and should not be regarded as providing a definitive diagnosis.

Correctly performed cytological examination provides the authenticity of the diagnosis in 78% - 90% of cases.

**Needle for aspiration histological and cytological biopsy.** The needle is removed from the sterile package. In the assembled form, the needle is inserted into the organ under investigation. After verifying that the distal end of the needle is in the required place, the plunger of the syringe is cocked. Vacuum causes aspiration.

Biopsy studies are often used method of modern diagnostics in medicine. This study was based on the lifetime taking of a biomaterial (tissue) in a patient for the purpose of microscopic examination.

The very process of research involves taking the material, fixing it securely, transporting it to the laboratory, where it is invariably processed,

then the slices are made and stained. And only after all these procedures you can proceed to a microscopic study, which will help to diagnose. Biopsy is advisable to conduct in the case when other methods in terms of diagnosis are little informative. In this case, a biopsy is necessarily prescribed for suspected malignant tumors.

### **Reasons for biopsy:**

Confirmation of the malignancy of the neoplasm;

Determination of tumor aggressiveness;

Determination of pathological processes in the organs of the digestive tract, lungs, retroperitoneal space, mammary gland, soft tissues, etc .

### **Is biopsy dangerous?**

Biopsy is a study that is conducted to collect and comprehensively study the structure of tissue cells. The procedure involves the collection of tissue fragments, partial or complete excision of the tumor. Due to the high level of soreness, a biopsy can be performed using anesthesia.

The study carries a risk to patients who have a disrupted blood coagulation function, can cause bleeding and, as a result, the loss of large amounts of blood. In order to avoid unfavorable consequences, doctors recommend several days before the procedure to stop taking drugs that suppress coagulation.

## **METHODS OF INVESTIGATION OF BIOLOGICAL MATERIAL IN BIOPPSIA**

There are two types of such methods:

**Cytological examination.** It involves the study of cells taken from a biopsy from the surface of the tumor. It is a technology of cytomorphological diagnostics, due to which the character of the neoplasm is determined (precancerous, malignant, reactive, benign, inflammatory). Preparation of the drug occurs as follows: the cut of the surgical material or biopsy touches the glass on which the imprint remains (a thin smear), it is stained and studied under a microscope.

**Histological examination.** It is carried out in a planned and urgent manner. Planned cell research with biopsy means placing the tissues in a special solution, and then - in paraffin, then perform slices and staining. Such a survey takes about a week's time. Urgent study of tissues is carried out by freezing tissues. A microtome (knife) is cut, and the staining is carried out by the doctor under a microscope. The duration of such diagnostics is up to 40 minutes. Usually, urgent research is used during the operation to determine its volume and the nature of the tumor.

**The research process includes several stages:**

- material intake;
- fixation;
- transportation to the laboratory with appropriate equipment;
- preprocessing the biopsy;
- preparation of sections (in the study of tissue fragment);
- coloring;
- microscopy;
- preparation of conclusion.

## **Biopsy happens:**

- Partial, when a piece of tissue from the center of education is taken for research. It is also called incisional biopsy.
- Total, in which the examined pathological focus is completely removed. This procedure is called excision biopsy. These two types of biopsies are used by surgeons in the process of interventions and they are performed exclusively in the operating room.

For a biopsy try to take a piece located on the border of pathologically altered and normal tissue. To do this, sometimes use the hardware control, for example, a biopsy is performed under the supervision of ultrasound scanning or mammography.

In spite of the fact that in most cases the biopsy is an invasive procedure, for the patient it passes painlessly, since anesthesia is used for its carrying out. As a rule, the study is conducted on an outpatient basis (exception - if the patient is in hospital at the time of the biopsy).

- **Excisional biopsy** - a fence for the study of pathological education entirely.
- **Injection biopsy** - a fence for the study of a part of pathological formation or diffusely altered organ.
- **Plucked biopsy** - using biopsy forceps (punch-biopsy)
- **Trepan-biopsy** - a fence of a column of dense tissue with the help of a hollow tube with a pointed edge - trephine. It is used for biopsy of bones and dense tumors.
- **Core (biopsy, core biopsy, cutting biopsy)** - taking a column of material from soft tissues with a special trephine consisting of a harpoon system and a hollow tube with a pointed edge.

- **Scarification** (surface) biopsy (shaving biopsy) - a material intake by cutting from the surface of the formation of a thin layer of tissue, is used for biopsy of pathological skin formations.
- **Loop biopsy** - the collection of material by a loop with the help of a coagulator in the mode of cutting tissues or a radio-frequency surgical apparatus. It is used in ENT, gynecology and endoscopy.
- **Fence material** for cytology
- **Imprint** with pathological formation (erosion, ulcers) - the material is transferred to the slide by applying it to the ulcerated surface.
- **Smear-imprint** from pathological education - the material is scraped off with pathological education with a spatula, a scalpel, and a cytocoque is then transferred to a slide.
- **Fine needle aspiration biopsy (FNAB)** - sampling of material for examination, usually using a needle and syringe. It is used both for biopsy of cystic formations and solid tumors.
- **Aspiration biopsy** is a variant of FNAB fluid formations: cysts, fluid intake from the pleural or abdominal cavity.

**By type of accuracy control:**

- Classical biopsy
- Aimed biopsy
- Endoscopic
- Biopsy under the supervision of ultrasound
- Biopsy under X-ray control
- Stereotactic biopsy

For a biopsy try to take a piece located on the border of pathologically altered and normal tissue. To do this, sometimes use the hardware control, for example, a biopsy is performed under the supervision of ultrasound scanning or mammography.

By type of accuracy control:

- Classical biopsy
- Aimed biopsy
- Endoscopic
- Biopsy under the supervision of ultrasound
- Biopsy under X-ray control
- Stereotactic biopsy

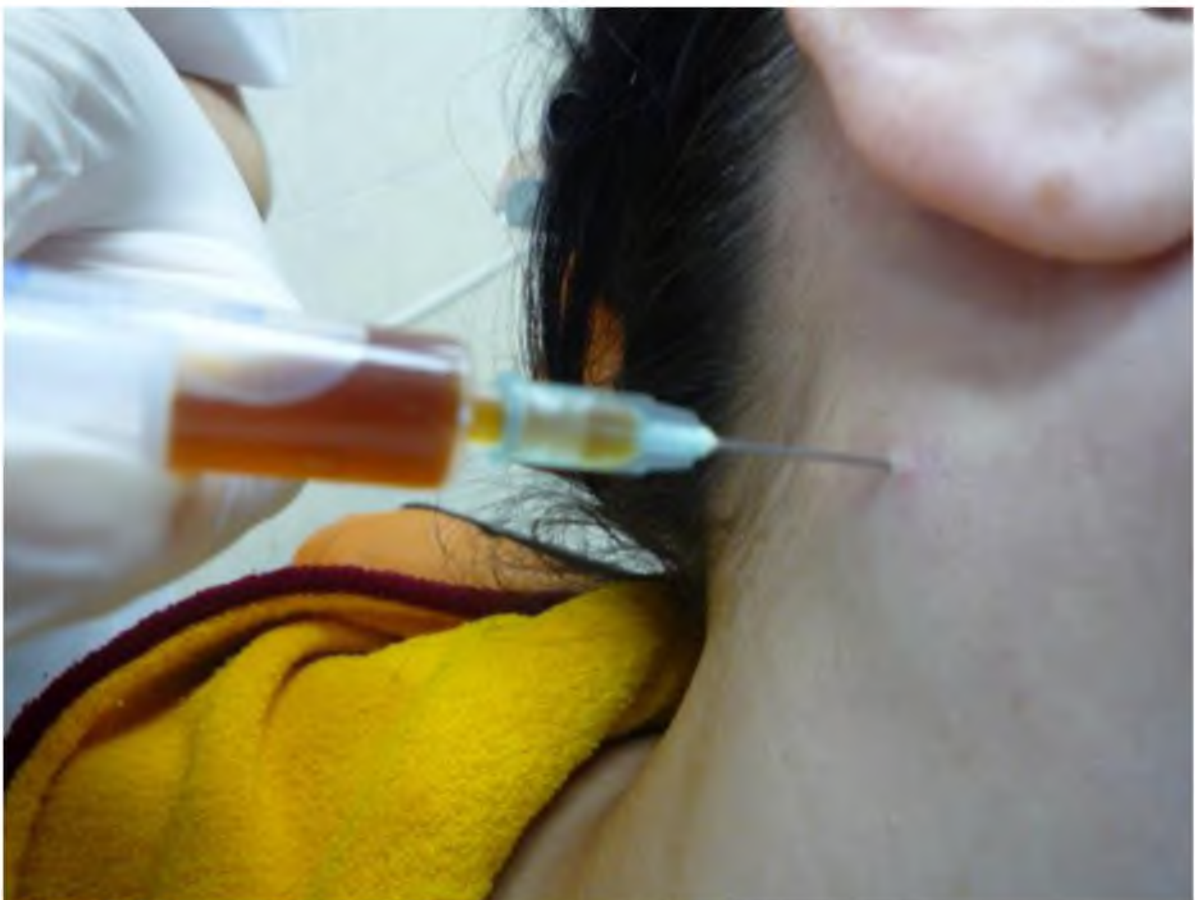

Fig. 1. Fine needle aspiration at lateral neck cyst

Clinical diagnosis and performed treatment should be specified. Material samples for cytological investigation should be delivered immediately after receiving it from the patient.

Compared with tissue biopsy, a cytology specimen usually:

- Is easier to get;
- Causes less discomfort to the patient;
- Is less likely to result in serious complications;
- Costs less.

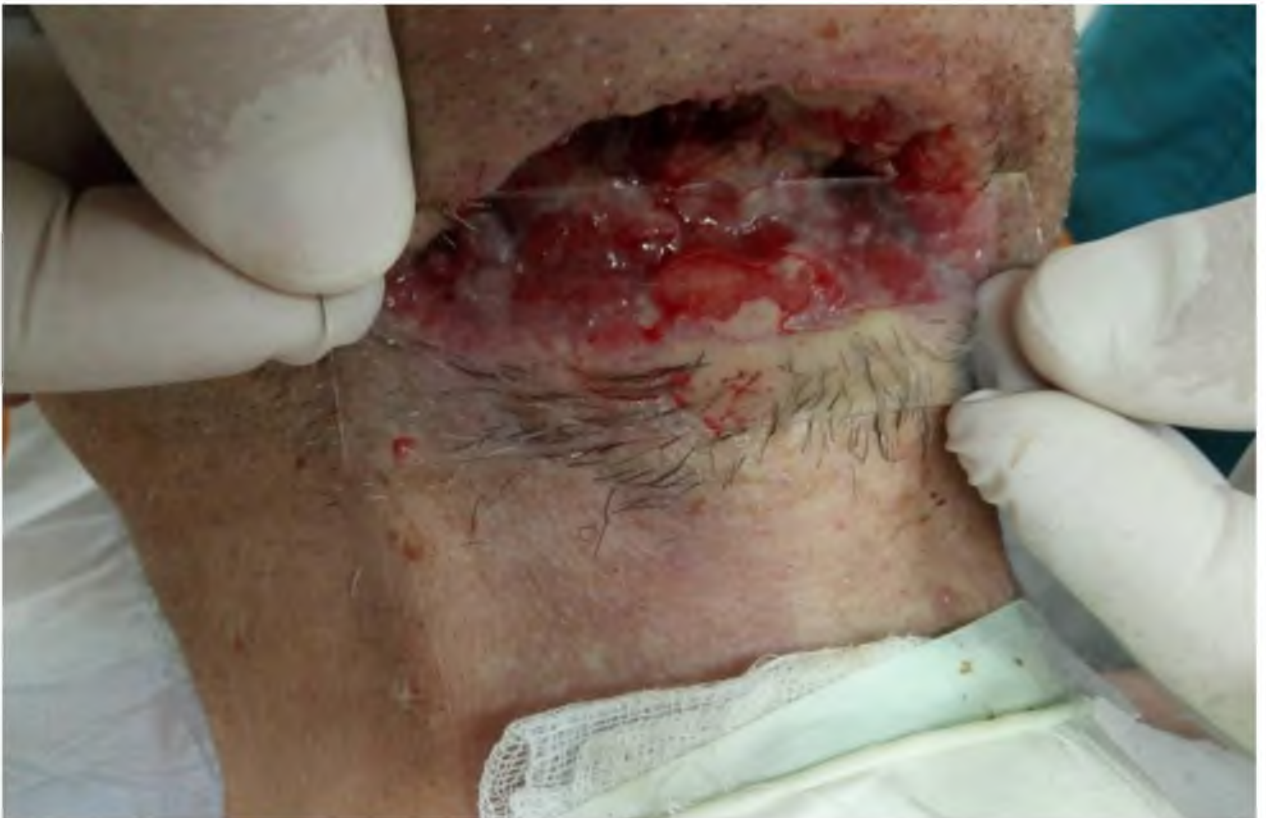

Fig. 2. The cytological investigation, the stamped smear of wound.



### **Indications for the cytological research:**

- Suspicion of the inflammatory process;
- Malignant tumors;
- Viral infection - to clarify the diagnosis;
- Confirmation of oncological diagnosis during surgical intervention (removal of tissues);
- Monitoring the dynamics of treatment of various diseases;
- Monitoring the results of therapy;
- Screening in preventive measures;
- Control over the condition with the probability of relapse (necessarily - after treatment of oncological diseases).

## **BIOPSY**

A biopsy is a medical procedure to remove a piece of tissue from body that is analysed in a histological laboratory. It is one of the most exact methods of investigation of tumors.

Biopsy makes it possible to diagnose such processes as benign and malignant tumors, inflammatory processes, hyperplastic formations. Biopsy is also needed to clarify the diagnosis and conduct already established differential diagnostics. Repeated biopsy allows to follow morphological dynamics of the pathological process under the influence on it treatments, evaluate the effectiveness of treatment.

During a biopsy, a doctor removes a sample of tissue or fluid from the body. A pathologist inspects the cells under a microscope to see if they are cancerous. If the cells are found to be cancerous, a biopsy may help determine whether the cancer began at the site of the biopsy or if it started somewhere else in the body and spread to the biopsy site.

Some biopsies are performed endoscopically, others under image guidance, such as ultrasound, computed tomography (CT) or magnetic resonance imaging (MRI) in the radiology suite. In some cases, biopsies are performed in the operating suite. This allows your doctor to collect tissue from deep inside the body.

Some sites that are commonly biopsied include the breast, skin, bone marrow, GI tract, lung, liver, bladder, colon and lymph nodes. Our doctors determine the method of biopsy based on several factors, such as the size, shape, location, and characteristics of the abnormality.

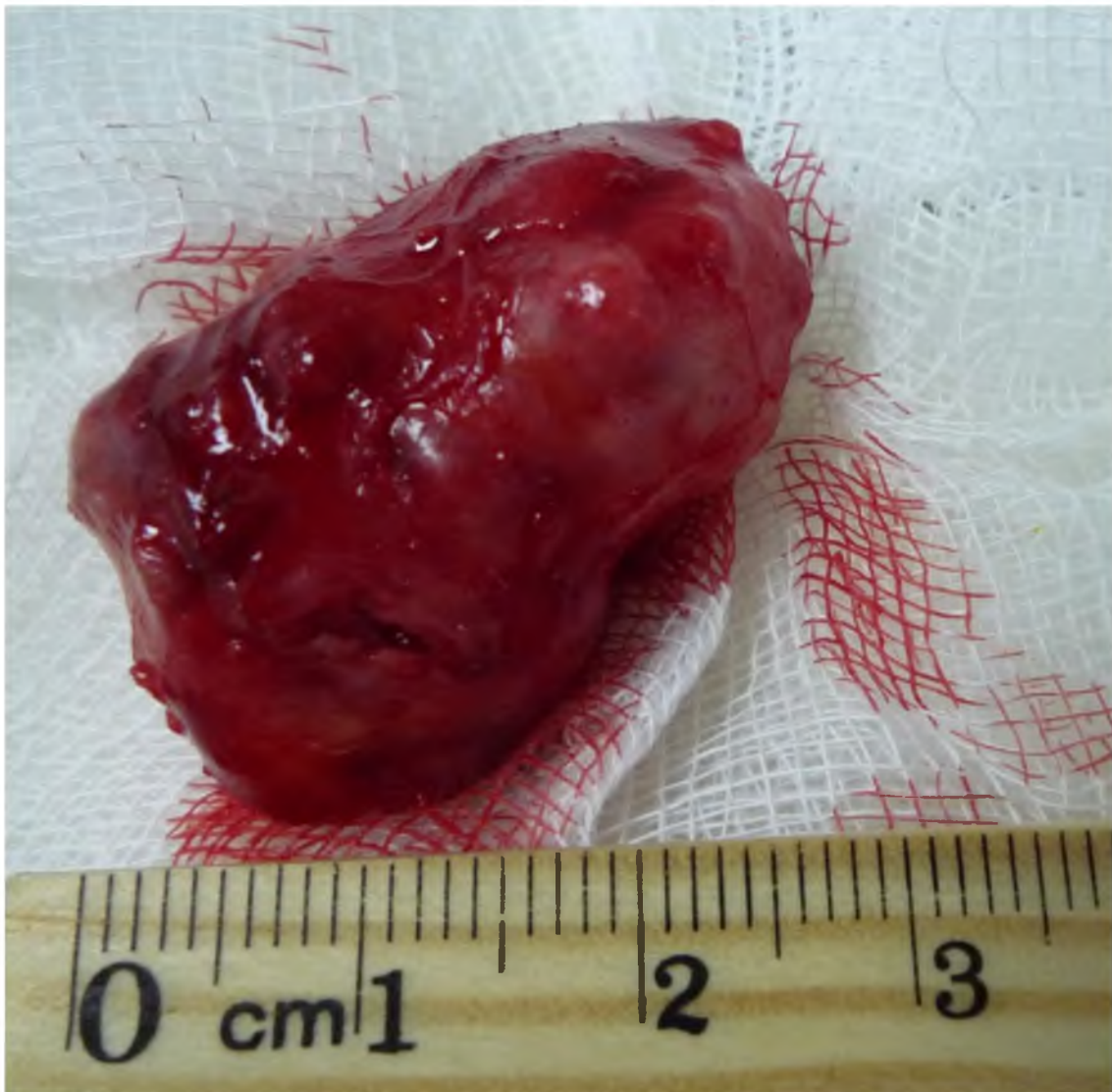

Fig. 3. The biopsy of pleomorphic adenoma of the parotid salivary gland.

There are several types of closed bone biopsies: aspiration biopsy, drill-biopsy and trepan-biopsy.

Aspiration bone biopsy is used mainly in osteosarcomas, chondrosarcomas, reticulosarcomas, giant cell tumors and chondromas. Some widely use a drill-biopsy of tumors and other destructive foci in the bones with the help of a special needle-drill. Trepan-biopsy of bone lesions of

predominantly tumor character by means of trephine-needles allows taking material of different consistency - from semi-liquid to solid - for research. Morphological examination is very important for clarifying the diagnosis of benign and malignant tumors, bone cysts, fibrotic dysplasia, tuberculosis, osteomyelitis, lymphogranulomatosis, eosinophilic granuloma. It is recommended that a bone biopsy be performed on the operating table. Under anesthesia, an appropriate incision is made, the tumor is exposed, a deep section of its tissues is taken and sent for an urgent laboratory examination. Having received the conclusion of the pathologist, the surgeon makes a decision about the further plan of the operation after comparing the clinical, radiological and histological data.

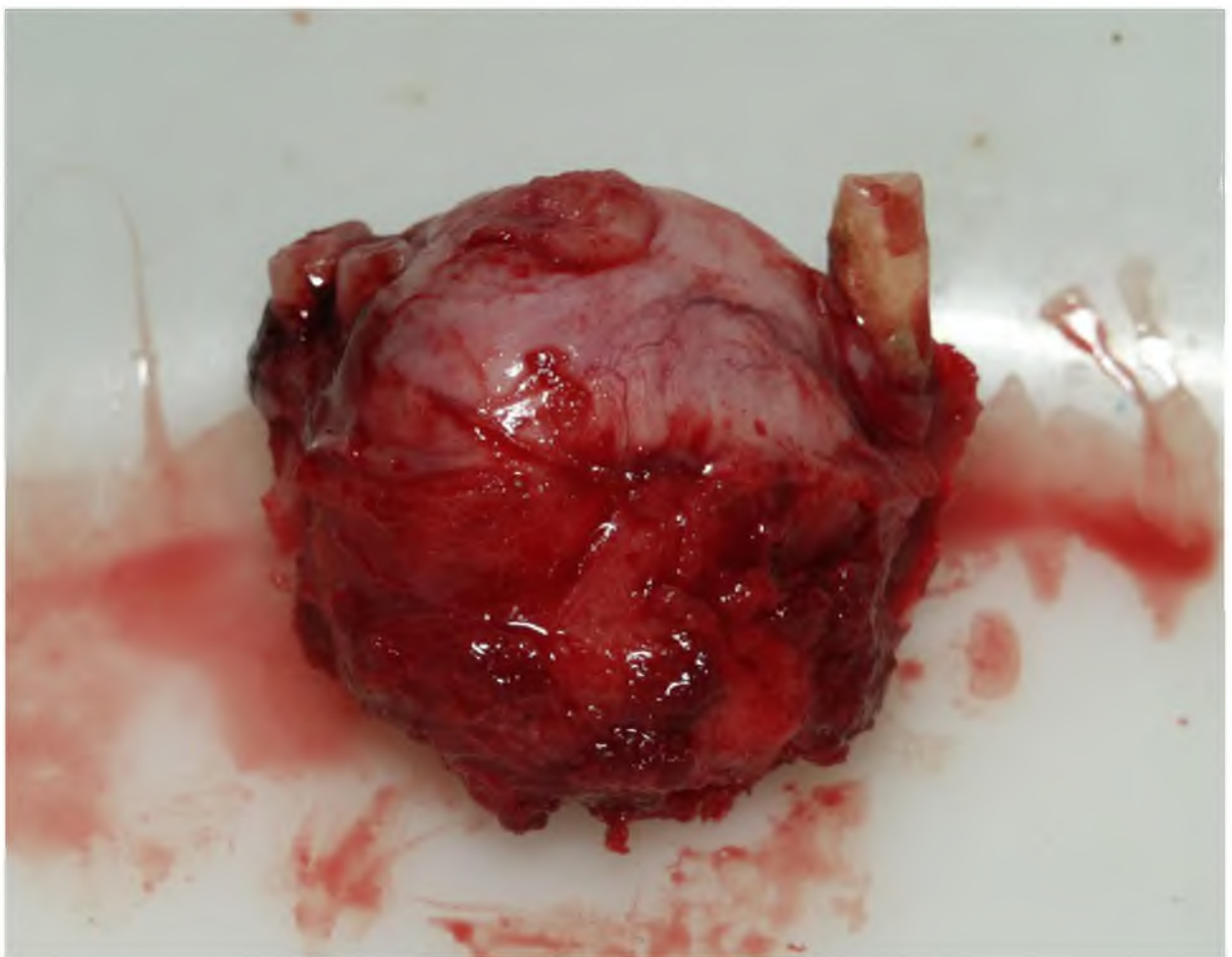

Fig. 4. The biopsy at the osteosarcoma of the mandible.

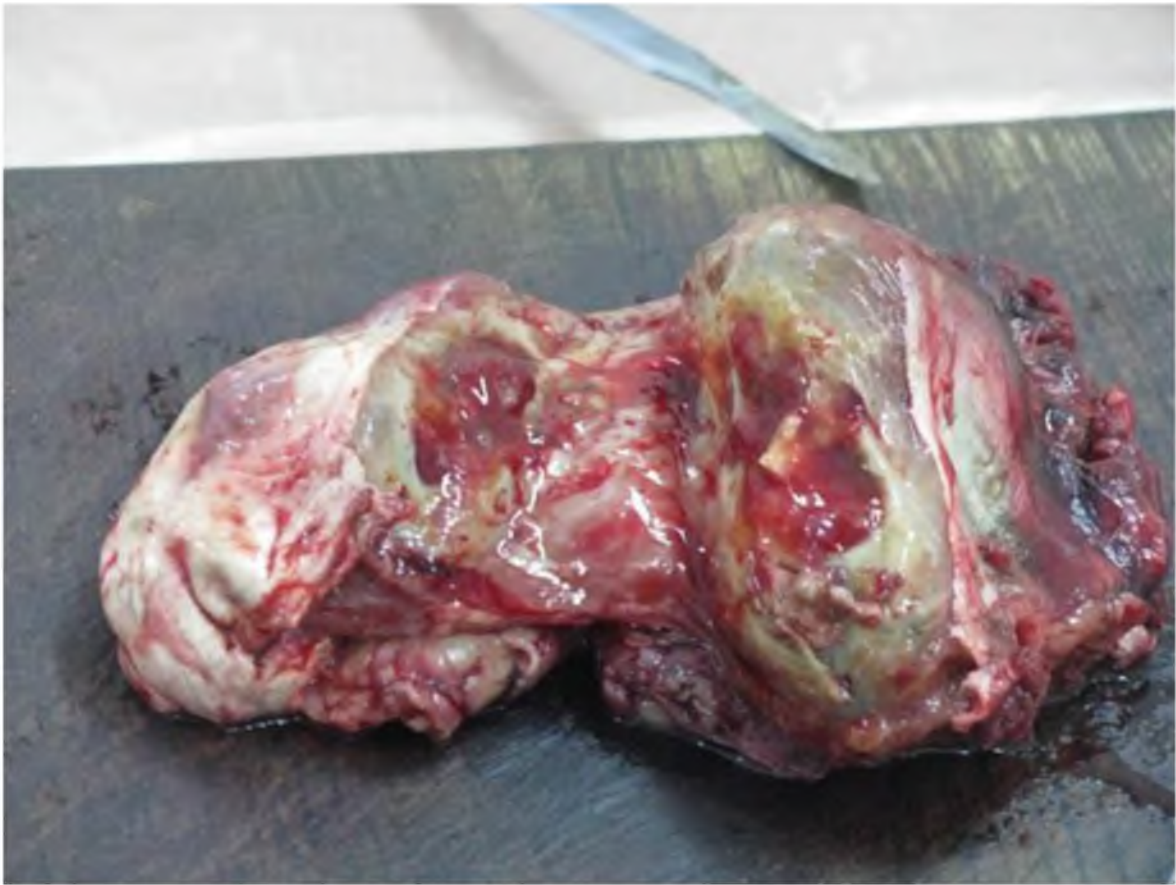

Fig. 5. The biopsy of lateral neck cyst.

Complications (the risk of biopsy). As this surgical procedure is associated with a violation of the integrity of the skin, doctors do not exclude the attachment of a secondary infection, followed by inflammation and suppuration. This is the most dangerous consequence for health, which can turn out even by infection of blood, exacerbation of other unpleasant diseases with periodic recurrence. So a temporary scar of different sizes at the site of a direct biopsy sampling is not the only aesthetic problem, potential complications that are no longer dangerous to health can be as follows: heavy bleeding at the fence site; acute pain syndrome in the diagnostic area; internal discomfort after the end of the session; inflammatory process with a high body temperature; trauma of the organ under investigation (especially if using

a biopsy forceps); infection of the organ under investigation; septic shock; blood poisoning; suppuration at the site of the puncture; the spread of a bacterial infection with a fatal outcome.

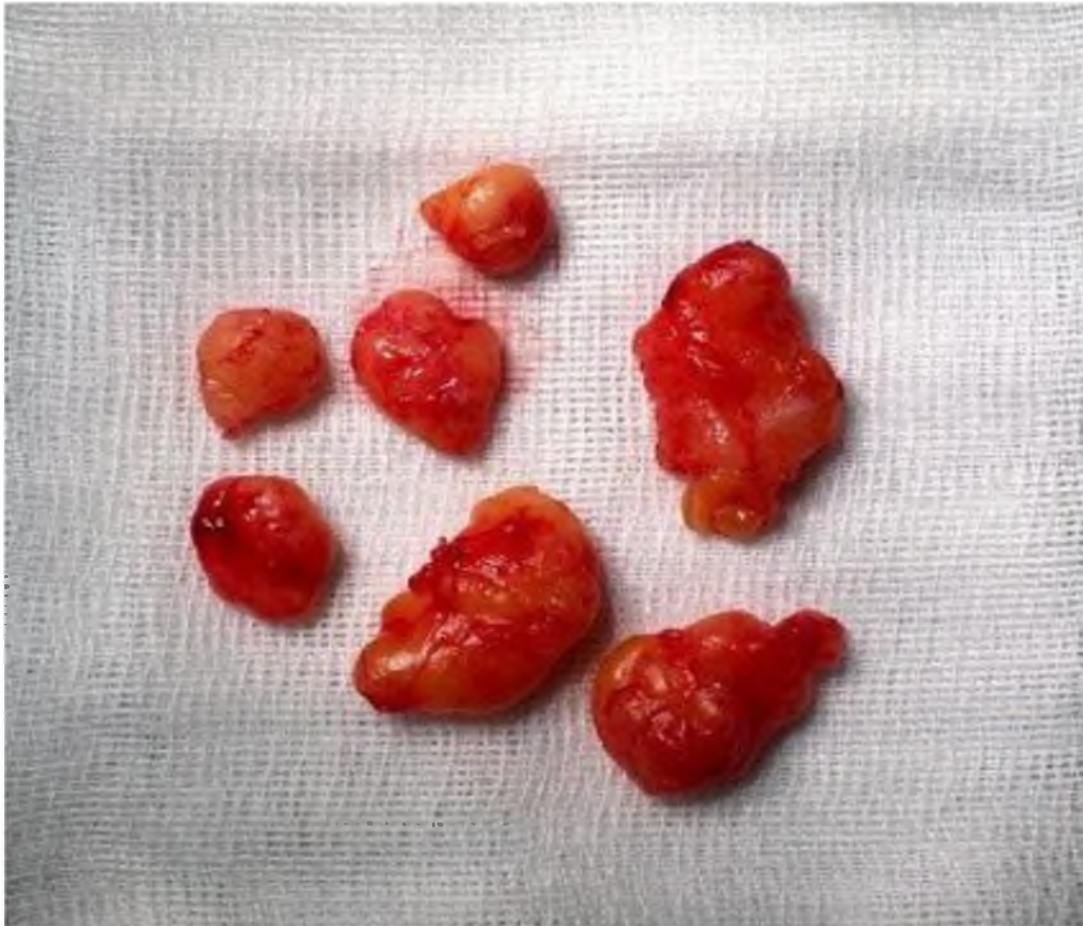

Fig. 6. The biopsy of lipoma.

**Complications of biopsy:**

- Bleeding
- Infection

- Accidental injury to adjacent structures such as the bowel during abdominal biopsy or lung parenchyma during renal biopsy

### **Contraindications**

Biopsy is not allowed to all patients according to indications, there are absolute and relative medical restrictions that it is important not to violate. Medical contraindications affect such clinical patterns: a clotting disorder; periods of pregnancy and lactation; diseases of the reproductive system; inflammatory and infectious processes of acute stage; systemic, somatic diseases; high threshold of pain sensitivity; after extensive blood loss.

## **ELECTROMYOGRAPHY OF MASTICATORY AND FACIAL MUSCLES**

Electromyography is a functional and diagnostic method for investigation of the functions of the peripheral neuromotor apparatus and evaluation of the coordination of the maxillofacial muscles in time and in intensity, in norm and in pathology.

Three methods of electromyographic studies are used:

- global EMG (interference) registers the bioelectrical activity of a large area of muscle, the entire muscle or a group of muscles located near the recording electrodes, with the use of large electrodes overlaid on the skin (more than 1 mm<sup>2</sup>);
- local EMG - registration with needle electrodes;
- stimulating EMG - study of motor response of the muscle (M-response), caused by stimulation of the motor nerve that innervates this muscle.

Interference EMG is used to study the bioelectric activity of masticatory and facial muscles. With the help of global EMG, it is possible to establish only the fact of asymmetry, but not its cause. Local EMG is used to detect denervation activity in motor nerve injuries, signs of beginning reinnervation (appearance of action potentials when attempting arbitrary



reduction) and to determine the nature (neurogenic or myogenic) of muscle function disorders.

Stimulation EMG is necessary at damages of the facial nerve to determine its conductivity and the rate of propagation of excitation along it, as well as quantify the degree of paresis of nerve's branches and the corresponding muscles. A global EMG is also used to determine the degree of paresis of mimic muscles.

The oscillations of the biopotentials found in the muscle with any form of motor reaction are one of the most accurate indicators of the functional state of the muscle.

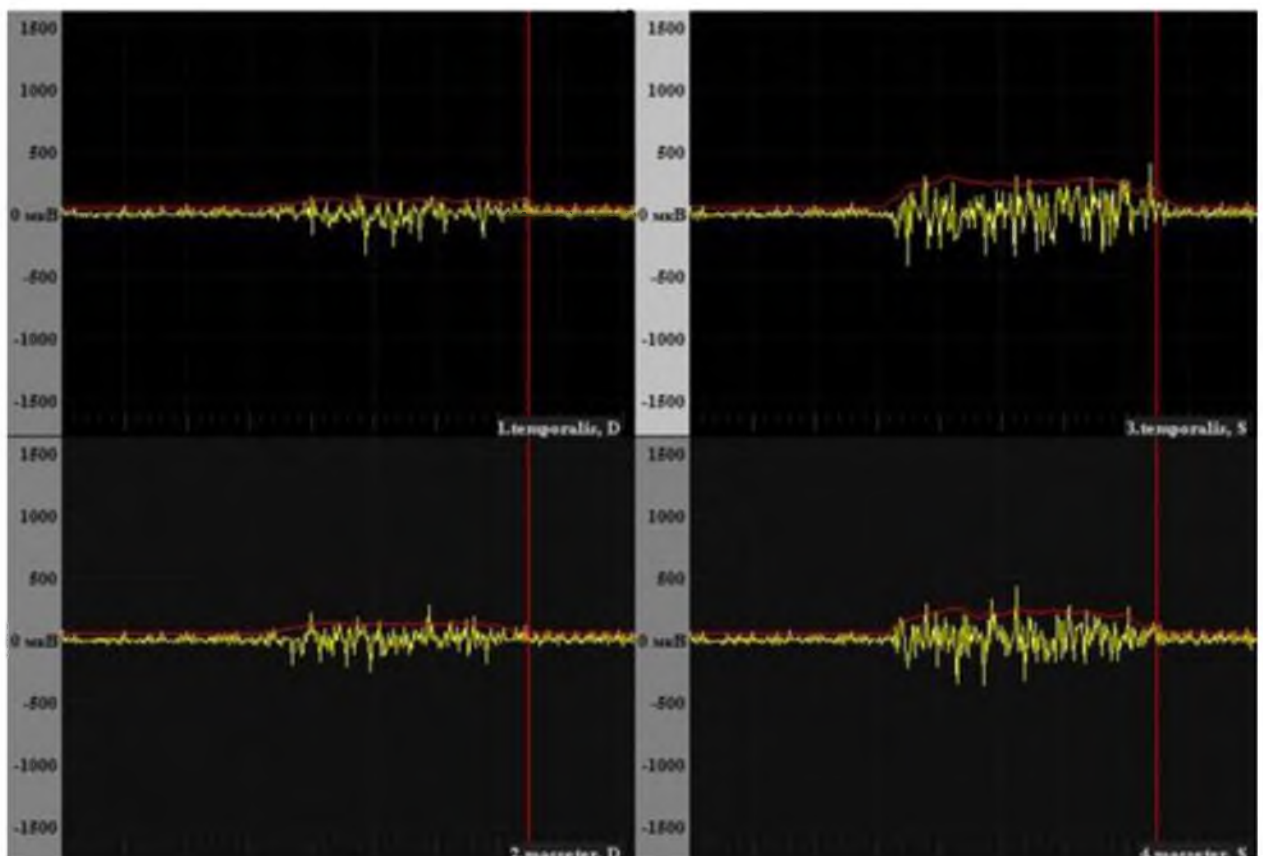


Fig. 7. The EMG of temporal and masseter muscles at brucism.

Electromyography of masticatory muscles is based on the registration of biopotentials of the action of muscle fibers functioning as a part of motor units. Before studying the bioelectrical activity of the masticatory muscles, it is necessary to clearly understand the structure of the motor unit. The motor unit consists of motor neuron and a group of muscle fibers innervated by this motoneuron. The number of muscle fibers innervated by one motoneuron is not the same in different muscles.

In chewing muscles, one motor neuron has about 100 muscle fibers, in the temporal muscle - up to 200, in the mimic muscles motor units are smaller, they include up to 20 muscle fibers. In small mimic muscles, this ratio is even smaller, which provides a high level of differentiation of contractions of facial muscles, which determine a wide range of facial expressions.

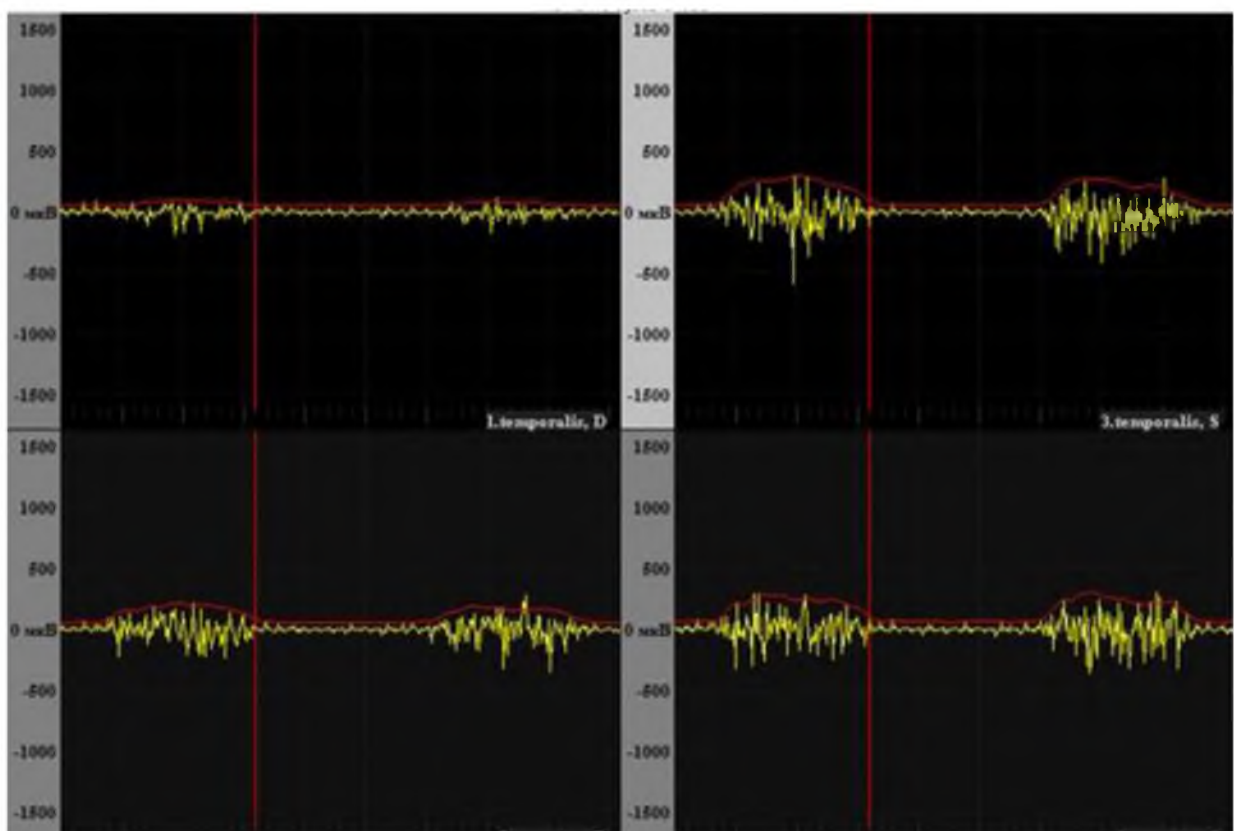


Fig. 8. The EMG of temporal and masseter muscles at TMJ disfunction.

The study of masticatory muscles, both in norm and in the pathology of occlusion, has a particular interest, since the functional state of the masticatory muscles is an indicator of occlusive disorders in the dentoalveolar system.

The main advantages of surface electromyography as a method of functional research are: minimally invasive, accessible, the possibility of qualitative registration of the study in the form of tables and diagrams, which is an important licit document of the protocol of orthodontic treatment and allows comparative analysis of the studied muscles in all parameters in the dynamics of orthodontic treatment.

The increased electrical activity of the masticatory muscles indicates the presence of muscle dysfunction in patients with a permanent bite, which is combined with violations of occlusion.

The amplitude of muscle contraction is equivalent to the muscle strength characteristic. Analyzing the duration of bioelectrical activity and bioelectric rest in muscle relaxation, we can directly conclude about the processes of excitation and inhibition, and, consequently, the endurance of muscle fibers.

Interspecific differences in chewing muscles are significant, which is already revealed with a superficial assessment of the volume of the masseter and temporal muscles. According to the regularity, the more pronounced the anterior and lateral components of the chewing movements, the greater the amount of chewing muscles.

Coordination of contractions of the basic and auxiliary masticatory muscles is regulated reflexively. The degree of chewing pressure on the teeth is controlled by the proprioceptive sensitivity of the periodontium. The

strength of the muscles is directed dorsally, therefore the greatest efforts of the chewing muscles are able to develop in the most distal sections of the dentition.

## FUNCTIONAL TESTS IN ELECTROMYOGRAPHY

The various functional tests are used to determine the coordination of the function of the muscles of the maxillofacial area, violations of their innervation. As the functional samples in electromyography, various natural actions are used, in which the muscles under study are involved, as well as external influences that cause reflex reactions of these muscles.

**The maximum muscle tension** is used for global and local electromyography. The patient is asked to make the maximum tension of the muscles studied: for chewing - the compression of the teeth with maximum force, for the circular eye muscle - the maximum closures of the eyes, for the frontal muscle - the maximum raising of the eyebrows, etc.

**Weak muscle contraction** is used to study the parameters of individual functional units in local electromyography. The contraction should be so weak that the potentials of the action of the individual functional units can be distinguished on the EMG and their interference (imposition) does not occur.

**Chewing load** is used to determine the functional state of the masticatory muscles, a functional test that is dosed and objectively recorded with the help of spring gnathodynamometers provides an adequate physiological load.

The patient is offered to repeatedly grind the gnathodynamometer bite areas by teeth for 1 minute. The maximum force produced during pressing on the nibbling areas and being the force of maximum compression is measured (in kg) on the scale of the gnathodynamometer. Simultaneously, the EMG is recorded. Reducing the compressive force of the bite areas to a weak muscle contraction is produced under the control of the readings of the gnathodynamometer scale. Evaluation of the efficacy of a prognostic course of treatment or examination of patients during the rehabilitation period is carried out at the registration of the EMG according to the initial indices of the gnathodynamometer scale and repeated measurement of the maximum gain (in kg).

**Natural movements.** These movements are reproduced in such a way that the studied muscles participate in them; for masticatory and some facial muscles, it is chewing the standard amount of bread, nut, chewing gum, swallowing saliva, water or other liquid, sagittal and lateral movements of the lower jaw; for the facial mimic muscles, the utterance of special sounds.

**Consensual movements of facial muscles.** To detect the abnormalities in muscle function at neuritis of the facial nerve, the activity of the facial nerve is examined in movements that are uncharacteristic for these muscles, for example, the circular eye muscle when stretching the lips into the tube or pulling the corners of the mouth downward, the circular muscles of the mouth - when eyes are screwed up or eyebrows lifted.

**Tapping the chin with a hammer.** A special sample for the study of reflex reactions of the chewing musculature, used for diseases of the temporomandibular joint. With the jaws closed, a reflex inhibition of muscle activity occurs in the masticatory musculature; the duration of this inhibition is of diagnostic significance. When the lower jaw is freely lowered, the

myotactic reflex (analogous to the tendon reflexes of the extremities) appears in the masticatory musculature, whose amplitude is related to the sensitivity of the muscular spindles (receptors).

**Electrical stimulation of the trunk of the facial nerve.** This functional sample is reproduced by stimulation electromyography.

Electromyography as one of the main methods of functional research makes it possible to study the coordination of work of antagonist muscles and synergists before, during and during the retention period of orthodontic treatment. In addition, comparative electromyography allows to establish the side and type of chewing in a particular patient.

The results of surface electromyography as a method of functional research serve as an objective indicator of the functional state of the masticatory muscles.

## **APPLICABILITY OF PHOTODIAGNOSTIC BY DEVICE «UFL-122»**

Significant differences in the nature of absorption of benign and malignant tissues, taken at different levels, are not revealed. More light absorption is determined in the wavelength range 550-650 nm, which corresponds to the yellow-green to the red color. With increasing thickness of the ball, the optical density of the substance of both types of tissues increases linearly. As the wavelength decreases, the optical density increases more rapidly with the increase in the sphere of tissues. The introduction of "Solcoseryl" somewhat reduces the absorption of light by the upper balls of tissues. Red light is more permeable, therefore for conducting phototherapy red and orange light of the device "UFL-122" can be used.

The spectra of light radiation of multifunctional machine «UFL-122» (firm Lux-dent, Kyiv) is studied in this work. The ability to use light sources «UFL-122» for phototherapy with Solcoseryl (gel) of precancerous lesions of the oral mucosa and lips (erosion, fissures, ulcers, prolonged healing) is proved. The absorption capacity of the gel Solcoseryl and its optical density are studied.

With the advent of lasers which give a strong, coherent monochromatic, polarized light, began the development and implementation of a variety of optical methods in medical practice. The good therapeutic effect can be obtained by quasi-monochromatic light.

Phototherapy is based on photo-biological processes. One of its variants is photodynamic therapy (PDT). Antimicrobial PDT is effectively used for the treatment of infectious inflammation of periodontal tissues, and root canals, periodontal pockets, the periimplantitis, deep caries.

This seems to be an easy, safe and noninvasive system capable of helping the dentist to better visualize lesions, as well as its edges. Another point to consider is that the lesion seems to be bigger under chemiluminescence light. One disadvantage is that this system is expensive and a stick is used for each patient. Furthermore, chemiluminescence light seems to be nonspecific as it does not identify the lesion etiology — whether inflammatory, neoplastic benign, or neoplastic malign — and this could lead to unnecessary biopsies

For achievement of desired therapeutic effect during using of phototherapy methods it should be pick up the light of a certain wavelength and ensure its access to tissues that require therapeutic intervention. It is important to know the effective of wavelength at which maximum system absorbs light energy and as a result generates free radicals, which in turn affects the chemical reactions and biological processes.



Fig. 9. Quasilaser «UFL-122»



The light absorption has the important role in a diagnostic. The positive effect will be better with more absorption of light energy, but on the other hand less light will penetrate to the tissues located deeper, which will reduce the therapeutic effect.

In absorption colorimetric it is exercised transmittance measurement  $\tau$  ( $\tau = \frac{I}{I_0}$ , where  $I$  - the intensity of the light that has passed through the object,  $I_0$  - the intensity of the incident parallel beam) and the optical density of the medium  $D$  ( $D = \lg \frac{1}{\tau}$ ) a narrow range of wavelengths of light.

The basis is colorimetric analysis by Bouguer - Lambert - Beer, whereby the intensity of the beam at the output layer of the substance is given by:

$$I = I_0 e^{-k_\lambda h},$$

where  $h$  - the thickness of the material;  $k_\lambda$  - Absorption coefficient, which depends on the wavelength of the incident light, the chemical nature and state of matter, but depends on its intensity.

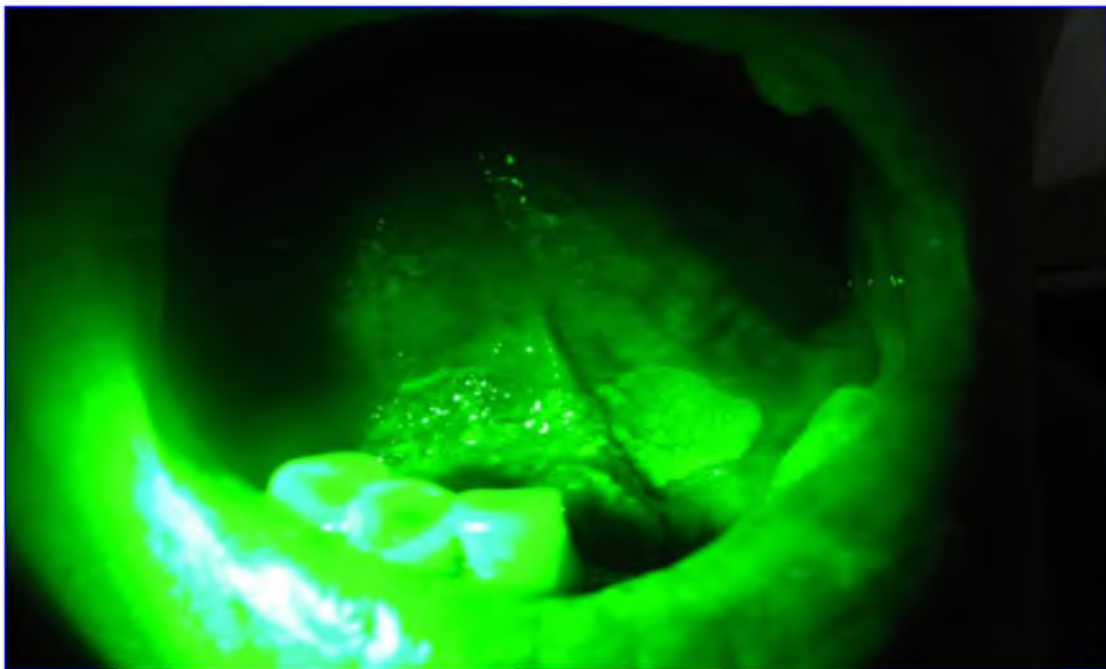


Fig. 10. Leukoplakia plana of mucose membrane of oral floor. Diagnostic by quasilaser «UFL-122», green color.

In dental clinics the device «UFL-122» is used, the source light flux which has a quartz-halogen lamp Philips (13164) power 200W. System of interference filters makes it possible to provide the necessary range of areas and absorb most other components, including ultraviolet and infrared. It provides optical radiation in five different spectral bands of the visible area of the spectrum. Analysis of the radiation spectrum shows that the maximum for UF filter corresponds to  $\lambda = 487_{nm}$  for G - G -  $\lambda = 567_{nm}$ , for R -  $\lambda = 602_{nm}$ .

The intensity or flux of density at the output of the fiber may lie within 50 - 300 mW/cm<sup>2</sup> - for red and 100–1300 mW/cm<sup>2</sup> - to orange light.

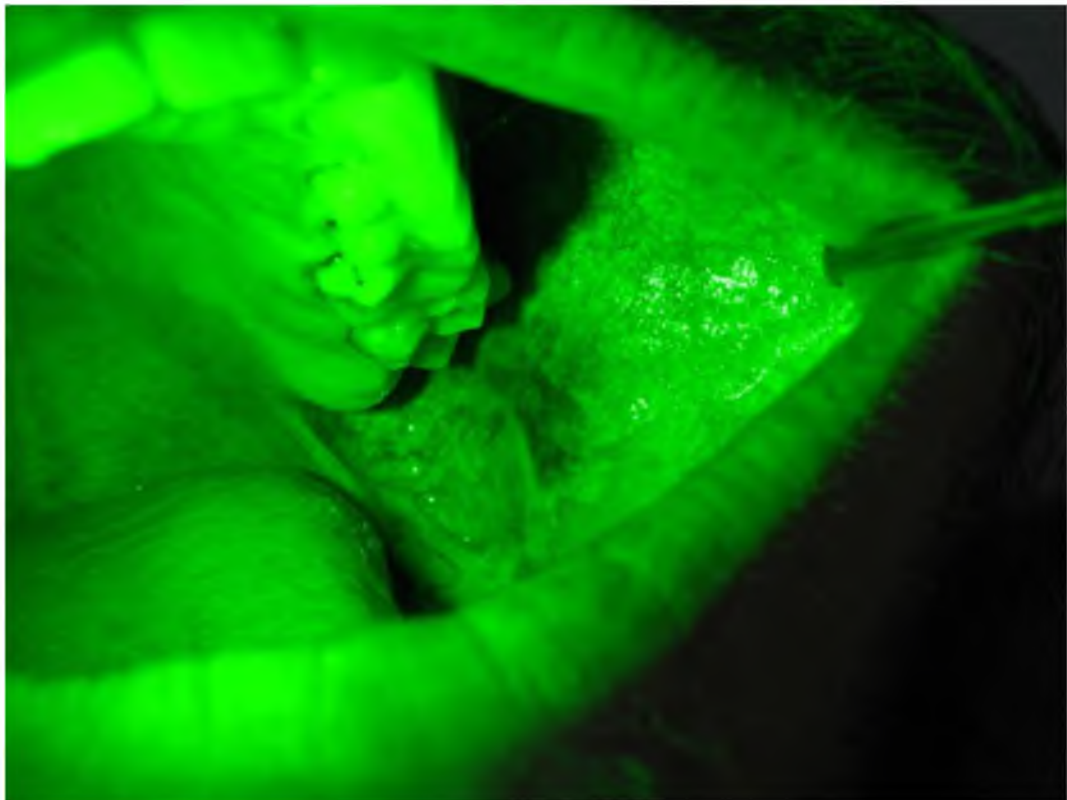


Fig. 11. Erosive-ulcerative forms of lichen ruber planus. Diagnostic by quasilaser «UFL-122», green color.

Dependence of transmittance coefficient from wavelength for benign tissue sections at the same thickness, taken at three levels are presented in

Fig. 1 and for malignant tissues - in Fig. 1b. Maximum absorption for all investigated tissues responsible wavelength ranges to 500-700 nm with a maximum at 550 nm. No significant differences in the nature of absorption of benign and malignant tissue were found. Fig. 1 shows the dependence of a transmittance coefficient of wavelength for "SOLCOSERYL" layer thickness is 2mm. Absorption of light is low and clearly not dependent on the wavelength.

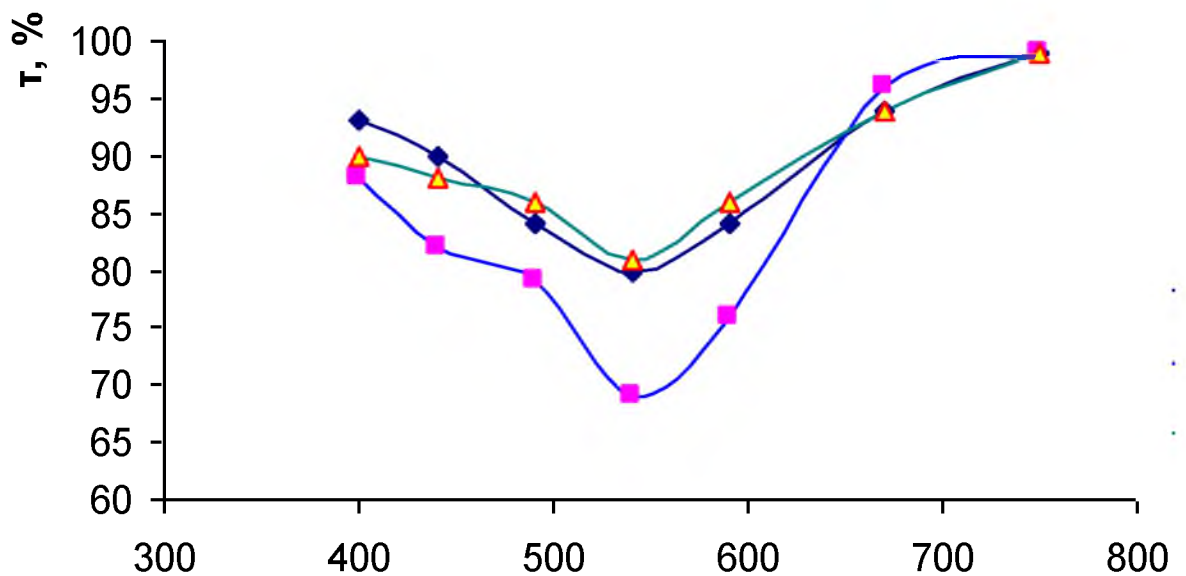


Fig. 12. A diagram of dependence of transmittance versus wavelength for tissue with benign formations.

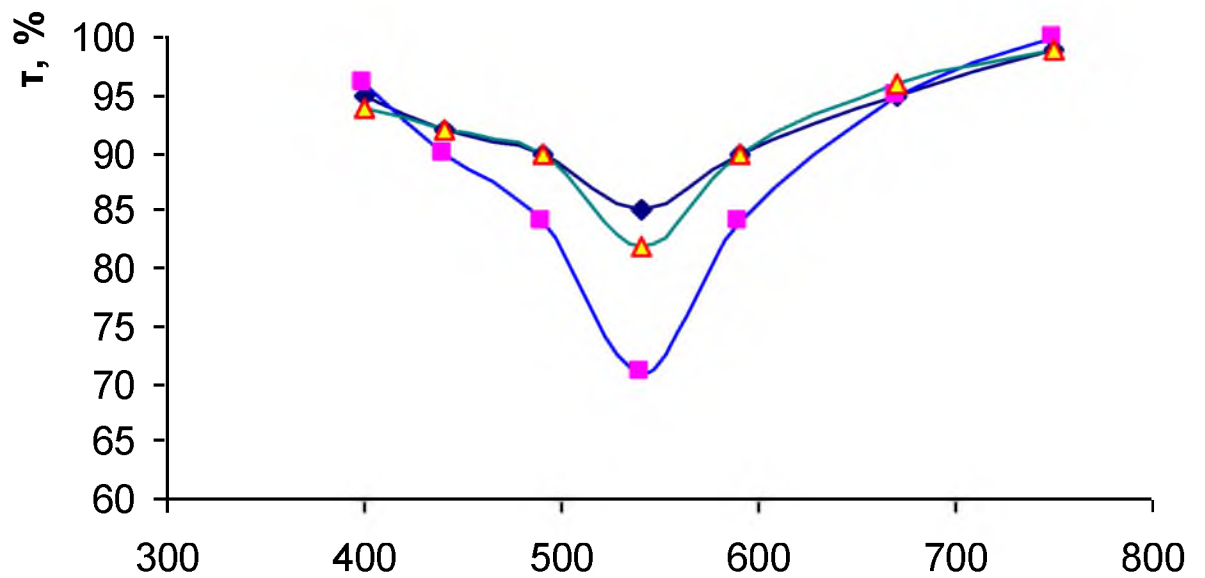


Fig. 13. A diagramme of dependence of transmittance versus wavelength for tissue with malignant formaions.

- ◆ I level
- II level
- ▲ III level

Comparing the absorption specters it can be concluded that the greater effect is achieved when irradiated with light in the wavelength range 550 - 650nm, which has color from yellow-green to red.

It is known that light absorption depend on the thickness of malignant and benign tissue, taken at different levels using the same filters colorimeter, there was no significant difference in the nature of absorption. Fig. 2 presents graphs showing the dependence of the optical density of the substance D material thickness in micrometers for wavelengths belonging to four spectral intervals. The figure shows that with decreasing wavelength of the optical

density of the medium grows faster with increasing depth of penetration of light.

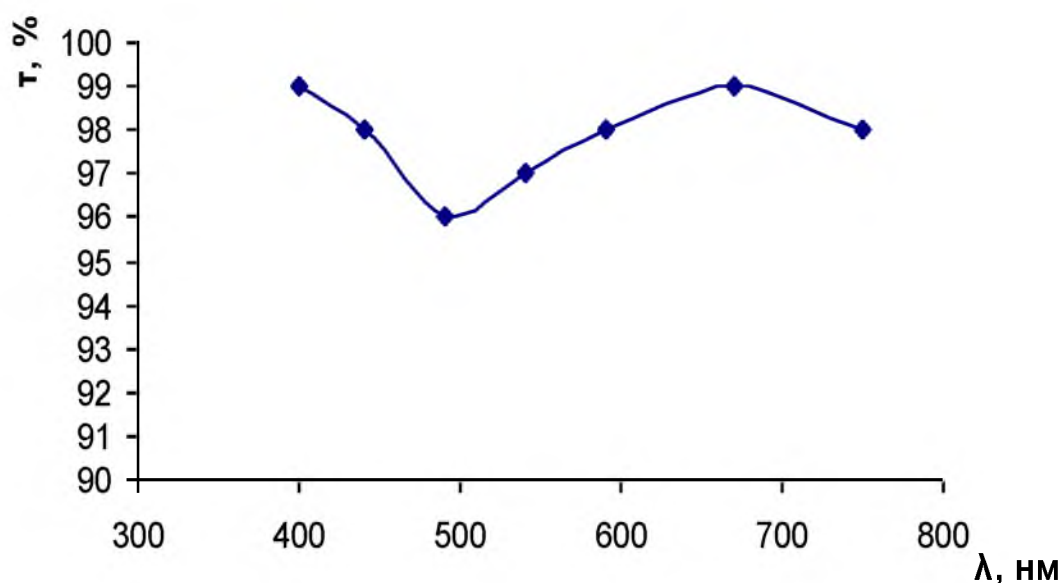


Fig. 14. A diagram of dependence of transmittance versus wavelength for Solcoseryl.

Dependencies of transmittance coefficient of mucosal tissues with the thickness of absorbing layer for different wavelengths are presented at Fig. 3. The intensity of light red is reduced by about 10 times during passage through tissues layer thickness of 1 mm, and the intensity of green light is reduced 10 times at a distance 100 mkm.

So permeable ability of light depends on the wavelength of light and it is the largest for light red. This makes it possible to use as a light source the quasi-monochromatic red light by device «UFL-122», which accounts for maximum radiation wavelength  $\lambda = 602nm$ .

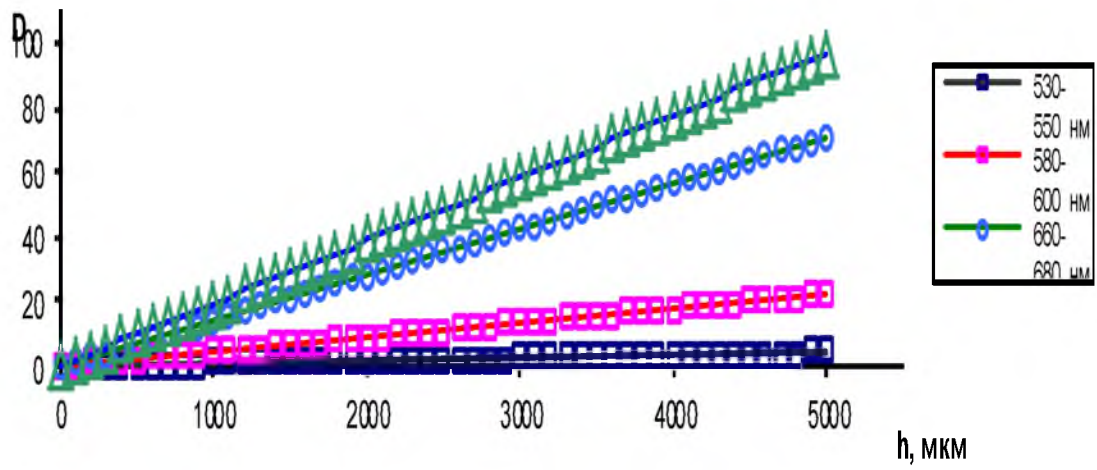


Fig. 15. A diagram of dependence of absorbance mucosal tissues of thickness for wavelengths in four intervals

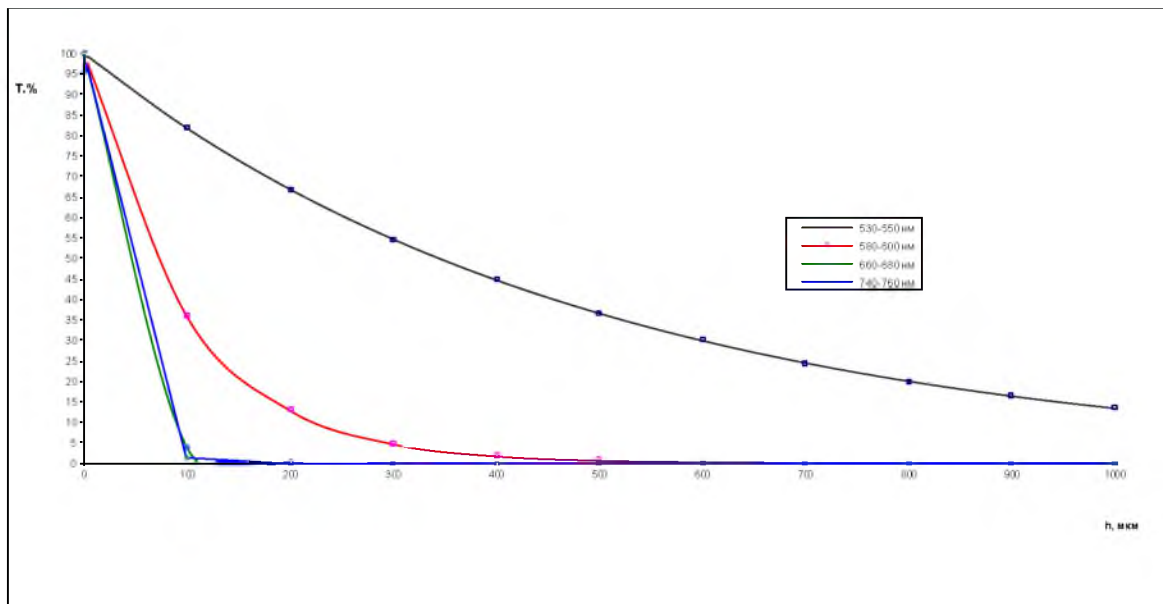


Fig. 16. A diagram of dependence of absorbance mucosal tissues of thickness for wavelengths in four intervals

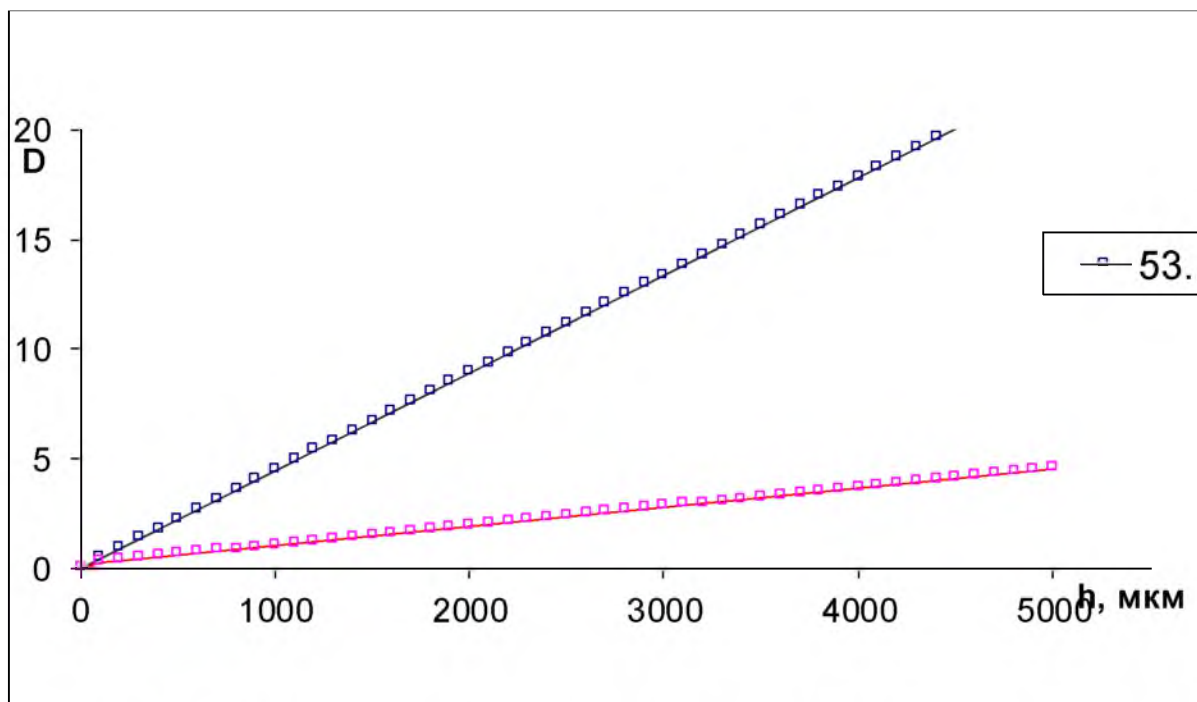


Fig. 17. A diagram of dependence of absorbance mucosal tissues of thickness for wavelengths 660-68- nm with and without Solcoseryl in four intervals

According to averaged experimental data, plots of optical density on the thickness for benign and malignant tissues using and without Solcoseryl for the spectral range of 660 - 680nm are presented in Figure4. The graph shows that the introduction of Solcoseryl is slightly reduced the absorption of upper layers of tissue that provides its penetration to the deeper layers.

So, significant differences in the nature of light absorption for benign and malignant tissue, taken at various levels, were not found. More light absorption is occurred in the wavelength range 550 – 650 nm, which has color from yellow-green till red.

The optical density of matter for both kinds of tissues is linearly increased with the increasing of layer thickness. The optical density is faster increased at decrease of thickness of tissue with the decrease of wavelength.

Introduction of Solcoseryl slightly reduces the light absorption of upper layers of tissue. Red light is more permeable. So, red and orange lights that are produced by «UFL-122» can be used for the implementation of phototherapy."



## **X-RAY INVESTIGATION**

An X-ray is a noninvasive, quick, painless test that produces images of the structures inside body.

X-rays were first discovered in 1895 when, during experiments with electric currents passed through a vacuum tube, Wilhelm Conrad Röntgen noted that a nearby fluorescent screen glowed when the current was being passed.

X-rays are a vital imaging tool used around the globe. Since first being used to image bones over 100 years ago, the X-ray has saved countless lives and helped in a range of important discoveries.

X-rays are a naturally occurring form of electromagnetic radiation. They are produced when charged particles of sufficient energy hit a material.

### **The general information about X-ray:**

- X-rays are a naturally occurring type of radiation.
- They are classed as a carcinogen.
- The benefits of X-rays far outweigh any potential negative outcomes.
- CT scans give the largest dose of X-rays compared to other X-ray procedures.
- In X-rays, bones show up white, and gasses appear black.

### **Types of X-ray:**

To produce a standard X-ray image, the patient or part of their body is placed in front of an X-ray detector and illuminated by short X-ray pulses. Because bones are rich in calcium, which has a high atomic number, the X-rays are absorbed and appear white on the resulting image.

Any trapped gases, for instance, in the lungs, show up as dark patches because of their particularly low absorption rates.

**Radiography:** This is the most familiar type of X-ray imaging. It is used to image broken bones, teeth, and the chest. Radiography also uses the smallest amounts of radiation.

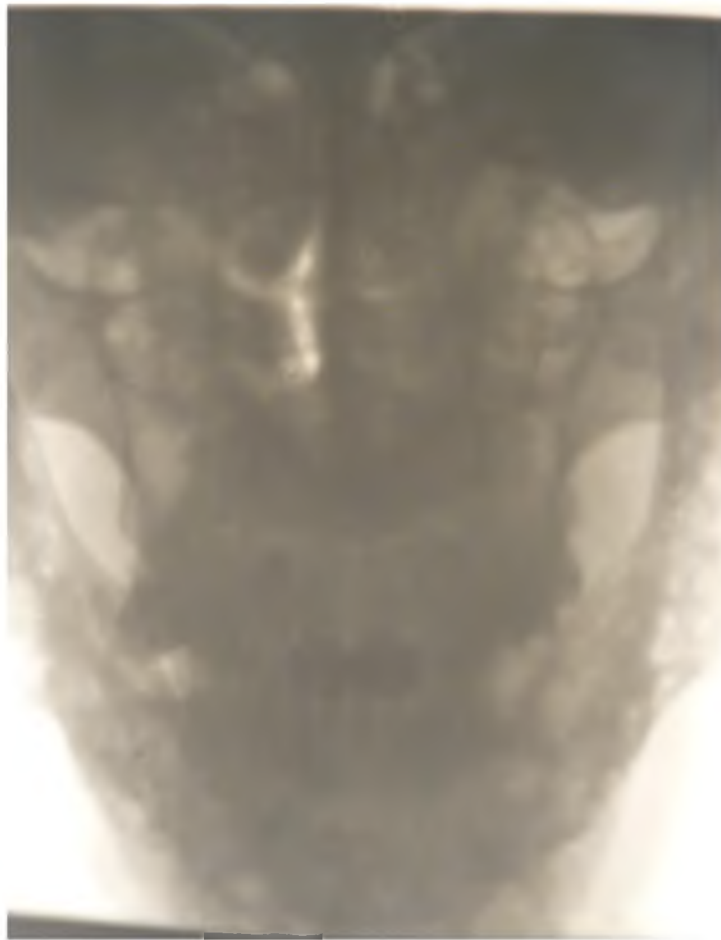

Fig. 18. The X-ray of facial skeleton in direct proection. The Paget's disease.

**Fluoroscopy:** The radiologist, or radiographer, can watch the X-ray of the patient moving in real-time and take snapshots. This type of X-ray might be used to watch the activity of the gut after a barium meal. Fluoroscopy uses more X-ray radiation than a standard X-ray, but the amounts are still extremely small.

**Computed tomography (CT):** The patient lies on a table and enters a ring-shaped scanner. A fan-shaped beam of X-rays passes through the patient onto a number of detectors. The patient moves slowly into the machine so that a series of "slices" can be taken to build up a 3D image. This procedure uses the highest dose of X-rays because a large number of images are taken in one sitting.

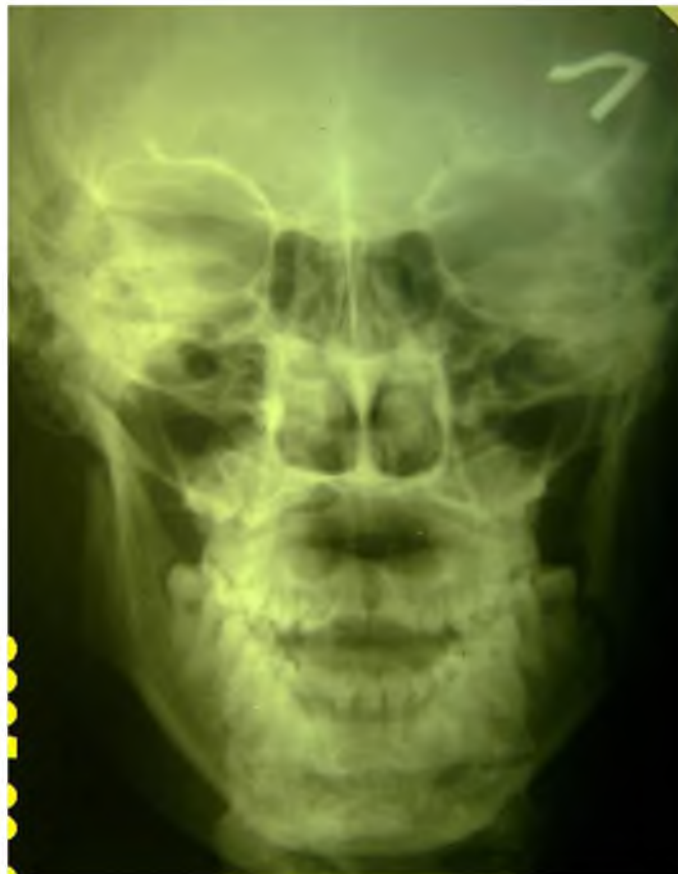


Fig. 19. The X-ray of facial skeleton in direct proection. The angular fracture of mandible on the left side.

**Review X-rays** can be performed in three projections - straight, lateral and forward semi-axial - and allow to get an image of the entire facial and cranial skull.

A **direct projection** can be performed at the nose-frontal or nasal-spinous distance of the cassette. Indications for pictures in the nose-frontal projection are: injuries and diseases of the cerebral and facial skull.

This projection is also used in sialography and fistulography. Images in the nose-chin of the projection are used: for studying the bones of the middle and upper floors of the facial skull, paranasal sinuses of the nose. The state of the teeth on the X-rays in the direct projection is not analyzed.

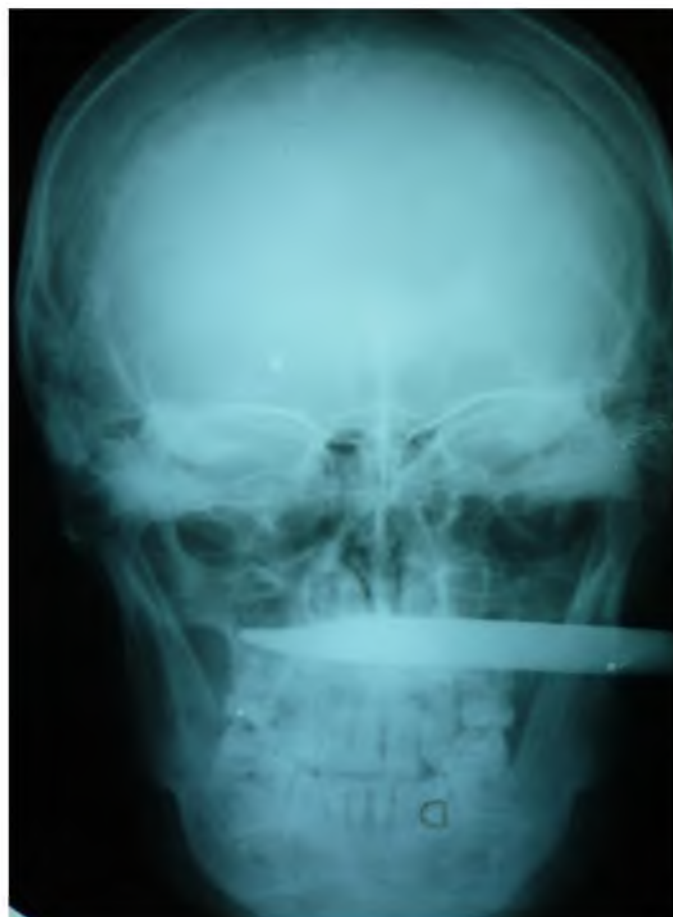


Fig. 20. The X-ray of facial skeleton in direct projection. The foreign body (knife).

**Lateral skull images** are made as a mandatory addition to direct. However, studying the state of the bones of the facial skeleton from these images due to the articulation effect of the right and left half of the skull is quite complicated. Usually only rough, large bone changes are available. Side images are often performed to study the condition of the brain skull, its foundation, the Turkish saddle, the main and frontal sinuses, as well as to determine the localization of extraneous bodies.

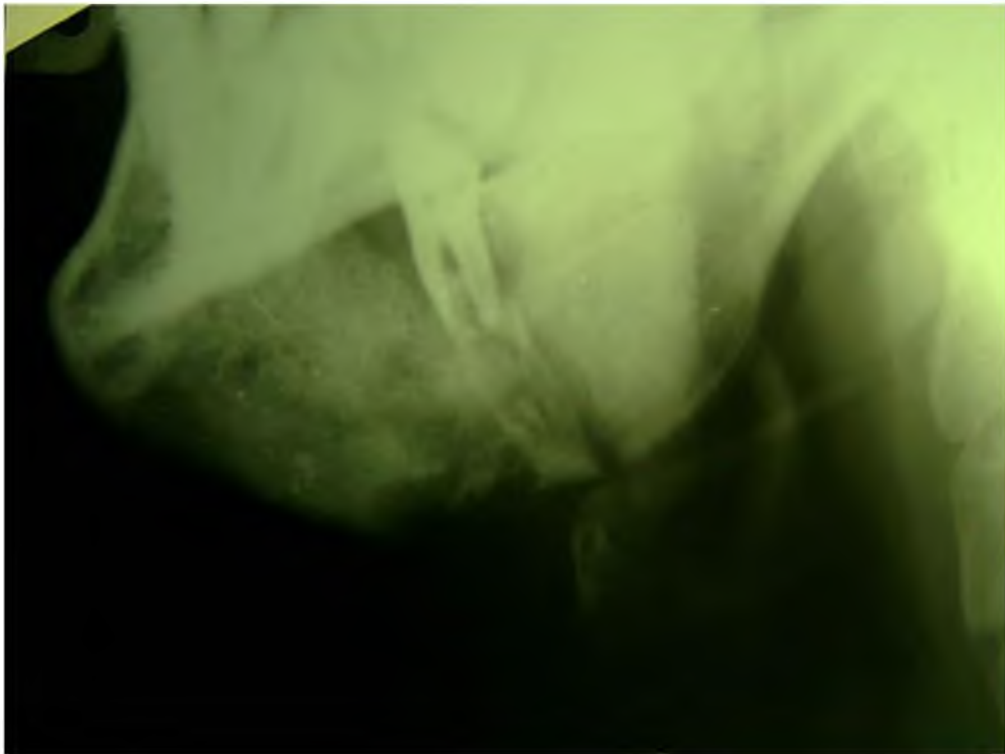

Fig. 21. X-ray of mandible in lateral projection. The posttraumatic osteomyelitis of mandible.

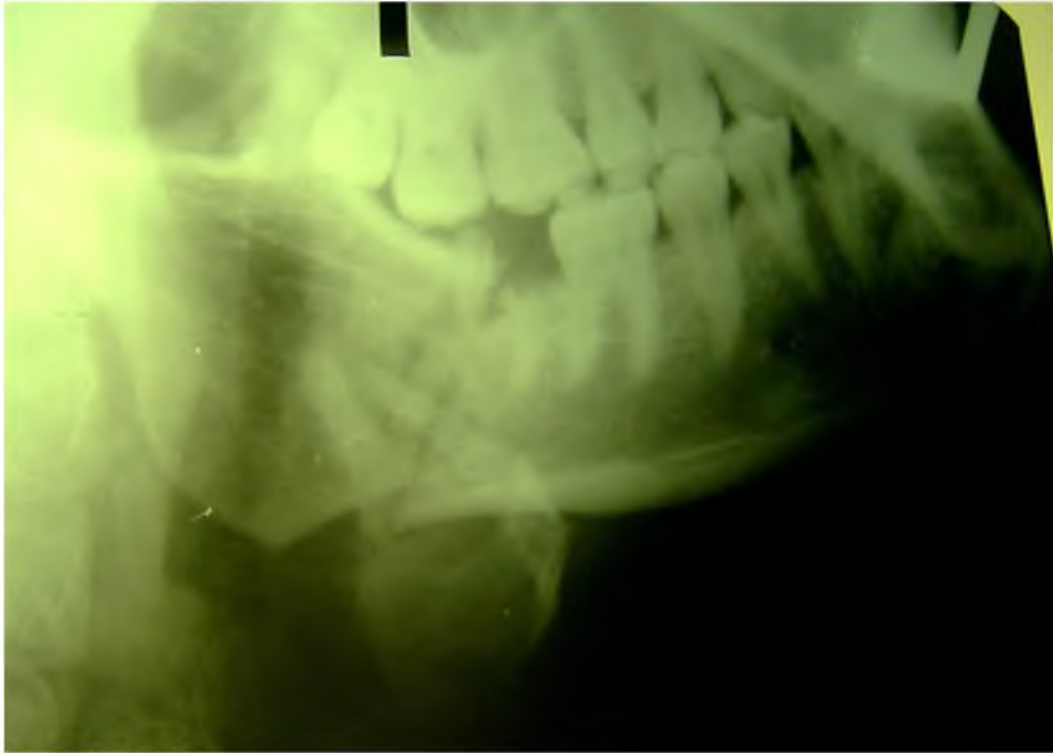


Fig. 22. X-ray of mandible in lateral projection. The angular fracture of mandible.

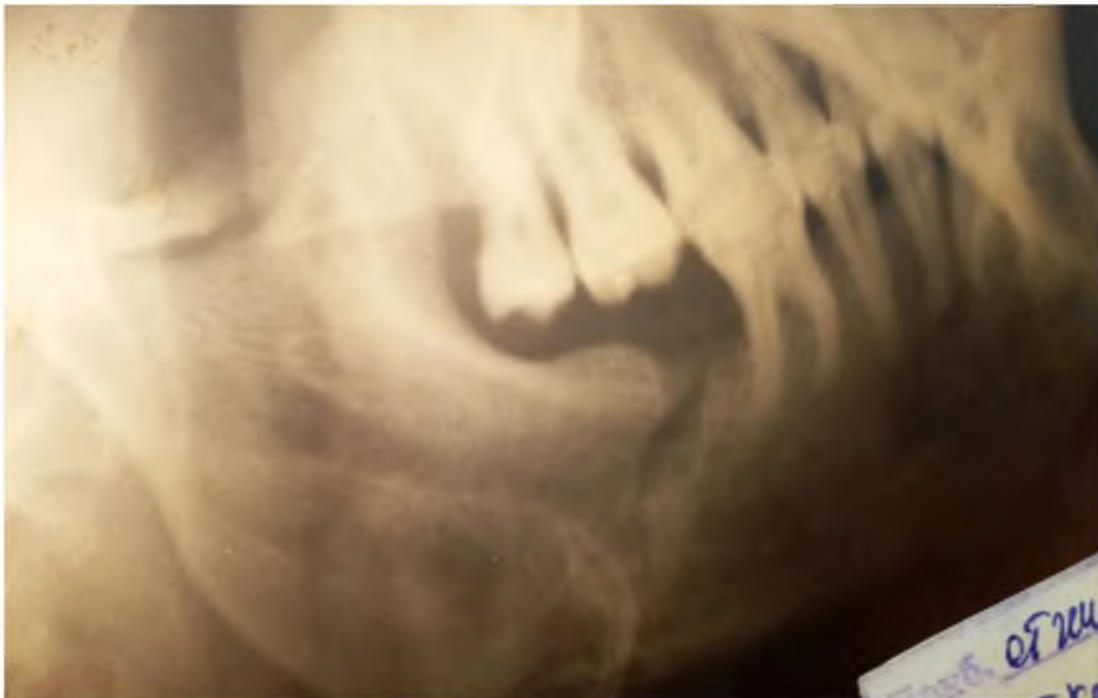

Fig. 23. X-ray of mandible in lateral projection. The pseudo-joint of mandible.

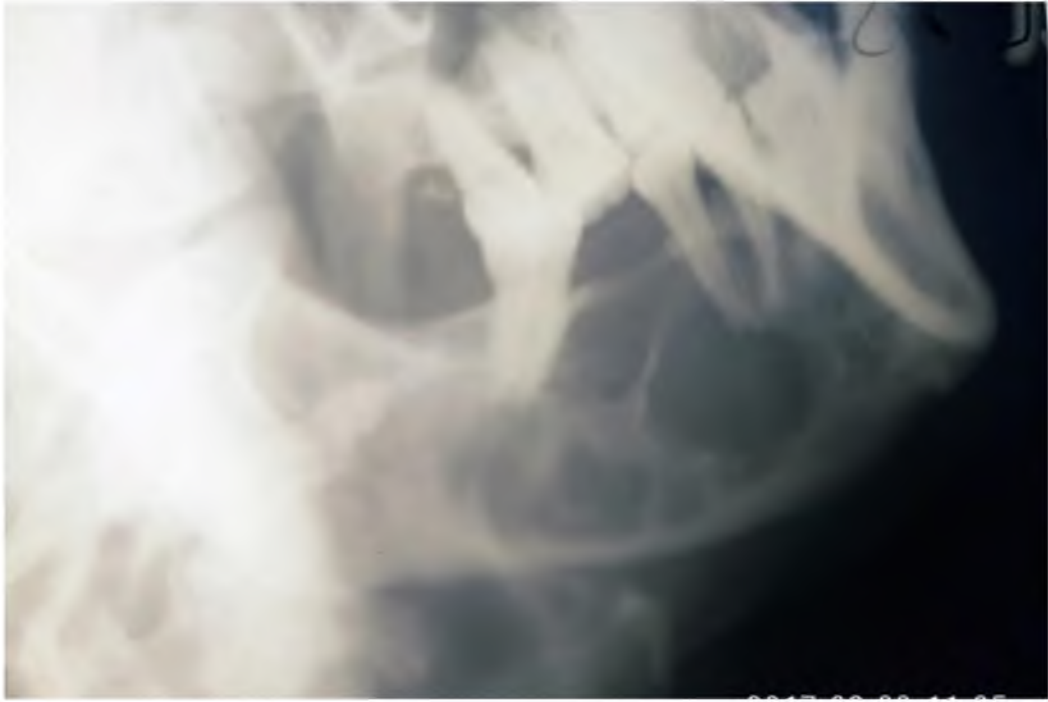

Fig. 24. X-ray of mandible in lateral projection. The osteoblastoclastoma of mandible.



Fig. 25. X-ray of mandible in lateral projection. The ameloblastoma of mandible.

**Axial and forward semi-axial images** are performed, if necessary, to study all structures of the base of the skull, the bones of the middle face, including the ophthalmic, the frontal and maxillary sinuses, the zygomatic bones and archs.

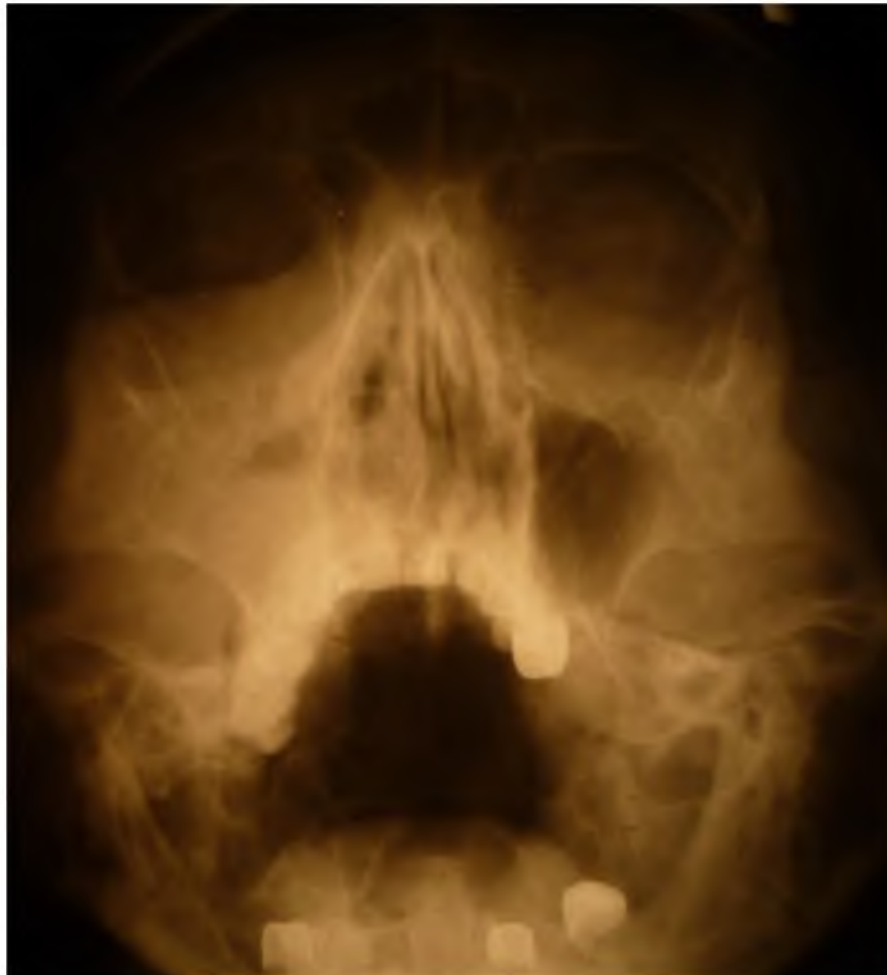


Fig. 26. The radiography of paranasal sinuses. The odontogenic sinusitis.

**Extraoral jaw images** are performed using both dental and other X-ray machines. X-ray film size 13x18 or 18x24 cm is used and corresponding cassettes with amplifying screens. Extraoral radiographs are performed to study the mandible, maxilla, zygomatic bones, temporomandibular joint (TMJ), as well as sialography, fistulography. Indications for such pictures can



be inflammatory, tumorous, traumatic damages of the jaws, large cysts, defeats of periodontology of the mandible in the absence of intraoral x-ray.

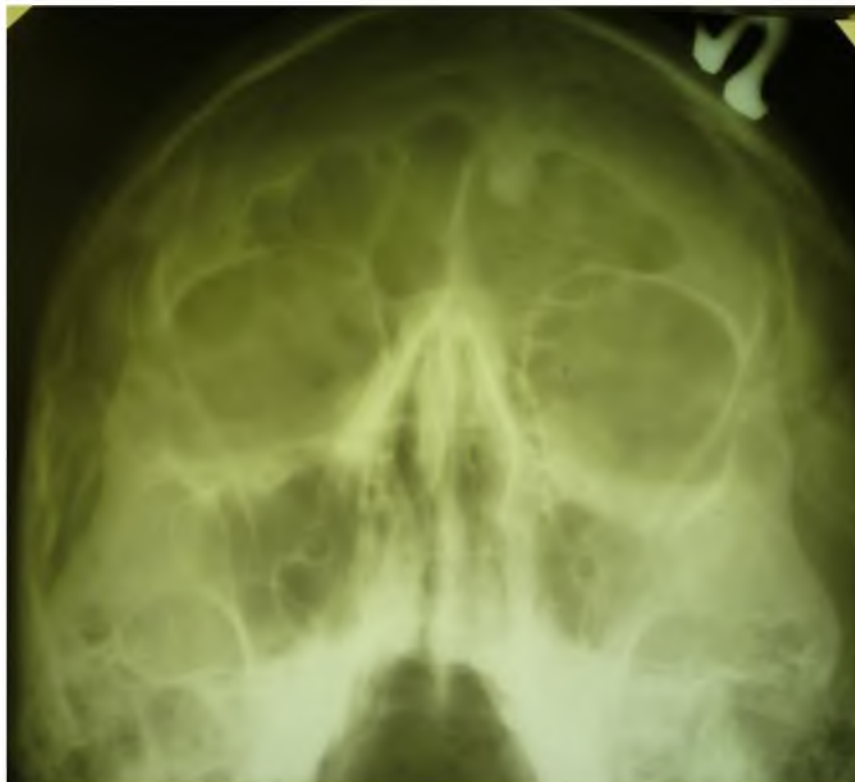


Fig. 27. The radiography of paranasal sinuses. The odontoma of frontal sinus.

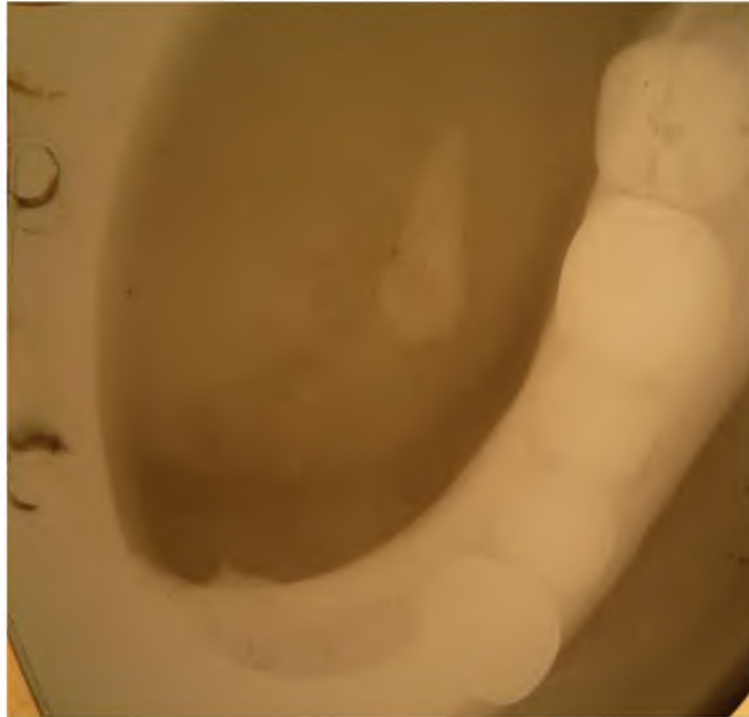

Fig. 28. The X-ray of the oral floor. The presents of the concrement is submandible saliva gland

For examination of the state of the **TMJ**, special arrangements by Schüller, Parma can be applied. Snapshots are required on both sides to compare joints.

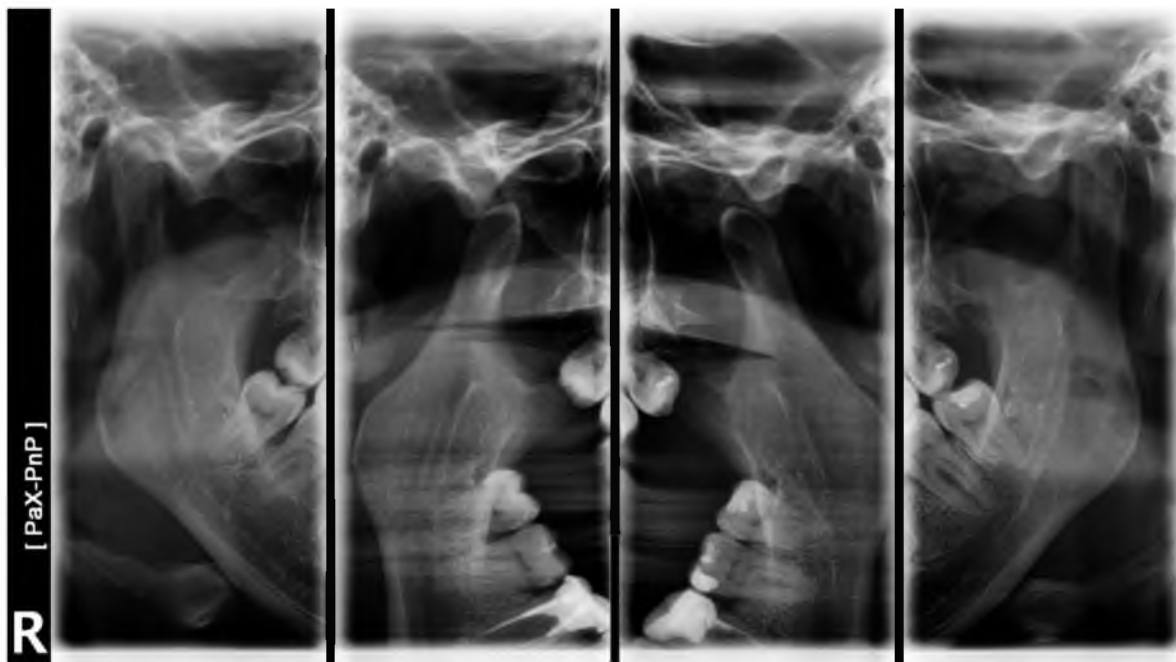


Fig. 29. The TMJ radiography. The deformity arthrosis of TMJ.

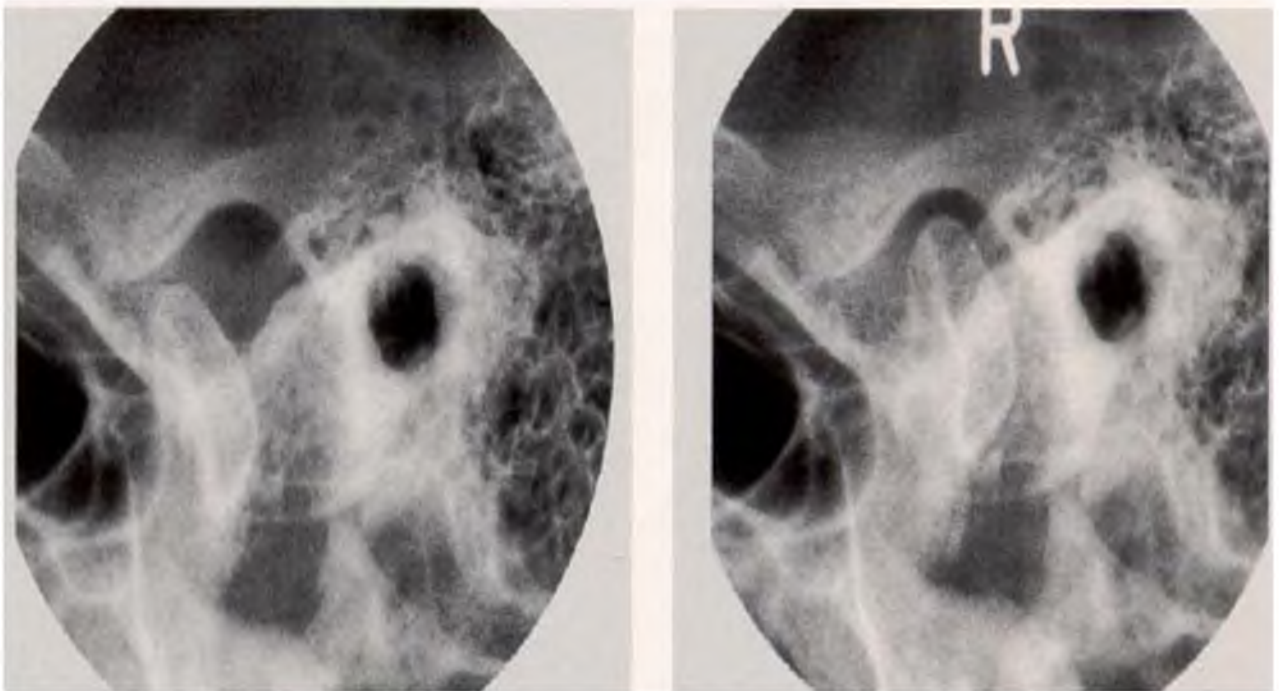


Fig. 30. The TMJ radiography by Schüller.

**Sialography** is the imaging of the salivary glands, most commonly the parotid gland. The salivary ducts are conventionally examined fluoroscopically with high sensitivity, though cross-sectional imaging with CT or MR sialography has also been described.

#### ***Indications***

- suspected sialolithiasis or salivary duct obstruction
- suspected sialadenitis: to identify ductal strictures
- suspected sialectasis in chronic inflammatory disorders and autoimmune diseases

#### ***Types of sialography***

There are three types:

- conventional/fluoroscopic sialography (with or without digital subtraction)
- CT sialography (ultrafast technique)
- MR sialography

In most cases, ultrasound (with sialography, if required) is an appropriate imaging modality for the investigation of ductal pathology. In cases of sialolithiasis, ultrasound of the parotid glands is a useful, readily available, noninvasive, and inexpensive option.

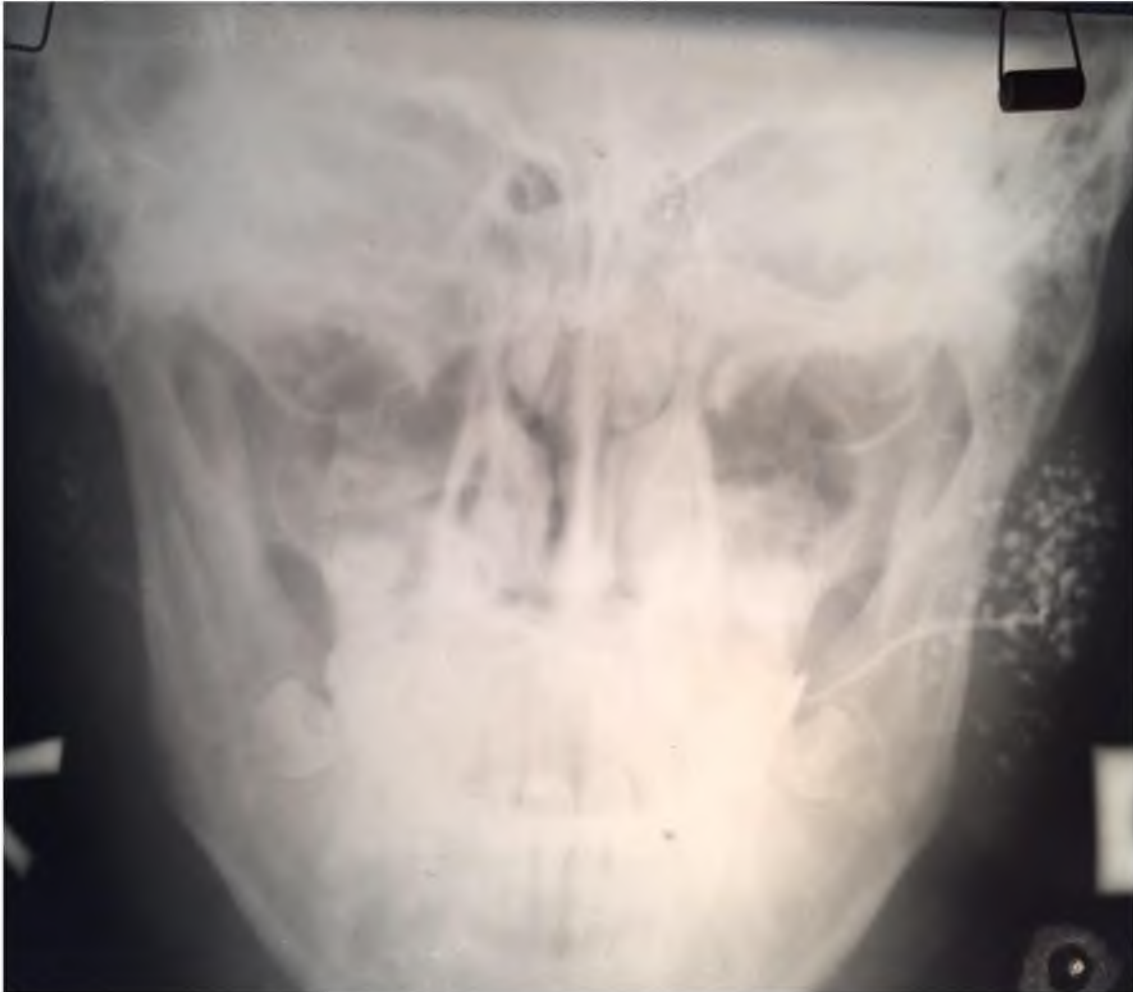


Fig. 31. The sialography of chronic parenchymatous sialoadenitis of parotid gland.

#### *Advantages*

- higher spatial resolution for superior diagnostic elucidation (when the procedure is successfully achieved) with accurate delineation of second- and third-order branches

- enables therapeutic approach in sialoendoscopy for removal of sialoliths, retrograde displacement of sialoliths to relieve acute obstruction, and to dilate strictures

#### *Disadvantages*

- invasive procedure
- substantial failure rate of procedure (especially submandibular sialography) due to cannulation problems, lack of skill, lack of patient compliance, pain, etc.
- radiation exposure
- contrast media exposure with risk of allergic reaction

### **Technique of CT sialography**

The procedure is essentially the same as a conventional sialogram, after which the patient is positioned in a CT in neutral supine position. Multiplanar data acquisition allows for 3D reconstruction. Intravenous contrast material can be administered for better soft tissue evaluation, especially for parotid masses. In the 1970s and 1980s, when this technique was first introduced, slower CT scans called for delayed ductal emptying, for which atropine was given.

#### *Advantages*

- assessment of glands other than the parotids is possible
- better diagnosis of parenchymal pathology, excellent visualisation of the deep lobe, and better subtraction options
- no special positioning required

#### *Disadvantages*

- intravenous atropine is required to minimise run-off of contrast and impair ductal clearance in some cases
- radiation exposure
- invasive procedure

## **Technique of MR sialography**

MRI sialography is a fairly sensitive and reliable method of evaluating the salivary glands. Fast acquisition heavily T2 weighted sequences brighten intraluminal fluid and display ductal morphology adequately with no need to inject contrast into the ducts. MR contrast administered intravenously is a useful adjunct.

### *Advantages*

- rapid acquisition
- non-invasive
- assessment of other glands possible
- excellent delineation of parenchymal pathology
- no special positioning required
- because no cannulation is required, the risk of air bubbles simulating intraductal calculi is minimised

### *Disadvantages*

- general MRI contraindications, e.g. pacemakers, implants, claustrophobia
- dental fillings, implants, bridges, etc. can cause image impairment
- only first- and second-order branches can be delineated

**Intraoral radiography** is still the basis of X-ray examination for most diseases of the teeth and periodontal disease. Currently, there are four methods of intraoral X-ray, used to study the state of teeth, para- and periodontal:

1. Contact X-ray according to the rule of isometry.
2. Interproximal X-ray.
3. Roentgenography of the ventricle (occlusion).

4. Roentgenography with an increase in the focal length of a parallel beam of beams (long-focal radiography).



Fig. 32. The position for the depiction of a maxillary third molar.

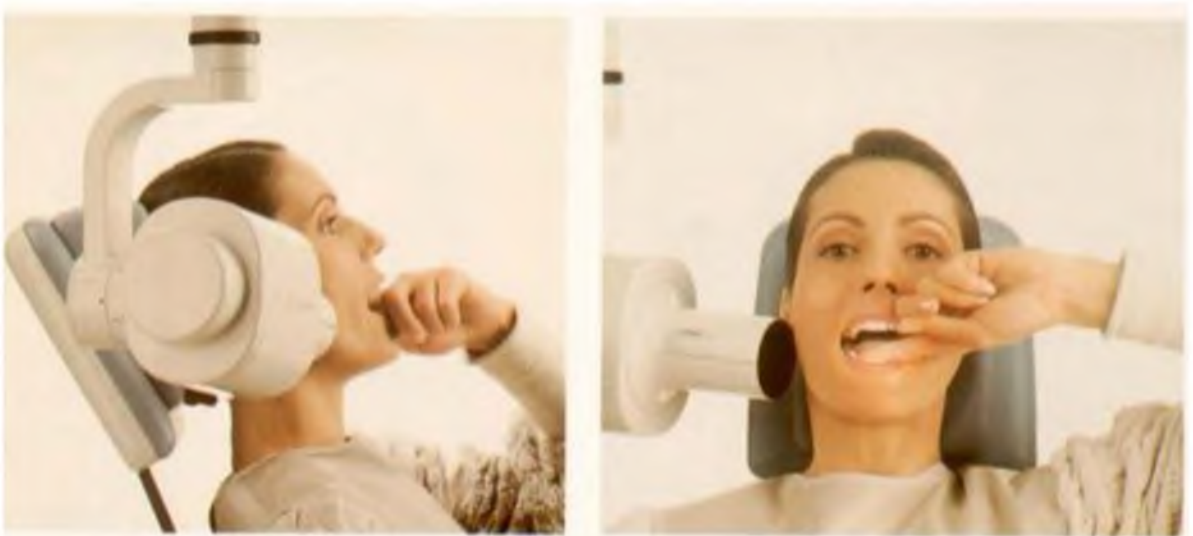

Fig. 33. The position for the depiction of a mandibular third molar.

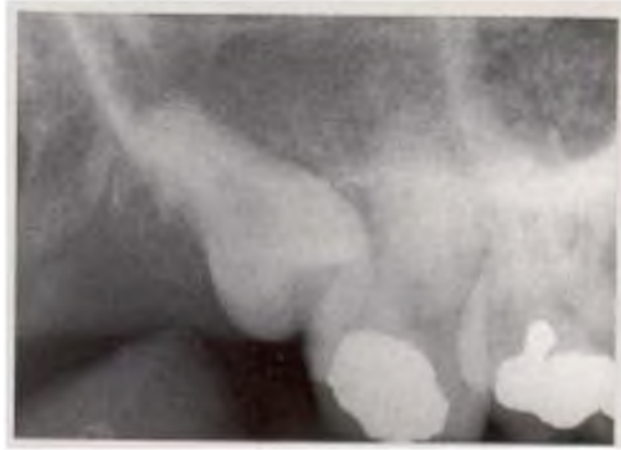

Fig. 34. Radiograph of an obliquely impacted third molar.

The analysis of radiographs of teeth and periodontium should be carried out according to the following scheme:

1. evaluation of the quality of X-rays: contrast, sharpness, the presence of projection distortions (extension, shortening, projection overlay), informative to assess the area;
2. crown assessment: size, shape, contours, intensity of solid tissues, presence of carious cavity, seal, seal defect, ratio of the bottom of the carious cavity and the cavity of the tooth, the presence of dental deposits;
3. Tooth cavity: presence, absence, form, size, structure, presence of filling material, dentiklies;
4. Tooth root: number, size, shape, contours, angle of bifurcation;
5. Root canal: presence, absence, width, direction, degree of sealing;
6. Evaluation of the periodontance gap: width, uniformity;
7. Compact plate of the alveola: presence, absence, thinning, thickening, violation of the integrity;
8. Surrounding bone tissue: osteoporosis, destruction, osteosclerosis;
9. Condition of interdental partitions: the shape, height, conservation of locking cortical plate, structure.



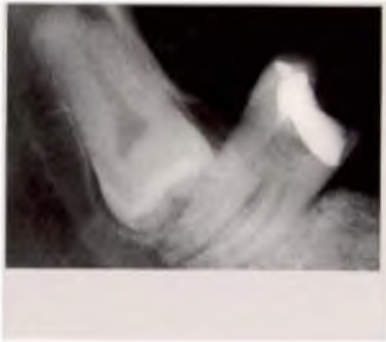

Fig. 35. Radiograph of the horizontally impacted mandibular third molar.

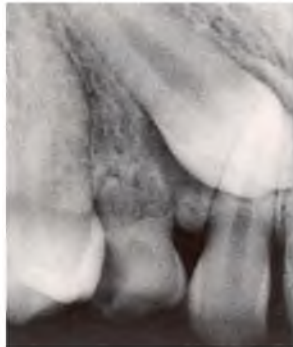

Fig. 36. Radiograph of the horizontally impacted canine of maxilla.

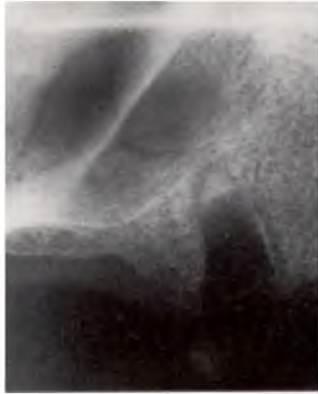

Fig. 37. The intraoral radiography of fragment root of 15 tooth.

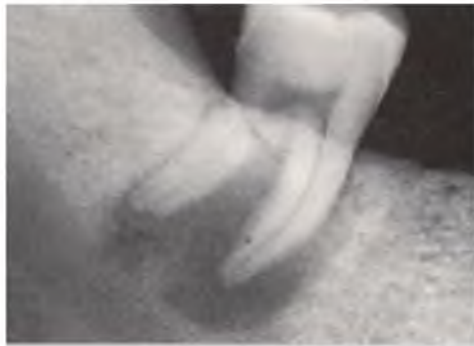

Fig. 38. The intraoral radiography. The fracture of distal rot and chronic periodontitis of 37 tooth.

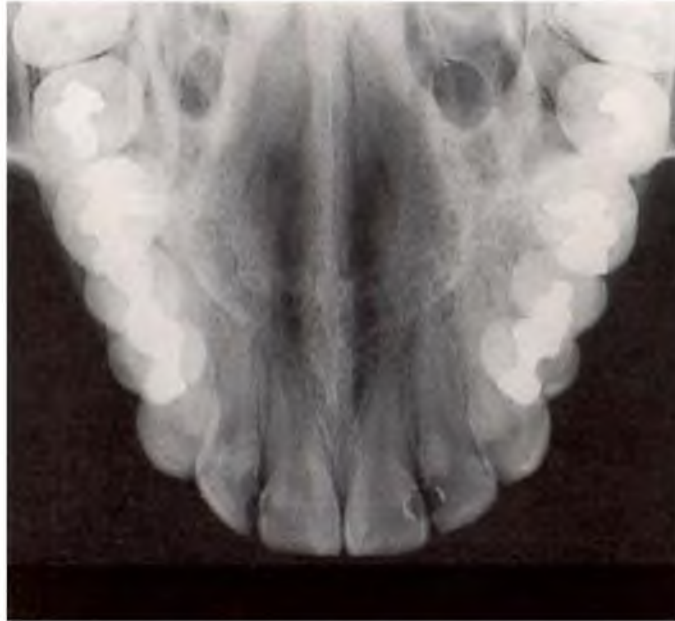


Fig. 39. Occlusal radiography of maxilla.

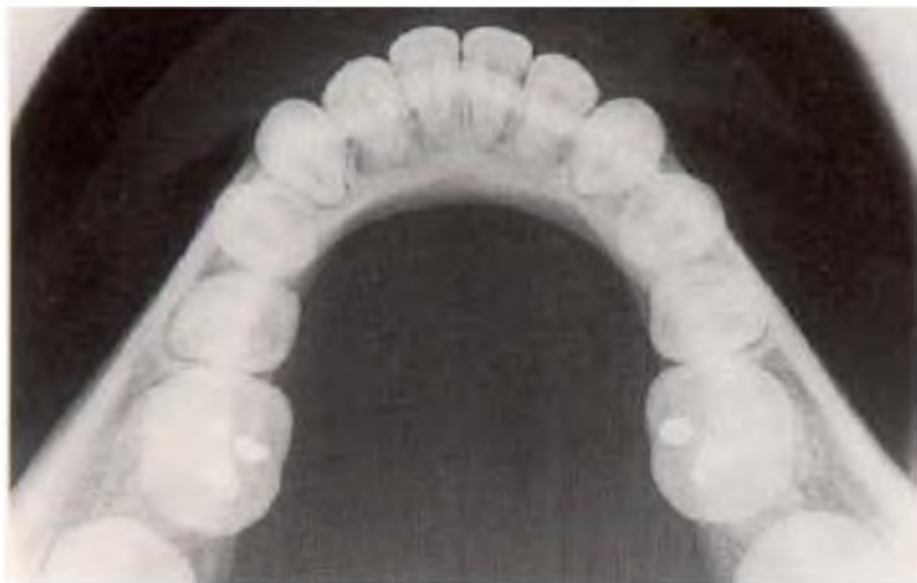

Fig. 40. Occlusal radiography of mandible.

**Orthopantomogramma (OPTG)** is a cross-sectional circular image of the teeth and jaws, unfolding in the plane. On panoramic tomography, an image of the entire dental-maxillary system appears with an increase of approximately 30%. It can be seen all departments of the lower jaw, alveolar bone and the relationship between the roots of the teeth with the bottom of the maxillary sinus, the elements of the winged pockets and pterigoid branches of

the sphenoid bone. Rear branches of the sinuses are outside the allocated layer.

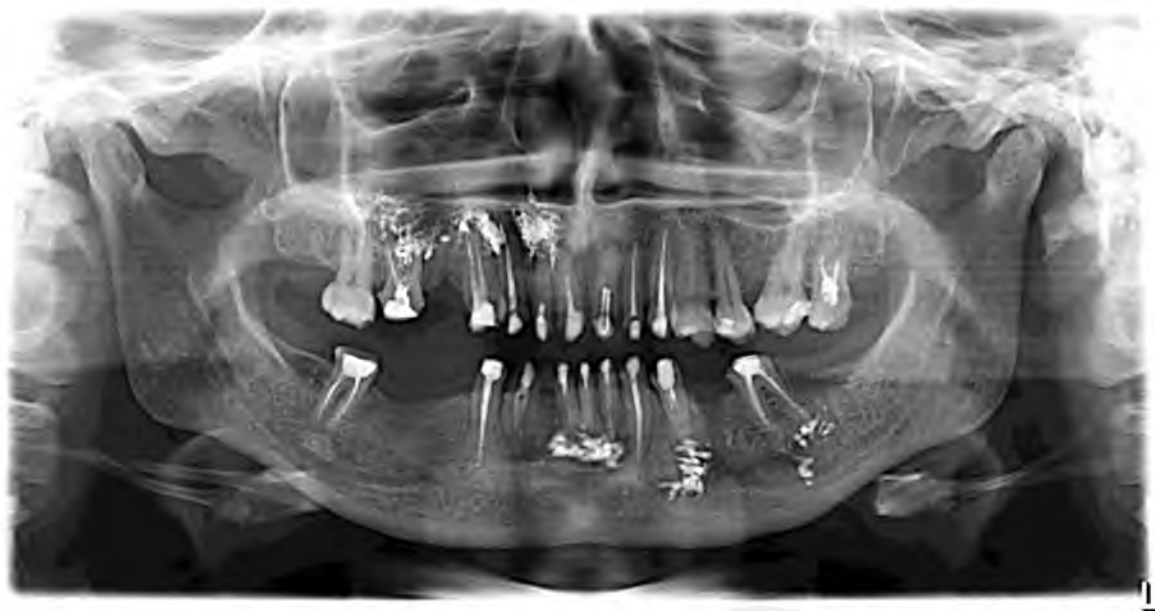

Fig. 41. OPTG. The presents of foreing bodies as a result of filling of roots chanals.

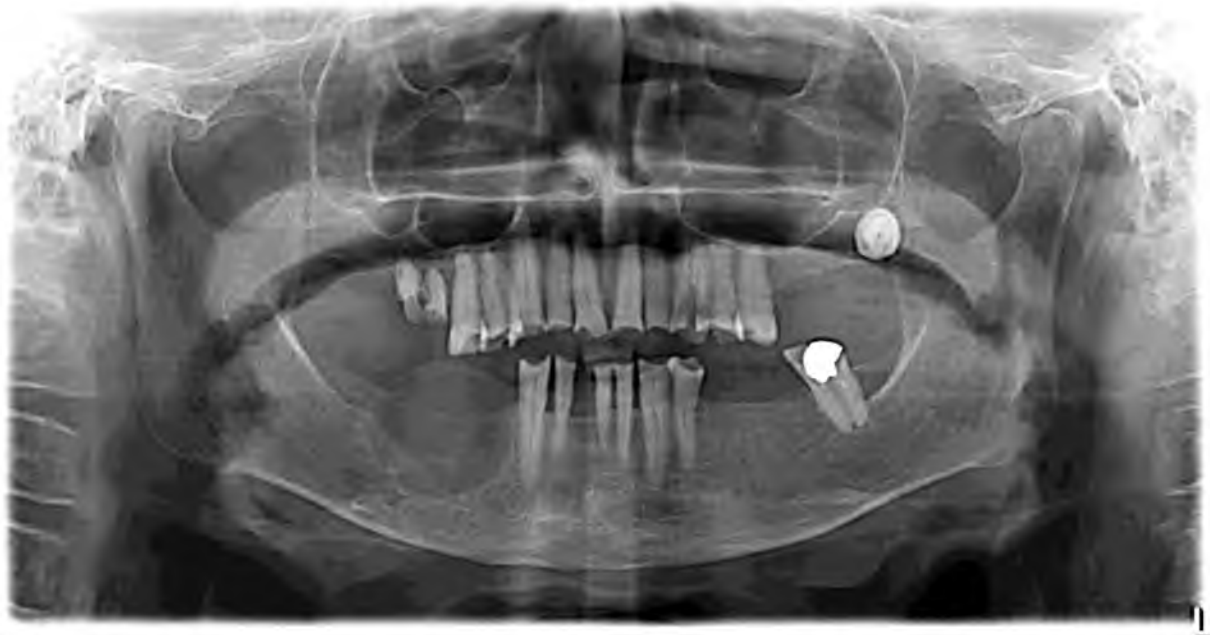


Fig. 42. OPTG. The residual cyst of mandible.

**The panoramic tomography allows to examine:**

The presence of paradontal pockets;

The dynamics of the installation and implantation of the implants;

The presence and degree of development of the rudiments of the teeth;

Roots of teeth and perineum tissues;

Periodontium diseases;

Hidden interdental carious cavities;

Degree of formation of dental roots;

Presence or absence of bone tissue for implantation required;

Condition of lower part of maxillary sinuses;

Traumatic damages of jaws;

Neoplasm of jaws.

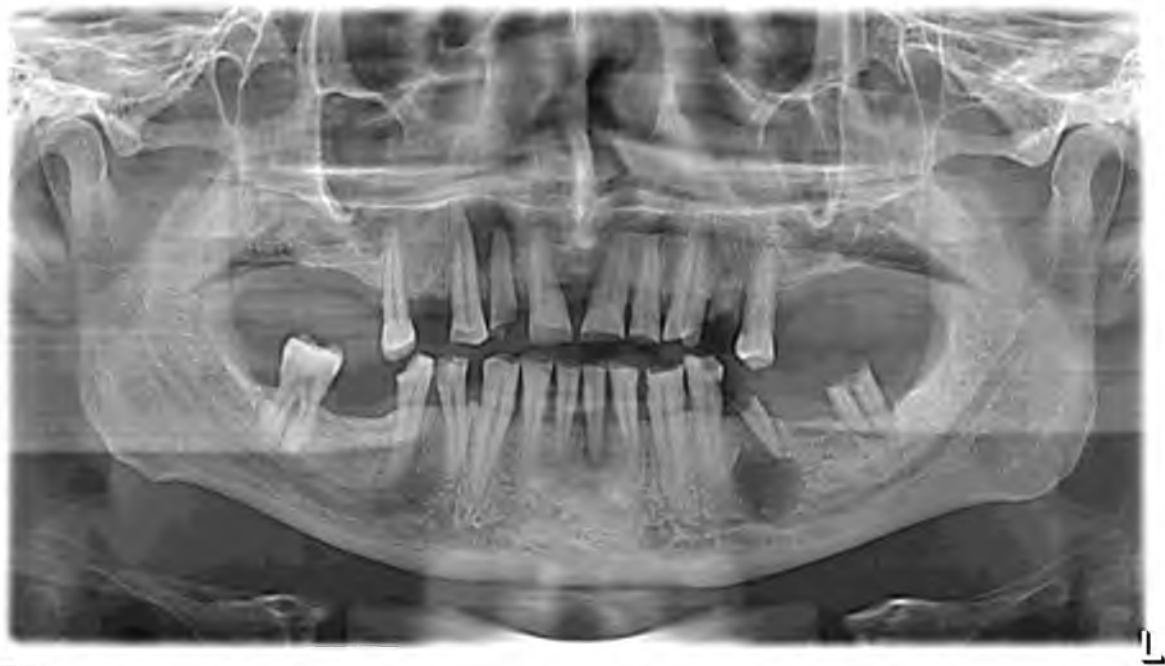

Fig. 43. OPTG. The radicular cyst of mandible.

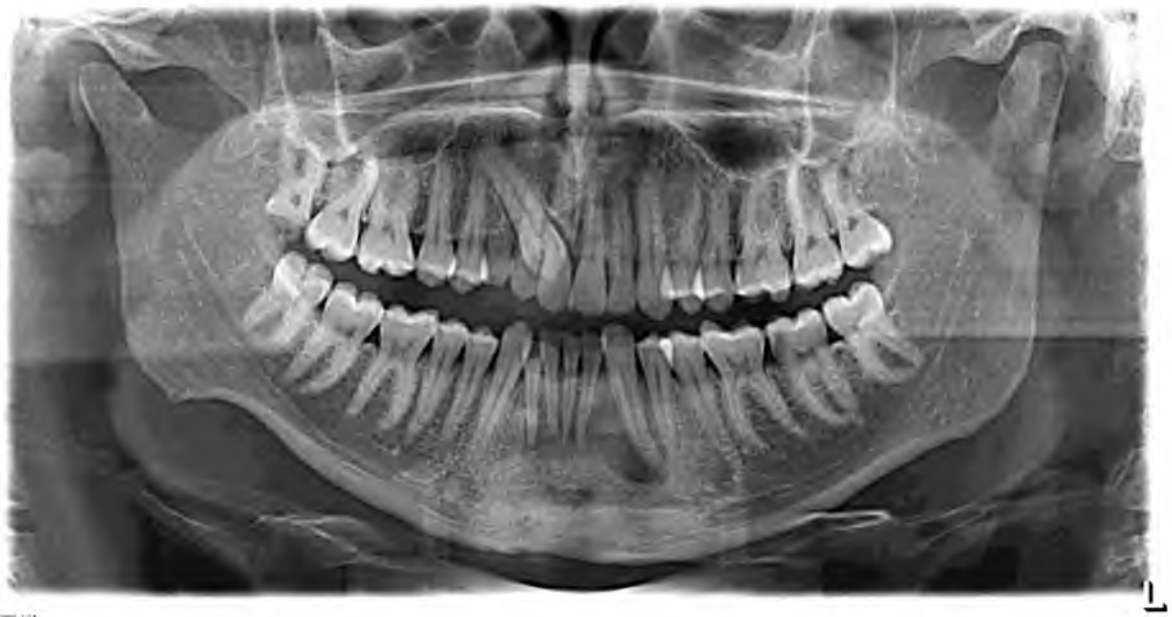

Fig. 44. OPTG. The retention and distopy of upper canine, radicular cyst of mandible.

### **The risk of X-ray:**

X-rays can cause mutations in our DNA and, therefore, might lead to cancer later in life. For this reason, X-rays are classified as a carcinogen by both the World Health Organization (WHO) and the United States government. However, the benefits of X-ray technology far outweigh the potential negative consequences of using them.

It is estimated that 0.4 percent of cancers in the U.S. are caused by CT scans. Some scientists expect this level to rise in parallel with the increased use of CT scans in medical procedures.

According to one study, by the age of 75 years, X-rays will increase the risk of cancer by 0.6 to 1.8 percent. In other words, the risks are minimal compared to the benefits of medical imaging.

Each procedure has a different associated risk that depends on the type of X-ray and the part of the body being imaged. The list below shows some of the more common imaging procedures and compares the radiation dose to the normal background radiation that all people encounter on a daily basis.

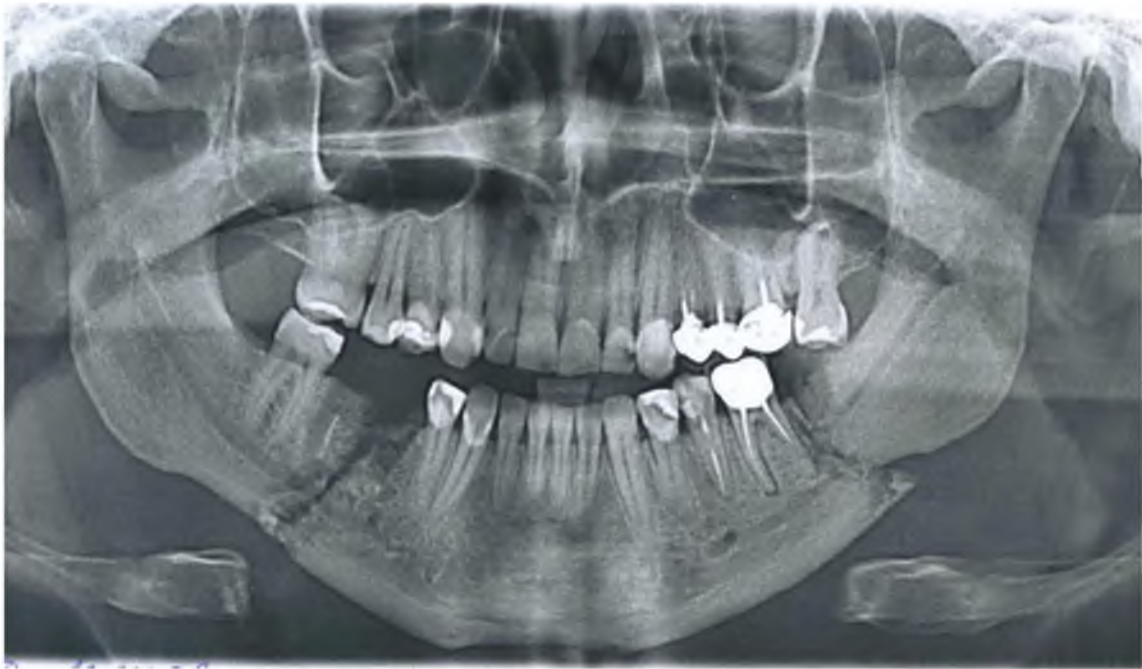

Fig. 45. OPTG. The pseudo-joint of mandible.

### **Side effects**

While X-rays are linked to a slightly increased risk of cancer, there is an extremely low risk of short-term side effects.

Exposure to high radiation levels can have a range of effects, such as vomiting, bleeding, fainting, hair loss, and the loss of skin and hair.

However, X-rays provide such a low dose of radiation that they are not believed to cause any immediate health problems.

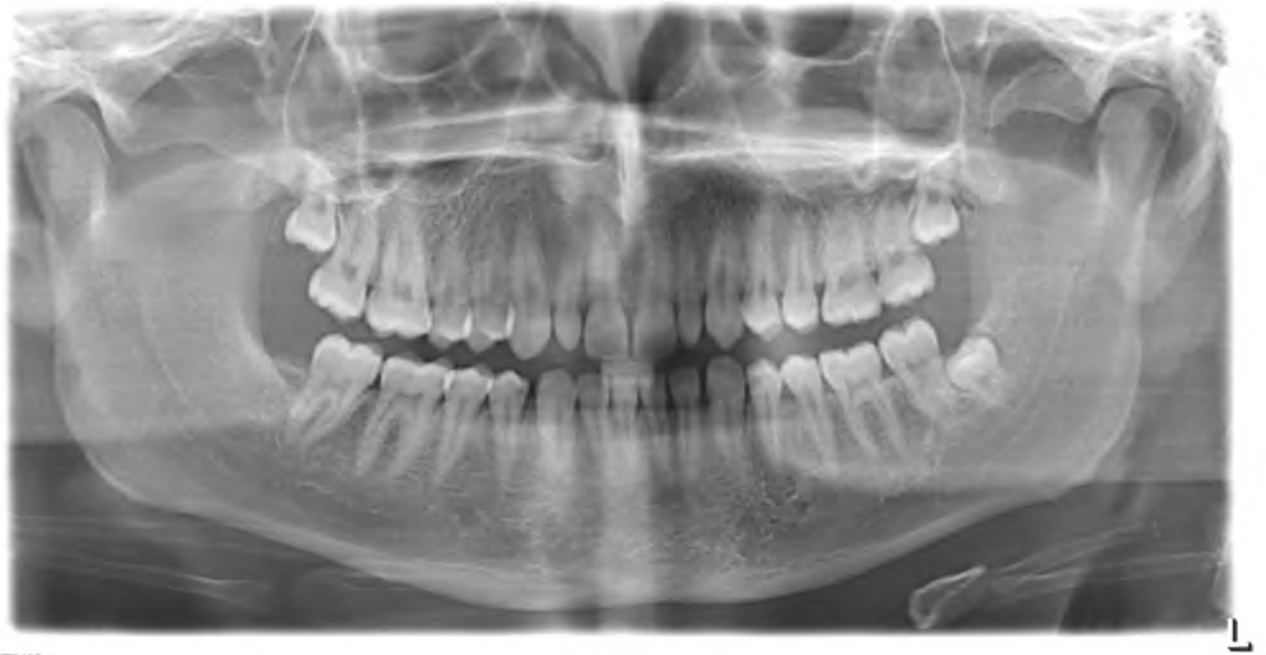

Fig. 46. OPTG. The radicular cyst of maxilla that growth into the maxillary sinus.

#### **Some of the main benefits of X-ray**

- **Non-invasive:** An X-ray can help diagnose a medical issue or monitor treatment progression without the need to physically enter and examine a patient.
- **Guiding:** X-rays can help guide medical professionals as they insert catheters, stents, or other devices inside the patient. They can also help in the treatment of tumors and remove blood clots or other similar blockages
- **Unexpected finds:** An X-ray can sometimes show up a feature or pathology that is different from the initial reason for the imaging. For instance, infections in the bone, gas or fluid in areas where there should be none, or some types of tumor.



## The description of X-ray images.

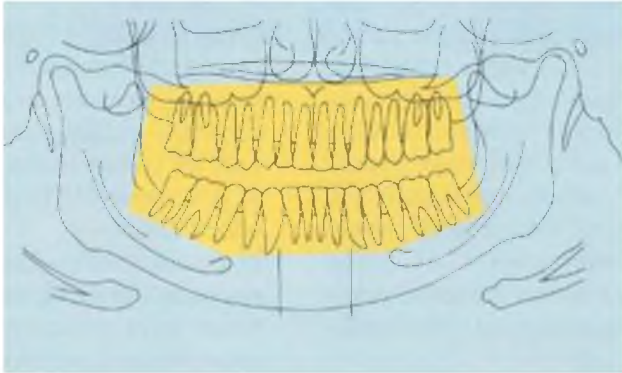


Fig. 47. Dentoalveolar region.

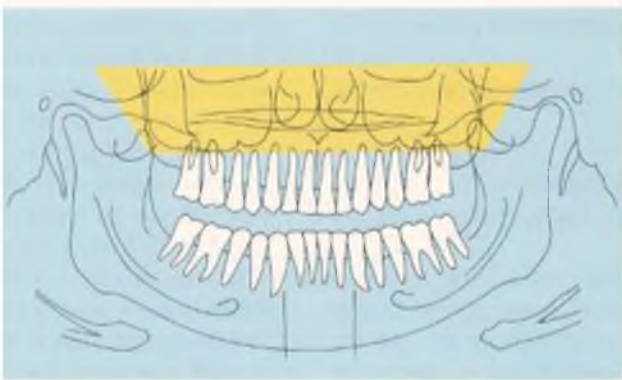


Fig. 48. Maxillary region.

Depending upon the demands of the case, occlusal films and skull films made with conventional or more modern imaging procedures may be required to supplement the panoramic radiograph.

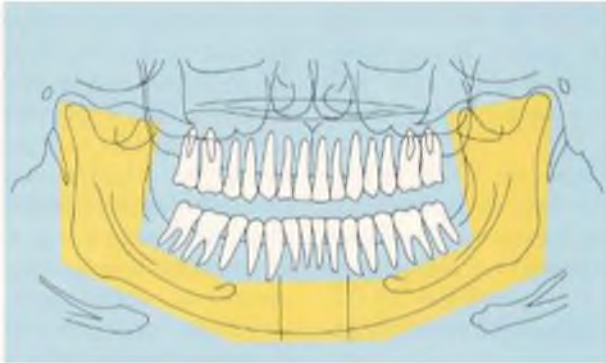


Fig. 49. Mandibular region.

In addition to occlusal radiographs the mandibular posteroanterior radiograph best serves to depict the anterior segment. In special cases, the “unilateral mandibular” technique or computerized tomography may be employed as appropriate to complement panoramic radiography.

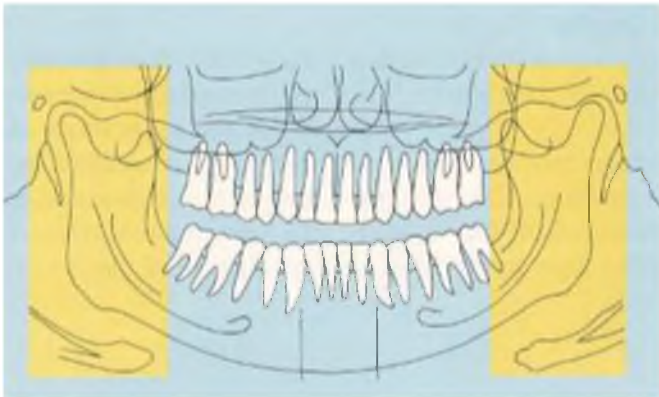


Fig. 50. The temporomandibular joint region, including the retromaxillary and cervical regions.

For more detailed study of the TMJ, spiral tomography and especially computered tomography and MRI are used in addition to conventional radiographs methods.

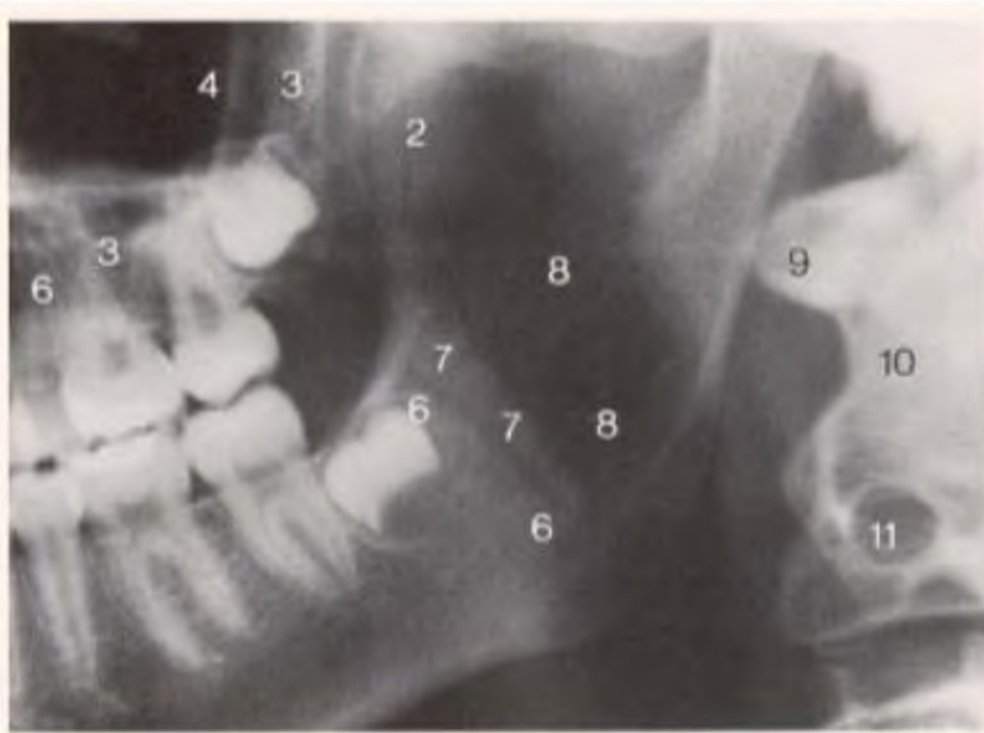

Fig. 51. The region of angle of the mandible and cervical vertebrae

1. Pterygoid process
2. Coronoid process
3. Maxillary sinus (borders)
4. Innominate line (temporal aspect of the zygomatic bone)
5. Major palatine foramen
6. Shadow from the soft tissue of the tongue
7. Shadow from the tissue of the soft palate
8. Air-containing epipharynx
9. Anterior tubercle of the atlas
10. Dens axis
11. Transversal axis foramen

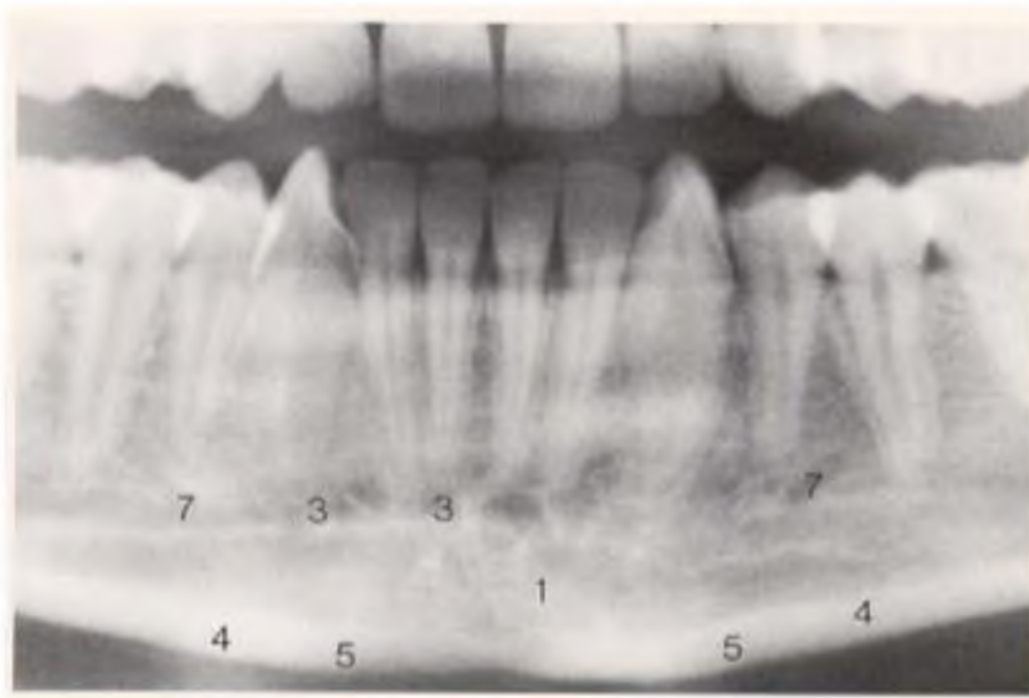


Fig. 52. The mental region.

1. Mental protuberance
2. Mental fovea
3. Shadow of the hyoid bone
4. Compact bone of mandible
5. Mental tubercle
6. Digastric (lingua) foramen
7. Mental foramen
8. Internal mental spine

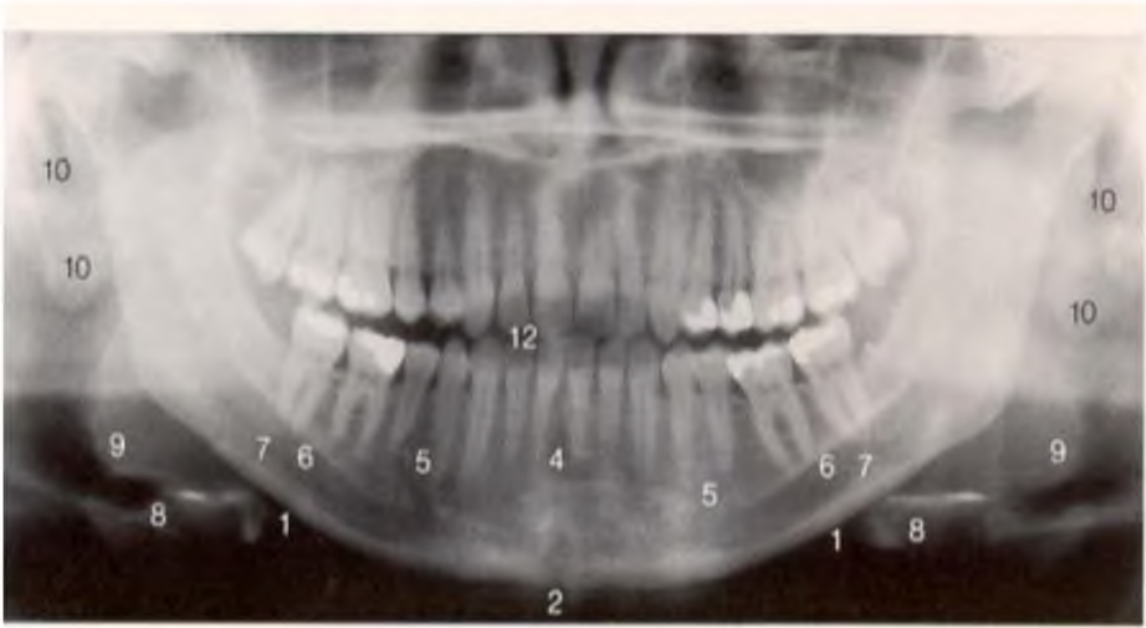

Fig 53. The mandibular region.

1. Compact bone of the mandible
2. Mental protuberance
3. Digastric fovea
4. Mental fovea
5. Mental foramen
6. Mylohyoid line
7. Submaxillary fovea
8. Hyoid bone
9. Base of tongue
10. External auditory opening and soft tissues
11. Small osteoma
12. Radiolucency created by lips.

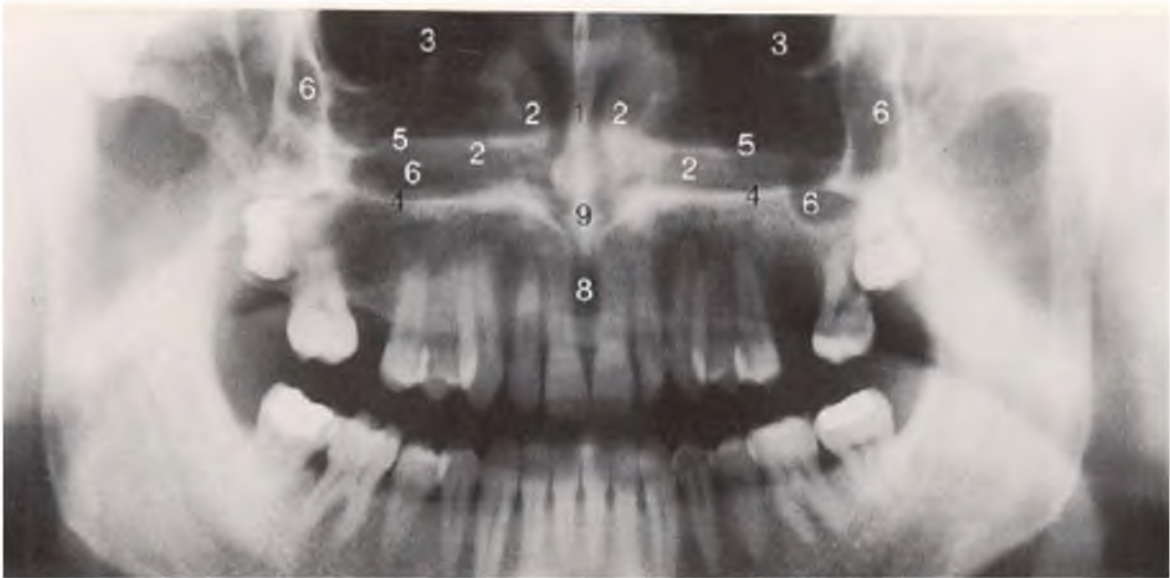


Fig. 54. The structure of the nasal cavity, paranasal sinuses.

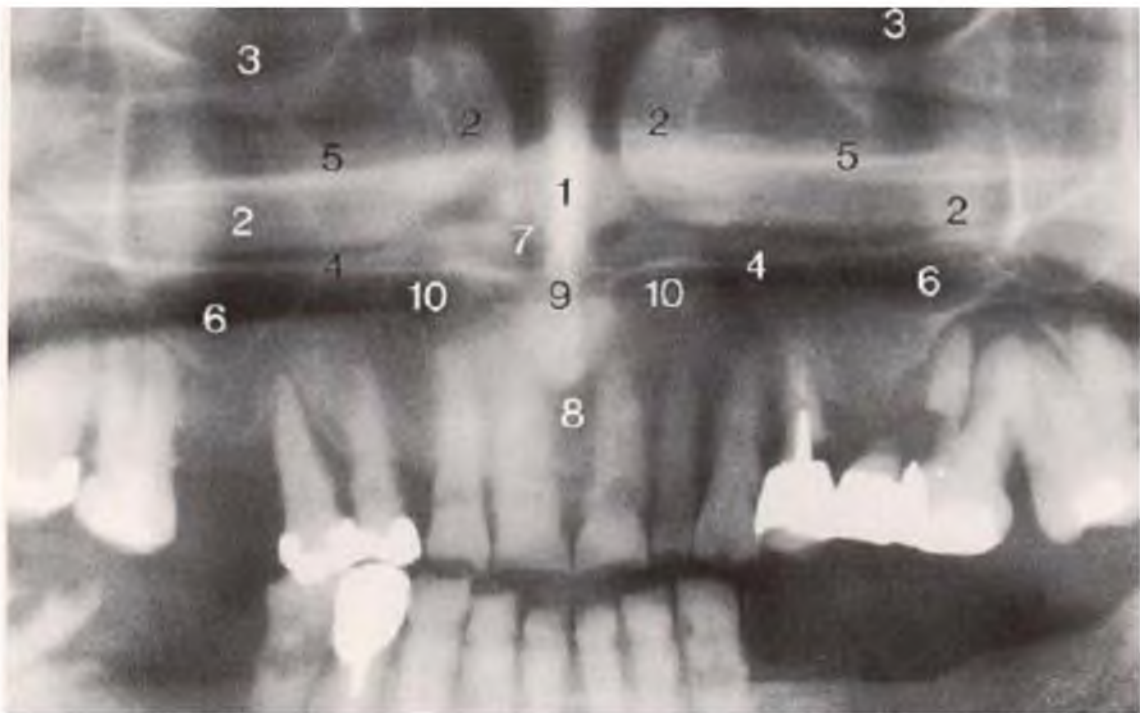


Fig. 55. The structure of the nasal cavity, paranasal sinuses.

1. Nasal septum
2. Inferior nasal concha
3. Orbit with right infraorbital canal
4. Laterobasal border of nasal cavity

5. Horizontal position of the pyramidal bone with the posterior border of nasal cavity
6. Maxillary sinus
7. Nasal entrance into the incisive canal
8. Incisive foramen
9. Anterior nasal spine with the nasal crest of the maxilla
10. Side of the nose.

## CT-SCAN

This is different from an X-ray machine, which sends just one radiation beam. The CT scan produces a more detailed final picture than an X-ray image.

The CT scanner's X-ray detector can see hundreds of different levels of density. It can see tissues within a solid organ./

This data is transmitted to a computer, which builds up a 3-D cross-sectional picture of the part of the body and displays it on the screen.

Sometimes, a contrast dye is used because it can help show certain structures more clearly.

For instance, if a 3-D image of the abdomen is required, the patient may have to drink a barium meal. The barium appears white on the scan as it travels through the digestive system.

If images lower down the body are required, such as the rectum, the patient may be given a barium enema. If blood vessel images are the target, a contrast agent will be injected into the veins.

The accuracy and speed of CT scans may be improved with the application of spiral CT, a relatively new technology. The beam takes a spiral path during the scanning, so it gathers continuous data with no gaps between images.

CT is a useful tool for assisting diagnosis in medicine, but it is a source of ionizing radiation, and it can potentially cause cancer.



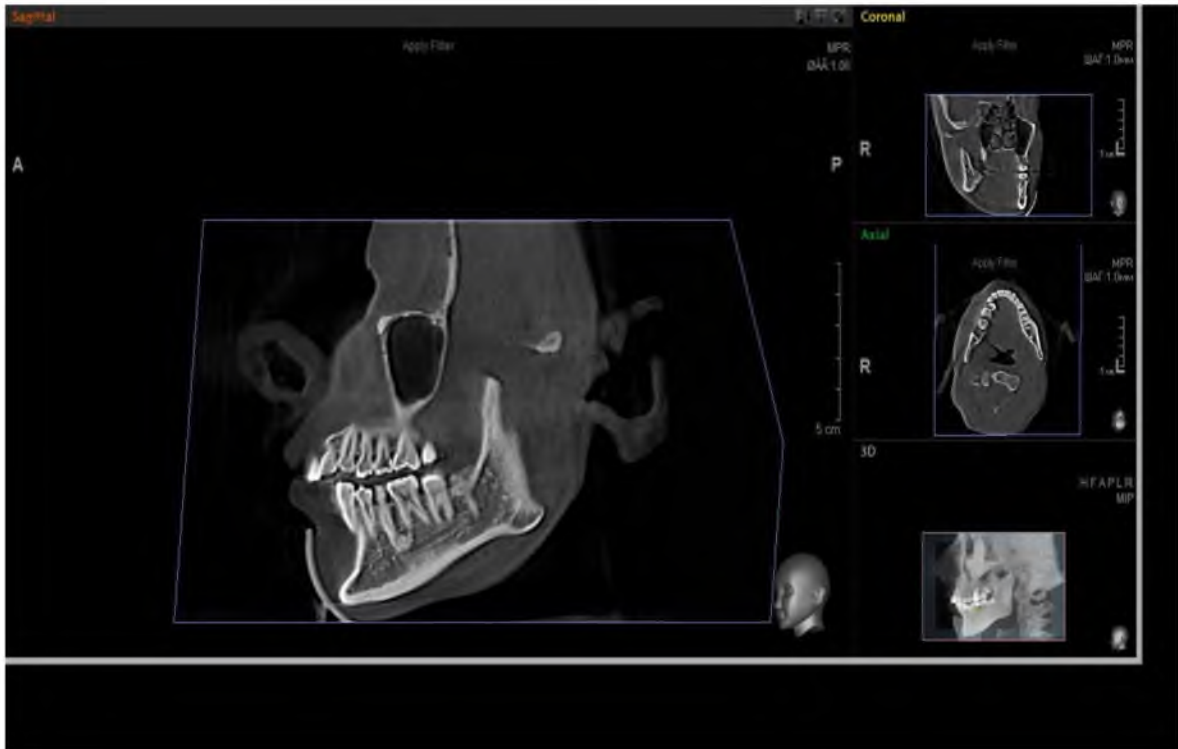

Fig. 56. The CT-scan. The cemenoma from the 45 tooth.

### CT Scanning of the Head

Computed tomography, more commonly known as a CT or CAT scan, is a diagnostic medical test that, like traditional x-rays, produces multiple images or pictures of the inside of the body.

The cross-sectional images generated during a CT scan can be reformatted in multiple planes, and can even generate three-dimensional images. These images can be viewed on a computer monitor, printed on film or transferred to a CD or DVD.

CT images of internal organs, bones, soft tissue and blood vessels provide greater detail than traditional x-rays, particularly of soft tissues and blood vessels.

CT scanning provides more detailed information on head injuries, stroke, brain tumors and other brain diseases than regular radiographs (x-rays).

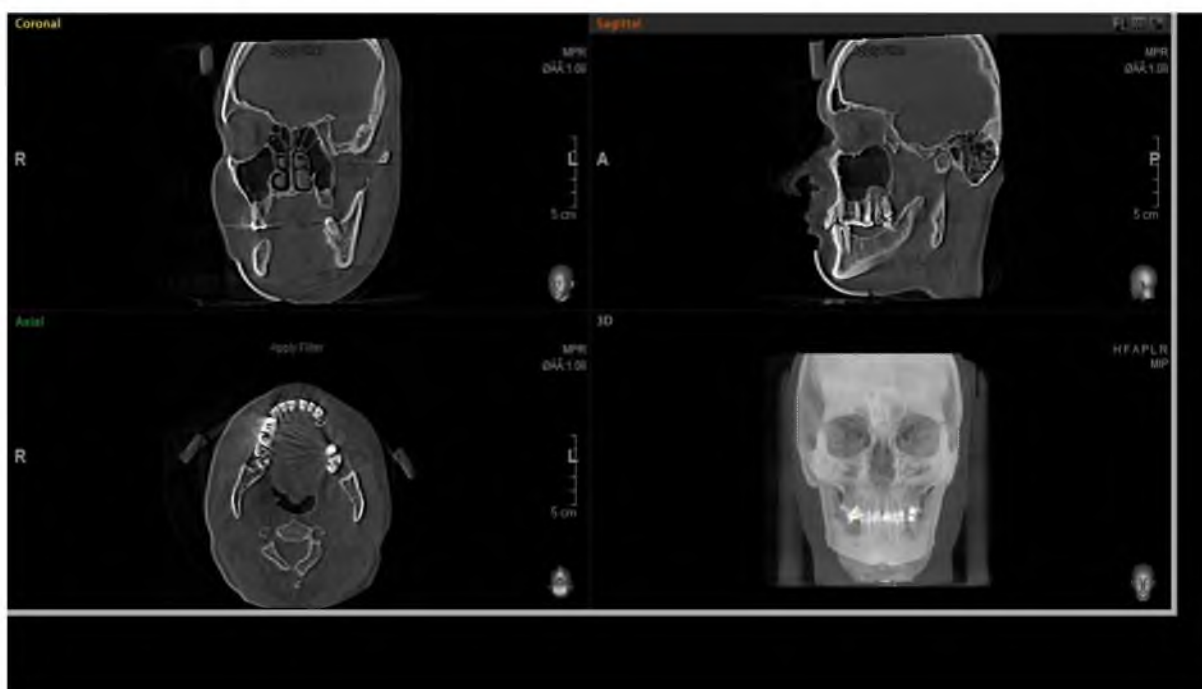

Fig. 57. The CT-scan. The deformity arthrosis of TMJ, the chronic sinusitis of maxillary sinus.

**CT scanning of the head is typically used to detect:**

- bleeding, brain injury and skull fractures in patients with head injuries.
- bleeding caused by a ruptured or leaking aneurysm in a patient with a sudden severe headache.
- a blood clot or bleeding within the brain shortly after a patient exhibits symptoms of a stroke.
- a stroke, especially with a technique called CT Perfusion of the Head.
- brain tumors.
- enlarged brain cavities (ventricles) in patients with hydrocephalus.
- diseases or malformations of the skull.

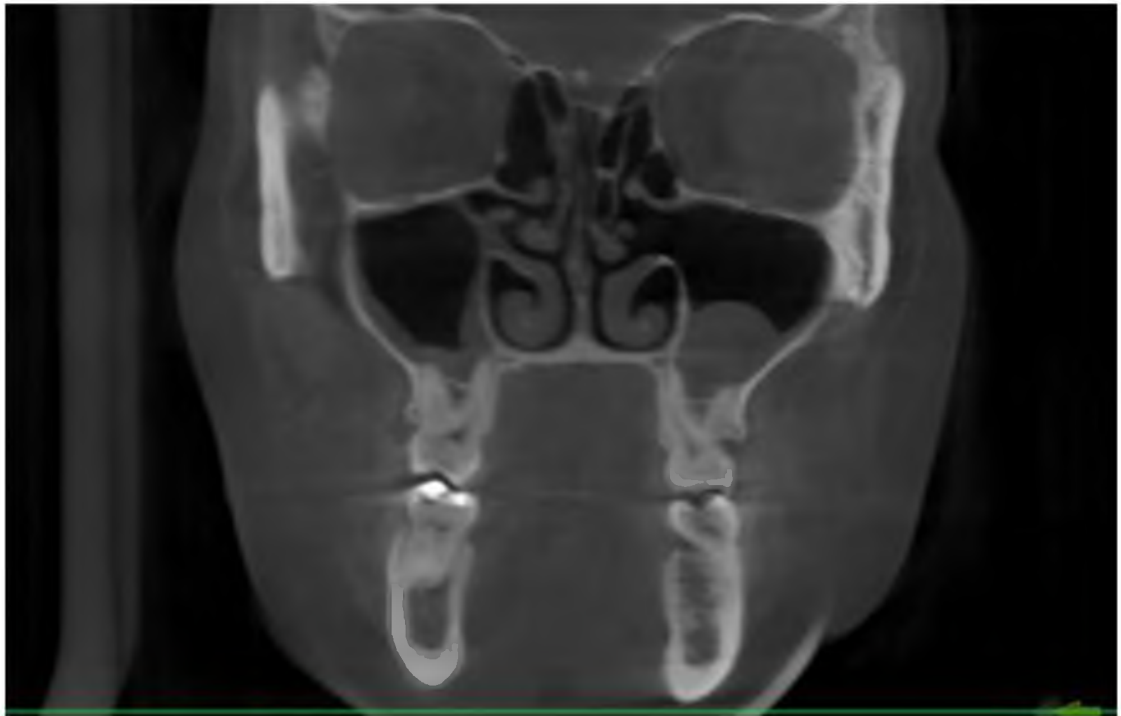


Fig. 58. The CT-scan. The chronic odontogenic sinusitis.

**CT scanning is also performed to:**

- evaluate the extent of bone and soft tissue damage in patients with facial trauma, and planning surgical reconstruction.
- diagnose diseases of the temporal bone on the side of the skull, which may be causing hearing problems.
- determine whether inflammation or other changes are present in the paranasal sinuses.
- plan radiation therapy for cancer of the brain or other tissues.
- guide the passage of a needle used to obtain a tissue sample (biopsy) from the brain.

- assess aneurysms, arteriovenous malformations, and blood vessels through a technique called CT angiography. For more information, see the CT Angiography page.

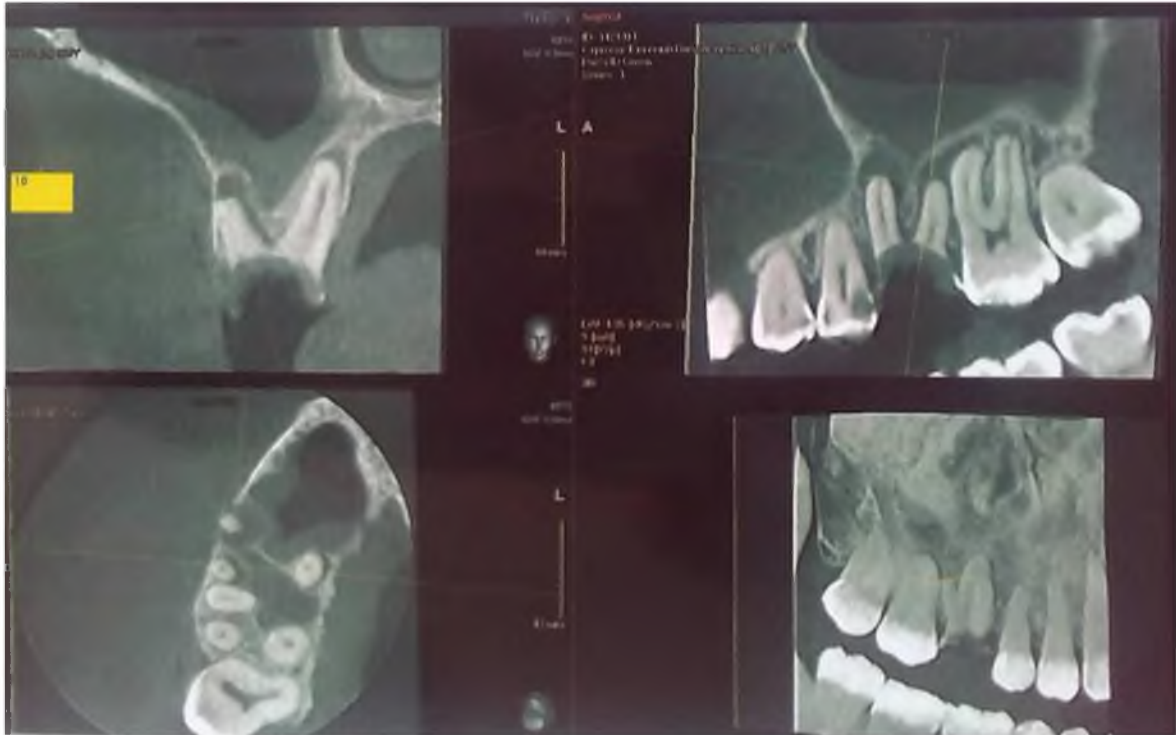


Fig. 59. The CT-scan. The chronic periodontitis complicated by chronic odontogenic sinusitis.

### **Benefits**

- CT scanning is painless, noninvasive and accurate.
- A major advantage of CT is its ability to image bone, soft tissue and blood vessels all at the same time.
- Unlike conventional x-rays, CT scanning provides very detailed images of many types of tissue as well as the lungs, bones, and blood vessels.
- CT examinations are fast and simple; in emergency cases, they can reveal internal injuries and bleeding quickly enough to help save lives.

- CT has been shown to be a cost-effective imaging tool for a wide range of clinical problems.

- 

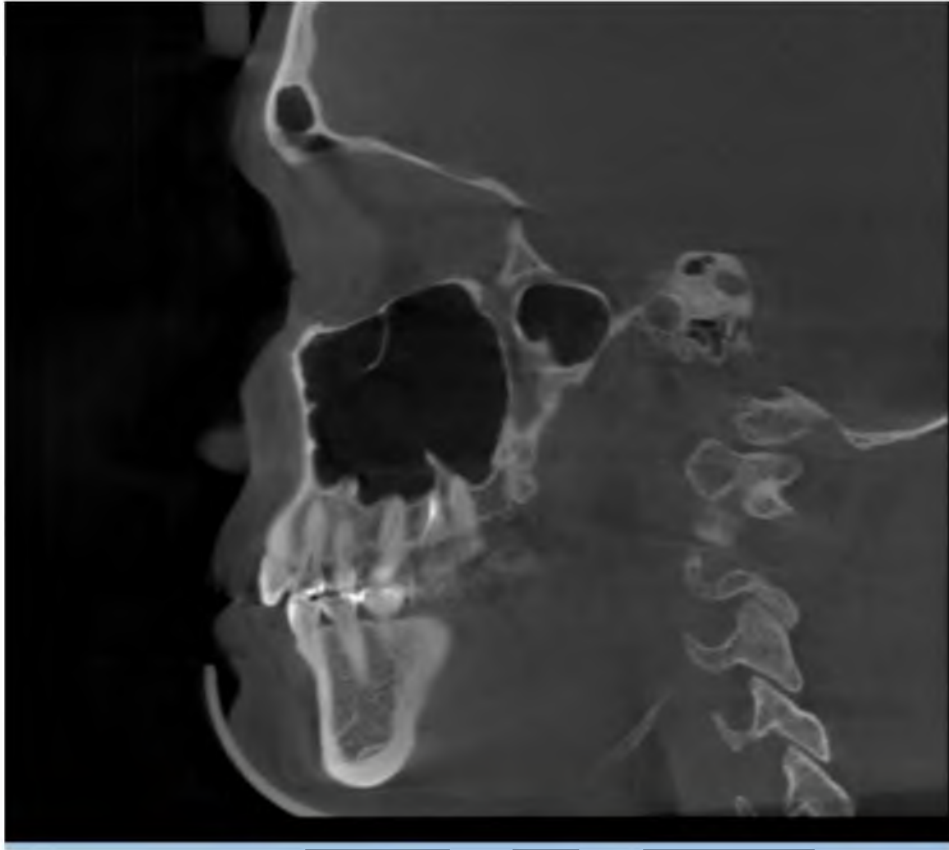


Fig. 60. The CT-scan. The maxillary osteoma.

- CT is less sensitive to patient movement than MRI.
- CT can be performed if you have an implanted medical device of any kind, unlike MRI.
- A diagnosis determined by CT scanning may eliminate the need for exploratory surgery and surgical biopsy.
- No radiation remains in a patient's body after a CT examination.
- X-rays used in CT scans should have no immediate side effects.

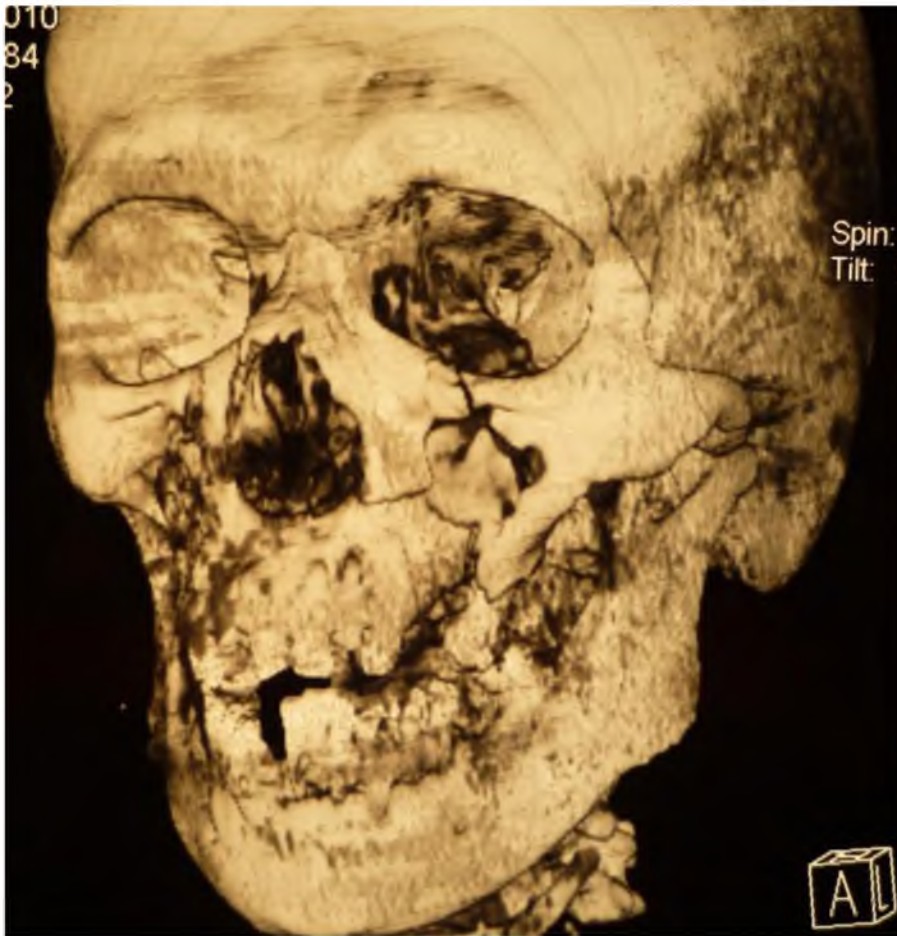

Fig. 61. The CT-scan (3D) at fracture of maxilla.

### **Risks**

This type of X-ray study, like computed tomography (CT), is an economically viable, easily executable and at the same time highly informative diagnostic method, and is therefore widely used both in children and adults. The popularity of CT scans around the world has increased significantly over the past decades: in particular, in the US from 1980 to 2006, the number of CT cases increased from 3 million to 60 million per year (in the latter case, 7 million of them were carried to children).

In children under the age of 16, approximately 80% of cases of CT scan of the head, while after 16 years, this figure is reduced to 40% with an increase in the percentage of CT of the chest, abdomen and pelvis. In this case, most often the motives for sending children to the CT of the head are injuries, suspicions of neoplasms and congenital anomalies.

The dose of irradiation received by the patient during the passage of CT depends on the size of the patient and the area of the body being examined. For example, according to P.C. Shrimpton and co-authors (2006), who studied about  $\frac{1}{4}$  of all CT devices in the UK, with the CT of the infant's first year of life, the absorbed dose is up to 28-34 mGy, the child at the age of 5 years - up to 42-50 mGy, 10 years - up to 52-68 mGy (in terms of the upper limit of the third quartile). It is assumed that such a dose is relatively safe, that is, the diagnostic value of CT exceeds the risk of potential side effects.

However, the results of a cohort retrospective study published in the online version of the journal Lancet indicate that a child who underwent CT and received a dose of about 50 mGy has a 3-fold higher risk of developing leukemia, and those who received a dose of about 60 mGy, is almost 3 times higher than the risk of malignant neoplasms of the brain.

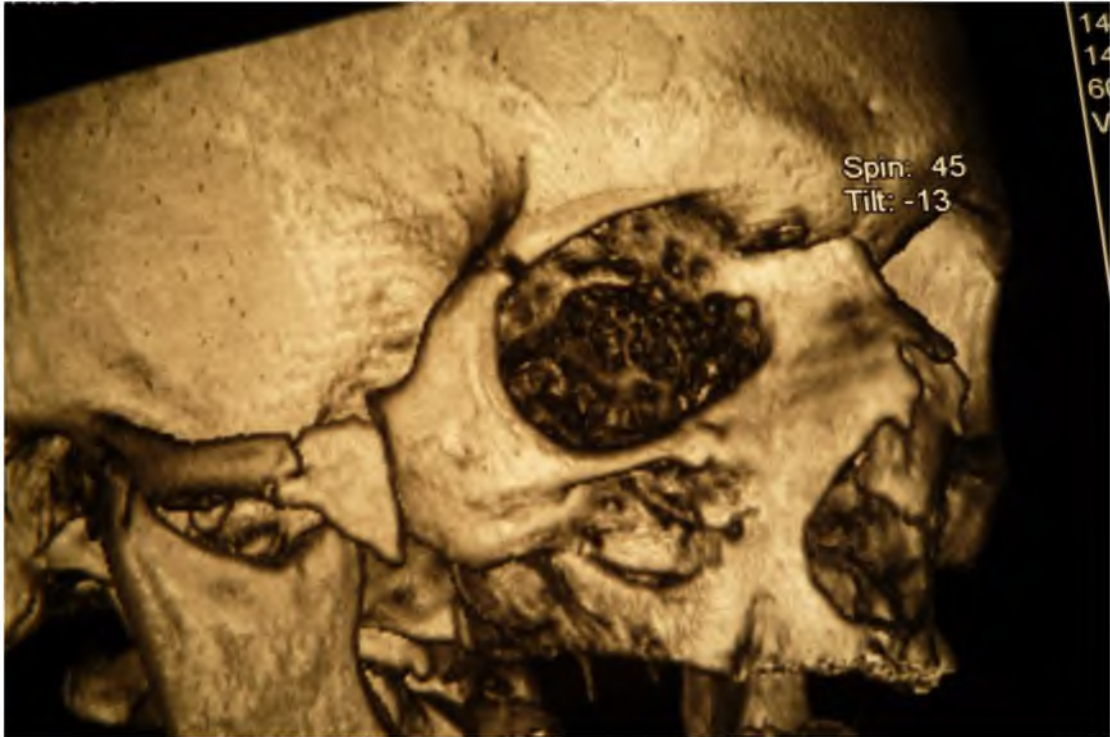


Fig. 62. The CT-scan (3D) at fracture of zygomatic bone.

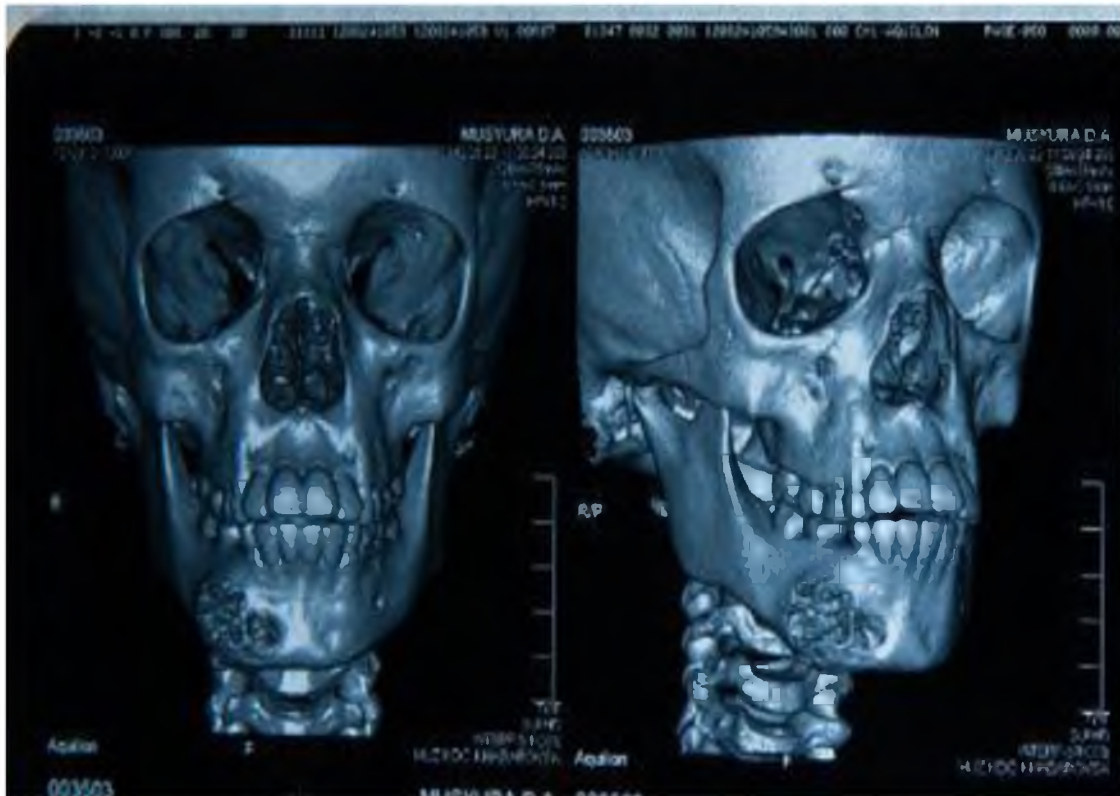
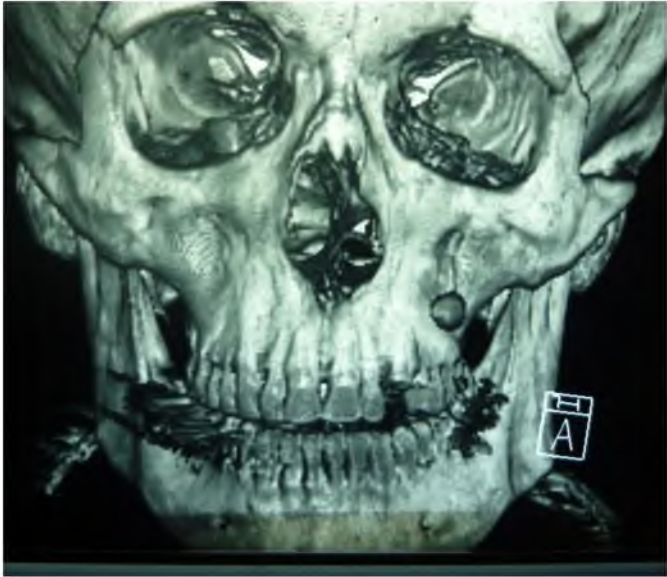
Fig. 63. The CT-scan (3D). The osteoblastoclastoma of mandible





- Fig. 64. The CT-scan(3D) at gunshot wound of face. The presents of foreing body (pule).

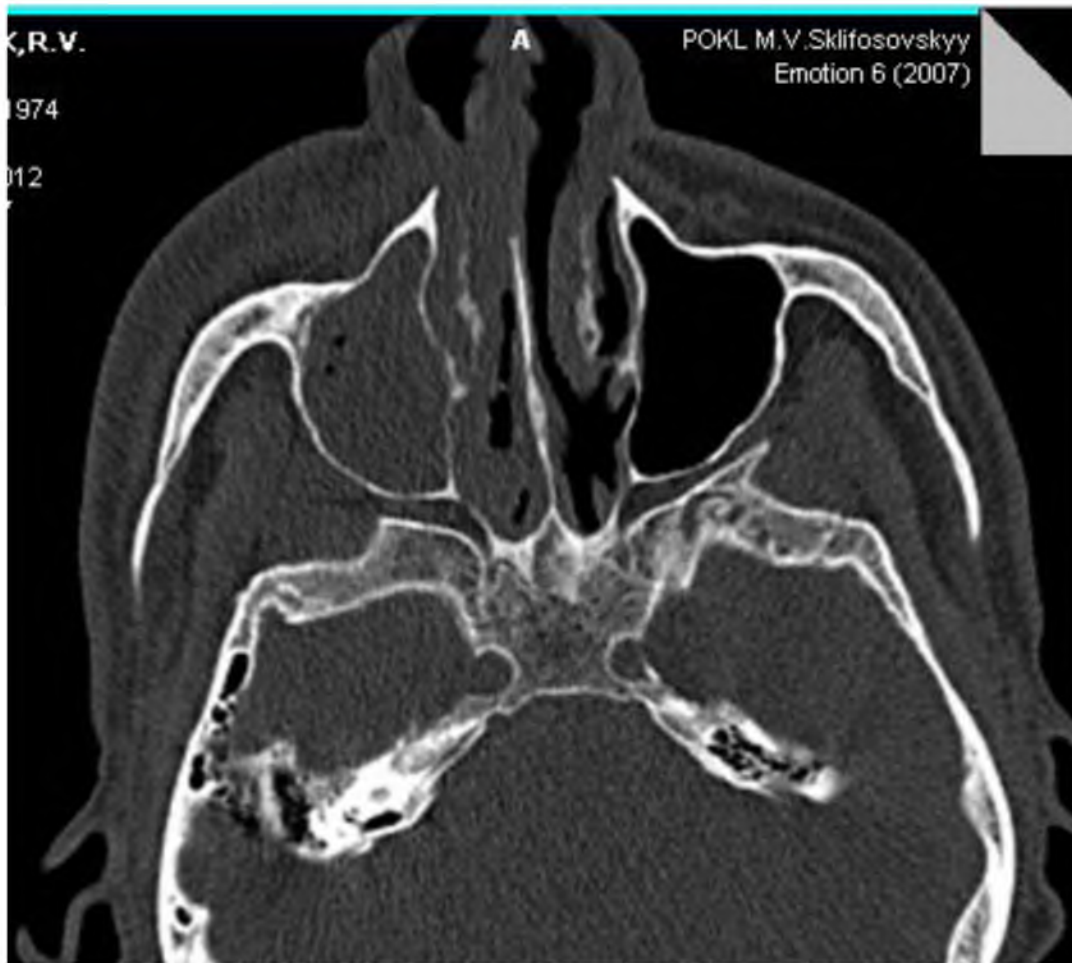

Fig. 65. The CT at chronic odontogenic sinusitis.

### **Contraindications for CT**

The study on a computer tomograph has many advantages (efficiency of carrying out, informative, possibility of application at emergency conditions), but not all patients can safely do it.

Do not perform the procedure when:

- pregnancy and lactation period in women;
- weight of the patient over 140-150 kilograms (due to the physical capabilities of the apparatus);
- renal dysfunction and allergic reaction to contrast in the examination with strengthening;

- claustrophobia and mental disorders;
- diseases and pathological conditions that do not allow to keep the body in a fixed position;
- The presence of gypsum or structures of metal in the area under investigation;
- myeloma disease.

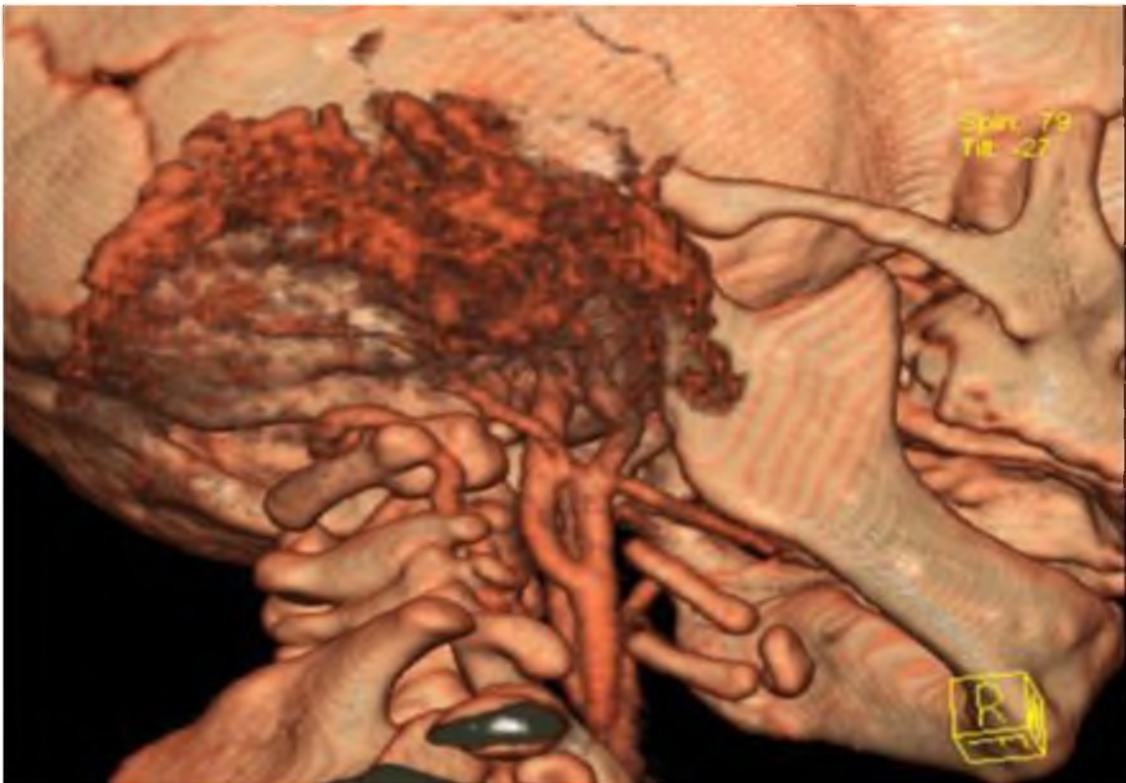


Fig. 66. The contrast CT-scan. The cavernouse hemangioma.

## MRI SCAN

An magnetic resonance imaging scan uses a large magnet, radio waves, and a computer to create a detailed, cross-sectional image of internal organs and structures.

The scanner itself typically resembles a large tube with a table in the middle, allowing the patient to slide in.

An MRI scan differs from CT scans and X-rays, as it does not use potentially harmful ionizing radiation.

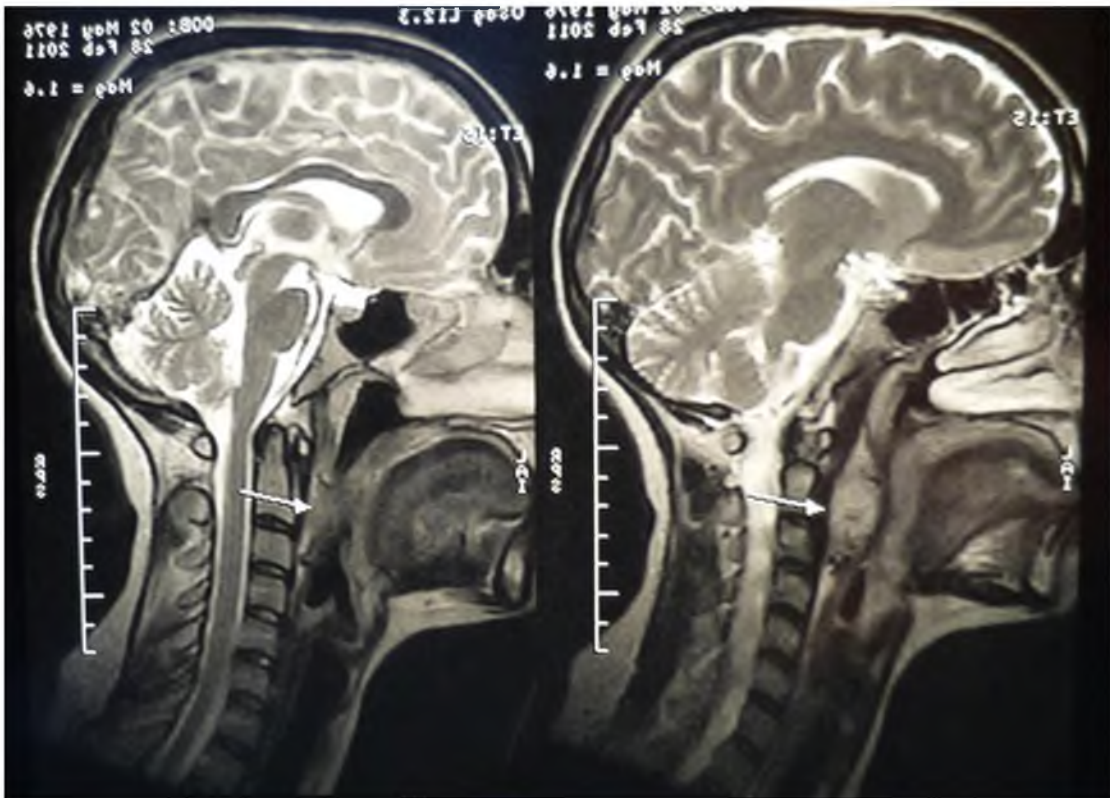


Fig. 67. The MRI of the head and neck. The angioma of neck

## Magnetic resonance imaging (MRI) scan definition and facts

- Magnetic resonance imaging or MRI scanning uses magnetism, radio waves, and a computer to produce images of body structures.
- MRI scanning is painless and does not involve x-ray radiation.
- Patients with heart pacemakers, metal implants, or metal chips or clips in or around the eyes cannot be scanned with MRI because of the effect of the magnet.
- Claustrophobic sensation can occur with MRI scanning.

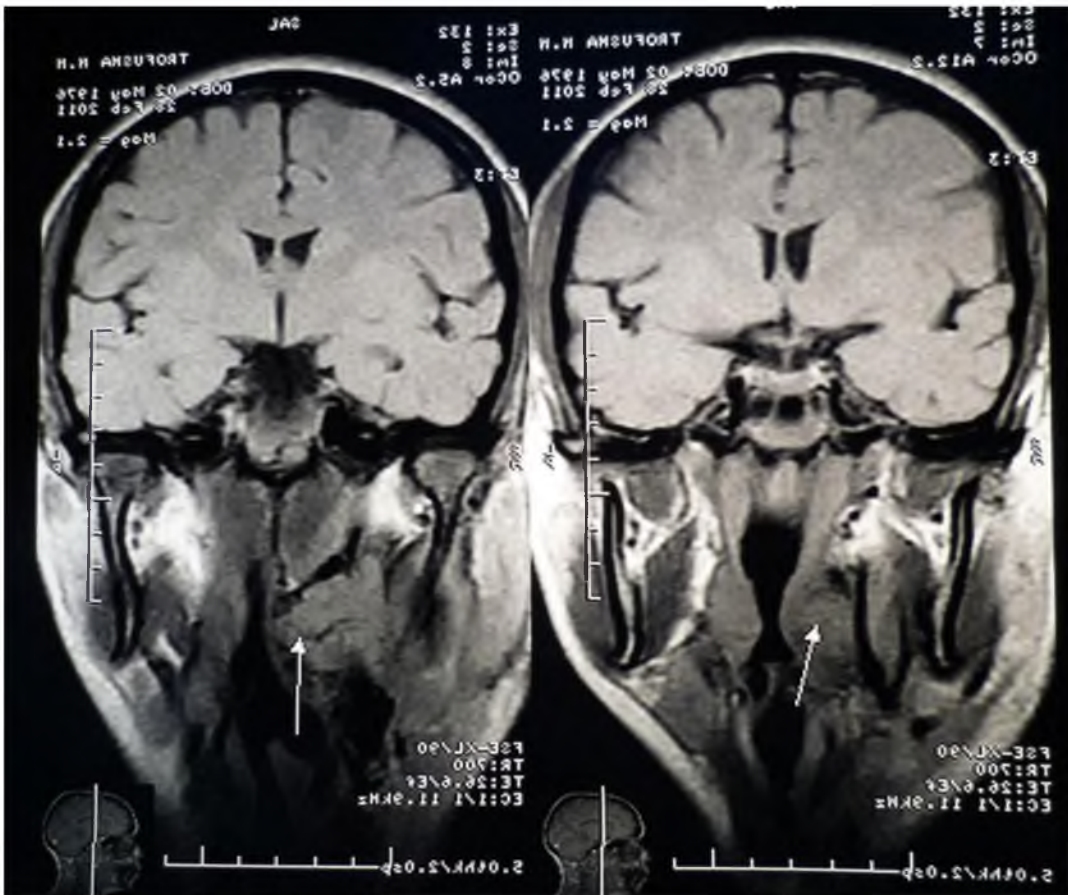


Fig. 68. The MRI of the head and neck. The angioma

An MRI or magnetic resonance imaging is a radiology technique scan that uses magnetism, radio waves, and a computer to produce images of body structures. The MRI scanner is a tube surrounded by a giant circular magnet. The patient is placed on a moveable bed that is inserted into the magnet.

The magnet creates a strong magnetic field that aligns the protons of hydrogen atoms, which are then exposed to a beam of radio waves. This spins the various protons of the body, and they produce a faint signal that is detected by the receiver portion of the MRI scanner. A computer processes the receiver information, which produces an image.

MRI image and resolution is quite detailed, and it can detect tiny changes of structures within the body. For some procedures, contrast agents, such as gadolinium, are used to increase the accuracy of the images.

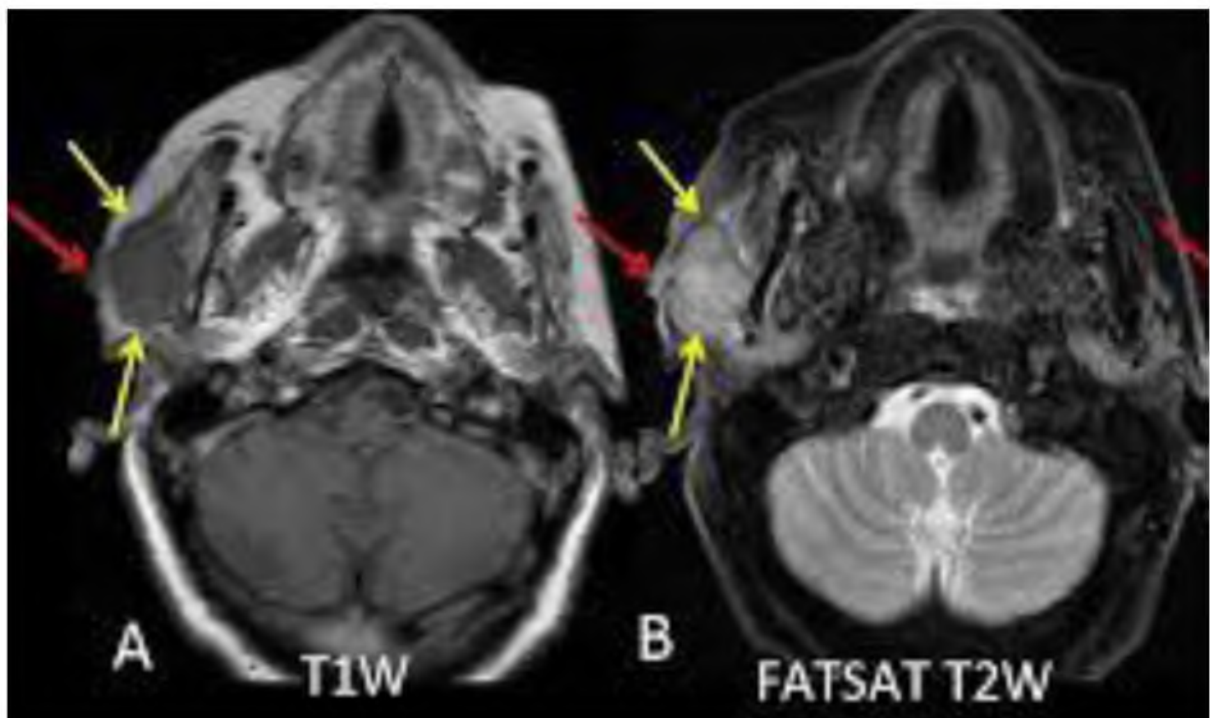


Fig. 69. The MRI at polymorphic adenoma of parotid salivary gland.

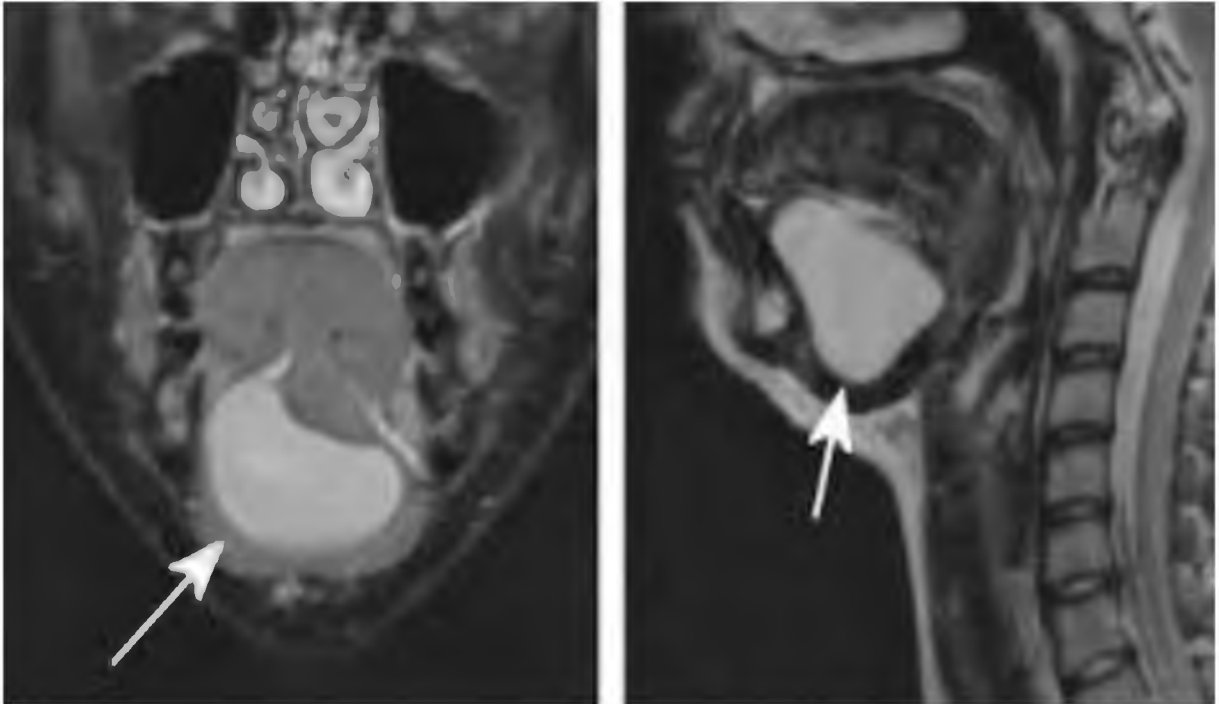


Fig. 70. The MRI at ranula (retention cyst of sublingual salivary gland).

### **What are the uses for an MRI?**

An MRI scan can be used as an extremely accurate method of disease detection throughout the body and is most often used after the other testing fails to provide sufficient information to confirm a patient's diagnosis. In the head, trauma to the brain can be seen as bleeding or swelling. Other abnormalities often found include brain aneurysms, stroke, tumors of the brain, as well as tumors or inflammation of the spine.

Neurosurgeons use an MRI scan not only in defining brain anatomy, but also in evaluating the integrity of the spinal cord after trauma. It is also used when considering problems associated with the vertebrae or intervertebral discs of the spine. An MRI scan can evaluate the structure of the heart and aorta, where it can detect aneurysms or tears. MRI scans are not the first line of imaging test for these issues or in cases of trauma.

It provides valuable information on glands and organs within the abdomen, and accurate information about the structure of the joints, soft tissues, and bones of the body. Often, surgery can be deferred or more accurately directed after knowing the results of an MRI scan.

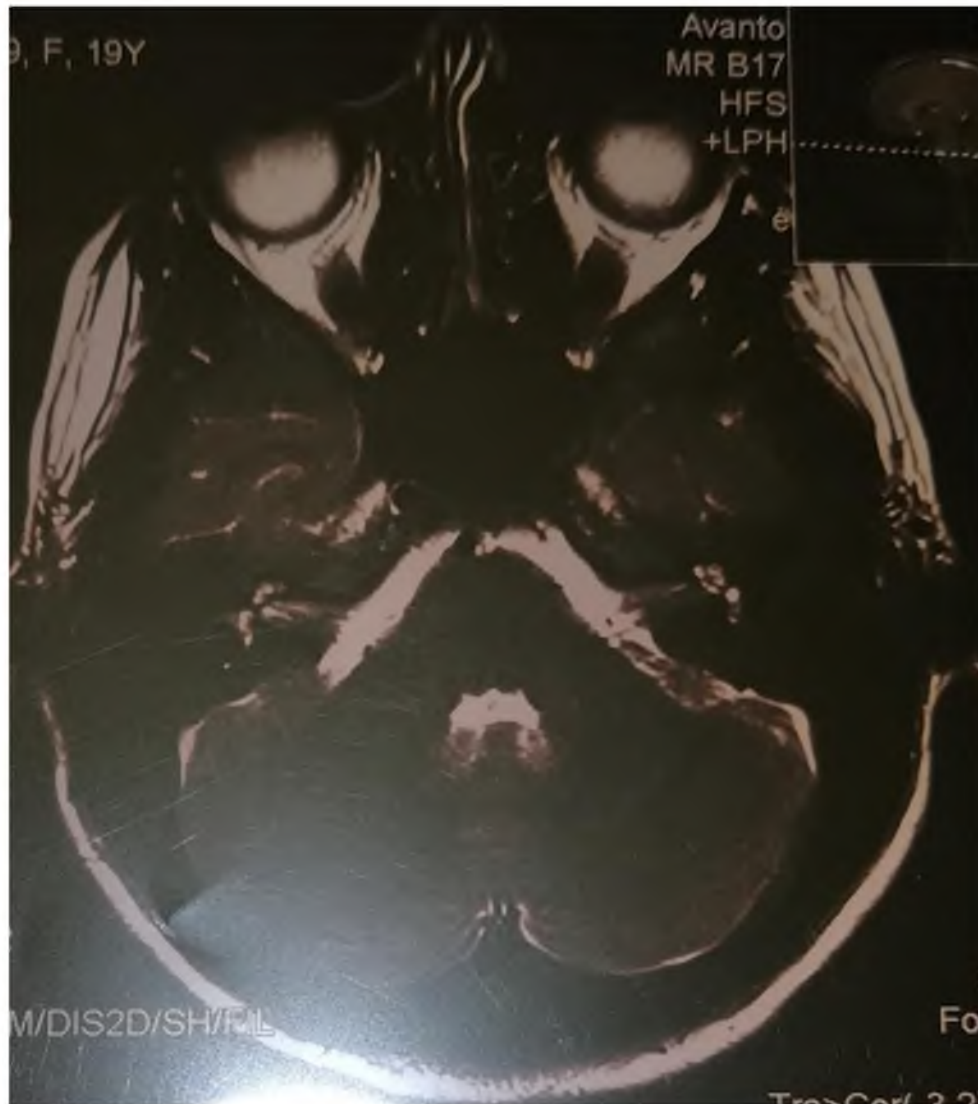


Fig. 71. The MRI at contortion of septum nasi.



## **Risks during examination of MRI**

So far, there are no known harmful effects from the action of the strong magnetic field used for MRI. But the magnet is very powerful. A magnet can affect pacemakers, artificial limbs, and other medical devices that contain iron. Any freely lying metal object can cause damage or harm due to the force of attraction of a powerful magnet.

Metal fragments in the eye can lead to damage to the retina. If you have a damaged eye fragment or a small object, then pre-render an X-ray. If a metal is found in the image, then the MRI is strictly prohibited.

Iron tattoo pigments or permanent eyeliner may cause skin or eye irritation.

MRI can cause burns of some medicinal plasters. Be sure to tell your doctor if you are wearing this.

There is a small risk of an allergic reaction to a contrast agent. But most of the reactions are easy and can be cured with medications.

## **How different are the different types of research (KT and MRI)?**

What is the fundamental difference?

Both studies allow for detailed, layer-by-layer diagnostics of the organism, in this their main similarity. And the principle of their effect is different: computed tomography is a method based on x-ray radiation, and the basis of MRI is the effect of the magnetic field.

Basically, these two methods solve the same problem: the creation of a three-dimensional image of the organ. But MRI better shows soft tissue, it is used to detect tumors, brain, spine, joints, pelvis. CT scan shows trauma,

fractures, fresh hemorrhages, pathologies of the abdominal cavity and chest. Therefore, CT is currently more of a method of urgent, "quick-help" diagnosis, MRI is more often used in outpatient practice.

## ULTRASOUND IMAGING

Ultrasound of the vessels of the head and neck.

A modern method of diagnosing blood flow in blood vessels that supply blood to the brain. Ultrasound can accurately assess the state of patency of extracranial vessels (outside the cranial vertebral and carotid arteries), and vessels that permeate the brain tissue (the three types of arteries are the anterior, middle, posterior).

It should be noted that the ultrasound procedure will not allow to obtain a complete picture of the vessel's condition and to determine the possibility of identifying key factors of vascular obstruction. Such ailments, as thrombosis, stenosis, spasms, the formation of atherosclerotic plaques, require additional procedures for examining the vascular system in the neck and head.

### **Indications for ultrasound of the brain and neck**

Conducting this type of study is recommended:

- people who have problems with cerebral circulation (in acute or chronic form);
- patients who suffered a vascular injury due to craniocerebral injury and neurosurgical operation);
- after toxic vascular injury;
- after diagnosing asymmetry or lack of pulse, arterial pressure in the upper limbs (arms);
- with pronounced noise on the aortic arch;
- with a sharp loss of vision;

- a different spectrum of pathologies in the cervical spine (after diagnosing osteochondrosis, trauma, congenital anomalies, and postural disorders), provided that there is a threat of compression of the vertebral artery and a violation of blood supply in the region of the spinal cord.
- **Ultrasound of the vessels of the brain and neck, the price** of which is optimal for patients of different financial possibilities - an available screening procedure of ultrasound should be repeated from time to time for a re-examination of patients with atherosclerosis and other pathologies of the head vessels. In the risk group of cerebral vascular diseases there are people with bad habits (smoking), with excess weight, suffering from hypertensive and ischemic heart disease.
- 
- Ultrasound diagnosis allows early detection of blood flow disorders to the brain tissues. Oxygen starvation of tissues leads to aggravation of the condition. On time, ultrasound will prevent a stroke of the brain. US-screening is recommended for monitoring patients suffering from vascular pathologies and comparing the results of vascular conditions after the course of treatment.
- 
- Ultrasound gives the expert important information about the patency of arterial vessels, which are responsible for feeding the brain - the price of the data is immense. The doctor can quickly identify violations of outflow of blood from the cranial cavity, which are fraught with lethal consequences. The neurologist diagnoses the degree of development of collateral and venous pathology by the results of diagnosis. The ultrasound shows the branching of the vascular system, the data on the presence of arteriovenous malformation and the violation of the

patency of the vessel. The information obtained is important for the subsequent choice of effective therapy.

- **Preparation of the patient for ultrasound of the vessels of the head and neck.**

- Despite the fact that ultrasound of the vessels of the brain and neck is an affordable procedure for the price, the patient needs to take into account some nuances for maximum truthfulness of the result.

- 

- On the day of the procedure the patient is advised:

- 

- interrupt the use of medications or restrict them if the treatment can not be canceled due to the presence of other diseases;

- avoid drinking tea or coffee (caffeinated drinks);

- refrain from smoking cigarettes within two hours before the procedure.

- It is important to adhere to these rules to avoid the occurrence of an increased vascular tone.

- 

- For the accuracy of the result, it is desirable to remove jewelry from the head and neck area.

- **Methods of ultrasound of the vessels of the head and neck**

- In the office near the device there is always a comfortable couch for relaxing the client. The procedure should not cause discomfort or pain. The doctor-ultrasound places the sensor of the device on the patient's skin for directing ultrasound into the area of passage of blood vessels requiring diagnosis.

-

- If there is insufficient blood flow in the vessel, the Doppler effect will not be displayed on the screen of the device. Computer processing of digital data allows you to evaluate the graph of blood flow through the vessel in real time. Ultrasound of the vessels of the brain and neck often involves the carrying out of additional functional tests:
  - 
  - hyperventilation;
  - finger pressing;
  - finger pressing;
  - This helps to more accurately diagnose the mechanism of blood flow regulation.
  - 
  - For severe patients, the procedure of prolonged dopplerography is applied - ultrasound signals are converted into sound signals. After listening to the data, a specialist is able to accurately assess the blood flow in the region of the neck or head being examined. This will allow to quickly detect clogging or narrowing of the vessel, determine the degree of violation of the transportation of blood through the circulatory system.
  - 
  - The time of ultrasound diagnosis varies within 30-45 minutes. Portable dopplerography takes three times less time.

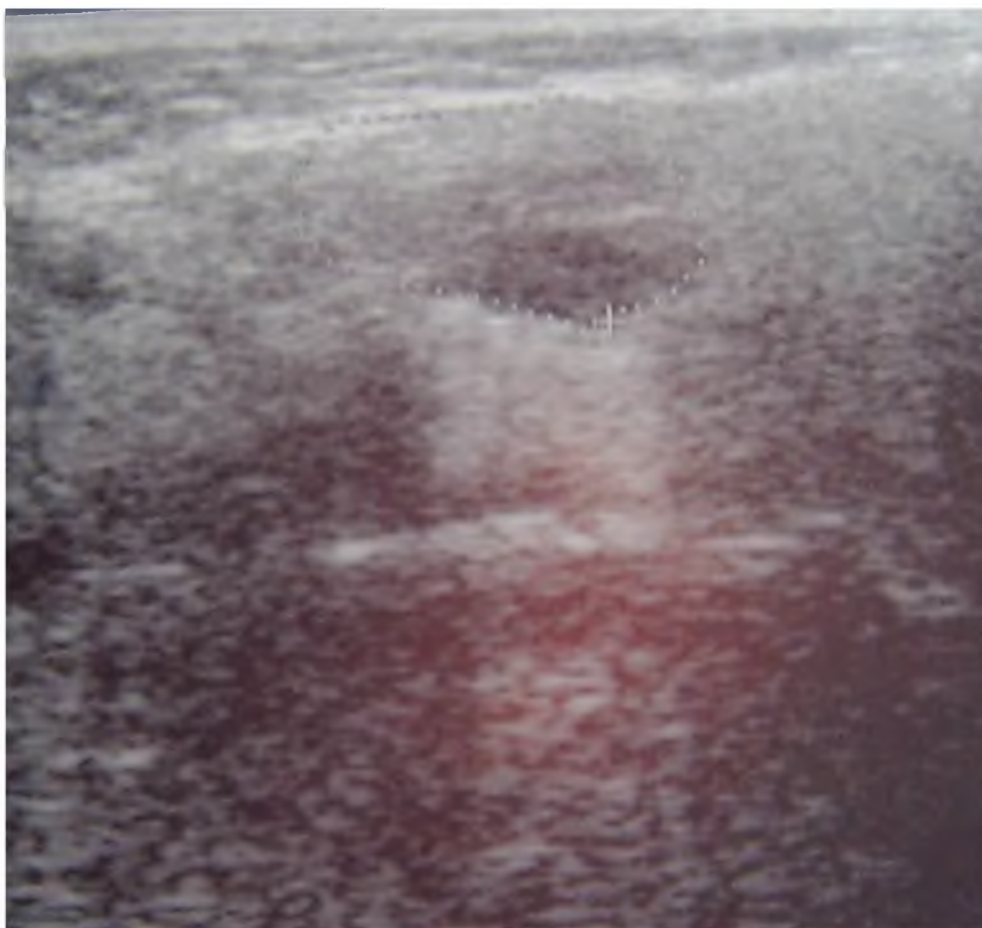


Fig. 72. The USI of lymphadenitis of maxillofacial area.

### **Contraindications to the procedure of ultrasound of the vessels of the head and neck**

For ultrasound, there are no age restrictions. Ultrasound waves are absolutely safe for humans. During the long-term treatment of vascular diseases, the procedure can be applied several times in a row.

The procedure can be difficult to implement if the diseased vessel is closed with bone tissue or a large layer of subcutaneous fat. Difficulties in carrying out diagnostics with the help of ultrasonic waves arise in patients with arrhythmia and cardiac pathologies, in patients with slow blood flow.

It is impossible to carry out the procedure in areas of damaged skin - this makes it impossible to attach the sensor of the device. It is advisable to wait for healing and only after that do ultrasound.

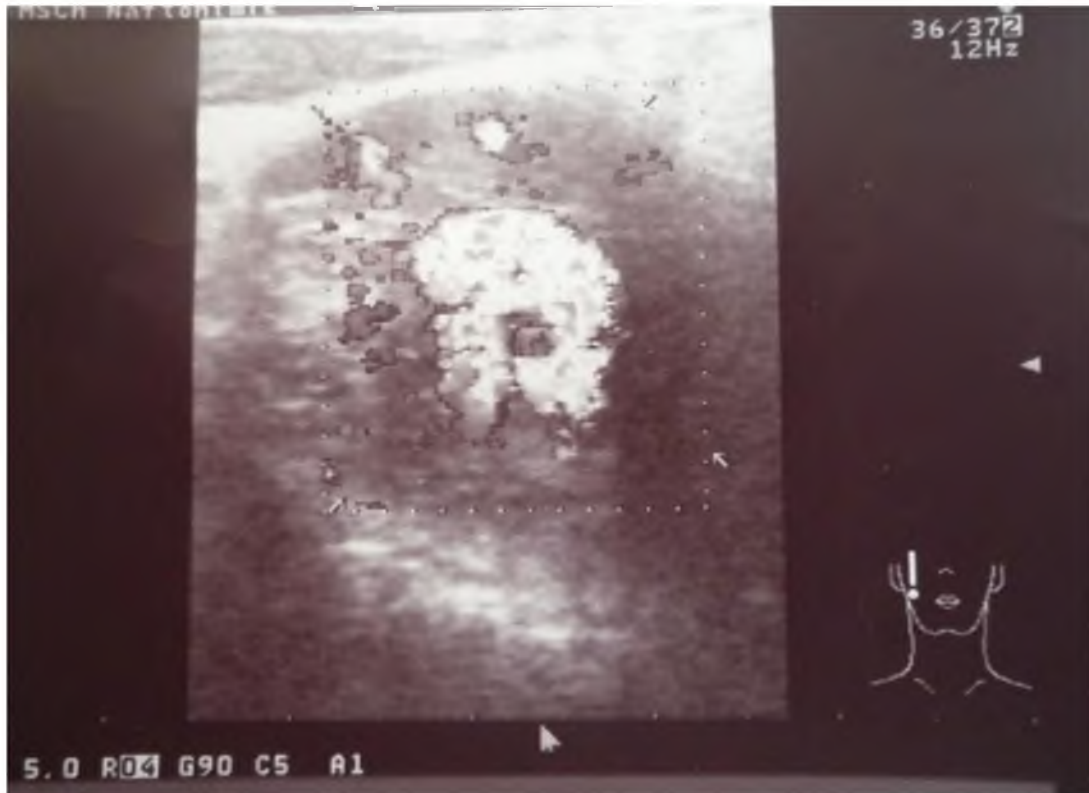


Fig. 73. The USI of lymphatic nodule limphadenopatya

### **Risks**

For standard diagnostic ultrasound, there are no known harmful effects on humans.



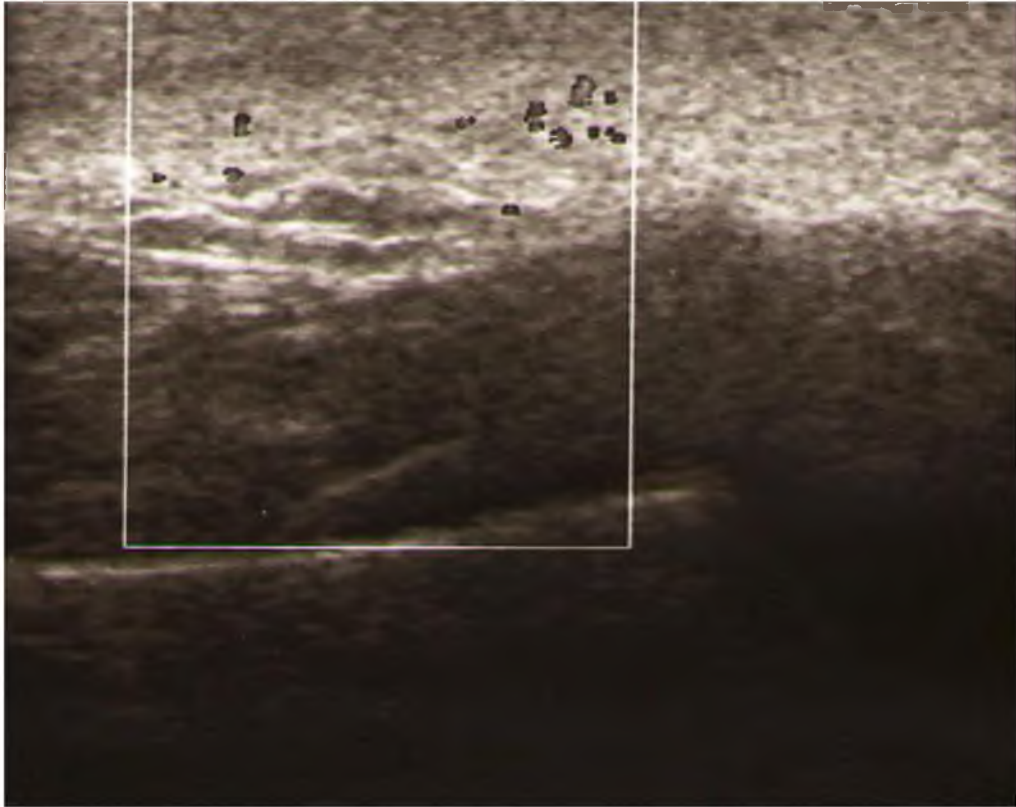


Fig. 74. The USI of keloid scar of maxillofacial localization.

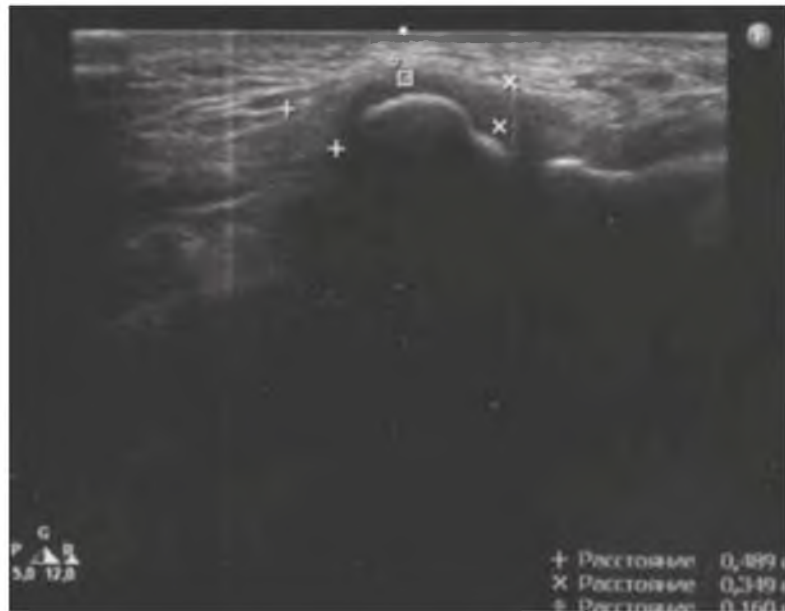


Fig. 75. The USI of TMJ.

## ARTHROSCOPY

Arthroscopy, as a method of eliminating dysfunction of the temporomandibular joint, is used last, when other methods of treatment proved ineffective. In this pathology, the patient experiences acute pain, which significantly reduces the quality of his life and leads to temporary disability.

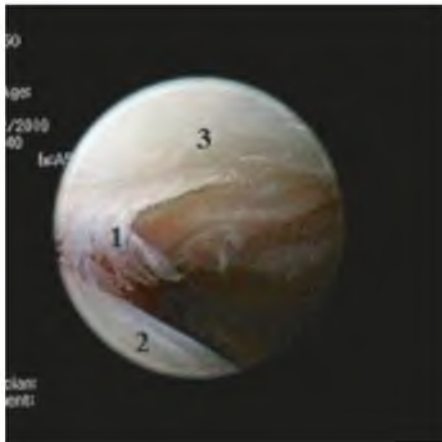


Fig. 76. The arthroscopy of temporamandibular joint.

Arthroscopy is performed with the following changes in the temporomandibular joint area:

Proliferation of connective tissue;

Displacement or misposition of the joint;

Perforation of bone;

The presence of bone fragments inside the jaw joint.



Fig. 77. The arthroscope.

In addition to arthroscopy, with dysfunction of the jaw joint, arthroplasty (open surgical procedure with articulation adjustment) and endoprosthesis (replacement of parts of the joint with artificial implants) can be used.

After the arthroscopy of the jaw joint is achieved:

Pain relief in articulation;

Elimination of structural changes;

Restoration of motor activity of the jaw.

Arthroscopy of the TMJ is used in an extreme case, since after the operation, the joint function is not restored in 100% of cases, and sometimes its deterioration is observed. However, with serious chronic changes that lead to disability and are not eliminated by non-surgical measures, arthroscopy is prescribed.

## DERMATOSCOPY

DERMATOSCOPY is considered to be the stethoscope or the third eye to a dermatologist to detect sub-surface features not visible to the unaided eye. The device was evolved primarily to detect melanomas and to get biopsy of suspicious lesions. Recently it has found application in diagnosis of papulosquamous disorders, pigmentary disorders other than melanoma and other benign conditions. However, there is paucity of data in literature regarding image differences between various dermatoscopes

Dermatoscopy refers to the examination of the skin using skin surface microscopy, and is also sometimes called ‘epiluminoscopy’ and ‘epiluminescent microscopy’. Dermoscopy is mainly used to evaluate pigmented lesions in order to distinguish malignant skin lesions, such as melanoma and pigmented basal cell carcinoma, from benign melanocytic naevi and seborrhoeic keratoses.

Dermoscopy requirements include a high quality lens for 10 to 14-times magnification and a lighting system (a dermatoscope). This enables visualisation of subsurface structures and patterns. Hand-held devices are usually lightweight and battery-powered.

Fluid immersion and polarised dermatoscopes are available.

- Fluid immersion involves applying mineral oil or spraying alcohol onto the lesion, then placing the lens in contact with the skin. These systems have the advantage of accurate focus but the disadvantage of compressing the vasculature. The plate needs to be cleaned between lesions,

and should be sterilised after each patient using alcohol. Alternatively, the lens can be covered with a fresh piece of polyvinyl film (cling food wrap) between each patient.

- Polarised lenses do not need to be in contact with the skin. They can be quickly scanned over many lesions. In general, the polarised view is as good as the fluid immersion technique, and may be better for evaluating vessels. However, it may be helpful to wipe a scaly lesion with oil to enhance the view. Surface scale may also be removed by repeated tape stripping.

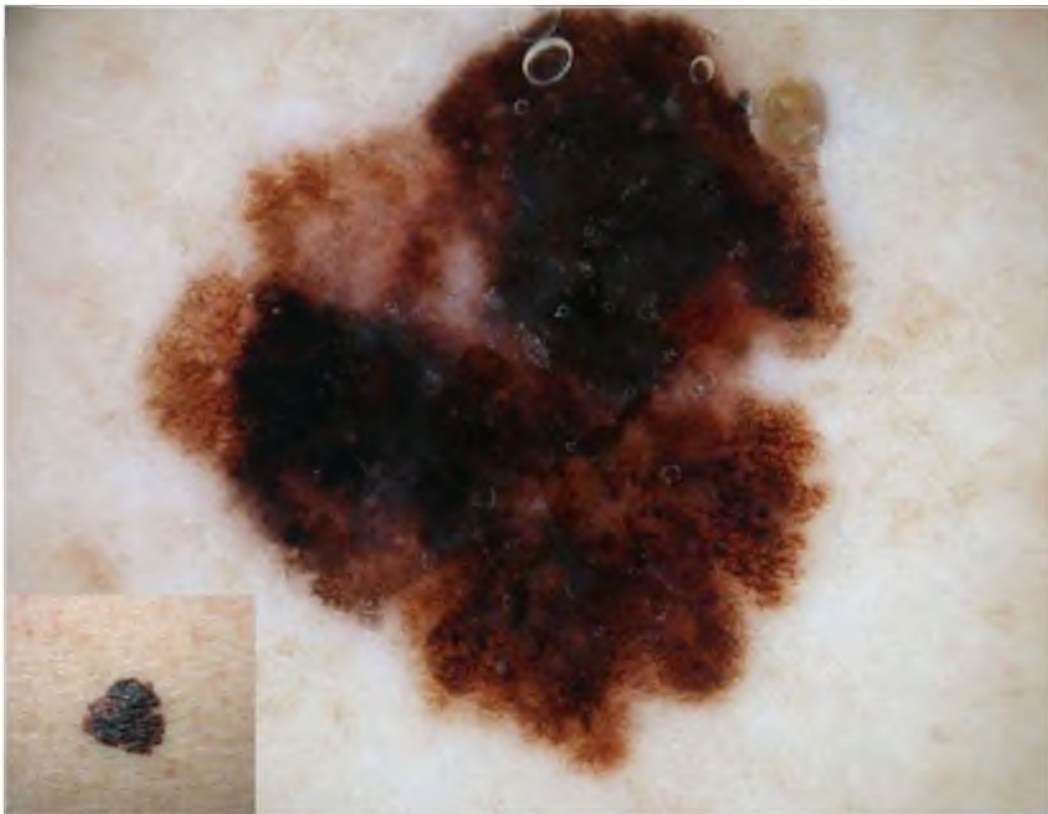


Fig. 78. The dermoscopy of melanoma.

### *Effectiveness of dermoscopy*

Several studies have demonstrated that dermoscopy is useful in the identification of melanoma, when used by experts.

- It may be up to 35% more accurate than clinical diagnosis

- It may reduce the number of benign lesions excised
- In primary care, it may result in the referral of more suspicious lesions and fewer banal ones

New users may unfortunately become less accurate at diagnosis at first, paradoxically increasing the number of unnecessary excisions.

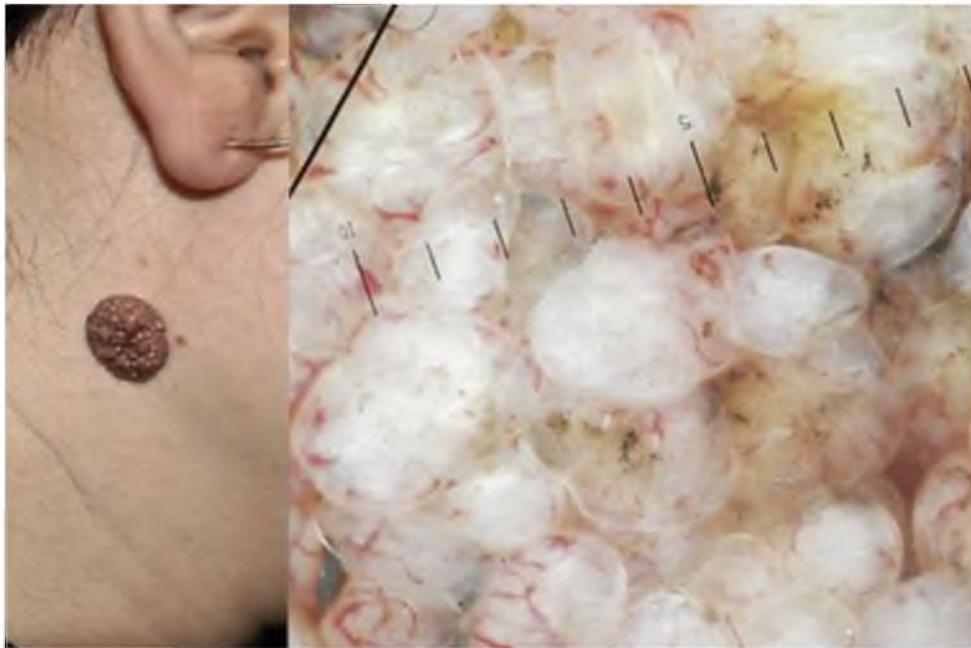

Fig. 79. The dermoscopy of nevus.

### ***Digital imaging***

Convenient attachments to dermoscopy devices allow high quality video or still digital photography, allowing review on a computer screen and comparison with images taken at follow-up appointments. It is estimated that dermoscopy can detect 92% of melanomas immediately because of typical features. The remaining 8% do not have identifying features and are diagnosed because of change in an atypical lesion. Structural change can be detected in superficial melanomas within 3 to 6 months.

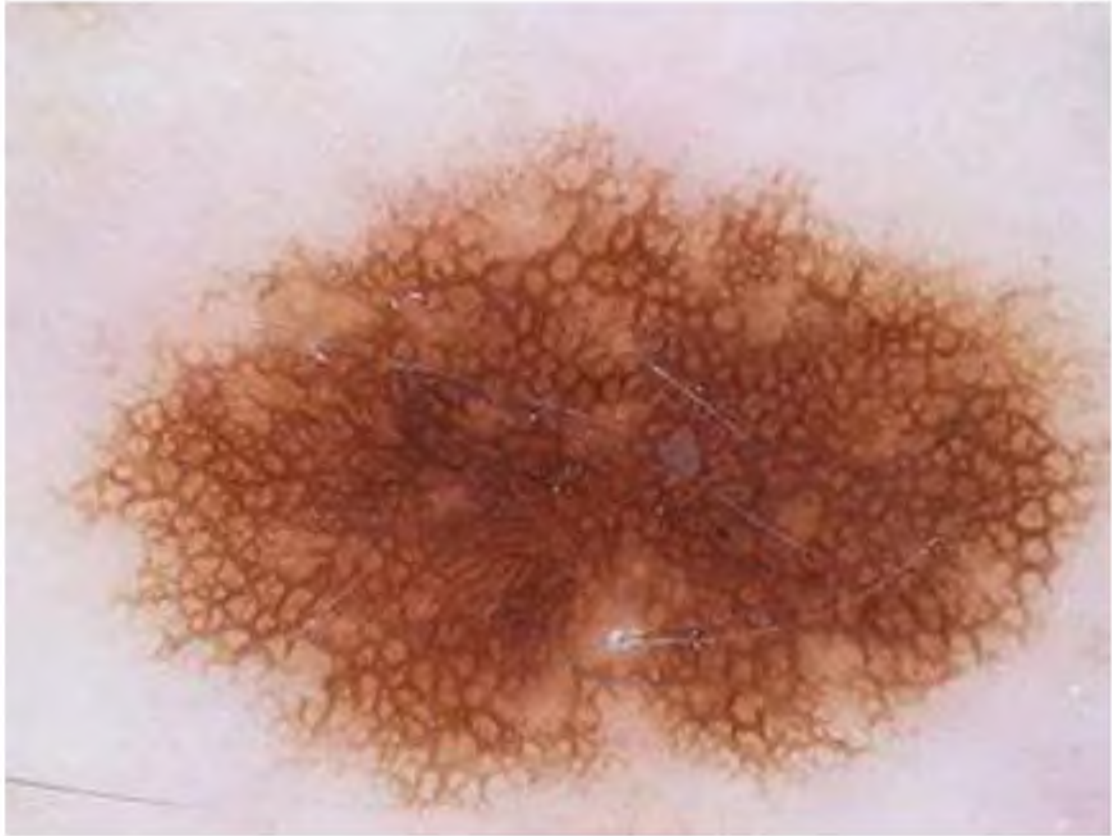

Fig. 80. The dermatoscopy of nevus.

### **Indications for examination**

Planned operation to remove the birthmark;

traumatization of a neoplasm or adjacent integuments;

change in color, shape or structure of the mole;

the appearance of pain, itching or swelling of the tissues in the area of the neoplasm.



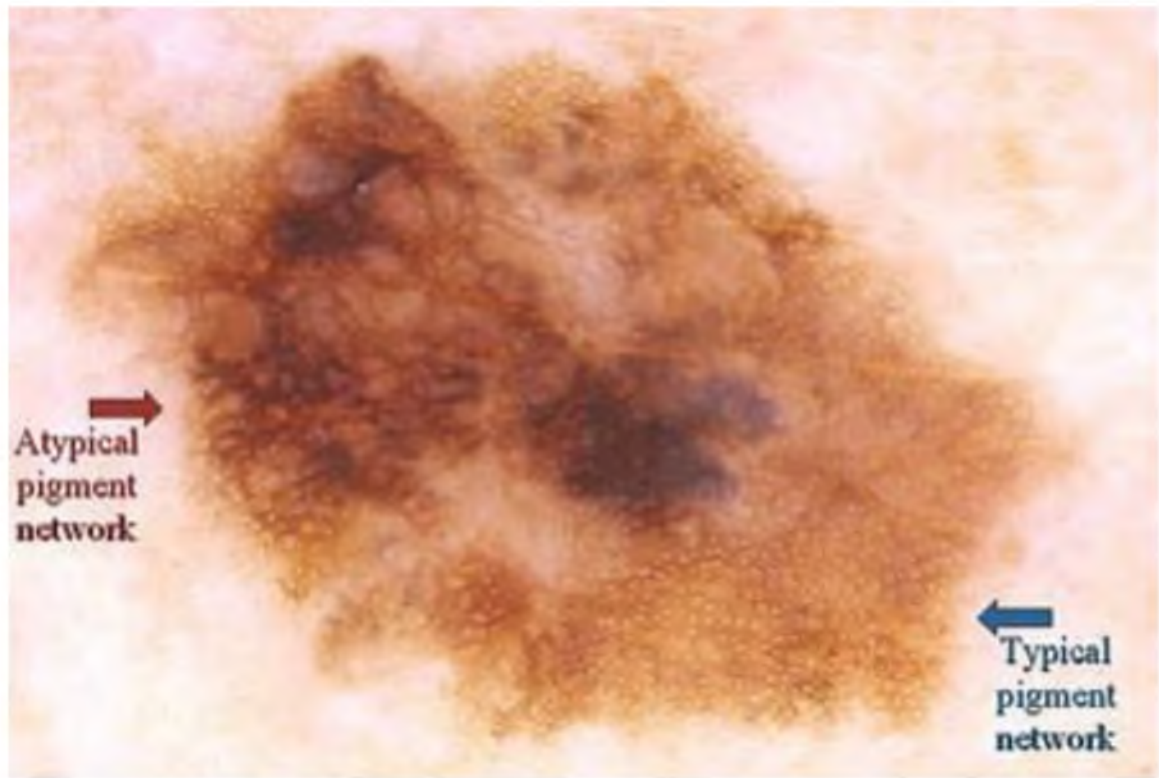


Fig. The dermatoscopy of melanoma.

### ***Whole body photography***

Surveillance of patients at risk for melanomas is greatly aided by the use of high quality images of the entire integument. It is particularly useful for those with atypical naevi or many moles. Several systems have been described, using about 24 to 30 images as conventional transparency slides, prints, or digital systems.

New lesions can be identified by careful comparison with older images. Lesions that are of concern can be kept under review, reducing unnecessary excisions if they are stable. Significant change in size or shape of individual lesions may prompt biopsy. However, close-up and dermoscopic images of the lesion under scrutiny are much more useful for this purpose.

Digital whole body imaging can be used for mole mapping, i.e. precisely locating an individual lesion that has been imaged by macro or

dermoscopic photography. It is not necessary to individually photograph every lesion.

Whole body photography should be supplemented by regular physician examinations. Skin self-examination is also valuable, and the patient may find it helpful to have copies as prints or digital images.

## LITERATURE:

1. Аветіков Д.С. Гістотопографічна характеристика загоєння післяопераційних ран при застосуванні клейової композиції «Сульфакрилат» в порівнянні з традиційним ушиванням / Д.С.Аветіков, Р.В.Талаш, І.І.Старченко // Актуальні проблеми сучасної медицини : Вісник УМСА. – 2015. – Т.15., Вип. 3 (51). – Ч. I. - С. 149-153.
2. Аветіков Д. С. Зміни біохімічного складу сироватки крові щурів у динаміці відновлення після перелому нижньої щелепи за умов хронічної інтоксикації нітратом натрію / Д. С. Аветіков, К. П. Локес // Сучасна стоматологія та щелепно-лицева хірургія : матер. міжнародної науково-практ. конф. присв.175-літтю НМУ ім.О.О.Богомольця, 120-літтю з дня народж. проф. Фетісова М.В., 90-літтю проф. Бердюка І.В., 20-літтю УАЧЩЛХ. – Київ, 2016. – С. 244–245.
3. Аветіков Д. С. Зміни мінерального компоненту нижньощелепної кістки в динаміці репаративного остеогенезу за умов хронічної нітратної інтоксикації / Д. С. Аветіков, К. П. Локес, В. В. Іщенко // Вісник проблем біології і медицини. – 2014. – Вип. 2. – Т. 1 (107). – С.37–39.
4. Аветіков Д. С. Комплексний підхід до вибору методів обстеження пацієнтів з больовою дисфункцією скронево-нижньощелепного суглобу як умова ефективного її лікування / Д.С. Аветіков, О.С. Іваницька, О.В. Рибалов // Актуальні проблеми сучасної медицини : Вісник Української медичної стоматологічної академії. – 2013. – Т. 13, Вип. 2 (42). – С. 50–52.

5. Аветіков Д. С. Морфофункціональні особливості будови м'яких тканин різних ділянок голови людини : автореф. дис. на отрим. вчен. ступення докт. мед. наук : спец. 14.03.01 "нормальна анатомія" / Д.С. Аветіков. – Х., 2011. – 37 с.
6. Аветіков Д.С. Особливості будови та біомеханічних властивостей сполучнотканинних структур голови / Д. С. Аветіков // Вісник морфології. – 2010. - № 16(3). – С. 721–726.
7. Аветіков Д. С. Одонтогенні та неодонтогенні кісти щелеп : навч. посіб. для студентів стоматологічних факультетів вищих навчальних закладів МОЗ України та лікарів-інтернів / Д. С. Аветіков, І.В. Яценко, В. Д. Ахмеров. – Полтава : СПДФО Гаража М.Ф., 2012. – 93 с.
8. Аветіков Д. С. Передпухлинні захворювання щелепно-лицевої ділянки : навч. посіб. для студентів стомат. фак-тів вищих мед.закладів та лікарів-інтернів / Д. С. Аветіков, Н. А. Соколова, Г.П.Рузін. — Полтава : ТОВ"АСМИ", 2012. — 82 с.
9. Аветиков Д. С. Предоперационная оценка и хирургическая коррекция преддверия полости рта / Д. С. Аветиков, И. В. Яценко, С.А.Ставицкий // Стоматология. Имплантация. Остеоинтеграция. VI Український Міжнародний конгрес. – Київ, 2014. – С. 220–222.
10. Аветіков Д.С. Сучасні підходи до хірургічного лікування рецесії ясен / Д.С.Аветіков, І.В.Яценко, К.П.Локес, С.О.Ставицкий, Каплун Д.В.// Вісник проблем біології і медицини. – 2015. – вип. 2, Т.2(119). – С.9-12.
11. Аналіз захворюваності та стан діагностики злоякісних новоутворень щелепно-лицевої ділянки / Н. А. Соколова, Д. С. Аветіков, В. М. Гаврильєв, В. Д. Ахмеров // Лікарська справа. – 2013. – № 8 (1125). – С. 137–141.

12. Амхадова М.А. Использование компьютерной томографии на этапах планирования субпериостальной имплантации / М.А. Амхадова, Н.А. Рабухина, А.А. Кулаков // Российский стоматологический журнал. – 2004. - №2. – С.31-32.

13. Белоусова И.П. Фармакологическая регуляция окислительного гомеостаза при гипоксическом синдроме / И.П. Белоусова, Е.Ю. Бибик // Проблеми військової охорони здоров'я : Зб. наук. праць Укр. військ.-мед. академії. Вип. 7 : за ред. проф. В.Я. Білого. – К., 2000. – С. 473–477.

14. Бородай Н.В. Морфофункціональні особливості слизової оболонки порожнини рота та зміни в ній при різних патологічних процесах / Н.В. Бородай // Лабораторна діагностика. – 2001. - № 1. – С. 49 -55.

15. Быков В.Л. Гистология и эмбриология органов полости рта человека : учебн. пособ. [для студентов стом. фак. мед. ин-тов.] / В.Л. Быков– М. : Спец. лит., 1996. – 246 с.

16. Влізло В. В., Федорук Р. С., Ратич І. Б. та ін. Лабораторні методи досліджень у біології, тваринництві та ветеринарній медицині. Львів: СПОЛОМ, 2012. – 761 с.

17. Волков К. С. Ультраструктура клітин і тканин : навчальний посібник-атлас / К. С. Волков, Н. В. Пасечко. – Тернопіль: Укрмедкнига, 2004. – 96 с.

18. Ву Вьет Куонг Современный взгляд на этиологию и патогенез одонтогенных абсцессов и флегмон челюстно-лицевой области / Ву Вьет Куонг, Д. С. Аветиков, С. Б. Кравченко // Вісник проблем біології і медицини. – 2014. – Вип. 2, т. 1 (107). – С. 79–83.

19. Гнойно-воспалительные процессы челюстно-лицевой локализации у пациентов с сахарным диабетом / Д.С. Аветиков,

Е.П. Локес, С.А. Ставицкий [та ін.] // Матеріали IV з'їзду Української асоціації черепно-щелепно-лицевих хірургів. – Київ, 2015. – С. 84–85.

20. Гуллер А.Е. Влияние возраста пациента и способа местного лечения раны на структуру рубцов при пограничных дермальных ожогах / А.Е. Гуллер, А.Б. Шехтер // Экспериментальная и клиническая дерматокосметология. - 2006. - № 3. - С. 6-14.

21. Гуллер А.Е. Клинический тип и гистологическая структура кожных рубцов как прогностические факторы исхода лечения / А.Е. Гуллер, А.Б. Шехтер // Анналы пластической, реконструктивной и эстетической хирургии - 2007. - №4. - С.19-31.

22. Деформативно–прочностные свойства мягких биологических тканей в аспекте пластической хирургии / А. Н. Черномашенцев, Г. Д. Бурдей, М. М. Горелик [и др.] // Биомеханика кровообращения, дыхания и биологических тканей. – 2004. – № 5. – С. 272–27.

23. Зміни імунологічних показників в сироватці крові і в ротовій рідині у хворих неврогенним сіалозаденітом / О. В. Рибалов, В. М. Гаврильєв, І. В. Яценко [та ін.] // Сучасна стоматологія та щелепно-лицева хірургія : матер. Міжнародної науково-практ. конф. присв.175-літтю НМУ ім. О.О.Богомольця, 120-літтю з дня народж. проф. Фетісова М.В., 90-літтю проф. Бердюка І.В., 20-літтю УАЧЩЛХ. – Київ, 2016. – С. 248–249.

24. Изменение биохимического состава сыворотки крови в условиях хронической нитратной интоксикации (экспериментальное исследование) / Д. С. Аветиков, Е. П. Локес, С. А. Ставицкий [и др.] // Georgian Medical News. – 2014. – № 11 (236). – С. 102–105.

25. Камышников В.С. Справочник по клинико-биохимическим исследованиям и лабораторной диагностике / В.С. Камышников. – М.: МЕДпресс-информ. – 2004. – 911 с.

26. Калюжна Л.Д. Хвороби шкіри обличчя, слизової оболонки ротової порожнини та червоної облямівки губ та червоної облямівки губ : навч. посіб./ Л.Д. Калюжна, Г.Ф. Білоклицька. - К. : Грамота, 2011. – 271 с.
27. Коробов В.М. Вплив гіпоксичної гіпоксії на кисневозв'язувальні властивості гемоглобінівшурів і напівводяних амніот / В.М. Коробов // Експер. та клін. фізіологія і біохімія. – 2001. – №1 (13). – С.38–41.
28. Лаврищева Г. И. Морфологические и клинические аспекты репаративной регенерации опорных органов и тканей / Г. И. Лаврищева, Г. А. Оноприенко. – М. : Медицина, 2006. – 208 с.
29. Локес К. П. Аналіз причин незадовільних результатів лікування хворих із гнійно-запальними процесами щелепно-лицевої ділянки / К. П. Локес // Актуальні проблеми сучасної медицини. – 2014. – Т. 14, Вип. 4 (48). – С. 20–23.
30. Локес Е. П. Использование квазилайзера «УФЛ-122» с лечебной целью при повреждениях слизистой оболочки полости рта / Е. П. Локес, В. В. Ищенко, А. А. Розколупа // Паринские чтения 2016. Обеспечение демографической безопасности при решении актуальных вопросов хирургической стоматологии и челюстно-лицевой хирургии : сборник трудов национального конгресса с международным участием. – Минск, 2016. – С. 342–345.
31. Маланчук В.О. Доброякісні пухлини та пухлиноподібні ураження щелепно-лицевої ділянки та шиї / В.О. Маланчук, А.В. Копчак. – К. : Видавничий дім «Асканія», 2008. – 320 с.
32. Маланчук В.О. Хірургічна стоматологія та щелепно-лицева хірургія : Т. 1 / В.О. Маланчук. – К., 2011. – 672 с.
33. Матушевская, Е.В. Сочетание клинических форм красного плоского лишая у одного больного / Е.В. Матушевская, И.Г. Богущ,

Д.К. Нажмутдинова, Т.В. Жомова, Л.М. Сабирова // Вестник дерматологии и венерологии. 2013. - №4. - С. 46 - 47.

34. Методичні рекомендації для самостійної роботи студентів. Методические рекомендации для самостоятельной работы студентов. Methodical recommendations for student's independent work. (3 Модуль) / Д. С. Аветіков, О. О. Розколупа, І. В. Яценко [та ін.]. — Полтава, 2012. — 498 с.

35. Методичні рекомендації для самостійної роботи студентів. Методические рекомендации для самостоятельной работы студентов.(4 модуль) / [ Д. С. Аветіков, О. О. Розколупа, І. В. Яценко та ін.]. — Полтава, 2013. — 390 с.

36. Методичні рекомендації для самостійної роботи студентів. Методические рекомендации для самостоятельной работы студентов. (5 модуль) / [Д. С. Аветіков, О. О. Розколупа, І. В. Яценко та ін.]. — Полтава, 2013. — 487 с.

37. Методичні рекомендації для самостійної роботи студентів. Методические рекомендации для самостоятельной работы студентов. (6 модуль) / [ Д. С. Аветіков, О. О. Розколупа, І. В. Яценко та ін.]. — Полтава, 2014. — 512 с.

38. Морфофункциональные и биомеханические параллели в изучении органов зубочелюстной системы / О. И. Салагай, Т. К. Шкавро [ и др. ] // Морфология. – 2002. – Т. 121, № 2–3. – С. 137–138.

39. Новиков В. М. Миофасциальная симптоматика в клинике компрессионно-дислокационной дисфункции височно-нижнечелюстного сустава / В. М. Новиков, П. И. Яценко, О. В. Рыбалов // Український стоматологічний альманах. – 2017. – № 1. – С. 32–36.

40. Новые взгляды на хирургическую анатомию лица / Д. С. Аветиков, С. А. Ставицкий, И. В. Яценко [и др.] // Матеріали IV з'їзду



Української асоціації черепно-щелепно-лицевих хірургів. – Київ, 2015. – С. 128–129.

41. Оптимізація хірургічних розрізів шкіри голови та шиї. Сучасний погляд на проблему / С. О. Ставицький, Д. С. Аветіков, І. В. Яценко, К.П. Локес // Вісник проблем біології і медицини. – 2013. – Вип. 3, Т. 2(103). – С. 42–47.

42. Оцінка ефективності аугментації альвеолярного гребня на етапі підготовки до дентальної імплантації / Д. С. Аветіков, С.О.Ставицький, К. П. Локес [та ін.] // Вісник проблем біології і медицини. – 2016. – Вип. 3, Т. 1 (131). – С. 240–242.

43. Пат. 86628 UA, МПК А 61К 39/00 (2013.01) А61G 10/02 (2006.01). Спосіб лікування гострих та хронічних сіалоденітів на фоні хронічної нітратної інтоксикації / Бондаренко В. В., Аветіков Д. С. ; заявник ВДНЗУ «УМСА». — № u 2013 07026 ; заявл. 04.06.2013; опубл. 10.01.2014, Бюл. № 1.

44. Патент на корисну модель 15448 Україна, МПК G01N 33/00. Спосіб профілактики виникнення патологічних рубців, що локалізовані в ділянках голови та шиї після планових оперативних втручань / Аветіков Д.С., Ставицький С.О., Скрипник В.М. - № u 2012 102712; заявл 14.10.2012; опубл. 20.12.2012, Бюл. №11.

45. Переваги та недоліки сучасних методик обстеження пацієнтів перед дентальною імплантацією / І. В. Яценко, Д. С. Аветіков, С. О. Ставицький, К. П. Локес // Матеріали IV з'їзду Української асоціації черепно-щелепно-лицевих хірургів. – Київ, 2015. – С. 159–161.

46. Переломи нижньої щелепи: аналіз частоти виникнення, локалізації та ускладнень / Д. С. Аветіков, К. П. Локес, С. О. Ставицький [та ін.] // Вісник проблем біології і медицини. – 2014. – Вип. 3, т. 3 (112). – С. 62–64.

47. Показники біоелектричної активності власне жувальних м'язів із різною м'язовою масою в чоловіків /О. В. Рыбалов, Ю. І. Семененко, П. І. Яценко [та інш.] // Український стоматологічний альманах. – 2016. – № 3, Т. 2. – С. 55–57.

48. Принципи знеболення хірургічних стоматологічних хворих в післяопераційному періоді / І. В. Яценко, Д. С. Аветіков, С.О. Ставицкий, І. В. Бойко // Нові технології в хірургічній стоматології і щелепно-лицевій хірургії : матер. наук.-прак. конф., присвяч. 100-річчю з дня народ. проф. Г. І. Семенченка. – Одеса: Астропринт, 2014. – С. 32–34.

49. Рабинович, О.Ф. Методы диагностики и местного лечения заболеваний слизистой оболочки полости рта (красный плоский лишай, рецидивирующий афтозный стоматит, декубитальные язвы) / О.Ф. Рабинович, Е.Л. Эпельдимова // Стоматология. – 2015. - № 3. — С. 58-62.

50. Руководство по хирургической стоматологии и челюстно-лицевой хирургии / Под ред. В.М. Безрукова, Т.Г. Робустовой. – М. : Медицина, 2000. – Т. 1. – 772 с.

51. Рыбалов О. В. Ошибки в диагностике и лечении компрессионно-дислокационной мышечно-суставной дисфункции височно-нижнечелюстного сустава / О.В. Рыбалов, П. И. Яценко, О.И. Яценко // Матеріали І з'їзду черепно-щелепно-лицевих хірургів України. – К. : 2009. – С. 88.

52. Серов В. В. Соединительная ткань / В. В. Серов, А. Б. Шехтер // . – М. : Медицина, 2002. – 194 с.

53. Сахарный диабет и его влияние на клиническое течение гнойно-воспалительных процессов челюстно-лицевой локализации / Д. С. Аветиков, Е. П. Локес, И. В. Яценко [та ін.] // Global Scientific Unity

2014. The European Scientific and Practical Congress. – Prague (Czech Republic), 2014. – Vol. 2. – P. 50–53.

54. Скрипник В.М. Клініко-генетичне та морфологічне обґрунтування профілактики утворення післяопераційних патологічних рубців голови та шиї : автореферат дис. на здобуття наук. ст. к.мед.н. : спец. 14.01.22 «Стоматологія» / В.М. Скрипник. – Полтава, 2013. – 21 с.

55. Современный подход к хирургическому лечению и послеоперационной реабилитации пациентов с жаберными кистами шеи / С.Н. Григоров, Л.Р. Криничко, С.А. Ставицкий, Е.П. Локес // Паринские чтения 2016. Обеспечение демографической безопасности при решении актуальных вопросов хирургической стоматологии и челюстно-лицевой хирургии : сборник трудов национального конгресса с международным участием. – Минск, 2016. – С. 327–329.

56. Ставицький С.О. Клініко-морфологічне обґрунтування комплексного лікування патологічних рубців, що локалізовані в ділянках голови та шиї : автореферат дис. на здобуття наук. ст. к.мед.н. : спец. 14.01.22 «Стоматологія» / С.О. Ставицький. – Полтава, 2012. – 19 с.

57. Сучасний підхід до вибору методів обстеження хворих із патологічними рубцями шкіри голови та шиї / Д.С. Аветіков, О.П. Буханченко, О.С. Іваницька [та ін.] // Вісник проблем біології і медицини. – 2018. – вип 1. – Т.1(142). – С.243-246.

58. Сучасні аспекти діагностики передракових захворювань щелепно-лицевої ділянки / Д. С. Аветіков, І. В. Яценко, В. Д. Ахмеров [та ін.] // Стоматологія Придніпров'я. Збірник наукових праць Третьої (III) міжрегіональної наук.-практичної конф. – Дніпропетровськ, Запоріжжя, 2015. – С. 11–12.

59. Сучасний підхід до вибору методів обстеження хворих із патологічними рубцями шкіри голови та шиї / Д.С. Аветіков,

О.П. Буханченко, О.С. Іваницька [та ін.] // Вісник проблем біології і медицини. – 2018. – вип 1. – Т.1(142). – С.243-246.

60. Тимофеев А.А. Руководство по челюстно-лицевой хирургии и хирургической стоматологии : учебник / А.А. Тимофеев. – [5-е изд., перераб. и доп.]. – К., 2012. - 1048 с. : ил.

61. Тимофеев А.А. Тесты контроля знаний по специальности «Челюстно-лицевая хирургия и хирургическая стоматология» : учеб. пособие / А.А. Тимофеев. – [5-е изд., перераб. и доп.]. – К., 2010. - 256 с.

62. Тимофеев А.А. Челюстно-лицевая хирургия : учебник / А.А. Тимофеев. – К., 2010. - 576 с. : ил.

63. Тимофеев О.О. Щелепно-лицева хірургія : підручник / О.О. Тимофеев. – К., 2011.- 752 с.

64. Факторы риска и анализ осложнений после регенеративных вмешательств в хирургии полости рта / Д. С. Аветиков, Л. Р. Криничко, С. А. Ставицкий [и др.] // Клінічна хірургія. – 2014. – № 11 (865). – С. 52–54.

65. Фисталь Н.Н. Рубцовые деформации и контрактуры / Фисталь Н.Н., Самойленко Г.Е. // Пластическая хирургия. – Донецк : «Вебер», 2008. – С. 136–162.

66. Фізична реабілітація в стоматології : навч. посібник / В.А. Шаповалова, В.М. Коршак, В.М. Халтогарова [та ін.]. – К., 2008. – 96 с.

67. Хирургическая стоматология и челюстно-лицевая хірургія : национальное руководство / [под ред. А.А. Кулакова, Т.Г. Робустовой, А.И. Неробеева]. – М., 2010. – 982 с.

68. Электромиографические характеристики височных и жевательных мышц у больных компрессионно-дислокационной дисфункцией височно-нижнечелюстных суставов различной степени

тяжести / П. И. Яценко, О. В. Рыбалов, О. И. Яценко [и др.] // *Wiadomosci Lekarskie*. – 2018. – Т. LXXI, Nr 3. – cz II. – P. 663–670.

69. Adducted thumb as an isolated morphologic finding: an early sonographic sign of impaired neurodevelopment: A STROBE compliant study / Y.S. Ouyang, Y.X. Zhang, H. Meng [et al.] // *Medicine (Baltimore)*. – 2018. – Vol. 97(38). – P. 124.

70. Agarwal R. Claudin -3 and claudin-4 expression in ovarian epithelial cells enhances invasion and is associated with increased matrix metalloproteinase-2 activity// Agarwal R., D'Souza T., Morin P. J. // *Cancer Res*. – 2012. - V. 65. - P. 7378-7385.

71. Age-related differences in test-retest reliability in resting-state brain functional connectivity / J. Song, A.S. Desphande, T.B. Meier [et al.] // *PLoS One*. – 2012. – Vol. 7. – P. 498.

72. Al-Omari M.H. Internal jugular vein morphology and hemodynamics in patients with multiple sclerosis / M.H. Al-Omari, L.A. Rousan // *Int Angiol*. –2010. – Vol. 29(2). – P. 115–120.

73. Amini M.H. Three-Dimensional Templating and Use of Standard Instrumentation in Primary Anatomic Total Shoulder Arthroplasty / M.H. Amini, E.T. Ricchetti, J.P. Iannotti // *JBJS Essent Surg Tech*. – 2017. – Vol. 7(3). – P. 28.

74. Ansai S.I. Topics in histopathology of sweat gland and sebaceous neoplasms / Ansai S.I. / *J Dermatol*. – 2017. – Vol. 44(3). – P. 315-326.

75. Avetikov D. S. Operation of Root Apex Resection – Modern Risk Factors and Complications / D. S. Avetikov, I. V. Yatsenko, K. P. Lokes // *Intermedical journal*. – 2017. – I (9). – P. 55–59.

76. Avetikov D. S. Precancerous diseases of maxillofacial area / D.S. Avetikov, V. V. Aipert, K. P. Lokes. – Poltava, 2017. – 126 p.

77. Bankfalvi A. Gains and losses of adhesion molecules (CD44, E-cadherin, and  $\beta$ -catenin) during oral carcinogenesis and tumor progression /

Bankfalvi A., Krassort M., Buchwalow I. B. [et al.] // J Pathol. 2014. - V. 198. - P. 343-351.

78. Borchard R. Incisions and tissue management in periodontal surgery / R. Borchard, H. Erpenstein // Perio. – 2004. – Vol. 1. – P. 111-122.

79. Case report of a p16INK4A-positive branchial cleft cyst / T. McLean, C. Iseli, D. Amott, M. Taylor // J Laryngol Otol. – 2015. – Vol. 129(6). – P. 611-613.

80. Combined Metabolo-Volumetric Parameters of 18F-FDG-PET and MRI Can Predict Tumor Cellularity, Ki67 Level and Expression of HIF 1alpha in Head and Neck Squamous Cell Carcinoma: A Pilot Study / A. Surov, H.J. Meyer HJ, A.K. Höhn AK // Transl Oncol. – 2018. – Vol. 12(1). – P. 8-14.

81. Comparative characteristics of echogenous structure of postoperative normotrophic and atrophic cutaneous cicatrices / D.S. Avetikov, O.P. Bukhanchenko, K.P. Lokes [et al.] // Klinichna khirurgiia. – 2018. – Vol. 85(5). – P. 44–46.

82. Comparison of MR and Contrast Venography of the cervical venous system in Multiple Sclerosis / G. Zaharchuk, N.J. Fischbein, J. Rosenberg [et al.] // AJNR Am J Neuroradiol. – 2011. – Vol. 32(8). – P. 1482–1489.

83. Cortellini P. The modified papilla preservation technique. A new surgical approach for interproximal regenerative procedures / P. Cortellini, P.G. Prato, M. Tonetti // J. Periodontol. – 1995. – Vol. 66. – P. 261-266.

84. CT-based delineation of organs at risk in the head and neck region: DAHANCA, EORTC, GORTEC, HKNPCSG, NCIC CTG, NCRI, NRG Oncology and TROG consensus guidelines / C.L. Brouwer, R.J. Steenbakkers, J. Bourhis [et al.] // Radiother Oncol. – 2015. – Vol. 117(1). – P. 83-90.

85. Detre J.A. Clinical applicability of functional MRI / Detre J.A. // *J Magn Reson Imaging*. – 2006. – Vol. 23. – P. :808–815.
86. Deschner J. Dimensional changes of periodontal soft tissues after intrasulcular incision / J. Deschner, S. Wolff, J. Hedderich // *Clin. Oral Invest*. – 2009. – Vol. 13. – P. 401-408.
87. Diagnostic and prognostic value of circulating tumor cells in head and neck squamous cell carcinoma: A systematic review and meta-analysis / X.L. Wu, Q. Tu, G. Faure G [et al.] // *Sci Rep*. – 2016. – Vol. 6. – P. 202-210.
88. Digital Subtraction Angiography for CT Angiogram Negative Haemorrhages / H. Wong H, L. Hodgson L, J. Banfield, J.J.S. Shankar // *Can J Neurol Sci*. – 2018. – Vol. 45(5). – P. 522-526.
89. Diseases of the submandibular gland as demonstrated using high resolution ultrasound / F. Alyas, K. Lewis, M. Williams [et-al.] // *Br J Radiol*. – 2005. – Vol. 78 (928). – P. 362-369.
90. Ectopic congenital bronchogenic cyst accompanied by infection appearing in the cervical region of an elderly female patient: A case report / Z. Liu, Z. Tian, C. Zhang, Y. He // *Oncol Lett*. – 2016. – Vol. 11(2). – P. 1065–1068.
91. Effects of differences in head holder on image quality and radiation dose in head CT / K. Yokomachi, E. Nishimaru, C. Fujioka [et al.] // *Nihon Hoshasen Gijutsu Gakkai Zasshi*. – 2014. – Vol. 70(10). – P. 1166-1172.
92. Endoscope-assisted second branchial cleft cyst resection via an incision along skin line on lateral neck / J. Chen, W. Chen, J. Zhang [et al.] // *Eur Arch Otorhinolaryngol*. – 2014. – Vol. 271(10). – P. 2789-2793.
93. Emergency imaging assessment of acute, nontraumatic conditions of the head and neck / E.F. Capps, J.J.Kinsella, M. Gupta [et-al.] // *Radiographics*. – 2010. – Vol. 30 (5). – P. 1335-1352.

94. Evidenced-based dicision making: the third molar / R.H. Haug, J. Abdul-Majid, G.H. Blakey [et al.] // Dent. Clin. N. Am. - 2009. - Vol. 53. - P. 77-96.

95. Extracranial Doppler sonographic criteria of chronic cerebrospinal venous insufficiency in the patients with multiple sclerosis / M. Simka, J. Kostecki, M. Zaniewski [et al.] // Int Angiol. – 2010. – Vol. 29(2). – P. 109–114.

96. Farina M. Cross-sectional area variations of internal jugular veins during supine head rotation in multiple sclerosis patients with chronic cerebrospinal venous insufficiency: a prospective diagnosticcontrolled study with duplex ultrasound investigation / M. Farina, E. Novelli, R. Pagani // BMC Neurol. – 2013. – Vol. 13. – P. 162.

97. Golledge J. The aetiology of lateral cervical (branchial) cysts: past and present theories / J. Golledge, H. Ellis // J Laryngol Otol. – 1994. – Vol. 108. – P. 653–659.

98. Goodman H.S. Oral cancer prevention: the role of family practitioners / Goodman H.S., Yellowitz J.A., Horowitz A.M. // Arch Fam Med. – 2014.- V.4.- P.628-636.

99. Hamamoto Y., Nakajima T., Ozawa H. Ultrastructural and histochemical study on the morphogenesis of epithelial rests of Malassez. Arch. Histol. Cytol. 1989; 52: 61-7Q.

100. Histological changes within dental pulps in teeth with moderate-to-severe chronic periodontitis / L. Wan, H.B. Lu, D.Y. Xuan [et al.] // Int Endod J. – 2015. – Vol. 48 (1). – P. 95-102.

101. Imaging resting state brain function in multiple sclerosis / M. Filippi, F. Agosta, E.G. Spinelli EG, M.A. Rocca // J Neurol. – 2013. – Vol. 260. – P. 1709–1713.



102. Intraoperative use of fibrin glue dyed with methylene blue in surgery for branchial cleft anomalies / M. Piccioni, M. Bottazzoli, N. Nassif [et al.] // *Laryngoscope* – 2016. – Vol. 126(9). – P. 2147-2150.
103. Head Motion and Correction Methods in Resting-state Functional MRI / M. Goto, O. Abe, T. Magn Reson Med Sci. – 2016. – Vol. 15(2). – P. 178-186.
104. How Much Is That Head CT? Price Transparency and Variability in Radiology / A.B. Paul, R. Oklu, S. Saini, A.M. Prabhakar // *J Am Coll Radiol.* – 2015. – Vol. - 12(5). – P. 453-457.
105. Kim S. Modern endodontic surgery concepts and practice: a review / S. Kim, S. Kratchman // *J. Endod.* – 2006. – Vol. 32. – P. 601-623.
106. Kolar Z., Geierova M., Bouchal J., Pazdera J., Zboril V., Tvrdy P. Immunohistochemical analysis of the biological potential of odontogenic keratocysts. *J. Oral. Pathol. Med.* 2006 Feb; 35(2): 75-80.
107. Lateral and median cysts of the neck / G. Buła , J. Waler , A. Niemiec [et al.] // *Pol Przegl Chir.* – 2012. – Vol. 84(9). – P. 445-448.
108. Lee M.H. Resting-state fMRI: a review of methods and clinical applications / M.H. Lee, C.D. Smyser, J.S. Shimony JS // *AJNR Am J Neuroradiol.* – 2013. – Vol. 34. – P. 1866–1872.
109. Lehrman B J., Mayer D.P., Tidwell O.F., Brooks M.L. Computed tomography of odontogenic keratocysts. *Comput. Med. Imaging Graph.* 1991; 15:365-8.
110. McKenna S.J. Dental Management of patients with Diabetes / S.J. McKenna // *Dent. Clin. N. Am.* - 2006. - Vol. 50. - P. 591-606.
111. McQueen A.S. Head and neck ultrasound: technical advances, novel applications and the role of elastography / A.S. McQueen, K.S. Bhatia // *Clin Radiol.* – 2018. – Vol. 73(1). – P. 81-93.

112. Modern methods of surgical treatment of cysts of jaws [Text-book] / D. S. Avetikov, K.P.Lokes, I. V. Yatsenko, S. O. Stavickij. – Poltava, 2014. – 108 p.
113. Ogawa R. Histologic analysis of keloids and hypertrophic scars / R. Ogawa, S. Akaishi, M. Izumi // *Ann Plast Surg.* – 2009. – Vol. 62. – P. 104–105.
114. Patient discomfort following periapical surgery / R. Christiansen, L.L. Kirkevang, P. Horsted-Bindslev [et al.] // *Oral Surg. Oral Med. Oral Pathol. Oral Radiol. Endod.* – 2008. – Vol. 105. – P. 245-250.
115. Choi N. Radiology quiz case 1. Iodine 131–induced sialadenitis / N. Choi, N. Schularick N, H. Diggelmann [et-al.] // *Arch. Otolaryngol. Head Neck Surg.* – 2012. – Vol. 138 (6). – P. 597-598.
116. Reduction of motion-related artifacts in resting state fMRI using aCompCor / J. Muschelli, M.B. Nebel, B.S. Caffo [et al.] // *Neuroimage.* – 2014. – Vol. 96. – P. 22–35.
117. Relationship between apical and marginal healing in periradicular surgery / L. Jansson, P. Sandstedt, A.C. Laftman [et al.] // *Oral Surg. Oral Med. Oral Pathol. Oral Radiol. Endod.* – 1997. – Vol. 83. – P. 596-601.
118. Ruthenborg R.J. Regulation of wound healing and fibrosis by hypoxia and hypoxia-inducible factor-1 / R.J. Ruthenborg, J. Ban, A. Wazir // *Mol Cells.* –2014. – Vol. 37. – P. 637–643.
119. Sato N. Periodontal Surgery. A Clinical Atlas / N. Sato. – Shtudgart : "Quintessence Publishing Co. Inc". - 2000. - 570 pp.
120. Selvig K.A. Wound healing after muco-periosteal surgery in the cat / K.A. Selvig, M. Torabinejad // *J. Endod.* – 1996. – Vol. 22. – P. 507-515.
121. Sialolithiasis: MR sialography of the submandibular duct--an alternative to conventional sialography and US? / L. Jäger, F. Menauer, N. Holzkecht [et-al.] // *Radiology.* – 2000. – Vol. 216 (3). – P. 665-671

122. Silverston L.H. Principles of dental suturing / L.H. Silverston. – Atlanta : "Montage Media Corporation". - 1999. – 375 pp.

123. Skikevych M. G. The basics of stomatology : text-book [for the students of medical faculty] / M. G. Skikevych, D. S. Avetikov. – Poltava : ASMI, 2012. – 206 p.

124. The reliability of high resolution ultrasound in the identification of pus collections in head and neck swellings / C.N. Mallorie, S.D. Jones, N.A. Drage, J. Shepherd // *Int J Oral Maxillofac Surg.* – 2012. – Vol. 41(2). – P. 252-255.

125. Vargas C. A systematic literature review of resting state network—functional MRI in bipolar disorder / C. Vargas, C. López-Jaramillo, E. Vieta // *J Affect Disord.* – 2013. – Vol. 150. – P. 727–735.

126. Web-based database for the management of tissue specimens in a transregional histologicalresearch facility / S. Huss, F. Fronhoffs, R. Büttner, L.C Heukamp // *Diagn Pathol.* – 2011. – Vol. 10(6). – P.17.