

St. Catherine University

SOPHIA

Doctor of Physical Therapy Research Papers

Physical Therapy

2-2011

An Outpatient Physical Therapy Intervention Program

Rebecca K. Henderson

St. Catherine University

Follow this and additional works at: https://sophia.stkate.edu/dpt_papers

Recommended Citation

Henderson, Rebecca K.. (2011). An Outpatient Physical Therapy Intervention Program. Retrieved from Sophia, the St. Catherine University repository website: https://sophia.stkate.edu/dpt_papers/4

This Research Project is brought to you for free and open access by the Physical Therapy at SOPHIA. It has been accepted for inclusion in Doctor of Physical Therapy Research Papers by an authorized administrator of SOPHIA. For more information, please contact amshaw@stkate.edu.

AN OUTPATIENT PHYSICAL THERAPY INTERVENTION PROGRAM
FOCUSING ON MANUAL THERAPY AND EXERCISE FOR A PATIENT WITH
CERVICAL RADICULOPATHY: A CASE REPORT

by
R. K. Henderson

Doctor of Physical Therapy Program
St. Catherine University

February 25, 2011

Research Advisor: Associate Professor Mary Weddle, PT, DSc

ABSTRACT

BACKGROUND AND PURPOSE: Two thirds of the United States population may experience neck pain at one point in their life. Two common categories of neck pain are whiplash associated disorders (WAD) and cervical radiculopathy. Conservative non-operative management of cervical radiculopathy is effective with the majority of patients. The purpose of this case report is to describe the outpatient physical therapy intervention for a patient with cervical radiculopathy. **CASE DESCRIPTION:** The patient is a 47-year-old right hand dominant female with a complicated history of neck pain referred to physical therapy for evaluation and treatment of cervical radiculopathy. Symptoms included bilateral cervical and upper thoracic pain, and upper extremity radicular symptoms. Decreased cervical and upper extremity range of motion (ROM), upper extremity and scapular muscle weakness, and significant tenderness with palpation were found. Eight visits over a six week course of therapy focused on nerve glides, soft tissue mobilization, joint mobilization and manipulation, therapeutic exercises, and a trial of cervical mechanical traction to reduce pain and increase function. **OUTCOMES:** The patient reported decreased overall pain, and improved cervical ROM and self management skills. Shoulder ROM, upper extremity and scapular strength did not improve. Tolerance to work and exercise activity did improve since the start of treatment. Neck Disability Index scores increased from 14/50 to 19/50, indicating greater functional difficulty. **DISCUSSION:** The interventions detailed throughout this report are supported by varying levels of research and may be related to changes in this patient's impairments and function. Any lack of improvements or gains made by the patient could

also be related to her motivation and activities she participated in outside of her therapy visits. Few studies are available to represent cases in which conservative treatment for cervical radiculopathy is unsuccessful and who potentially may require surgical referral. This case report helps to give current insight into one such possible rehabilitation experience.

The undersigned certify that they have read, and recommended approval of the research project entitled

An Outpatient Physical Therapy Intervention Program Focusing on Manual Therapy and Exercise for a Patient with Cervical Radiculopathy: A Case Report

submitted by
Rebecca K. Henderson

in partial fulfillment of the requirements for the Doctor of Physical Therapy Program

Primary Advisor:

Mary Middle Date: 4.26.11

Table of Contents

Abstract	ii
Research Advisor Final Approval.....	iv
Chapter 1: Introduction	1
Chapter II: Review of Related Literature	4
Chapter III: Case Description	8
The Patient	8
Examination	10
Evaluation/Diagnosis/Prognosis	14
Intervention	15
Chapter IV: Outcomes	23
Chapter V: Discussion	25
References.....	27
Appendices	
Appendix A. Patient Consent Form	32
Appendix B. Cervical Interventions	35

CHAPTER I: INTRODUCTION

Two thirds of the United States population may experience neck pain at one point in their life.^{1,2,3} Two common categories of neck pain are cervical radiculopathy and whiplash associated disorders (WAD). A patient may have examination findings or a medical history of both disorders. Although cervical radiculopathy and WAD can have very similar clinical presentations, their underlying etiology can differ.

Whiplash associated injuries are generally the result of acceleration-deceleration forces on the neck often incurred during a motor vehicle accident (MVA). Symptoms of whiplash associated disorders (WAD) may include neck pain or stiffness, arm pain, paresthesias of the upper extremity, and headaches.^{4,5} Difficulty with concentration and memory, emotional distress, depression, anxiety, fear, and anger can be associated with WAD related to disability, along with economic costs, and possible litigation.⁵

Degenerative disc disease or loss of normal cervical lordosis is often seen in radiographic imaging in individuals who experienced a whiplash injury. In one study, approximately one third of patients showed evidence of neural impingement by cervical discs two years after injury.^{5,6} Delayed recovery from a WAD has been associated with being female, having increased age, heightened initial pain, neurologic symptoms, and preexisting neck or low back pain.^{1,4,5,7} Localized muscle tenderness with palpation, decreased range of motion (ROM), and weakness of neck and shoulder muscles may also be present due to guarding.¹ Whiplash pain may be related to lesions of the cervical facet capsules or

degenerative changes, ligamentous strain, and disc protrusions.¹ Approximately half of patients diagnosed with a WAD experienced ongoing symptoms long-term.^{4, 8}

Cervical radiculopathies are most typically caused by either a disc herniation or spondylosis.^{1, 9, 10, 11} The incidence of cervical radiculopathy/disc herniation has been reported at approximately 83 per 100,000 individuals.^{1, 9, 10, 12, 13} Cervical disc herniation comprises approximately 20-25% of patient cases of neck pain,^{12, 14} and often leads to compression and inflammation of nerve roots which can give rise to sensory impairments, motor deficits, and radicular pain.^{1, 4, 9, 10, 12, 13} Symptoms related to cervical disc herniation are neck pain and stiffness, radiating pain to the shoulder or scapular area, upper extremity pain or weakness with possible paresthesia.^{1, 9, 10, 15} The location of symptoms depends on the nerve root affected.^{1, 9, 10} The C7 and C6 nerve roots, compressed by the C6-7 and C5-6 discs respectively, are the two most common nerve roots involved with cervical disc herniation.^{1, 10} Pain with or without numbness that travels from the neck to the biceps or lateral forearm, dorsal hand, and the web space of the first and second digits is a common sensory presentation of C6 nerve root compression. Motor weaknesses seen with C6 nerve compression are of the wrist extensors, biceps, and triceps. Brachioradialis or biceps deep tendon reflex may also be diminished or absent.^{1, 9, 10} These symptoms can be mistaken for carpal tunnel syndrome.^{1, 10} Nerve conduction studies are often required to rule this out.^{9, 10} Pain patterns for C7 involvement are located across the posterior shoulder, triceps, dorsal and lateral forearm, and dorsum of the third digit. Triceps, latissimus dorsi, wrist flexors, and

finger extensor weakness can be seen with C7 nerve compression. The triceps reflex may also be diminished or absent.^{1, 9, 10}

Cervical disc herniation can progress to myelopathy. Myelopathy is compression on the spinal cord resulting in upper motor neuron symptoms such as hyperreflexia, neck stiffness, clumsiness of gait, shoulder pain, unilateral or bilateral arm or hand paresthesia or other radicular symptoms. The gold standard used to diagnose myelopathy is magnetic resonance imaging (MRI) and changes in spinal cord signal intensity.^{9, 10, 16}

CHAPTER II: REVIEW OF RELATED LITERATURE

Several studies have shown excellent long-term outcomes for patients who had radiculopathy and were treated conservatively.⁹ While radicular pain, strength and sensory deficits may improve more quickly following surgery, there were no significant differences after one year between patients who underwent surgery or received conservative therapy.¹⁷

Conservative non-operative management of cervical radiculopathy is effective with the majority of patients.⁹ Mechanical traction, nerve mobilization, massage, joint manipulation or mobilization, and exercise are the common interventions utilized in a multimodal physical therapy plan of care (POC).^{4, 9, 18}

Mechanical Traction

There is inconclusive evidence supporting the use of traction to treat herniated cervical discs. One study reported insufficient evidence for using traction with chronic neck symptoms but reported more favorable evidence for its use with acute symptoms.^{9, 19} Better pain and disability outcomes are more widely seen when traction is used in conjunction with manual therapy and exercise.^{4, 20, 21} One study reported improvements in grip strength in patients with cervical radiculopathy when cervical mechanical traction was utilized as one component of a multimodal approach.¹⁵ In a randomized controlled trial, however, mechanical traction was not shown to improve pain, function, or disability any better when used with manual therapy and exercise compared to manual therapy and exercise alone in patients with cervical radiculopathy.¹³ Five variables were found to

predict increased success with traction intervention: peripheralization of pain during cervical mobility assessment; positive shoulder abduction test; positive upper limb neurodynamic tests; a decrease in symptoms with manual distraction; and being 55 years of age or older.^{4, 22} One study demonstrated similar results of six kilograms (13.2 pounds) or less applied manual traction as 12 kilograms (26.4 Lbs) applied mechanical traction in relieving pain related to the surrounding muscle structures.¹⁴ In a case where mechanical traction used with manual therapy and exercise was unsuccessful in alleviating pain and improving function, the patient had had a traumatic onset of cervical radiculopathy such as a motor vehicle accident.¹⁶ Although the overall efficacy of using mechanical traction to treat cervical radiculopathy has not been established, it is commonly utilized in clinical practice.²⁰ Traction is not recommended in patients with suspected myelopathy.⁹

Nerve Mobilization and Massage

Nerve mobilizations and massage are commonly utilized to treat patients with neck pain. Peripheral nerve glides have been shown to decrease neck and arm pain greater than cervical mobilization alone.^{4, 23} Moderate levels of evidence support the use of nerve glides to decrease pain in patients with neck and arm pain.⁴ Application of massage techniques alone for treatment of neck pain is not supported by research.²⁴ One study suggests massage is a safe intervention for treating chronic neck pain and that it may have clinical short-term effects of pain relief.²⁵ Though massage and nerve glides are not strongly supported by studies, patients report and physical therapists observe some level of therapeutic benefit to these interventions.⁴

Joint Manipulation and Mobilization

Strong evidence suggests that manipulation and mobilization of the cervical spine along with exercise is more effective in treating mechanical neck pain than when either intervention is used alone.⁴ Cervical manipulation is not suggested for treatment of cervical radiculopathy due to the risks of myelopathy or spinal cord injury.⁹ Several studies reported that manual therapy and exercise were successful in providing long-term pain relief for patients with chronic neck disorders, with or without headaches or radicular symptoms, when compared to a no-treatment control.^{4, 26, 27, 28} A plan of care including manipulation, mobilization, and exercise had greater improvements in short-term pain relief than one including just exercise alone.^{26, 27} This multimodal approach also was shown to be related to improvements in pain, function, quality of life, and patient satisfaction.^{26, 27, 29} There is some evidence to support using thoracic manipulation and mobilization to treat neck and related radicular arm pain.^{4, 30}

Exercise

Gentle ROM, stretching, and progression of isometric strengthening exercises has been shown to decrease pain and increase segmental stability.^{4, 9, 28} Stretching of the scalenes, upper trapezius, levator scapulae, pectoralis minor, and pectoralis major muscles has been reported as being effective in increasing ROM.^{4, 29} Strong evidence suggests the use of strengthening exercise²¹ and endurance training of the cervical and scapulothoracic musculature, especially the deep flexors²⁰, to decrease neck pain and headache.^{4, 29}

The purpose of this case report is to describe the conservative outpatient physical therapy intervention program that focused on nerve glides, soft tissue mobilization, joint mobilization and manipulation, and therapeutic exercises for a 47-year-old female patient experiencing bilateral cervical, upper thoracic, and upper extremity radicular symptoms.

CHAPTER III: CASE DESCRIPTION

The patient received co-evaluation and treatment by the physical therapist (PT) and student physical therapist (SPT). This case report adheres to the patient confidentiality requirements of the Health Insurance and Portability and Accountability Act. The patient agreed and gave written consent to participate in this case report. See Appendix A for example of consent form used.

Patient

A 47-year-old, right-hand dominant female was referred to outpatient physical therapy for evaluation and treatment of cervical radiculopathy. In January 2010, the patient experienced pain on both sides of her head and neck, which progressed to radiating pain in her upper thoracic region and bilateral upper extremities. Tingling was present in digits one through three on her right hand. She reported weakness in her left hand, thumb and second digit, which her primary physician initially thought was related to carpal tunnel syndrome. She was referred to a neurologist and underwent nerve conduction testing; results were normal and carpal tunnel syndrome was ruled out.

The patient noted she suffered a possible mild whiplash event four years prior while riding dune buggies. No medical treatment or examination was sought immediately following this injury, and no official diagnosis of whiplash was reported in her medical records. The patient noted she had experienced a recent episode of neck pain within the last year. In June 2009, the patient underwent cervical spine radiographic imaging and the results were normal. She did not relate the onset to any injury or occurrence and

stated that it resolved after three or four months. Upon return of her pain, an MRI conducted in April 2010 revealed mild disc space narrowing at the C5-6 levels with possible involvement of C6 nerve root. Mild degenerative narrowing was also found at the C6-7 disc space resulting in minimal spinal stenosis. The MRI also showed mild straightening of the normal lordosis of the cervical spine and normal size and signal of her cervical spinal cord. The patient's past medical history included seizures, anxiety/depression, and osteoporosis. She was receiving medical care to address these issues and reported no concerns at the time of evaluation. She reported smoking a half-pack of cigarettes per day. She denied any unusual fatigue, nausea, vomiting, night sweats, unrelenting night pain, or unexplained weight changes. The patient had received previous chiropractic treatment in 2005 consisting primarily of spinal adjustments, which relieved her neck pain. She also reported receiving prior occasional treatment from a massage therapist since 2005, which also relieved her pain.

The patient experienced difficulty every day with dressing and grooming tasks because of pain. Increased pain was also experienced with driving. She worked as a mammographer and reported difficulty with required tasks such as opening sterile packages, assisting with biopsies, reaching, grasping, and prolonged posturing of her neck. Sitting or rest breaks could not be effectively utilized due to the facility's high patient caseload and low employee staffing. Swimming was the patient's preferred method of exercise. She experienced high levels of pain while she swam in a prone position; she was able to swim supine with mild pain one to two times per week for

approximately 30 minutes. Prior to this episode of pain she was able to swim three to five times a week for an hour each time. The patient expressed her need to strengthen her left hand, gain general neck mobility, and become pain-free in order to perform her work tasks and participate in regular exercise without restrictions.

Examination

Upon examination, the PT and SPT identified impairments with appropriate tests and measures. Postural positioning and strain can complicate and contribute to symptoms.^{1, 31} During observation of dynamic and seated posture, the patient displayed a rigid neck. Mild forward and elevated shoulder posturing was noted as well. Gait and coordination during gait should also be observed for presentation of lower extremity weakness or clumsiness related to upper motor neuron damage, such as in the case of myelopathy.¹ Her gait pattern appeared neurologically intact with no instances of loss of balance or uncoordinated movements. However, stiff neck posturing and slightly decreased arm swing was displayed during gait.

Muscle, sensation, and reflex testing are components of the neurologic exam appropriate when a herniated disc is suspected.¹ Bilateral UE active and passive ROM, and strength measurements are shown in Table 1. Upper extremity active ROM was measured with a goniometer and the patient seated on the plinth using the protocol described by Norkin and White.³² The patient verbally noted medial radiating arm pain with active shoulder abduction bilaterally. Resisted isometric testing was used to assess contractile tissue function in relation to pain. Pain was elicited with resistance to all shoulder motions with

the exception of extension. Her right upper extremity demonstrated mild general weakness, while weakness was noted to be greater distally versus proximally on her left. The patient was not able to tolerate strength testing of scapular muscles. Her nerve pain was presumably inhibiting her ability to actively move through her likely available full passive shoulder ROM.

Table 1. Bilateral UE Active ROM and Strength Measurements at Initial Evaluation

Motion		Strength		Active ROM	
		Left	Right	Left	Right
Shoulder	Flexion	Strong and some pain	Strong and some pain	135°	110°
	Extension	Strong and no pain	Strong and no pain	WNL	WNL
	Abduction	Weak and painful	Weak and painful	58°	58°
	Adduction	Weak and painful	Weak and painful	WNL	WNL
Elbow	Flexion	Slightly weak and some pain	Slightly weak and some pain	WNL	WNL
	Extension	Slightly weak and no pain	Slightly weak and no pain	WNL	WNL
Wrist	Flexion	Slightly weak and no pain	Weak and no pain	WNL	WNL
	Extension	Slightly weak and no pain	Weak and no pain	WNL	WNL

Cervical ROM was measured according to standard positions described by Norkin and White³² using a goniometer for rotation and an inclinometer for flexion, extension, and lateral flexion motions. Measurements are shown in Figure 1. Cervical rotation ROM less than 60 degrees is also typical toward the side of the compromised nerve root.⁴ Cervical ROM measurement revealed dramatic limitations. Total pain-free motion comprised less than 50% of total expected normal cervical range. Restrictions were more pronounced to her left.

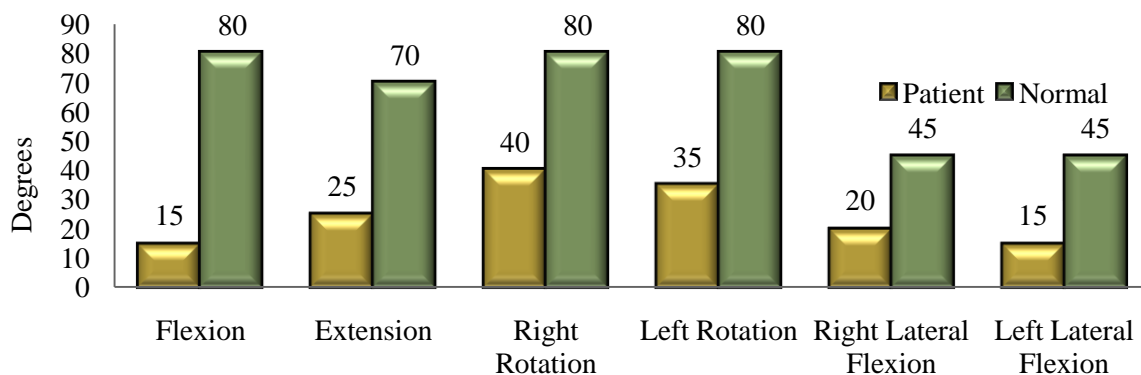


Figure 1. Cervical ROM at initial evaluation compared to normal values.²⁰ Specific motions are shown on the X axis and degrees of range on the Y axis. Green bars represent normal range values and yellow bars represent the patient's available range.

Deep tendon reflex testing was conducted on the patient's upper extremities. Bilateral brachioradialis reflexes were 1+ (diminished) and bilateral biceps reflexes were 2+ (normal). The triceps tendon reflexes were not tested due to pain with attempting to position the patient's arms. The diminished brachioradialis reflexes suggest possible C5 or C6 nerve root compromise. Positions and procedures utilized for reflex testing were as defined by Reese.³³

Spurling's, distraction, and upper limb tension tests are appropriate tests for patients with radicular symptoms and possible herniated disc tissue.⁴ Spurling's Test³¹ was performed with lateral flexion and overhead pressure applied by the therapist. The test was positive bilaterally for nerve root compression with a greater increase in symptoms when the left side was tested. Vertebral artery and ligament laxity screens of the alar³¹ and transverse ligaments should be performed for patient safety, especially in patient cases with a history of trauma or genetic risk of laxity.^{1,9} The rotational alar ligament test was

performed gently with the patient seated and was negative for instability of the connective tissues between the occiput and dens of C2. The patient was repositioned to supine for the following tests. The transverse ligament test was performed and was negative for instability at the C1-2 level. Muscles are a common generator of pain.¹ Nerves, bone, and ligamentous tissue can be the source of referral pain.⁴ The exact tissue that is the source of neck pain is often unknown.⁴ Considering this, palpation of muscles and assessment of joint mobility may be appropriate to help better understand possible origins of pain.^{1,31} Gentle manual cervical traction was applied, and the patient noted mild relief of symptoms, indicating possible nerve root compression. The upper trapezius, levator scapula, scalene, sternocleidomastoid, and paraspinal muscles elicited tenderness bilaterally when palpated. Her occipital region was also painful with palpation bilaterally. Passive intervertebral movement (PIVM) testing revealed pain and muscle guarding throughout the cervical spine. Lateral glide at C3-7, rotation at C1-2, and lateral glide and flexion at O-C1 were all restricted. The patient reported pulling and tightness throughout her upper thoracic region during PIVM testing. Cervical segmental mobility was difficult to assess due to muscle guarding and pain. Muscle length was also assessed and stretching of bilateral cervical musculature elicited verbal reports of tightness or restriction. Deep cervical flexors were found to be weak using test procedures as explained by Magee,³¹ except without the use of a pressure cuff. She was unable to hold the chin-tuck position because of pain and could not tolerate full muscle endurance testing.

Evaluation/ Diagnosis/ Prognosis

The patient was experiencing a decrease in function of the cervical spine and bilateral upper extremities during work and exercise due to increased pain, decreased upper body and cervical muscle strength, and decreased cervical muscle flexibility. Scapular muscle weakness was assumed due to the forward shoulder posture she displayed. The patient's symptoms were consistent with her physician's referral for cervical radiculopathy, MRI findings of cervical disc herniation, and *Guide to Physical Therapist Practice*³⁴ Preferred PT Practice Pattern Musculoskeletal Pattern F- Impaired Joint Mobility, Motor Function, Muscle Performance, Range of Motion, and Reflex Integrity Associated With Spinal Disorders. Based on the PT and SPT's clinical experience, the patient's prognosis with skilled PT services was determined to be fair to good. Despite her prior history of neck pain, she displayed good motivation to participate in physical therapy intervention. The patient appeared ready to adhere to a home exercise program focusing on return to daily tasks with decreased pain.

The following goals were established at the time of initial evaluation to address the patient's pain, limited ROM, and strength deficits, and return to function.

1. In two weeks, the patient will report decreased overall pain by 25%.
2. ROM will increase by 25% in two weeks.
3. In 12 weeks, the patient will increase left grip strength in order to open sterile packages without difficulty.
4. In 12 weeks, the patient will complete a week of work tasks with limited or no reports of symptoms.
5. In 12 weeks, the patient will swim on her stomach with 0-3/10 pain in order to return to her regular exercise routine.

The patient agreed to the plan of care addressing the goals above with modalities, therapeutic exercise, and manual therapy as part of the cervical intervention program.

Intervention

The patient was seen one to two days each week as her schedule allowed. She was seen for a total of 8 intervention days over approximately six weeks. All interventions performed during the course of treatment are described in Appendix B. Numerical pain ratings were given at the beginning and end of every patient visit. Minimal clinically important change for the numeric pain rating scale is 1.3 – 2.2 points on a 10-point scale.^{13, 35, 36}

On day one, intervention followed the PT examination and evaluation. The patient displayed understanding and good technique with the first exercises she was instructed in. The patient was educated to perform the exercises within a comfortable range of motion. Neck rotation, flexion and extension were given and side bending was avoided to reduce nerve root compression. Side bend motions produced greater pain than other motions. Also, to avoid increased pain with supine thoracic self-mobilization with a towel roll, she was instructed to rest her arms on her stomach. After osteopathic spinal manipulation she reported breathing easier with reduced thoracic pain. The main goal of the exercises was to slowly return the patient to non-painful cervical and thoracic motion.

On intervention day two, the patient came in without report of changes in pain levels. However, she displayed good technique and adherence with her home exercises. In addition to her herniated cervical disc, peripheral nerve restrictions were suspected. The SPT conducted upper limb neurodynamic testing as described by Magee.³¹ Tests for

radial, median, and ulnar nerves were positive bilaterally. Greater sensitivity was found while testing her right upper extremity compared to her left. She was then instructed in nerve glide exercises. The exercises were more easily performed with a neutral neck position while the distal UE was positioned appropriately and actively assisted through each nerve glide. She was instructed to perform the gliding exercises into slight discomfort then back into a non-painful range. Wand exercises for shoulder flexion and abduction were also initiated to promote UE elevation range of motion without pain. She was also instructed in the corner stretch to increase extensibility of her pectoralis minor muscles to promote decreased forward shoulder posturing. Following the manual therapy and mobilization interventions, she reported less pain when performing chin-tucks and other cervical motions. The patient also completed the Neck Disability Index (NDI) in order to better assess improvement with her symptoms. The NDI is a reliable and valid measure for assessing pain and disability associated with neck pain resulting from musculoskeletal dysfunction, whiplash, or cervical radiculopathy.^{4, 37} Minimal detectable change is 5/50 – 10/50 for cervical radiculopathy.^{4, 37} A seven point change on the NDI indicates a clinically important difference reflecting improvements or further declines in function.^{37, 38, 39} Her score was 14/50 or 28 percentage points. This score is suggestive of mild disability.^{37, 40, 41}

On day three, the patient arrived with greatly reduced thoracic pain and reported improved productivity at work. She was able to keep a copy of her exercises at work and completed them when she started to feel tension or increased pain. The SPT then re-

measured bilateral shoulder flexion range of motion. The patient elevated her right shoulder into 162 degrees of flexion and her left into 157 degrees of flexion. Grip strength was also measured bilaterally using a hydraulic hand dynamometer. At position one, her right was 60 pounds and her left was 30 pounds. At position four, her right was 40 pounds and her left was still 30 pounds. The patient was started on the upper body ergometer (UBE) to promote active use of her upper extremities and to warm-up her muscles for the rest of the therapy session. Cervical retraction was performed on a therapy ball to increase focus on posture. Overall, the patient's pain pattern changed since initial evaluation. Her upper thoracic pain was relatively absent but her neck and headache pain remained. Considering the change in her pain pattern, a trial of mechanical cervical traction was conducted. Prior to treatment the patient noted pain relief with grade III manual cervical spine traction. Cervical traction was applied to promote further joint surface distraction to relieve possible compressed nerve roots.⁴² For this purpose, a traction force of 20-29 pounds is recommended. During mechanical traction, cervical flexion is used to target separation of posterior structures such as the facets and intervertebral foramina.⁴² A more neutral position is used to target anterior structures such as the disc spaces.⁴² An angle of 15 degrees of cervical flexion was used for possible affects on all structures mentioned. The patient verbally noted some relief of her neck and hand symptoms during and after the mechanical traction session. The supine positioning did aggravate her lower back. Depending on her tolerance of the initial traction treatment, alternative positions or parameters were considered for future sessions.

On day four, the patient reported a slight return of pain in her upper thoracic region and pain remaining through her neck and head. She attributed the pain to the mechanical traction session. She also noted increased stress with work and the inability to perform her home exercises consistently. Mechanical cervical traction was discontinued due to the increase in patient symptoms. Soft tissue mobilization (STM), which can be an appropriate option to treat muscle tension and headaches, was used to reduce the patient's pain and promote tissue extensibility, both of which were likely limiting her cervical range of motion. See Appendix B for details. Greater tension and sensitivity was found on the patient's right upper trapezius and sternocleidomastoid muscles and her left levator scapula and paraspinal muscles. Her suboccipital region was also tender and the patient was educated in the home use of tennis balls to provide a suboccipital release at home as the patient may have needed it. The SPT recommended that other upper back and neck muscles be treated with tennis balls at home with a trigger point type technique. The patient verbally reported relief with STM treatment.

On day five, the patient received treatment from the physical therapist assistant. The patient reported that she had experienced an overall decrease in pain since initial evaluation. She had not felt much improvement in shoulder and neck range of motion. She also stated that the numbness and tingling in her hands and arms was persisting. Seated scapular retraction/adduction without resistance was initiated by the SPT to slowly begin progression of strengthening exercises to improve her posture. The patient experienced radiating pain with this exercise. Again, she was instructed to perform this

exercise in a pain-free range of motion. The patient was seated in the massage chair during the manual therapy intervention to prevent aggravation of her lower back pain. See Appendix B for details.

On day six the patient was seen by the physical therapist assistant again. She came in with increased pain and muscle tightness. She also had increased difficulty performing range of motion and flexibility exercises. Pendulum exercises were given to help relieve pain. She verbally noted decreased pain with this exercise.

On day seven the patient was re-evaluated by the SPT. Her neck and shoulder range of motion was measured and recorded as shown in Table 3.

Table 3. Cervical and Shoulder ROM at Re-Evaluation

Cervical	Flexion	35°	
	Extension	34°	
		Right	Left
	Rotation	50°	52°
	Lateral Flexion	30°	15°
Shoulder		Right	Left
	Flexion *(160°)	135°	116°
	Abduction *(58°)	37°	35°

*Greatest range measured bilaterally on intervention day three, prior to re-evaluation.

All neck motions improved except for left lateral flexion. Shoulder flexion ROM was less than previously measured on intervention day three yet still improved from or equal to the initial PT evaluation. Shoulder abduction was decreased bilaterally as compared to day one and day three measurements. Range was limited primarily due to radiating pain. Strength was re-assessed and no changes were found since initial evaluation. The patient

reported having slight decreased tingling and numbness in her hands. Her grip strength remained impaired and continued to be an issue with work tasks. Dynamometer measurements reflected weakness and were the same as day three values. In general, the patient felt there had been gains in decreasing her pain and increasing her neck motion. She still felt very much limited by her lack of pain-free active shoulder motion and by her grip weakness. Her skills to self manage her pain at home and work had improved. Goals one and two set at initial evaluation were deemed partially met and the other goals were not met at the time of re-evaluation. Physical therapy intervention was verbally noted by the patient to have been beneficial, and she agreed with continuing physical therapy to treat her symptoms. A moist hot pack was applied to thoracic spine simultaneously with an aggressive cervical STM and joint mobilization session to promote greater pain relief and tissue mobility.⁴² The SPT discussed with the patient that strengthening exercises would be progressed as the patient's pain decreases and ROM increases, at which time manual therapy interventions would be reduced. At this point in the physical therapy intervention, it was obvious the patient enjoyed manual therapy and felt it was helping. However, the SPT felt it was important to stress the transition to and benefits of active exercise in reducing her symptoms. Biofeedback was added to neck retraction to progress deep cervical flexor strengthening. The patient had increased pain and tingling with this activity. Resisted bilateral scapular retraction while standing was also initiated; however, she was still unable to perform this exercise without increased pain.

On day eight, the patient noted slightly increased pain compared to day seven. Aggressive soft tissue mobilization and moist hot pack were again used for increasing tissue extensibility and for pain relief.⁴² A side-lying scapular release performed bilaterally was added to the manual therapy intervention due to observed scapular restrictions. The patient noted good relief following the manual techniques. Since abduction was the primary shoulder motion that was limited, pulleys were used in a scaption motion. The patient felt no pain during this activity and expressed joy with being able to elevate her arms. Also, since bilateral resisted scapular retraction/adduction was painful, unilateral strengthening was attempted. The patient had no pain but scapular muscle weakness was observed bilaterally with decreased control with this exercise. Tactile and verbal cues given by the SPT improved the patient's technique. The patient was given resistive tubing to perform this strengthening exercise at home. The plan for the next patient visit was to continue with progression of general strengthening for her upper extremities, scapular, and cervical muscles.

The patient went on vacation for a week following intervention day eight and did not return to therapy to continue treatment. She did not communicate her reasons for not returning to physical therapy; she may have sought other professional help or her symptoms may have resolved enough so that she could self-manage them at home. In the original plan of care, two patient visits were planned each week, but due to missed appointments, the patient had two visits during just one of the intervention weeks. Three visits were missed in total, before visits three, five, and seven. She did return a follow-up

NDI, indicating changes in her limitations. The NDI score was 19/50 or 38 percentage points. This was five points or 10 percent higher than her first NDI, which indicated that a minimal detectable change had occurred. A change of seven points is needed for a clinically important difference, however. Considering this, her score suggested a change of her status from mild to moderate disability.^{37, 40, 43} A QuickDASH outcome tool was also completed and returned: the patient scored 36.4/100 on the QuickDASH portion and 25/100 on the work module. Both scores are on a scale of 100 with higher scores indicating greater disability.⁴⁴ Based on this scale, 0- 25 percent is no to mild difficulty, 25-50 percent is mild to moderate difficulty, 50-75 percent is moderate to severe difficulty, and greater than 75 percent is severe difficulty; the patient's scores suggest mild to moderate functional difficulty. There is a lack of research to suggest level of functional difficulty based on QuickDash scores related to radiculopathy.

CHAPTER IV: OUTCOMES

Six weeks after initial evaluation, the patient reported decreased overall pain, displayed improved cervical range of motion and bilateral shoulder flexion range of motion. Upper extremity and scapular strength did not improve. This result was expected since only a few strengthening exercises were implemented during the initial phase of her plan of care. Tolerance to work and exercise activity did improve since the start of treatment as did pain self-management skills. Refer to Figures 1 and 2 for progress made during the course of conservative cervical physical therapy intervention.

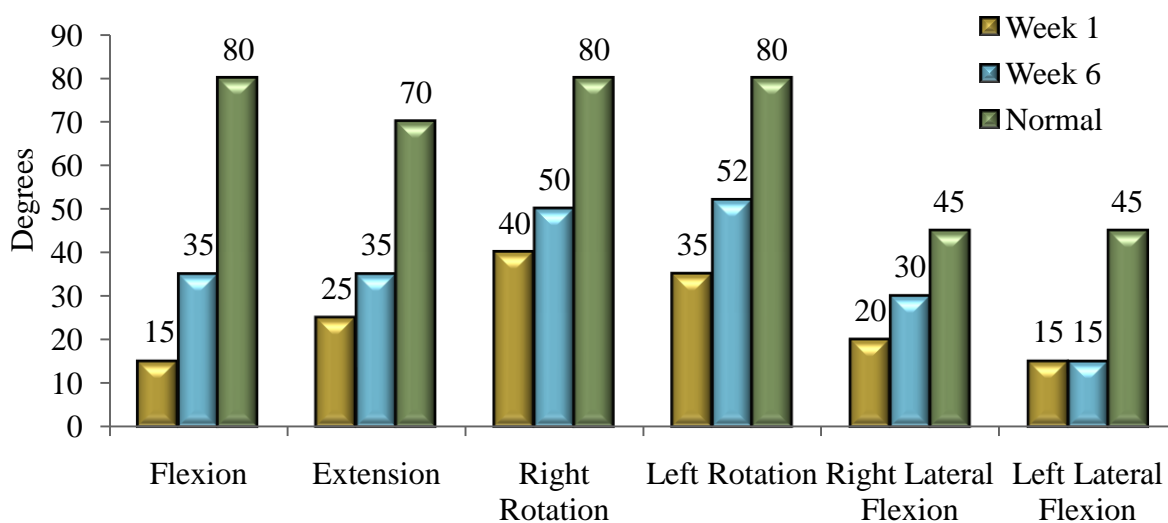


Figure 2. Cervical range of motion improvements over six weeks of Intervention.

As shown in Figure 2, flexion, extension, right rotation, left rotation, and right lateral flexion all improved but remained restricted compared to normal. Limited active shoulder range of motion persisted due to pain.

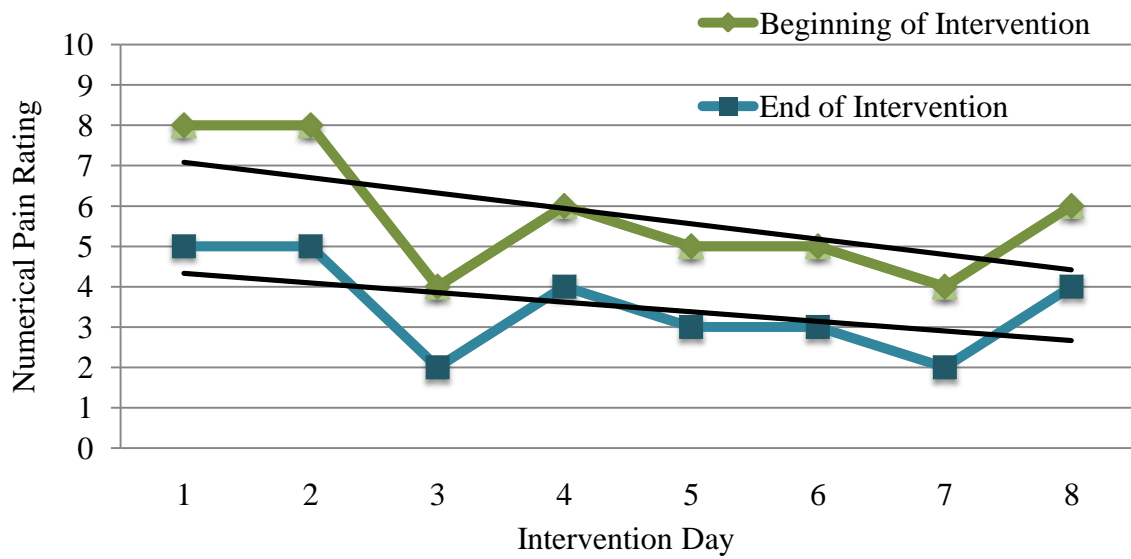


Figure 3. Trends in numerical pain ratings at beginning and end of eight intervention days.

Figure 3 shows that the patient had a decrease in pain within each session and over the course of six intervention weeks.

CHAPTER V: DISCUSSION

This case report describes the conservative outpatient interventions focusing on manual therapy and therapeutic exercises utilized for a 47-year-old female patient experiencing bilateral cervical, upper thoracic, and upper extremity radicular symptoms. Over the course of six weeks of physical therapy, the patient progressed in areas of reduced pain, increased cervical ROM and self-management skills. Shoulder ROM and UE strength did not improve. Cervical mechanical traction was trialed but unsuccessful with this patient and may have contributed to increased pain per patient report. Research suggests when there is a traumatic onset of cervical radiculopathy, mechanical traction may be less effective in alleviating pain and improving function.¹⁶ Resistance strengthening was not able to be aggressively implemented. This was likely related to high patient pain ratings and missed patient visits. Therapy sessions were slow to progress as the patient was seen one visit each week on average. Ultimately, this patient presented with very complex symptoms which may have been related to both an unresolved mechanical whiplash disorder and radiculopathy. It is also possible that this is a complicated patient case of chronic pain.

Retrospectively, separate pain scales for upper thoracic and neck areas would have been useful to better assess improvements or increases in pain of specific areas and to improve documentation of outcomes. Also, the Patient Specific Functional Scale could have been used to assess individual changes in the patient's function due to its level of sensitivity to change.⁴⁵ Research suggests a psychosocial component related to neck pain.^{46, 47} The

patient appeared to remain motivated with mild anxiety noted. A greater focus on relaxation techniques may have been beneficial in treating this patient to address her anxiety.

The interventions detailed throughout this report are supported by research and may be related to changes in this patient's impairments and function. An estimated one third of patients with cervical radiculopathy who were treated conservatively had some unalleviated symptoms.^{9, 48} Approximately 30 percent of patients experiencing cervical radiculopathy symptoms had recurrence of symptoms and 25 percent required surgery for unalleviated pain, sensory or motor deficits.¹² Few studies are available to represent cases in which conservative treatment for cervical radiculopathy is unsuccessful and who potentially may require surgical referral. This case report helps to give current insight into one such possible rehabilitation experience. Recent prospective studies are needed to establish consistent manual therapy and exercise parameters and definitions to improve comparison across studies researching patients experiencing cervical radiculopathy.

REFERENCES

1. Devereaux M. Neck pain. *The Medical Clinics Of North America*. March 2009;93(2):273.
2. Cote P, Cassidy JD, Carroll L, et al. The Saskatchewan health and back pain survey: the prevalence of neck pain and related disability in Saskatchewan adults. *Spine*. 1998; 1689-98.
3. Croft PR, Lewis M, Papegegiou AC, et al. Risk factors for neck pain: a longitudinal study in the general population. *Pain*. 2001;93:317-25.
4. Childs J, Cleland J, Elliott J, et al. Neck pain: Clinical practice guidelines linked to the International Classification of Functioning, Disability, and Health from the Orthopedic Section of the American Physical Therapy Association. *J Orthop Sports Phys Ther*. September 2008;38(9):A1-A34.
5. Yadla S, Ratliff J, Harrop J. Whiplash: diagnosis, treatment, and associated injuries. *Current Reviews In Musculoskeletal Medicine*. March 2008;1(1):65-68.
6. Petterson K, et al. Disc pathology after whiplash injury: a prospective magnetic resonance imaging and clinical investigation. *Spine*. 1997;22:283-7.
7. Dufton JA, et al. Prognostic factors associated with minimal improvement following acute whiplash-associated disorder. *Spine*. 2006;20:E759-65.
8. Bunketorp L, Nordholm L, Carlsson J. A descriptive analysis of disorders in patients 17 years following motor vehicle accidents. *Eur Spine J*. 2002;11:227-234.
9. Eubanks J. Cervical radiculopathy: nonoperative management of neck pain and radicular symptoms. *Am Fam Physician*. January 1, 2010;81(1):33-40.
10. Abbed K, Coumans J. Cervical radiculopathy: pathophysiology, presentation, and clinical evaluation. *Neurosurgery*. January 2007;60(1 Suppl 1):S28-S34.
11. Algren B, Garfen S. Cervical radiculopathy. *Orthop Clin North Am*. 1996;27:253-63.
12. Radhakrishman K, Litchy W, O'Fallon W, et al. Epidemiology of cervical radiculopathy: a population-based study from Rochester, Minnesota, 1976 through 1990. *Brain*. 1994;117:325-35.

13. Young I, Michener L, Cleland J, Aguilera A, Snyder A. Manual therapy, exercise, and traction for patients with cervical radiculopathy: a randomized clinical trial. *Phys Ther.* July 2009;89(7):632-642.
14. Jellad A, Ben Salah Z, Boudokhane S, Migaou H, Bahri I, Rejeb N. The value of intermittent cervical traction in recent cervical radiculopathy. *Annals Of Physical And Rehabilitation Medicine.* November 2009;52(9):638-652.
15. Joghataei M, Arab A, Khaksar H. The effect of cervical traction combined with conventional therapy on grip strength on patients with cervical radiculopathy. *Clin Rehabil.* December 2004;18(8):879-887.
16. Cook C, Roman M, Stewart K, Leithe L, Isaacs R. Reliability and diagnostic accuracy of clinical special tests for myelopathy in patients seen for cervical dysfunction. *J Orthop Sports Phys Ther.* March 2009;39(3):172-178.
17. Persson L, Moritz U, Brandt L, Carlsson C. Cervical radiculopathy: pain, muscle weakness and sensory loss in patients with cervical radiculopathy treated with surgery, physiotherapy or cervical collar. A prospective, controlled study. *European Spine Journal: Official Publication Of The European Spine Society, The European Spinal Deformity Society, And The European Section Of The Cervical Spine Research Society.* 1997;6(4):256-266.
18. Hoving J, de Vet H, Koes B, et al. Manual therapy, physical therapy, or continued care by the general practitioner for patients with neck pain: long-term results from a pragmatic randomized clinical trial. *Clin J Pain.* May 2006;22(4):370-377.
19. Graham N, Gross A, Goldsmith CH, et al. Mechanical traction for neck pain with or without radiculopathy. *Cochrane Database Systematic Reviews.* 2008;(3):CD006408.
20. Cleland J, Fritz J, Whitman J, Heath R. Predictors of short-term outcome in people with a clinical diagnosis of cervical radiculopathy. *Phys Ther.* December 2007;87(12):1619-1632.
21. Cleland J, Whitman J, Fritz J, Palmer J. Manual physical therapy, cervical traction, and strengthening exercises in patients with cervical radiculopathy: a case series. *J Orthop Sports Phys Ther.* December 2005;35(12):802-811.

22. Raney N, Petersen E, Smith T, et al. Development of a clinical prediction rule to identify patients with neck pain likely to benefit from cervical traction and exercise. *European Spine Journal: Official Publication Of The European Spine Society, The European Spinal Deformity Society, And The European Section Of The Cervical Spine Research Society*. March 2009;18(3):382-391.
23. Allison GT, Nagy BM, Hall T. A randomized clinical trial of manual therapy for cervico-brachial pain syndrome- - a pilot study. *Manual Therapy*. 2002;7:95-102.
24. Ezzo J, Haraldsson B, Gross A, et al. Massage for mechanical neck disorders: a systematic review. *Spine*. February 1, 2007;32(3):353-362.
25. Sherman K, Cherkin D, Hawkes R, Miglioretti D, Deyo R. Randomized trial of therapeutic massage for chronic neck pain. *Clin J Pain*. March 2009;25(3):233-238.
26. Miller J, Gross A, D'Sylva J, et al. Manual therapy and exercise for neck pain: a systematic review. *Manual Therapy*. August 2010;15(4):334-354.
27. Gross A, Hoving J, Haines T, et al. A Cochrane review of manipulation and mobilization for mechanical neck disorders. *Spine*. July 15, 2004;29(14):1541-1548.
28. Kay T, Gross A, Goldsmith C, Hoving J, Brønfort G. Exercises for mechanical neck disorders. *Cochrane Database of Systematic Reviews*. September 2005;(3).
29. Walker M, Boyles R, Young B, et al. The effectiveness of manual physical therapy and exercise for mechanical neck pain: a randomized clinical trial. *Spine*. October 15, 2008;33(22):2371-2378.
30. González-Iglesias J, Fernández-de-las-Peñas C, Cleland J, Gutiérrez-Vega M. Thoracic spine manipulation for the management of patients with neck pain: a randomized clinical trial. *J Orthop Sports Phys Ther*. 2009;39(1):20-27.
31. Magee DJ. *Orthopedic Physical Assessment*. 5th ed. St. Louis, Mo: Saunders; 2008.
32. Norkin CC, White DJ. *Measurement of Joint Motion: A Guide to Goniometry*. 3rd ed. Philadelphia, Pa: F.A. Davis Co; 2003.
33. Reese NB. *Muscle and Sensory Testing*. 2nd ed. Philadelphia, Pa: Saunders; 2005.
34. American Physical Therapy Association. *Guide to Physical Therapist Practice*. 2nd ed. Alexandria, Va: American Physical Therapy Association; 2003.

35. Cleland J, Childs J, Whitman J. Psychometric properties of the Neck Disability Index and Numeric Pain Rating Scale in patients with mechanical neck pain. *Arch Phys Med Rehabil*. January 2008;89(1):69-74.
36. Young I, Cleland J, Michener L, Brown C. Reliability, construct validity, and responsiveness of the neck disability index, patient-specific functional scale, and numeric pain rating scale in patients with cervical radiculopathy. *Am J PM R/ AAP*. October 2010;89(10):831-839.
37. MacDermid J, Walton D, Avery S, et al. Measurement properties of the neck disability index: a systematic review. *J Orthop Sports Phys Ther*. May 2009;39(5):400-417.
38. Cleland JA, Fritz JM, Whitman JM, Palmer JA. The reliability and construct validity of the Neck Disability Index and patient specific functional scale in patients with cervical radiculopathy. *Spine*. 2006;31:598-602.
39. Stratford PW, Riddle DL, Binkley JM, Spadoni G, et al. Using the Neck Disability Index to make decisions concerning individual patients. *Physiother Canada*. 1999;51:107-112.
40. Vernon HT. Assessment of self-rated disability, impairment and sincerity of effort in whiplash-associated disorder. *J Musculoskel Pain*. 2000;8:155-167.
41. Miettinen T, Leino E, Airaksinen O, Lindgren KA. The possibility to use simple validated questionnaires to predict long-term health problems after whiplash injury. *Spine*. 2004;29:E47-51.
42. Cameron MH. *Physical Agents in Rehabilitation*. 2nd ed. St. Louis, MO: Saunders; 2003.
43. Sterling M, Jull G, Vicenzino B, Kenardy J. Characterization of acute whiplash-associated disorders. *Spine*. 2004;29:182-188.
44. Institute for Work and Health. The QuickDASH outcome measure: a faster way to measure upper-extremity disability and symptoms. http://www.dash.iwh.on.ca/assets/images/pdfs/quickdash_info_2010.pdf. Published 2006. Updated June 30, 2010. Accessed August 2010.
45. Pietrobon R, Coeytaux R, Carey T, Richardson W, DeVellis R. Standard scales for measurement of functional outcome for cervical pain or dysfunction: a systematic review. *Spine*. March 1, 2002;27(5):515-522.

46. Persson L, Lilja A. Pain, coping, emotional state and physical function in patients with chronic radicular neck pain. A comparison between patients treated with surgery, physiotherapy or neck collar -- a blinded, prospective randomized study. *Disabil Rehabil.* May 20, 2001;23(8):325-335.
47. Wedding D, Stuber ML, eds. *Behavior & Medicine*. 4th ed. Cambridge, Ma: Hogrefe & Huber; 2006.
48. Lees F, Turner JW. Natural history and prognosis of cervical spondylosis. *Br Med J.* 1963;2(5373):33-88

Appendix A: Case Report Information and Consent Form

Introduction:

You are invited to be the subject of a case report to be written by _____, Doctor of Physical Therapy graduate student/s from St Catherine University, under the supervision of Mary Weddle, PT, DSc, Doctor of Physical Therapy program faculty member, and _____, the student's clinical instructor/s. You were selected as a possible subject for this case report because your course of physical therapy care would be of interest to physical therapist students and physical therapists. Please read this form and ask questions before you agree to be the subject of this case report.

Background Information:

The purpose of this case report is to describe the physical therapy care you are receiving and how you respond to the care you are receiving at

(name and address of facility).

For example, the case report would describe the following:

1. why you are receiving physical therapy at this time;
2. the kinds of physical therapy treatment/s you are receiving at this time;
3. the effectiveness of the physical therapy treatment for you at this time.

This case report will help others better understand how physical therapy may help other people like you.

Procedures:

Your decision about participation will not affect your physical therapy care in any way. If you decide to participate, your physical therapy care will proceed just as it would if you were to decide not to participate. If you decide to participate, you may choose whether or not you will allow the following:

1. whether your photograph can be taken and used in public presentation and/or publication of this case report;
2. whether what you say can be quoted directly in the case report.

You may be given an opportunity to read or review parts, or all, of the case report prior to its completion, so that you can make suggestions to the student about the accuracy of the information described in the case report. You are not obligated to read/review the case report, however.

The case report will be read by the student's faculty supervisor, Mary Weddle. This case report may be read by the physical therapist/s supervising the student at this facility. The case report will be presented publicly by the student/s at St Catherine University Doctor of Physical Therapy Program Research Day. This

case report would be available for students and faculty at the St Catherine University to read. The case report may also be published in a scientific journal and/or presented at a professional meeting locally or nationally.

Risks and Benefits:

There are no risks or benefits to you for participating in this case report.

Confidentiality:

Any information obtained in connection with this case report that could identify you will be disclosed only with your permission. Unless stated otherwise, your name, or names of your family members, will not be used in any way in the case report.

Voluntary nature of this case report:

Participation in this case report is voluntary. Your decision whether or not to participate will not affect your future relations with the St Catherine University, or with the facility at which you are receiving physical therapy. If you decide to participate, you are free to discontinue participation at any time without affecting these relationships.

Contacts and questions:

You are encouraged to ask the student or the physical therapist supervising the student any questions about this case report, at any time. You may also contact the student's faculty supervisor, Mary Weddle, if you have any questions, at any time.

You may keep a copy of this consent form for your records.

See next page for Statement of Consent

Statement of Consent:

You are making a decision whether or not to participate in this case report. Your signature indicates that you have read this information and your questions have been answered. Even after signing this form, please know that you may discontinue your participation in this case report, at any time.

I agree to participate in this case report. Yes ____ No ____

I agree to being quoted directly in this case report. Yes ____ No ____

I agree to being photographed and having the photographs included in the public presentation and/or publication of this case report. Yes ____ No ____

If the student wishes to have me read or review the case report prior to its completion, the student may contact me, after my course of physical therapy is complete. If I check no, that means I do not want the student to contact me at any time, after my course of physical therapy is complete.

Yes ____ No ____

Signature of subject Date

Student's signature Date _____

Faculty member supervising the student:

Mary Weddle, PT, DSc
Associate Professor and Director of Clinical Education
Doctor of Physical Therapy Program
St Catherine University
601 25th Avenue South
Minneapolis, MN 55454
Phone: 651-690-7806

Appendix B. Cervical Interventions

Intervention Day	Therapeutic Exercise	Manual Therapy	Modalities	Numerical Pain Rating
1 30 min eval	<ul style="list-style-type: none"> -Neck AROM: rotation/flexion/extension 1 set x 10 reps each motion -Upper trapezius stretch 5 reps x 30 seconds -Seated neck retraction 1 set x 10 reps -Supine thoracic self-mobilization 1 set x 30 seconds -15 min of therapeutic exercise 	<ul style="list-style-type: none"> -Osteopathic spinal manipulation with opening to mid thoracic spine approximately at T5 		Beginning: 8/10 End: 5/10
2	<ul style="list-style-type: none"> -AAROM for bilateral shoulder flexion and abduction with wand while standing 1 set x 15 reps each -Bilateral corner stretch 4 reps x 30 seconds -Upper limb nerve glides for median, radial, and ulnar nerves bilaterally 1 set x 10 reps x 1 sec each -30 min of therapeutic exercise 	<ul style="list-style-type: none"> -Osteopathic spinal manipulation with opening to mid thoracic spine approximately at T5 -Cervical spine distraction grades I-II -Occiput –C5 joint mobilizations oscillatory grades III-IV -Posterior-anterior upper thoracic spine (T1-3) joint mobilizations oscillatory grades III-IV -15 min manual therapy 		Beginning: 8/10 End: 5/10
MISSED VISIT				
3	<ul style="list-style-type: none"> -Upper body ergometer (UBE) Alternating forward and reverse for 30 seconds for 5 minutes total -Neck AROM: rotation/flexion/extension 1 set x 10 reps each motion -Upper trapezius stretch 5 reps x 30 seconds -Seated neck retraction 1 set x 10 reps -AAROM for bilateral shoulder flexion and abduction with wand while standing 1 set x 15 reps each -Bilateral corner stretch 4 reps x 30 seconds -Upper limb nerve glides for median, radial, and ulnar nerves bilaterally 1 set x 10 reps x 1 sec each -Neck retraction seated on green therapy ball: 2 reps x 30 seconds -40 min of therapeutic exercise 	<ul style="list-style-type: none"> -Osteopathic spinal manipulation with opening to mid thoracic spine approximately at T5 -5 min manual therapy 	<ul style="list-style-type: none"> -Static supine mechanical cervical traction on an *Empi Saunders cervical traction device x 15 minutes at 25 pounds and 15 degrees of flexion -15 min mechanical traction 	Beginning: 4/10 End: 2/10

4	<ul style="list-style-type: none"> -Upper body ergometer (UBE) Alternating forward and reverse for 30 seconds for 5 minutes total -AAROM for bilateral shoulder flexion and abduction with wand while standing 1 set x 15 reps each -Bilateral corner stretch 2 reps x 30 seconds -Upper limb nerve glides for median, radial, and ulnar nerves bilaterally 1 set x 10 reps x 1 sec each -25 min of therapeutic exercise 	<ul style="list-style-type: none"> -Soft tissue mobilization and trigger point release to bilateral suboccipital regions, upper traps, levator scapulae, paraspinals, scalenes, and active release on the sternocleidomastoid muscles -Occiput –C5 joint mobilizations sustained grade II -20 min manual therapy 		<p>Beginning: 6/10 End: 4/10</p>
MISSED VISIT				
5	<ul style="list-style-type: none"> -Upper body ergometer (UBE) Alternating forward and reverse for 30 seconds for 5 minutes total -Neck AROM: rotation/flexion/extension 1 set x 10 reps -Upper trapezius stretch 5 reps x 30 seconds -Bilateral corner stretch 2 reps x 30 seconds -Upper limb nerve glides for median, radial, and ulnar nerves bilaterally 1 set x 10 reps x 1 sec each -Neck retraction seated on green therapy ball 1 set x 10 reps -Supine thoracic self-mobilization 1 set x 30 seconds -Bilateral scapular adduction/retraction 1 set x 10 reps seated with no resistance -15 min of therapeutic exercise 	<ul style="list-style-type: none"> --Soft tissue mobilization and trigger point release to bilateral suboccipital regions, upper traps, levator scapulae, paraspinals, scalenes, and active release on the sternocleidomastoid muscles -Gentle grade I-II manual cervical traction -25 min manual therapy 		<p>Beginning: 5/10 End: 3/10</p>
6	<ul style="list-style-type: none"> -Upper body ergometer (UBE) Alternating forward and reverse for 30 seconds for 5 minutes total -AAROM for bilateral shoulder flexion and abduction with wand while standing 1 set x 15 reps each -Seated upper trapezius stretch 5 reps x 30 seconds -Neck retraction seated on green therapy ball 1 set x 10 reps -Pendulum: 1 set x 10 reps bilaterally -15 min of therapeutic exercise 	<ul style="list-style-type: none"> -Soft tissue mobilization and trigger point release to bilateral suboccipital regions, upper traps, levator scapulae, paraspinals, scalenes, and active release on the sternocleidomastoid muscles -Gentle grade I-II manual cervical traction -25 min manual therapy 		<p>Beginning: 5/10 End: 3/10</p>
MISSED VISIT				

7 15 min re-eval	<ul style="list-style-type: none"> -Upper body ergometer (UBE) Alternating forward and reverse for 30 seconds for 5 minutes total -AAROM for bilateral shoulder flexion and abduction with wand while standing 1 set x 15 reps each -Neck retraction using blood pressure cuff 1 set x 10 reps -Bilateral scapular adduction/retraction 1 set x 10 reps Theratube level 3 -15 min of therapeutic exercise 	<ul style="list-style-type: none"> -Soft tissue mobilization and trigger point release to bilateral suboccipital regions, upper traps, levator scapulae, paraspinals, scalenes, and active release on the sternocleidomastoid muscles -Gentle grade I-II manual cervical traction -Occiput –C5 joint mobilizations sustained grade II -15 min manual therapy 	<ul style="list-style-type: none"> -Moist hot pack to upper thoracic spine x 15 minutes while in supine simultaneous with manual therapy treatment 	<ul style="list-style-type: none"> Beginning: 4/10 End: 2/10
8	<ul style="list-style-type: none"> -Upper body ergometer (UBE) Alternating forward and reverse for 30 seconds for 5 minutes total -Neck AROM: rotation/flexion/extension 1 set x 10 reps -Bilateral corner stretch 2 reps x 30 seconds -Unilateral scapular retraction/adduction 1 set x 10 reps each side Theratube level 3 -Bilateral pulleys in scaption x 6 minutes -20 min of therapeutic exercise 	<ul style="list-style-type: none"> -Soft tissue mobilization and trigger point release with winding technique to bilateral suboccipital regions, upper traps, levator scapulae, paraspinals, scalenes, and active release on the sternocleidomastoid muscles -Grade III manual cervical traction -Occiput –C5 joint mobilizations sustained grade II -Bilateral scapular muscle release while in sidelying. -25 min manual therapy 	<ul style="list-style-type: none"> -Moist hot pack to upper thoracic spine x 10 minutes while in supine simultaneous with manual traction 	<ul style="list-style-type: none"> Beginning: 6/10 End: 4/10

*Empi, 599 Cardigan Road, St. Paul, MN 55176-4099; www.empi.com