

(143)

COPYRIGHT 2019 © BY THE ARCHIVES OF BONE AND JOINT SURGERY

**RESEARCH ARTICLE**

# Acromion Clavicular Joint Reconstruction with LARS Ligament in Acute Dislocation

Alessandro Geraci, MD, PhD, BBM; Alberto Riccardi, MD; Isabella Monia Montagner, MSc; Dario Pilla, MD; Lawrence Camarda, MD, PhD; Antonio D'Arienzo, MD; Michele D'Arienzo, MD

Research performed at Orthopedic Department, San Giacomo Apostolo Hospital, Castelfranco Veneto, Italy

Received: 25 February 2018

Accepted: 28 May 2018

**Abstract**

**Background:** The acromion clavicular joint dislocations are common injuries of the shoulder. The severity is dependent upon the degree of ligamentous injury. Surgical treatment is typically performed in higher grade acromioclavicular separation with several static and dynamic operative procedures with or without primary ligament replacement.

**Methods:** 47 patients with acute Rockwood type III, IV, and V injuries were treated surgically with LARS reconstruction. The success of technique was evaluated by radiographic outcomes for each patient at every follow-up visit (one, three, 12 months), while to assess pain reduction and clinical evaluation Visual Analogue scale score (VAS) and Constant-Murley score (CMA) was performed, respectively. An One Way Analysis of Variance (Kruskal-Wallis test), a multiple comparison Turket test, or a t-test (Mann-Whitney Rank Sum Test) were used when required.

**Results:** Follow-up radiographs revealed maintenance of anatomical reduction in 41 patients, and no bone erosions has been identified. In short-term joint functional recovery has been observed. Indeed, after 12 months pain on the VAS-scale in all groups decreased significantly ( $P < 0.05$ ), and the CMS revealed a significant overall improvement ( $P < 0.05$ ).

**Conclusion:** These data demonstrate that the use of the LARS allows to provide stability to the joint and especially to ensure its natural elasticity, relieving pain and improving joint function already one month post-surgery.

**Level of evidence:** III

**Keywords:** Acromionclavicular joint, Coracoclavicular ligament reconstruction, Coracoid process, Shoulder injury

**Introduction**

The acromion clavicular joint (ACJ) dislocations are common injuries of the shoulder. They account for about 12% of all shoulder injuries in clinical practice, a rate that increases to almost 40% in athletes participating in contact or collision sports (1). The acromioclavicular (AC) capsular ligaments provide the joint stability in the anteroposterior (AP) direction and the extracapsular or coraco-clavicular (CC) ligaments

(conoid and trapezoid) are responsible of vertical stability to the ACJ (2). ACJ and/or CC ligaments are involved in ACJ sprains. The severity of an AC separation is dependent upon the degree of ligamentous injury (3). ACJ dislocation can be classified into six types according to Rockwood with I to III increasing in severity, and IV to VI being the most severe (4). Shoulder or trapezius area pain in general and ACJ pain specifically is common

**Corresponding Author:** Alessandro Geraci, Orthopedic Department, San Giacomo Apostolo Hospital, Castelfranco Veneto, Italy  
Email: [geracialessandro@libero.it](mailto:geracialessandro@libero.it)



THE ONLINE VERSION OF THIS ARTICLE  
[ABJS.MUMS.AC.IR](http://ABJS.MUMS.AC.IR)

following an accidental fall. Patients typically appear with acute pain and swelling at the superior part of the shoulder with limited right shoulder range of motion (ROM). The distal clavicle may appear prominent and feel mobile, so-called "piano-key sign". Standard shoulder radiographs must to be carried out for trauma series. Instead, an axillary view is important for the assessment of AP displacement of the clavicle which could be easily missed (5).

The conservative treatment is the conventional choice for Rockwood type I and II ACJ injuries, and the operative treatment is typically performed in higher grade ACJ separation. In the literature several treatment options are proposed, targeted toward the different types of injuries, but it is difficult to compare the different series (6). Generally, type III to V injuries account for 3.6% of all ACJ dislocations and in the majority of cases a surgical reconstruction is required (22.2%), given the presence of persistent pain that reduced function and overall quality of life (7). For the reconstruction of ACJ separation, several static and dynamic operative procedures with or without primary ligament replacement have been described. Since the CC ligaments are considered the primary suspensory restraint of the ACJ against superior and posterior translation of the distal clavicle with respect to the scapula, current techniques are focused on anatomical restoration of the CC ligament complex (8, 9). The ligaments used to repair the ACJ need to bear the heavy load of the upper limb, thus it is important that they have adequate structure and biomechanical integrity to act as a scaffold while the tissue regenerates. Among the artificial ligaments used to reconstruct there is the LARS (Ligament Augmentation and Reconstruction System). This is a synthetic device, designed to mimic the normal anatomic ligament fibers. The material used is polyethylene terephthalate, an industrial strength polyester fiber, which has the ideal feature for ligament replacement applications (10). LARS can be used to separately reconstruct the trapezoid and conoid ligaments, due to its mechanical properties and biocompatibility (11).

The aim of this study is to describe how the pain and functional limitation given by severe ACJ dislocation can be improved and healed with the reconstruction of the CC ligaments with the LARS system.

### Materials and Methods

This study was approved by ethics committee of our hospital (San Giacomo Hospital, Castelfranco Veneto, Italy), and all patients were well informed of this study after hospitalization. An informed consent was obtained from all patients. A total of 47 patients with ACJ dislocation Rockwood type III, IV and V were treated with surgical LARS reconstruction between February 2012 and September 2016 in our hospital.

### Patients

This study involved 39 men (82.9%) and eight women (17.1%) with a mean age of 44.3 years (range, 21 - 69 years), and most of them have been injured after falling off a bicycle or an accidental fall. Out of these patients,

6.4% (3/47, two males and one female) had type III lesions, 66% (31/47, 27 males and four females) had type IV lesions, and 27.6% (13/47, 10 males and three females) were found to have type V lesions. All 47 patients underwent an anatomic reconstruction of the AC using the LARS ligament, and attended follow-up for at least 12 months. We selected the patients with the following criteria: type III, IV or V ACJ dislocation according to Rockwood classification, mature bone, within three weeks after trauma, a non-surgical history in the injured shoulder, and active lifestyle. The exclusion criteria were as follows: open dislocation, immature bone, neurovascular injury, craniocerebral injury, scapula fracture, humerus fracture, shoulder dislocation, brachial plexus injury, and over 75 years of age. The same group of experienced surgeons performed all surgical treatment.

### Surgical technique

Pre-operative treatment consisted of a single shot antibiotic with the use of cefazolin two gr administered intravenously. Then, surgery had been performed under general anesthesia. The patient was laid in a beach-chair position with the head turned away from the side of the fracture, and a transverse incision was made over the lateral clavicle and ACJ.

In the LARS technique, an incision was made in the transversal plane, extending over the front edge of the clavicle. After identification and exposure of the lateral clavicular and the coracoid process, two transosseous tunnels were made in the lateral clavicle, one on each side of the coracoid. Two oblique drill holes were made in the lateral clavicle, either side of the coracoid, and a hook-like surgical instrument passes the synthetic ligament under the coracoid [Figure 1]. Then the new ligament was introduced into the clavicular tunnels: from the lateral band front to back and the medial band from back to front. Finally the clavicle was reduced. The ligament was fastened on the clavicle with two titanium interference blunted thread screws. Fluoroscopy was used to confirm whether the dislocated ACJ was reduced properly. The AC capsule was closed with large absorbable suture.

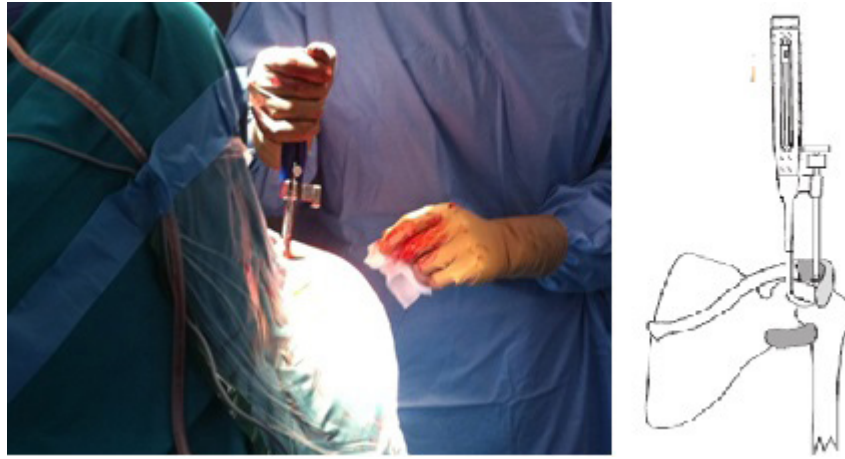### Postoperative assessment and clinical evaluation

The guidelines for postoperative treatment included inpatient surgery, immobilization with Gilchrist-Bandage for five days, and limitation of shoulder ROM to 90° of abduction and anteversion for two weeks under the instruction of a physiotherapist. Furthermore, patients could start shoulder rehabilitation exercises one week after surgery.

Follow-up was performed by the Shoulder Unit of Department of San Giacomo Hospital at one, three, and 12 months after surgery. Patients were assessed with clinical exams and radiographs postoperatively and at every follow-up visit. The radiological examination consisted of anteroposterior and axillary radiographs for each shoulder and bilateral stress radiographs.

### Data collection

The CMS and the VAS were evaluated in order to determine the overall success of the procedure. The CMS



**Figure 1.** Insertion of the artificial ligament around the coracoid. LARS is passed under the coracoid with a hooked instrument.

includes the pain score, ROM, strength measurement, functional assessment, and change in occupation with a maximum score of 100 points. Whereas, the VAS was used to rate the patient's subjective pain. ROM was measured using a goniometer. The patients were also asked to rate their subjective satisfaction at the final follow-up. The clinical evaluation was performed by one independent physician who was not part of the surgical team.

#### **Statistical analysis**

A One Way Analysis of Variance (Kruskal-Wallis test), a multiple comparison Turket test, or a t-test (Mann-Whitney Rank Sum Test) were used when required. Analysis of data was done using the MedCalc (version 12) and SigmaPlot (version 12.3) statistical packages. The *P-value* <0.05 was considered statistically significant.

## **Results**

### **General results**

The surgical time for ACJ reconstruction with LARS ligament was 36.4 minutes (range, 25 - 45 minutes), and the incision length was five cm (range, 3 - 6 cm). The period of hospitalization lasted for up to 24 hours. No tendinous, neurological or arterial iatrogenic lesions were reported from LARS reconstruction. All patients underwent a rehabilitation course with the same exercises for the recovery of shoulder, in the physiotherapy department of San Giacomo Hospital.

### **Functional and radiographic results**

The outcome of shoulder LARS reconstruction was evaluated clinically, functionally and radiographically. All the patients had pain beyond the first few days after surgery (range, 2 - 5 days), that was controlled with oral analgesics. Follow-up radiographs revealed maintenance of anatomical reduction in 41 patients (87.2%) [Figures 2; 3] slight loss of reduction in four patients (8.5 %), and failure of the system in two patients (4.2%) [Figure 4].

In all 47 patients no significant horizontal displacement of the distal clavicle was seen on the axillary view radiographs. Furthermore, we have not had any cases of bone erosion.

The VAS and CMS were used to assess the results obtained during the follow-up period. With regard to the clinical outcomes, already, after one month post-operative the mean VAS scores decrease significantly compared to pre-operative period ( $3.2 \pm 1.8$  and  $7.9 \pm 1.5$ , respectively;  $P < 0.05$ ) [Figure 5]. Furthermore, in the last follow-up visits, the postoperative pain disappears almost entirely (three months,  $0.9 \pm 1.6$ ; 12 months,  $0.7 \pm 1.4$ ). The evaluation of functional assessment with CMS showed a significant activity in shoulder recovery even after one month postoperative compare to pre-operative period ( $72.5 \pm 13.7$  and  $31.8 \pm 9.5$ , respectively;  $P < 0.05$ ), as well as after the other follow-up visits at three and 12 months ( $97.0 \pm 4.0$  and  $99.5 \pm 2.0$ , respectively) [Figure 6]. There were no significant differences in VAS score at the final follow-up between patients with positive outcome after first LARS reconstruction ( $n = 45$ ) and after the second surgery using Kirschner wires (K-wires;  $n$ : two), ( $0.7 \pm 1.4$  vs. 0, respectively;  $P = 0.484$ ), conversely, there were a significant different in CMS ( $99.5 \pm 2$  vs.  $63 \pm 9.9$ , respectively;  $P < 0.001$ ) [Figure 7]. In the two cases of failure, we removed the LARS ligament and the clavicle screws. In order not to aggravate the clavicular bone weakness, we reduced and synthesized the clavicle to the acromial bone with K-wires (strength 1.8 mm), and removed the wires after 60 days [Figure 4 C; D]. The K-wires approach relieves pain in patients but reduces the shoulder recovery due to rigid and mechanical properties that lead to restricted function. Instead, LARS reconstruction approach recovers joint function, relieves pain faster and overall quality of life, since after one month post-treatment.

### **Complications**

The overall complication rate was 4.2% (two

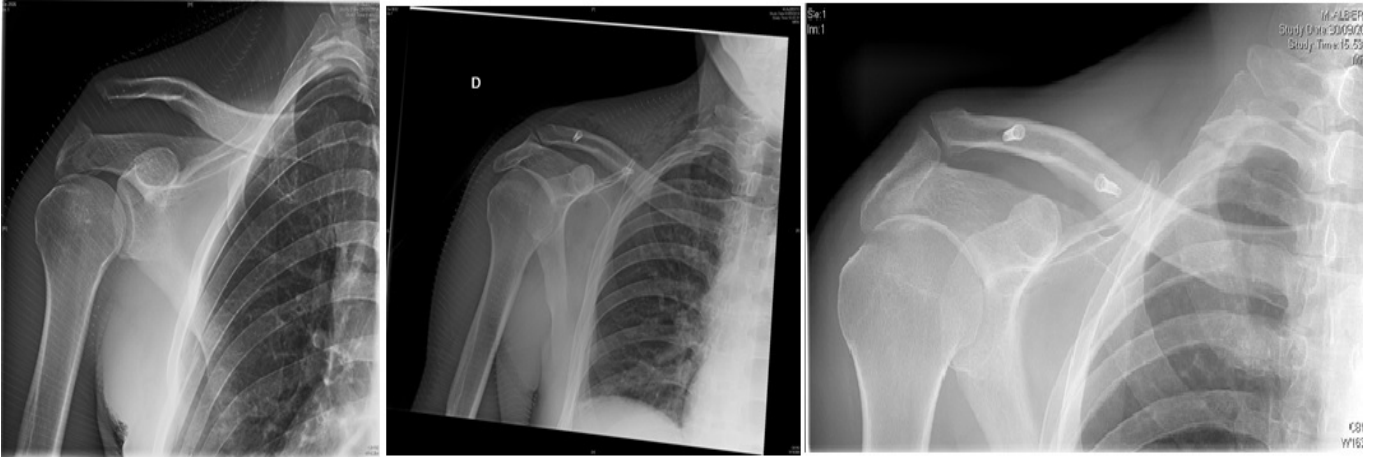


Figure 2. Radiography of acromion clavicular dislocation Rockwood type V. A) Initial injury; B) follow-up performed at three months after surgery; C) final follow-up performed at 12 months after surgery.

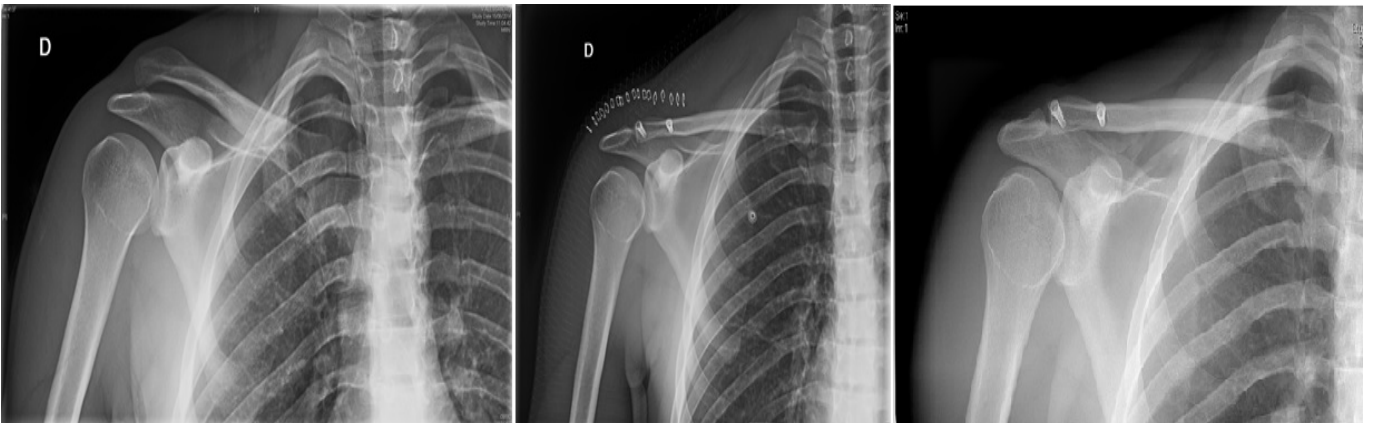


Figure 3. Radiography of acromion clavicular dislocation Rockwood type III. A) Initial injury; B) follow-up performed after surgery; C) final follow-up performed at 12 months after surgery.

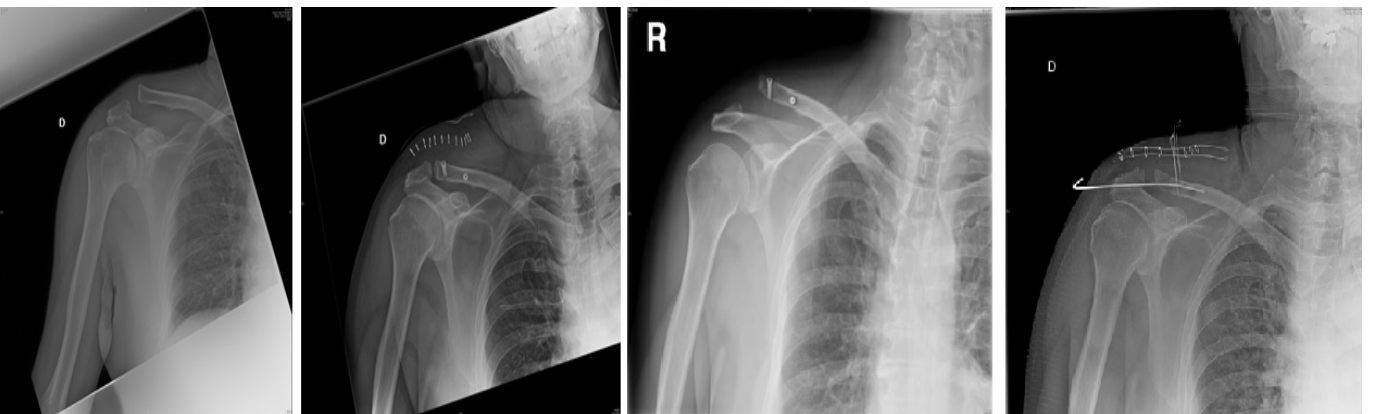


Figure 4. Radiography of a failure of the LARS system in a patient with Rockwood type 3 lesion. A) Initial injury; B) result after the surgery; C) X-ray of the shoulder after severe pain and functional impairment 20 days after surgery; D) surgical revision with K-wires.



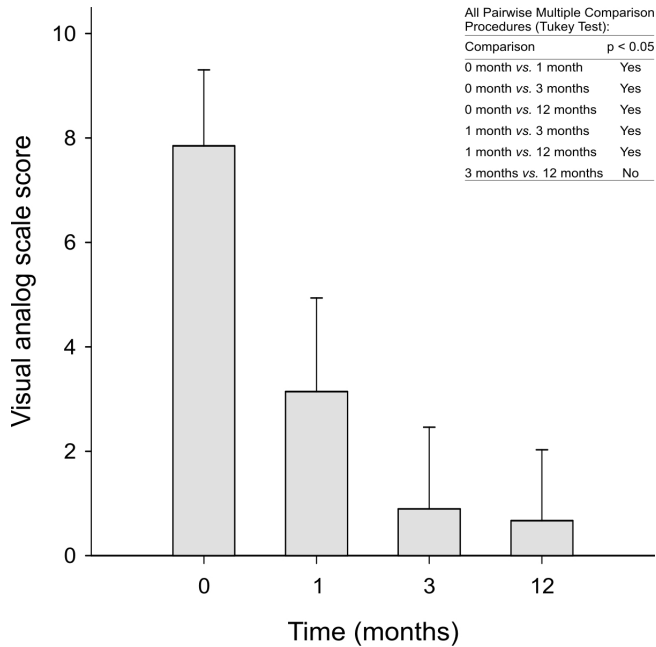


Figure 5. Visual Analogue Scale measure. The vertical histograms refer to the VAS value at different time point (0 month is referred to as basal values, and 1, 3, and 12 months). Data are expressed as means ± S.D, there is a statistically significant difference in the median values among the groups (ANOVA, Kruskal-Wallis test,  $P < 0.001$ ). The table in the upper-right corner represents a multiple comparison analysis with Tukey test, the  $P$ -value  $< 0.05$  was considered statistically significant.

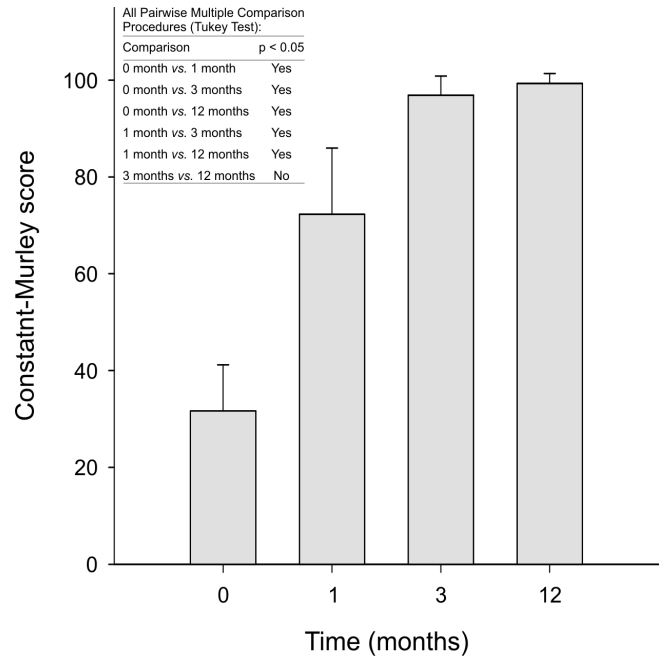


Figure 6. Constant-Murley score measure. The vertical histograms refer to the CMS value at different time point (0 month is referred to as basal values, and 1, 3, and 12 months). Data are expressed as means ± S.D, there is a statistically significant difference in the median values among the groups (ANOVA, Kruskal-Wallis test,  $P < 0.001$ ). The table in the upper-left corner represents a multiple comparison analysis with Tukey test, the  $P$ -value  $< 0.05$  was considered statistically significant.

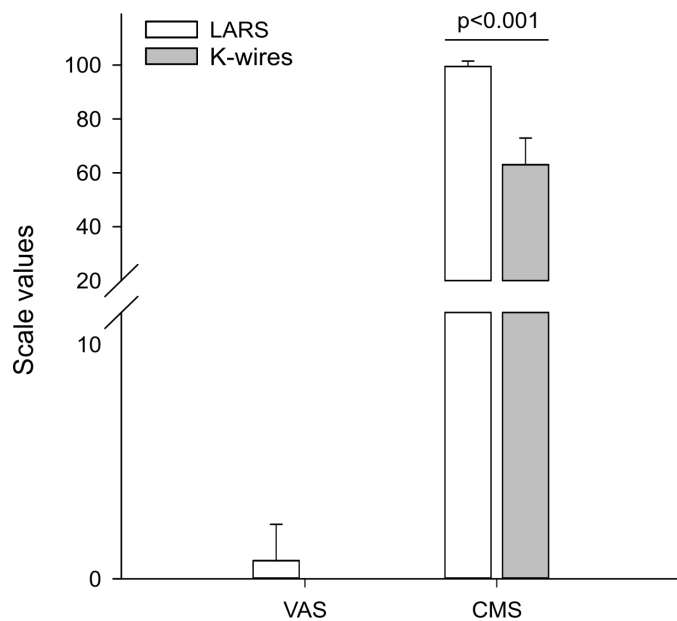


Figure 7. Comparison between the patients who had LARS ligament reconstruction versus those who had K-wire fixation at the final follow-up. There were no significant differences in VAS between the two groups (Mann-Whitney Rank Sum Test,  $P = 0.484$ ), conversely, there were a significant different in CMS (Mann-Whitney Rank Sum Test,  $P < 0.001$ ).

complications). There were two cases, composed of male patients with a type III dislocation joint, that carried out the failure of the LARS reconstruction after about 20 days (range, 18 - 26 days) from the surgical treatment, without having new reported trauma. Subsequently, they underwent conventional open surgery using K-wires, and were relatively satisfied with the results and pain-free. Postoperatively, six of 47 patients have had the development of a keloid at the site of the surgical wound.

### Discussion

Acromion clavicular dislocation is a frequent lesion by direct trauma on the shoulder. The treatment of acute ACJ Rockwood type III dislocation is still debated because of disagreement regarding its optimal management (12). Indeed, current reviews have identified more than 150 different surgical techniques for reconstruction of the ACJ, without identify an appropriate unequivocal approach as a gold standard (6).

If surgical treatment is chosen, many different procedures exist like transarticular techniques (e.g. K-wires), extrarticular implants, such as Bosworth screws, CC loop wires or plate fixation (13-15). However, rigid fixation techniques permit early mobilization, but lead to restricted function due to their mechanical properties. The ACJ is a pivotal point (although technically it is a gliding synovial joint), acting like a strut to help with movement of the scapula resulting in a greater degree of arm rotation. Many studies disclose that the ACJ is a shoulder dynamic element. Inman et al. identified before anyone else the specific ACJ kinematics two-dimensionally, describing approximately 30° of upward rotation at the ACJ with full flexion or abduction of the arm (16). Conway et al. measured superior/inferior (upward/downward rotation) and anterior/posterior (internal/external rotation) changes in position (17). Finally, Teece et al. demonstrated that significant motion occurs at the ACJ during active humeral elevation, contributing to scapular motion on the thorax (18). The kinematics of the acromion clavicular articulation showed that its reconstruction must respect the mutual movement between the clavicle and acromion, and that a reduction and synthesis of this joint with a plate (or K-wire) could change the function of the joint. All of these methods obtain satisfactory results when performed suddenly, but they are associated with hardware breakage, migration, and need for removal (9, 19). The ideal surgical treatment for complete AC dislocation is considered to be restoring separately each CC ligament supporting the joint to achieve optimal clinical outcomes (20, 21). The anatomical reconstruction of CC ligaments reduces complications considerably, especially when such reconstruction is made using materials with a grip strength similar to the one offered by native ligaments (22).

The basis of our technique have shaped up the concept of Fukuda et al., who claims what the ligament reconstruction is essential in restoring the ACJ function (2, 23, 24, 25). The surgical technique described

includes an anatomical reconstruction of the CC and AC ligaments using an artificial ligament that is employed to reconstruct the anatomy and mechanics of the CC space. Literature regarding the LARS system device, its indications, applications, and outcomes is continuously growing. The LARS artificial ligament is made of industrial strength polyester longitudinal mode fibers, and has sufficient strength as a graft for CC reconstruction, 2.500 or 3.600 N, corresponding to 60 or 80 fibers. These fibers are oriented according to the ligament, miming the anatomical fibers. This patented structure allows a high resistance to fatigue, as well as its porosity favors the fibroblastic in growth which isolates the synthetic fibers. Indeed, the biopsies taken from LARS artificial ligament, 6 months after implantation, showed complete cellular and connective tissue in growth in the LARS ligament (26). In vitro fibroblasts and osteoblast-like cells encapsulated the fibers by building a cellular net around them. Moreover, the true anatomical reconstruction, attempting to recreate the conoid and trapezoid ligaments, may be advantageous in preventing both recurrent subluxation and AP instability (6). Lu et al. analyzed 24 patients with acute complete ACJ dislocations that were treated with CC reconstruction using LARS artificial ligaments (11). They disclosed that LARS could provide immediate stability, allow early shoulder mobilization with good functional results, and induce few complications. In other study was compared outcomes of ACJ reconstruction with LARS ligament in professional and non-professional athletes at two years minimum follow-up (27). AC joint reconstruction did not reveal differences in clinical outcomes between groups.

In our study we have carried out an analysis of 47 patients, disclosing a high functional recovery of the shoulder since from the first month postoperative with a major reduction in pain ( $p < 0.05$ ). The implementation of any surgical technique, if compared with conservative treatment, has a higher incidence of complications. None of our patients developed major complication, but some minor complications were detected: failure of the LARS system in two patients, all occurred at the beginning of the surgical learning curve. LARS device is passed through two drill holes in the clavicle and fixed with two interference screws, distributing the load over two points (28). Therefore, transection of the clavicle due to bone erosion is unlikely to occur, and in all of the patients no bone erosions has been identified. The loop fixation techniques seem to be superior in early rehabilitation, as supported by our own data, and do not require a secondary operative procedure for implant removal.

The reconstruction of the dislocated ACJ should ensure the recovery of anatomy and biomechanics of the joint. The hook plates and K-wires used by us in the past gave stiffness and pain, because they were rigid fixation techniques. Moreover, these approaches require a secondary operative procedure for implant removal. The international literature has highlighted the importance of CC ligaments and their influence on the ACJ (29). In our opinion, the use of LARS artificial

ligament allows an anatomical reconstruction of the joint, but above all the restoration of the trapezoid and conoid ligaments are fundamentals for the biomechanics of the ACJ. Furthermore, LARS provides stability to the joint and especially to ensure its natural elasticity, permitting early shoulder mobilization with good functional results and few complications. Due to these remarkable features of LARS ligament technique, this procedure seems to be the better approach in the treatment of ACJ dislocation, disclosing satisfied clinical and radiographic outcomes.

The authors report no conflict of interest concerning the materials or methods used in this study or the findings specified in this paper.

Alessandro Geraci MD PhD BBM

Alberto Ricciardi MD

Dario Pilla MD

Orthopedic Department, San Giacomo Apostolo Hospital,  
Castelfranco Veneto, Italy

Isabella Monia Montagner MSc

Veneto Institute of Oncology IOV - IRCCS, Padua, Italy

Lawrence Camarda MD PhD

Antonio D'Arienzo MD

Michele D'arlenzo MD

Department of Orthopedic Surgery, University of Palermo  
(DiChirOnS), Palermo, Italy

## References

1. Headey J, Brooks JH, Kemp SP. The epidemiology of shoulder injuries in English professional rugby union. *Am J Sports Med.* 2007; 35(9):1537-43.
2. Fukuda K, Craig EV, An KN, Cofield RH, Chao EY. Biomechanical study of the ligamentous system of the acromioclavicular joint. *J Bone Joint Surg Am.* 1986; 68(3):434-40.
3. Monica J, Vredenburg Z, Korsh J, Gatt C. Acute shoulder injuries in adults. *Am Fam Physician.* 2016; 94(2):119-27.
4. Riand N, Sadowski C, Hoffmeyer P. Acute acromioclavicular dislocations. *Acta Orthop Belg.* 1999; 65(4):393-403.
5. Spencer HT, Hsu L, Sodl J, Arianjam A, Yian EH. Radiographic failure and rates of re-operation after acromioclavicular joint reconstruction: a comparison of surgical techniques. *Bone Joint J.* 2016; 98-B(4):512-8.
6. Beitzel K, Obopilwe E, Apostolakis J, Cote MP, Russell RP, Charette R, et al. Rotational and translational stability of different methods for direct acromioclavicular ligament repair in anatomic acromioclavicular joint reconstruction. *Am J Sports Med.* 2014; 42(9):2141-8.
7. Virk MS, Apostolakis J, Cote MP, Baker B, Beitzel K, Mazzocca AD. Operative and nonoperative treatment of acromioclavicular dislocation: a critical analysis review. *JBJS Rev.* 2015; 3(10):1-10.
8. Yoo YS, Tsai AG, Ranawat AS, Bansal M, Fu FH, Rodosky MW, et al. A biomechanical analysis of the native coracoclavicular ligaments and their influence on a new reconstruction using a coracoid tunnel and free tendon graft. *Arthroscopy.* 2010; 26(9):1153-61.
9. Arirachakaran A, Boonard M, Piyapittayanun P, Phiphobmongkol V, Chaijenkij K, Kongtharvonskul J. Comparison of surgical outcomes between fixation with hook plate and loop suspensory fixation for acute unstable acromioclavicular joint dislocation: a systematic review and meta-analysis. *Eur J Orthop Surg Traumatol.* 2016; 26(6):565-74.
10. Iliadis DP, Bourlos DN, Mastrokalos DS, Chronopoulos E, Babis GC. LARS artificial ligament versus ABC purely polyester ligament for anterior cruciate ligament reconstruction. *Orthop J Sports Med.* 2016; 4(6):1-10.
11. Lu N, Zhu L, Ye T, Chen A, Jiang X, Zhang Z, et al. Evaluation of the coracoclavicular reconstruction using LARS artificial ligament in acute acromioclavicular joint dislocation. *Knee Surg Sports Traumatol Arthrosc.* 2014; 22(9):2223-7.
12. De Carli A, Lanzetti RM, Ciompi A, Lupariello D, Rota P, Ferretti A. Acromioclavicular third degree dislocation: surgical treatment in acute cases. *J Orthop Surg Res.* 2015; 10(1):13.
13. Bateman JE. Athletic injuries about the shoulder in throwing and body-contact sports. *Clin Orthop.* 1962; 23(1):75-83.
14. Bosworth BM. Complete acromioclavicular dislocation. *N Engl J Med.* 1949; 241(6):221-5.
15. Vascellari A, Schiavetti S, Battistella G, Rebuzzi E, Coletti N. Clinical and radiological results after coracoclavicular ligament reconstruction for type III acromioclavicular joint dislocation using three different techniques. A retrospective study. *Joints.* 2015; 3(2):54-61.
16. Inman VT, Saunders JB, Abbott LC. Observations of the function of the shoulder joint. 1944. *Clin Orthop Relat Res.* 1996; 330(1):3-12.
17. Conway AM. Movements at the sternoclavicular and acromioclavicular joints. *Phys Ther Rev.* 1961; 41(1):421-32.
18. Teece RM, Lunden JB, Lloyd AS, Kaiser AP, Cieminski CJ, Ludewig PM. Three-dimensional acromioclavicular joint motions during elevation of the arm. *J Orthop Sports Phys Ther.* 2008; 38(4):181-90.
19. Wiesel BB, Gartsman GM, Press CM, Spencer EE Jr, Morris BJ, Zuckerman JD, et al. What went wrong and what was done about it: pitfalls in the treatment of common shoulder surgery. *Instr Course Lect.* 2014; 63(1):85-93.
20. Aslani H, Mirzaee F, Zafarani Z, Salehi S. Modified

- internal fixation technique for acromio-clavicular (AC) joint dislocation: the "Hidden Knot Technique". *Arch Bone Jt Surg.* 2018; 6(1):81-4.
21. Lee KW, Debski RE, Chen CH, Woo SL, Fu FH. Functional evaluation of the ligaments at the acromioclavicular joint during anteroposterior and superoinferior translation. *Am J Sports Med.* 1997; 25(6):858-62.
  22. González-Erreguín V, Morales-Villanueva J. Surgical treatment of acute acromioclavicular dislocation. Preliminary report. *Acta Ortop Mex.* 2015; 29(4):203-6.
  23. Frascini G, Ciampi P, Scotti C, Ballis R, Peretti GM. Surgical treatment of chronic acromioclavicular dislocation: comparison between two surgical procedures for anatomic reconstruction. *Injury.* 2010; 41(11):1103-6.
  24. Modi CS, Beazley J, Zywiol MG, Lawrence TM, Veillette CJ. Controversies relating to the management of acromioclavicular joint dislocations. *Bone Joint J.* 2013; 95-B(12):1595-602.
  25. Nakazawa M, Nimura A, Mochizuki T, Koizumi M, Sato T, Akita K. The orientation and variation of the acromioclavicular ligament: an anatomic study. *Am J Sports Med.* 2016; 44(10):2690-5.
  26. Trieb K, Blahovec H, Brand G, Sabeti M, Dominkus M, Kotz R. In vivo and in vitro cellular ingrowth into a new generation of artificial ligaments. *Eur Surg Res.* 2004; 36(3):148-51.
  27. Marcheggiani Muccioli GM, Manning C, Wright P, Grassi A, Zaffagnini S, Funk L. Acromioclavicular joint reconstruction with the LARS ligament in professional versus non-professional athletes. *Knee Surg Sports Traumatol Arthrosc.* 2016; 24(6):1961-7.
  28. Milewski MD, Tompkins M, Giugale JM, Carson EW, Miller MD, Diduch DR. Complications related to anatomic reconstruction of the coracoclavicular ligaments. *Am J Sports Med.* 2012; 40(7):1628-34.
  29. Torkaman A, Bagherifard A, Mokhatri T, Haghighi MH, Monshizadeh S, Taraz H, et al. Double-button fixation system for management of acute acromioclavicular joint dislocation. *Arch Bone Jt Surg.* 2016; 4(1):41-6.