



Erratic movement disorders disclosing Graves' disease and paralleling thyroid function but not autoantibody levels

Journal of International Medical Research

2019, Vol. 47(3) 1378–1386


© The Author(s) 2019

Article reuse guidelines:

sagepub.com/journals-permissions

DOI: 10.1177/0300060518816873

journals.sagepub.com/home/imr

Sébastien Delhasse¹, Ines Debove²,
Gabiella Arnold-Kunz³, Joseph-André Ghika⁴
and Joelle Nsimire Chabwine^{4,5} 

Abstract

Graves' disease (GD) is an autoimmune pathology characterized by hyperthyroidism and the presence of specific anti-thyroid antibodies. Neurological symptoms such as seizures, cognitive impairment, and tremor can be observed during the course of GD, but more complex movement disorders such as chorea and myoclonus are less frequent. The mechanisms underlying movement disorders in GD are not fully understood. While some authors relate movement disorders to thyroid dysfunction, others claim an autoimmune origin. We herein report a case involving a 60-year-old woman who presented with erratic, intricate movement disorders for which a medical workup revealed GD. During the 2-year follow-up period, her neurological symptoms evolved in parallel with her thyroid function, but not with her autoimmune anti-thyroid antibody level. Her neurological symptoms completely disappeared when she became euthyroid. We herein discuss the complicated clinicobiological relationship between thyroid function and movement disorders. This relationship involves several factors, including the impact of radioactive treatment. The present case emphasizes the importance of including thyroid function screening in the workup of unexplained movement disorders.

¹Internal Medicine Division, Department of Internal Medicine and Geriatrics, Valais Hospital, Sion, Switzerland

²Department of Neurology, Bern University Hospital, Bern, Switzerland

³External consultant in endocrinology; Department of Internal Medicine and Geriatrics, Valais Hospital, Sion, Switzerland

⁴Neurology Unit, Department of Internal Medicine and Geriatrics, Valais Hospital, Sion, Switzerland

⁵Neurology Unit, Medicine Section, Department of Neuroscience and Movement Science, Faculty of Science and Medicine, University of Fribourg, Fribourg, Switzerland

Corresponding author:

Joelle Nsimire Chabwine, Neurology Unit, Medicine Section, Department of Neuroscience and Movement Science, Faculty of Science and Medicine, University of Fribourg, Chemin du Musée 5, Fribourg CH-1700, Switzerland.

Email: joelle.chabwine@unifr.ch



Keywords

Movement disorders, Graves' disease, hyperthyroidism, myoclonus, chorea, tremor, autoimmune

Date received: 13 March 2018; accepted: 12 November 2018

Introduction

Graves' disease (GD), the most frequent cause of hyperthyroidism, is relatively frequent (prevalence of approximately 1%) and predominantly affects middle-aged women. The autoimmune background of this endocrine pathology is now well recognized to involve not only anti-thyroid-stimulating hormone (anti-TSH) receptor antibodies (TRAbs) but also less specific antibodies, such as anti-thyroperoxidase (TPO) and anti-thyroglobulin (Tg) antibodies.^{1,2} Two types of TRAbs have been identified from biological assays performed to assess the effect of such antibodies on thyroid function: stimulating TRAbs, which directly cause GD and lead to hyperthyroidism and goiter, and blocking TRAbs, which lead to hypothyroidism. Nevertheless, the pathological mechanisms of GD are probably complex because the levels and actions of TRAbs do not perfectly correlate with thyroid function, and both stimulating and blocking TRAbs coexist in patients with GD and hypothyroidism. TRAbs are even suggested to trigger a switch from hyperthyroidism to hypothyroidism and to predict the clinical outcome.^{2,3} The diagnosis of GD is straightforward and involves the use of clinical and biological signs of hyperthyroidism (low TSH and high free T3 and T4 serum levels) combined with specific immunological markers (elevated TRAbs) and imaging markers (diffuse goiter, high radioactive tracer uptake on scintigraphy and radioiodine uptake at 24 hours, and increased vascularity on Doppler ultrasound).¹

Tremor, muscle weakness, and cognitive dysfunction are common neurologic

manifestations of hyperthyroidism; however, only a few cases of chorea and myoclonus have been reported in the literature. In general, movement disorders disappear with normalization of thyroid function, but whether these movement disorders are a direct effect of excess thyroid hormones or a consequence of autoimmune dysfunction remains unclear.⁴⁻⁹

We herein describe a 60-year-old patient who was referred to our division for predominant left-limb complex dyskinesia, including high-amplitude myoclonic jerks, mild chorea, and associated postural tremor. Etiological investigations of these erratic involuntary movements led to a diagnosis of hyperthyroidism due to GD. Close clinical and biological follow-up for 2 years allowed us to demonstrate a clear temporal relationship between the intensity of these movement disorders and the serum levels of thyroid hormones, but not between the movement disorders and thyroid autoantibody concentrations. This observation suggests that in the context of GD, thyroid function is better correlated with movement disorders than are autoantibodies. Although the latter contribute to neurological symptoms, their levels are determined by several parameters with complex mechanisms,^{1,7} making it difficult to draw parallels with clinical evolution. Finally, this case report illustrates that thyroid function should be systematically assessed in cases of unexplained movement disorders.

Case report

The ear, nose, and throat division referred a right-handed 60-year-old woman to our

department for consultation regarding unsteadiness in August 2014. Her main complaint was the presence of progressive involuntary movements that predominated in her left upper and lower extremities and had evolved during the past 5 years (oral report by the patient without documentation in the endocrinologist's reports). No trigger or suppressing factor was evident, but walking aggravated her symptoms and caused rare falls. Nausea and positional rotatory vertigo sometimes occurred, but she had no associated hearing loss or tinnitus. She had ocular discomfort, headache, palpitations, and weight loss without a reduction in her food intake. She felt anxious and nervous and could not sleep properly. She did not report fever, fatigue, joint pain, or skin abnormalities. Her medical history was remarkable for high blood pressure treated by losartan 100 mg, chronic back pain for which she took low doses of oral tramadol, chronic diarrhea, and a dry cough of unknown etiology. She was not being treated with neuroleptic drugs. One of her old medical reports from almost 1 year before our evaluation described a thyroid nodule with strictly normal thyroid function (Figure 1; month 0 [M0] in upper graph) and no documented movement disorders (however, when asked about the accuracy of this old report, the patient confirmed already having had a mild but not worrisome bilateral upper extremity tremor). Her movement disorders worsened with time and became so stigmatizing that the patient was socially isolated and suffered conflicting situations with her family and friends (they incorrectly suspected that she was an alcoholic and taking illicit drugs).

The initial neurological examination showed mainly complex asymmetrical limb movements, predominating on the left side (Figure 1; M9 in the upper graph, corresponding to the first visit with a clinical evaluation during which Video 1 [V1] was

obtained; see also Video 1). These movements consisted of a subtle postural high-frequency tremor of approximately 7 Hz in the horizontal axis (Figure 1; z axis on the middle graphs), involving the upper left limb in Video 1 and, later on, both upper limbs as shown in Video 2. The tremor was outweighed by high-amplitude lower limb myoclonic jerky and irregular movements that were visible at rest and with certain postures (particularly when extending the legs while sitting). The tremor was enhanced when walking, thereby causing unsteadiness. Additional discrete upper limb choreic movements and akathisia were possibly present (not shown in Figure 1; see Video 1). The spiral test confirmed the overall erratic feature of the movement disorders, especially on the left side at the first visit (Figure 1; V1, left-most graph in the middle of the figure and left spirals in the lower part of the figure). No other somatic neurological deficit was observed (normal vestibular, cerebellar, and sensory functions; no muscle strength deficit, Parkinsonism, exophthalmos, or cranial nerve abnormalities). There was no evidence of cognitive impairment, and the patient was calm and lucid, although anxious.

Extended etiological investigations showed no brain or spinal cord abnormalities on magnetic resonance imaging. A standard electroencephalogram was normal, as was a cerebrospinal fluid examination (including the absence of 14-3-3 protein). Blood tests revealed no infectious disease (human immunodeficiency virus, *Treponema pallidum*, and *Borrelia burgdorferi* serologies) or systemic autoimmune disease (rheumatoid factor, antinuclear antibody, and lupus anticoagulant); paraneoplastic antibodies were absent, and there was no electrolytic disturbance. We detected no micronutrient or vitamin deficiency (B1, B9, B12, and E), no kidney or liver dysfunction, and no stigma of systemic

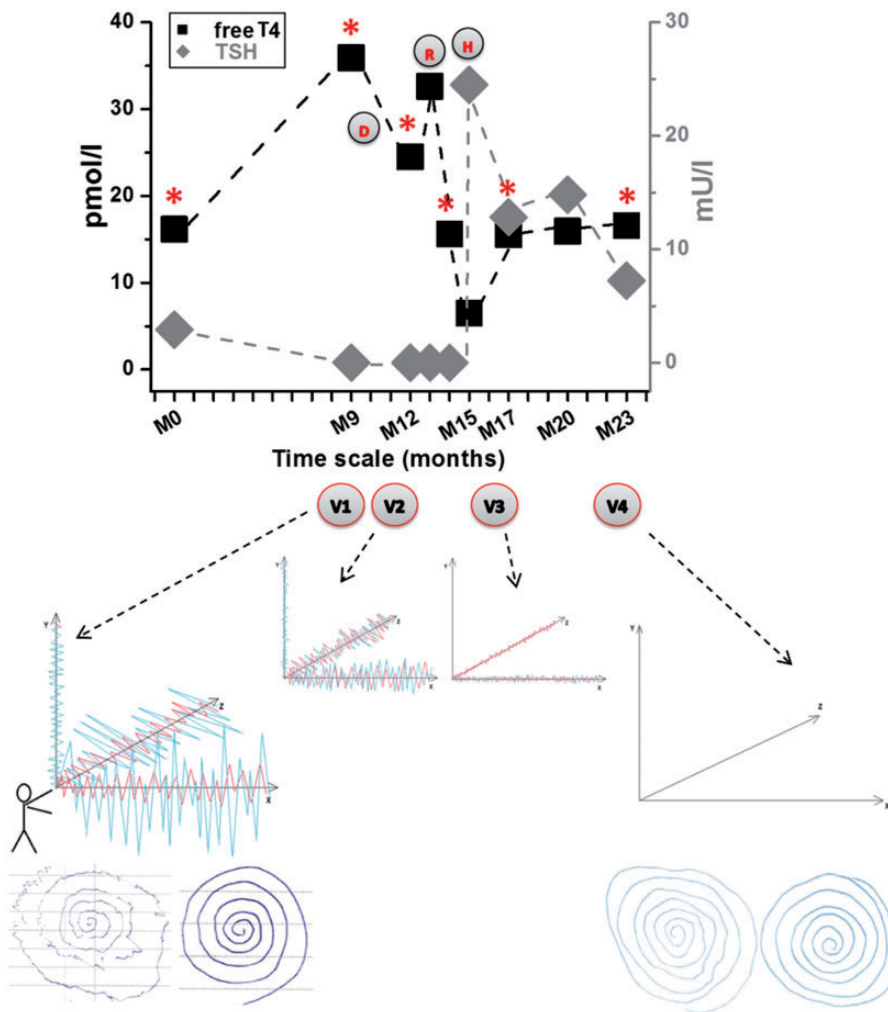


Figure 1. Clinical and biological follow-up of the movement disorders and thyroid function in the present case. *Upper graph:* free T4 level (black squares, left y-axis) and thyroid-stimulating hormone (TSH) level (gray diamonds, right y-axis) plotted against follow-up time (M, months). The x-axis shows the observation time points in months, starting in December 2013 (M0) and ending in November 2015 (M23). The red stars above the time points correspond to the performance of clinical evaluations. The four medical visits [labeled Visit 1 (V1), V2, V3, and V4, respectively] are shown below the corresponding time points, and videos were recorded at these time points. The treatment steps are shown as red letters within circles according to the initial treatment: D (oral anti-thyroid drugs), R (thyroid I31I radiation), and H (thyroid hormonal substitution). *Middle graphs:* schematic representation of myoclonic movements (blue lines) and postural tremor (red lines) on an arbitrary tridimensional axis system, oriented according to the patient's left hand. They correspond to the recorded videos at the medical visits, as shown by the black dashed-arrows. *Bottom figures:* spiral tests performed at the initial and final neurological evaluations. The left figures correspond to the patient's left-hand drawings, and the right figures correspond to the right-hand drawings. Thyroid function as assessed by TSH and free T4 was normal in December 2013 (M0). At the first neurological evaluation in September 2014 (M9), TSH was undetectable in accordance with an elevated free T4 level, and the movement disorders had the highest amplitudes. Myoclonic jerky movements were so intense that

inflammation or rhabdomyolysis. The only abnormalities were undetectable TSH at 0.01 mUI/L (reference range, 0.27–4.20 mUI/L), high serum free T4 at 36 pmol/L (reference range, 10–24 pmol/L) (Figure 1; M9, upper graph), and elevated free T3 at 17.6 pmol/L (reference range, 2.8–4.2 pmol/L). Complementary tests revealed high serum titers of TRAbs, anti-TPO antibodies, and anti-thyroglobulin antibodies (1.4 U/L [reference range, 0.0–0.4 U/L], 206 kUI/L [reference range, 0–16 kUI/L], and 140 kUI/L [reference range, 0–100 kUI/L], respectively). The thyroid gland was diffusely enlarged (30-mL volume) with augmented vascularity on Doppler flow ultrasound (the volume of the previously described nodule was proportionally increased in this context). Thyroid scintigraphy (^{123}I) and radioactive iodine (RAI) uptake consistently showed intense and homogenous tracer uptake into both thyroid lobes (15.0% at 3 hours and 33.5% at 24 hours for RAI).

We therefore diagnosed hyperthyroidism due to GD. Upon reconsidering the patient's clinical course, we determined that general symptoms of thyrotoxicosis (anxiety, weight loss, palpitation, headache, high blood pressure, ocular discomfort, and tremor)¹ had been present but were overlooked, most probably because the erratic involuntary movements misled the diagnosis toward other neurological diseases.

The patient benefited from carbimazole treatment (Figure 1; D (drugs), upper graph of figure) that unfortunately had to be stopped due to severe myalgia but was rapidly switched to propylthiouracil (Figure 1; still D in upper graph). However, the propylthiouracil was also stopped because of adverse effects. Nevertheless, significant clinical amelioration was noticed in parallel with her improved thyroid function (Figure 1; V2 at M12 in the upper graph; second-to-left middle graph) (Video 2) during this short anti-thyroid treatment, whereas slight deterioration in the free T4 level occurred when the oral drugs were definitively stopped. Her heart rate was 80 and 85 beats per minute in November 2014 (Figure 1; M11). Shortly thereafter, the patient was re-evaluated and showed no clinical or biological evidence of myositis or any other muscular or systemic disorder (normal creatine kinase and inflammatory biomarkers, no liver dysfunction, no eosinophilia). Thus, radioiodine therapy could be initiated (Figure 1; R at M13, upper graph). The free T4 level subsequently normalized (Figure 1; M14) before iatrogenic hypothyroidism occurred (Figure 1; M15). Under thyroid hormonal substitution (Figure 1; H initiated at M15, upper graph), the free T4 level returned to normal and the TSH level decreased in parallel, with further improvement in her movement disorder (Figure 1; V3 at M17 in the upper graph and third-to-left middle graph) (Video 3).

Figure 1. Continued.

tremor was difficult to visualize. Both involuntary movements predominated in the horizontal and vertical axes. The spiral test confirmed left-side predominance and the erratic characteristics of the movement disorders. After oral anti-thyroid treatment (D), the patient's thyroid function slightly improved in parallel with both movement disorders (V2 at M12). Reduction of the myoclonic movement amplitude made the tremor more apparent at this point. Thyroid function further deteriorated after anti-thyroid treatment was stopped; radioactive iodine treatment (R) then led to significant lowering of the free T4 level with subsequent TSH elevation, until hypothyroidism developed (M15). After thyroid hormonal substitution (H), thyroid function began to normalize (M17 to M23), while the movement disorders progressively decreased (tremor was the last to disappear). At the last evaluation (M23), no abnormal movements were present and the free T4 level was normal (TSH was close to the reference values). The last spiral test also reflected this marked clinical and biological amelioration.

From February 2015 to August 2015 (Figure 1; M14–M20), her heart rate remained stable at 65 beats per minute. At the end of the observation period, her movement disorders had completely disappeared, her free T4 level remained within the reference range, and her TSH level had almost normalized; additionally, the spiral test was now almost correctly performed on the left and right sides (Figure 1; V4 at M23 in the upper graph; right-most middle graph; right spirals at the bottom of the figure) (Video 4).

This case study was performed in accordance with local and international ethical guidelines, and the patient provided oral and written informed consent for the present publication.

Discussion

The patient described in this case report had progressive irregular and involuntary limb movements, including myoclonic jerk and chorea mixed with high-frequency postural tremor. The workup only revealed suppressed TSH and high free T4 and free T3 levels associated with increased TRAbs. Diffuse goiter with increased vascularity and homogeneously elevated RAI uptake after 24 hours further confirmed the diagnosis of GD.¹ Because the extensive etiological workup was otherwise negative, including tests for systemic diseases associated with similar neurological disorders,^{10,11} we assumed the presence of a causal relationship between the patient's movement disorders and GD.

The involuntary movements observed in our patient were more complex than the usual tremor expected for hyperthyroidism¹² because they included myoclonic jerky limb shaking and discrete choreic movements. During careful observation of the patient at the initial neurological examination, we finally identified the more typical high-frequency tremor in the left upper limb. As the myoclonic jerks disappeared,

the tremor became more evident in both upper limbs. Apart from tremor, chorea is more frequently mentioned than myoclonus (which predominated in our patient) in the context of GD, but both have been reported.^{1,4–9} These findings led us to conclude that the movement disorders observed in our patient were compatible with hyperthyroidism.¹³

The 2-year follow-up showed that the patient's movement disorders evolved in parallel with her thyroid function; i.e., their highest amplitude coincided with the worst hyperthyroid state (undetectable TSH and highest free T4 levels). Similarly, as her thyroid function improved, the amplitude of the movement disorders decreased until they disappeared upon normalization of the thyroid hormone levels.^{4–9} In addition, the nature of the anti-thyroid treatment (anti-thyroid drugs or RAI therapy) did not influence the patient's clinical responsiveness. During the course of treatment, the patient developed post-RAI hypothyroidism. One could therefore question the role of hypothyroidism in the patient's involuntary movements because both hyperthyroidism and hypothyroidism are associated with similar movement disorders.¹⁰ However, we noticed that the involuntary movements were not modified either with or without hypothyroidism. Taken together, these observations suggest a role of thyroid hyperfunction in the occurrence of movement disorders.

In hyperthyroidism, beta-adrenergic stimulation is incriminated as a mechanism leading to tremor and probably also to chorea; indeed, both respond well to beta-blockers.¹⁴ Alternative mechanisms underlying chorea and myoclonus, although not fully elucidated,^{4,7} could involve a direct effect of thyroid hormones on the basal ganglia,⁵ thus supporting our hypothesis of a causal relationship between excessive serum thyroid hormone levels and movement disorders. Conversely, autoimmune

mechanisms have been proposed as an explanation for these two unusual movement disorders in GD.^{1,7} Our patient's neurological symptoms appeared well ahead of her thyroid dysfunction, and the serum levels of all thyroid autoantibodies were high at the initial evaluation, supporting this hypothesis.^{4,7,15} However, despite the disappearance of neurological symptoms at the end of treatment, her anti-TPO antibody level remained steadily high, and her TRAbs even increased up to five fold. Several other observations should be considered to explain this discrepancy. Anti-TSH receptors, as well as anti-TPO antibodies, often increase and remain high for long periods after RAI treatment,¹ especially in patients who develop post-iodine hypothyroidism,¹⁶ as did our patient. This is a reflection of the intensity and duration of the thyroid's autoimmune inflammatory response or gland destruction in reaction to radioiodine therapy rather than a sign of treatment efficiency.^{3,16} Moreover, published reports have indicated that during the disease course, the levels and actions of TRAbs do not perfectly parallel the TSH profile. In addition, our measurements did not differentiate between blocking and stimulating TRAbs,³ which are suggested to trigger the switch from hyperthyroidism to hypothyroidism and vice versa.^{2,3} Thus, it appears that the levels of thyroid autoantibodies are determined by many factors (pathological and therapeutic) and therefore cannot be considered as biomarkers of the neurological outcome in patients with GD, even if autoimmunity at least partially regulates the clinical evolution in such cases.

In summary, a direct effect of excessive thyroid hormone levels is the most plausible mechanism explaining the genesis and disappearance of movement disorders in our patient, although we cannot completely exclude contribution of the autoimmune background of GD.

Although such movement disorders have been reported in patients with hyperthyroidism,^{13,14} a functional origin must also be considered because of the complexity of such movements.¹⁷ Entrainment and distractibility could not be excluded in our case because the patient was not challenged by complex mental tasks and activities during the clinical examination. However, the existence of tremor in more than one axis (i.e., in the vertical and horizontal axes) and variability in the amplitude and axes in the different tasks in the first neurological evaluation supported a functional component.¹⁸⁻²⁰ Nevertheless, the following observations argue against a functional tremor. First, the tremor did not suddenly appear and was not triggered by a stressful life event. Second, no somatization was reported in the patient's medical history, and the tremor's high frequency remained more or less stable throughout consecutive clinical examinations. Finally, the parallel evolution of the tremor and other movement disorders with thyroid function, as well as their occurrence well before the patient developed anxiety (in the context of hyperthyroidism), contends a functional hypothesis. In summary, although it is difficult to rule out functional tremor with certainty and distinguish tremor due to hyperthyroidism, both could coexist in this clinical picture.

Our patient exhibited myalgia, an extremely rare complication of both of the oral anti-thyroid treatments,^{21,22} which vanished after stopping the treatment. The normal clinical and blood test results after disappearance of the muscle pain prevented us from hypothesizing as to the underlying mechanisms.

In conclusion, our patient presented rare and handicapping movement disorders that were presumably due to hyperthyroidism in the context of GD, although we could not completely exclude a functional component. During the 2-year clinical and

biological follow-up, we documented that the neurological symptoms were well correlated with the thyroid hormone levels rather than with markers of autoimmunity (probably influenced by many other parameters). Similar movement disorders are associated with autoimmune Hashimoto's encephalopathy and respond well to corticosteroids^{23,24} (even if elevation of anti-TPO antibodies does not seem to be linked to the severity of neurological symptoms²³). In contrast, our case allows for consideration of non-autoimmune mechanisms at the origin of such a complex dyskinetic syndrome. This case report emphasizes that inexplicable movement disorders warrant thyroid function evaluation, especially because treating thyroid dysfunction such as hyperthyroidism efficiently alleviates neurological symptoms.


Declaration of conflicting interest

The authors declare that there is no conflict of interest.

Funding

This research received no specific funding from any funding agency in the public, commercial, or not-for-profit sectors.

ORCID iD

Joelle Nsimire Chabwine  <http://orcid.org/0000-0002-5470-9272>

References

- Burch H and Cooper D. Management of Graves disease: a review. *JAMA* 2015; 314: 2544–2554.
- McLachlan S and Rapoport B. Thyrotropin-blocking autoantibodies and thyroid-stimulating autoantibodies: potential mechanisms involved in the pendulum swinging from hypothyroidism to hyperthyroidism or vice versa. *Thyroid* 2013; 23: 14–24.
- Orgiazzi J, Madec A-M and Ducottet X. The role of stimulating, function-blocking and growth-blocking anti-TSH receptor antibodies (TRAbs) in GD, Hashimoto's disease and in atrophic thyroiditis. *Ann Endocrinol (Paris)* 2003; 64: 31–36.
- Seeherunvong T, Diamantopoulos S and Berkovitz G. A nine year old girl with thyrotoxicosis, ataxia, and chorea. *Brain Dev* 2007; 29: 660–661.
- Yu J-H and Weng Y-M. Acute chorea as a presentation of Grave disease: case report and review. *Am J Emerg Med* 2009; 27: 369.e361–369.e363.
- Park J, Kim J, Park S, et al. Asymmetric chorea as presenting symptom in Graves' disease. *Neurol Sc* 2012; 33: 343–345.
- Kaminska A, Kaminski M, Nowaczewska M, et al. Chorea, convulsive seizures and cognitive impairment in a patient with autoimmune thyroid disease. *Neurol Sci* 2013; 34: 263–264.
- Nagaoka T, Matsushita S, Nagai Y, et al. A woman who trembled, then had chorea. *Lancet* 1998; 351: 1326.
- Loh L, Hum A, Teoh H, et al. Grave's disease associated with spasmodic truncal flexion. *Parkinsonism Relat Disord* 2005; 11: 117–119.
- Alarcon F and Gimenez-Roldan S. Systemic diseases that cause movement disorders. *Parkinsonism Relat Disord* 2005; 11: 1–18.
- Sudo K and Tashiro K. Hyperthyroidism-associated chorea. *Lancet* 1998; 352: 239.
- Hoogendam Y, van der Lijn F, Vernooij M, et al. Older age relates to worsening of fine motor skills: a population-based study of middle-aged and elderly persons. *Front Aging Neurosci* 2014; 6: 259. doi: 210.3389/fnagi.2014.00259.
- Smaga S. Tremor. *Am Fam Physician* 2003; 68: 1545–1552.
- Kung AW. Neuromuscular complications of thyrotoxicosis. *Clin Endocrinol (Oxf)* 2007; 67: 645–650. DOI: 10.1111/j.1365-2265.2007.02909.x.
- Canton A, de Fabregas O, Tintore M, et al. Encephalopathy associated to autoimmune thyroid disease: a more appropriate term for an underestimated condition? *J Neurol Sci* 2000; 176: 65–69.
- Chiovato L, Fiore E, Vitti P, et al. Outcome of thyroid function in Graves' patients

- treated with radioiodine: role of thyroid-stimulating and thyrotropin-blocking antibodies and of radioiodine-induced thyroid damage. *J Clin Endocrinol Metab* 1998; 83: 40–46.
17. Schwingenschuh P and Deuschl G. Chapter 19 - functional tremor. In: Hallett M, Stone J and Carson A (eds) *Handbook of clinical neurology*. Amsterdam: Elsevier, 2016, pp. 229–233.
 18. Nowak D and Fink G. Psychogenic movement disorders: aetiology, phenomenology, neuroanatomical correlates and therapeutic approaches. *Neuroimage* 2009; 47: 1015–1025.
 19. Alty J and Kempster P. A practical guide to the differential diagnosis of tremor. *Postgrad Med J* 2011; 87: 623–629.
 20. Bhatia K and Schneider S. Psychogenic tremor and related disorders. *J Neurol* 2007; 254: 569–574.
 21. Hyeseon K, Jinsup K, Rimm H, et al. Elevation of serum creatine kinase during methimazole treatment of Graves disease in a 13-year-old girl and a literature review of similar cases. *Ann Pediatr Endocrinol Metab* 2015; 20: 106–109.
 22. Bou Khalil R, Abou Salbi M, Sissi S, et al. Methimazole-induced myositis: a case report and review of the literature. *Endocrinol Diabetes Metab Case Rep* 2013; 2013: 130008. doi: 130010.131530/EDM-130013-130008.
 23. Gauthier A and Baehring J. Hashimoto's encephalopathy mimicking Creutzfeld-Jakob disease. *J Clin Neurosci* 2017; 35: 72–73.
 24. Santoro D, Colombo I, Ghione I, et al. Steroid-responsive Hashimoto encephalopathy mimicking Creutzfeld-Jakob disease. *Neurol Sci* 2011; 32: 719–722.